

## Movement Disorders Clinical Practice - Case Reports

### Holmes tremor-like phenotype in DYT1 dystonia

Sergio Rodriguez-Quiroga, MD<sup>1</sup>; Dolores Gonzalez-Moron, MD<sup>1</sup>; Alberto J Espay, MD,<sup>id</sup>  
MSc<sup>2</sup>; Marcelo A Kauffman, MD, PhD<sup>1-3</sup>

1- Consultorio y Laboratorio de Neurogenética, Centro Universitario de Neurología "José María Ramos Mejía" y División Neurología, Hospital JM Ramos Mejía, Facultad de Medicina, UBA, Argentina

2- UC Gardner Neuroscience Institute, Department of Neurology, Gardner Center for Parkinson's disease and Movement Disorders, University of Cincinnati, Ohio, USA

3- Programa de Medicina de Precision y Genomica Clinica. Instituto de Investigaciones en Medicina Traslacional. Facultad de Ciencias Biomédicas. Universidad Austral-CONICET

Sergio Rodríguez Quiroga [sergiorodriguez@dr.com](mailto:sergiorodriguez@dr.com)

Dolores Gonzalez Moron [doloresgm@gmail.com](mailto:doloresgm@gmail.com)

Alberto J Espay [aespay@gmail.com](mailto:aespay@gmail.com)

Marcelo A Kauffman [marcelokauffman@gmail.com](mailto:marcelokauffman@gmail.com)

#### All correspondence to:

Alberto J. Espay, MD, MSc, University of Cincinnati

260 Stetson St., Suite 2300, Cincinnati, OH 45267-0525, USA

P: 513-558-4035 - F: 513-558-7015 - E-mail: [aespay@gmail.com](mailto:aespay@gmail.com)

This article has been accepted for publication and undergone full peer review but has not been through the copyediting, typesetting, pagination and proofreading process which may lead to differences between this version and the Version of Record. Please cite this article as an 'Accepted Article', doi: 10.1111/mdc3.12585

This article is protected by copyright. All rights reserved.

## Word Count:

Text: 797 words

## Running title:

Holmes tremor-like phenotype in DYT1 dystonia

## Keywords:

Holmes Tremor; Neurogenetics; TOR1A gene; Dystonia; DYT1; Whole Exome Sequencing.

Holmes tremor is characterized by a combination of a flexion-extension resting, postural, and action tremor, most often due to mesencephalic lesions affecting the nigrostriatal and cerebello-thalamo-cortical pathways [1]. On the other hand, dystonic tremor represents a jerky postural and action tremor, which if severe enough may include a resting component and may also arise from cerebellar and nigrostriatal dysfunction [2]. We here present a patient with a four-decade history of progressive tremor, initially interpreted as Holmes tremor with a dystonic (pseudospastic) gait, in whom whole exome sequencing (WES) demonstrated a pathogenic *TOR1A* deletion. This case highlights two important clinical points: (1) the need for proper semiologic interpretation: direct DYT1 testing could have been entertained should the tremor have been properly categorized as dystonic rather than cerebellar at the outset; and (2) the phenotypic variability of DYT1 dystonia, with tremor as a presenting and disabling feature, separate from the body part affected by dystonia (“tremor associated with dystonia”)[3, 4].

Born from nonconsanguineous parents and with no past medical or family history of relevance, this 52-year-old man presented with progressive tremor since the age of 9. His tremor was first noted in his right hand, extending sequentially, over several years, to the left hand, lower limbs and head. Trials with propranolol, primidone and levodopa yielded

no benefits. He was thought to have mild dysarthria (in retrospect, speech-induced orofacial dystonia, with an intermittent lingual component) but no other cranial nerve abnormalities. He showed an irregular, low-frequency (4-5Hz) (Figure 1), high-amplitude head, trunk, and appendicular tremor at rest, worse with posture, and worse yet with action, suggestive of Holmes tremor (Video 1, Segment 1). The amplitude of the tremor on finger-to-nose testing, however, varied depending on how the movements changed the elbow and hand posture, a position-dependent dystonic feature overlooked at the time of this assessment (Video 1, Segment 2). Amplitude and speed of movements were normal, as was muscle tone. His gait showed stereotypical jerky movements of the left leg to a greater extent than the right, as “*if he was kicking a ball*” (Video 2, Segment 1). Notably, the gait phenotype improved when walking backwards and running (Video 2, Segment 2). No abnormalities were observed in stride length, balance, turning, and arm swinging. Furthermore, he was able to ride his bicycle without difficulties (Video 2, Segment 3). Collectively, these findings were initially interpreted as Holmes tremor associated with a dystonic gait. Brain and spine neuroimaging were normal as were extensive metabolic investigations, including, copper, ceruloplasmin, creatinine-kinase, alpha-fetoprotein, urine organic acids, and plasma amino acids. WES performed by a diagnostic laboratory (Argenomics; Buenos Aires, Argentina) on purified DNA samples using the Agilent SureSelect Human All Exon V5-Kit (Agilent-Technologies, Santa Clara-CA) on an Illumina sequencing system identified a DYT1-causing deletion in *TOR1A* (NM\_000113.2:c.907\_909delGAG;p.Glu303del), a variant known worldwide as a recurrent cause of DYT1.

Although tremor is part of the phenotypic spectrum of DYT1 dystonia[5], the severe tremor phenotype of our patient, and the sequential worsening from rest to posture to action, was interpreted as cerebellar in nature. As a result this patient was considered to have a “complicated ataxia” with leg dystonia rather than an “isolated dystonia,” expressed as dystonic tremor and dystonic gait [6]. This misinterpretation directed the laboratory investigations away from dystonia genes, such as DYT1 and DYT6. In retrospect, after the WES finding was made available, the phenomenology of the tremor was revisited, with such overlooked features as the position-dependent alteration of the tremor amplitude reinterpreted as supportive of a dystonic rather than cerebellar (Holmes-like) tremor. Although late-onset rest tremor occurring as a progression of DYT1-dystonia has been

reported before [7], to our knowledge, this is the first report of a DYT1 patient presenting with a dystonic tremor severe enough to suggest a cerebellar outflow or Holmes tremor.

Although there is uncertainty in the assignment of disease causality for sequence variants identified in genomic testing, the uncertainty is magnified in the context of a genetic finding of known reduced penetrance, if unambiguously pathogenic, in *TOR1A* [8]. However, the overall phenotype was consistent with isolated dystonia, with an unusual dystonic gait and a prominent Holmes-like but ultimately dystonic tremor, expanding the phenotypic spectrum for this genetic disorder.

The *TOR1A* gene has been shown to affect the intrinsic activity of Purkinje cells and outflow neurons in the deep cerebellar nuclei [9]. Thus, in a clinico-pathologic twist, the dystonic features of the tremor may have been at least partly determined by cerebellar dysfunction[2].

In sum, this case illustrates the difficulty of detecting dystonia in tremulous DYT1 patients, which may be especially challenging with aging, and the importance of genomic information in assisting the interpretation of clinical features in the same manner that clinical interpretation will continue to be important in giving context to testing results in the era of next-generation sequencing.

**Author Roles:**

(1) Research project: A. Conception, B. Organization, C. Execution; (2) Statistical Analysis: A. Design, B. Execution, C. Review and Critique; (3) Manuscript: A. Writing of the first draft, B. Review and Critique.

S.R.Q.: 1A,1C,3A

D.G.M.: 1A,1C,3B

A.J.E.: 1A,1B,1C,3B

M.A.K.: 1A,1B,1C,3B

## Conflict of Interest Disclosures

**Dr. Rodríguez-Quiroga** has received scholarship support from Ministry of Health of Buenos Aires City.

**Dr. Gonzalez-Moron** has received scholarship support from Argentinean National Science Council (CONICET).

**Dr. Espay** has received grant support from NIH, Great Lakes Neurotechnologies and the Michael J Fox Foundation; personal compensation as a consultant/scientific advisory board member for Abbvie, TEVA, Impax, Merz, Acadia, Cynapsus, Lundbeck, and USWorldMeds; publishing royalties from Lippincott Williams & Wilkins, Cambridge University Press, and Springer; and honoraria from Abbvie, UCB, USWorldMeds, Lundbeck, Acadia, the American Academy of Neurology, and the Movement Disorders Society.

**Dr. Kauffman** has received grant support from Ministry of Health of Buenos Aires City, Argentinean National Science Council (CONICET) and Argentinean Ministry of Science and Technology. He serves as Associate Editor of the journal Neurologia Argentina.

### **Ethical Compliance Statement:**

The authors confirm that the approval of an institutional review board was not required for this work. We confirm that we have read the Journal's position on issues involved in ethical publication and affirm that this work is consistent with those guidelines

## References

- [1] Raina GB, Cersosimo MG, Folgar SS, Giugni JC, Calandra C, Paviolo JP, et al. Holmes tremor: Clinical description, lesion localization, and treatment in a series of 29 cases. *Neurology*. 2016;86:931-8.
- [2] Sadnicka A, Teo JT, Kojovic M, Pareses I, Saifee TA, Kassavetis P, et al. All in the blink of an eye: new insight into cerebellar and brainstem function in DYT1 and DYT6 dystonia. *Eur J Neurol*. 2015;22:762-7.
- [3] Deuschl G, Bain P, Brin M. Consensus statement of the Movement Disorder Society on Tremor. Ad Hoc Scientific Committee. *Mov Disord*. 1998;13 Suppl 3:2-23.
- [4] Erro R, Rubio-Agusti I, Saifee TA, Cordivari C, Ganos C, Batla A, et al. Rest and other types of tremor in adult-onset primary dystonia. *J Neurol Neurosurg Psychiatry*. 2014;85:965-8.
- [5] Klepitskaya O, Neuwelt AJ, Nguyen T, Leehey M. Primary dystonia misinterpreted as Parkinson disease: Video case presentation and practical clues. *Neurol Clin Pract*. 2013;3:469-74.
- [6] Albanese A, Bhatia K, Bressman SB, Delong MR, Fahn S, Fung VS, et al. Phenomenology and classification of dystonia: a consensus update. *Mov Disord*. 2013;28:863-73.
- [7] Stamelou M, Edwards MJ, Bhatia KP. Late onset rest-tremor in DYT1 dystonia. *Parkinsonism Relat Disord*. 2013;19:136-7.
- [8] Martino D, Gajos A, Gallo V, Cif L, Coubes P, Tinazzi M, et al. Extragenetic factors and clinical penetrance of DYT1 dystonia: an exploratory study. *J Neurol*. 2013;260:1081-6.
- [9] Fremont R, Tewari A, Angueyra C, Khodakhah K. A role for cerebellum in the hereditary dystonia DYT1. *Elife*. 2017;6.

## Figure Legend

**Figure 1.** Graphical representation of the patient's tremor, where a dominant frequency of about 4.88 Hz was determined using a mobile app.

## Video Legends

### 1. Appendicular tremor suggesting Holmes tremor

*Segment 1:* Coarse, irregular, large amplitude, 4-5Hz resting and postural tremor affecting both upper limbs, lower limbs, trunk and head.

*Segment 2:* An increase in the tremor amplitude was observed during maneuvers assessing its action and intentional components. A decrease in amplitude was achieved with certain postures in the forearm and hand.

## Part 2. Pseudospastic (dystonic) Gait

*Segment 1:* A bilateral hand rest tremor with normal arm swing is shown during gait, which showed normal stride length, base, balance, and turns. The left leg showed a stereotypical jerky movement during the swing phase as “*if he was kicking a ball while walking*”, typical of dystonic gait.

*Segment 2 and 3:* Gait improved substantially walking backwards and running, supporting its dystonic nature. He was able to ride his bicycle almost without difficulties.

### **Consent for Publication of Photos, Videos, and Other Identifying Materials**

The subject described in this manuscript authorized for the publication of photographs and video tapes referred to his person. The subject is aware that these materials may appear in print and online and the public may have access to them.

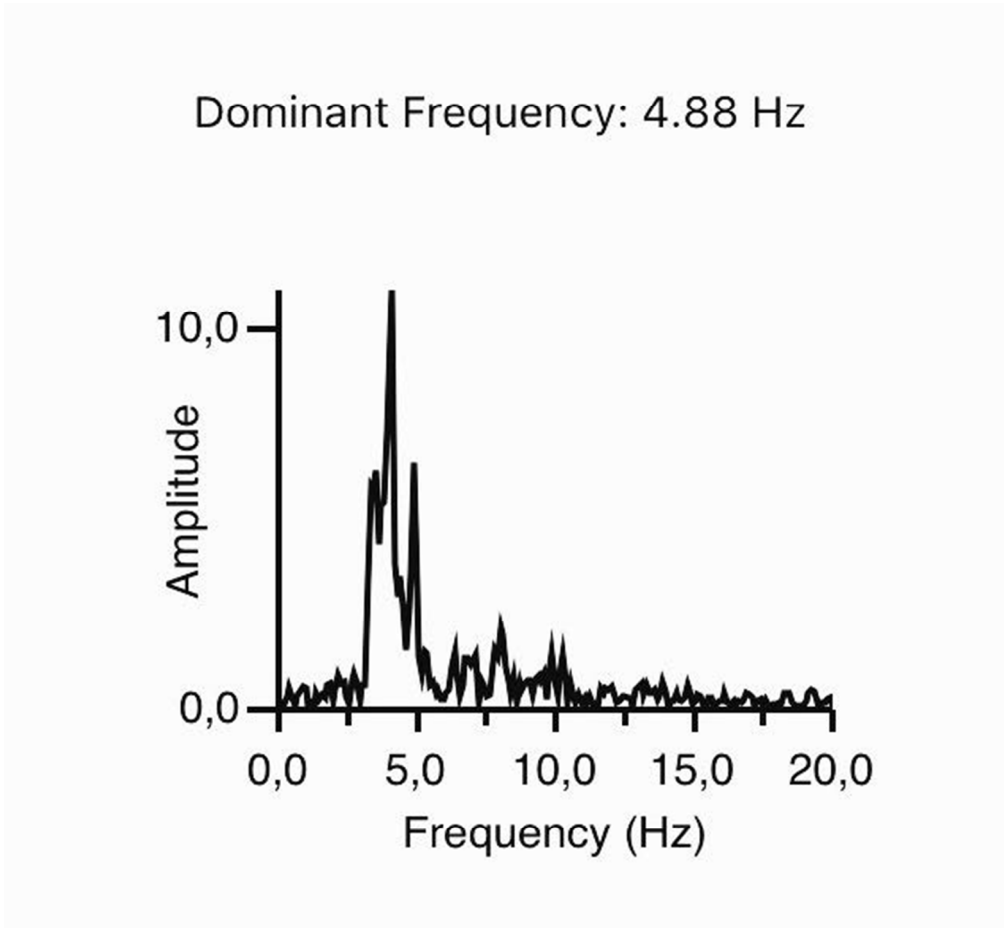


Figure 1. Graphical representation of the patient's tremor, where a dominant frequency of about 4.88 Hz was determined using a mobile app