


Accepted Manuscript

Fatal canine encephalitozoonosis in Latin America, first report

Gabriela Cintia Postma, Lais Pardini, Silvana Carnevale, Elena Gregnoli, María Alejandra Quiroga, María Cecilia Venturini, Leonardo Minatel



PII: S2405-9390(17)30132-6
DOI: doi:[10.1016/j.vprsr.2017.11.007](https://doi.org/10.1016/j.vprsr.2017.11.007)
Reference: VPRSR 147

To appear in: *Veterinary Parasitology: Regional Studies and Reports*

Received date: 23 June 2017
Revised date: 5 November 2017
Accepted date: 16 November 2017

Please cite this article as: Gabriela Cintia Postma, Lais Pardini, Silvana Carnevale, Elena Gregnoli, María Alejandra Quiroga, María Cecilia Venturini, Leonardo Minatel , Fatal canine encephalitozoonosis in Latin America, first report. The address for the corresponding author was captured as affiliation for all authors. Please check if appropriate. *Vprsr*(2017), doi:[10.1016/j.vprsr.2017.11.007](https://doi.org/10.1016/j.vprsr.2017.11.007)

This is a PDF file of an unedited manuscript that has been accepted for publication. As a service to our customers we are providing this early version of the manuscript. The manuscript will undergo copyediting, typesetting, and review of the resulting proof before it is published in its final form. Please note that during the production process errors may be discovered which could affect the content, and all legal disclaimers that apply to the journal pertain.

Fatal canine encephalitozoonosis in Latin America, first report

Gabriela Cintia Postma¹, Lais Pardini^{2,3}, Silvana Carnevale⁴, Elena Gregnoli⁵, María Alejandra Quiroga⁶, María Cecilia Venturini², Leonardo Minatel¹

¹ Universidad de Buenos Aires, Facultad de Ciencias Veterinarias, Cátedra de Patología, Chorroarín 280, C1427CWO, Buenos Aires, Argentina. ² Laboratorio de Inmunoparasitología, Facultad de Ciencias Veterinarias, Universidad Nacional de La Plata, Argentina. ³ Consejo Nacional de Investigaciones Científicas y técnicas, Buenos Aires, Argentina. ⁴ Departamento de Parasitología, INEI-ANLIS “Dr. Carlos G. Malbrán”, Buenos Aires, Argentina. ⁵ Actividad privada. ⁶ Laboratorio de Patología Especial Veterinaria, Facultad de Ciencias Veterinarias, Universidad Nacional de La Plata, Argentina.

Corresponding author: Gabriela Cintia Postma. Full telephone: +54114580-2821. E-mail address: gpostma@fvvet.uba.ar

Correspondence address: Chorroarín 280, C1427CWO, Buenos Aires, Argentina. E-mail address: gpostma@fvvet.uba.ar

Abstract

Encephalitozoon cuniculi is an obligate, intracellular microsporidian organism capable of establish infection in a wide variety of animals. In carnivores it may cause a sporadic, severe disease in the first few months of life, which usually culminates with the death of the animal. The objective of this study was to report a natural fatal case of encephalitozoonosis in a puppy from Argentina. Clinical signs included reduced appetite, depression, vocalizing, weight loss, weakness, convulsions and recumbency. No significant gross lesions were noticed at necropsy. Microscopically, severe, diffuse, lymphocytic encephalitis was seen. Large cytoplasmic vacuoles containing spores, morphologically compatible with *E. cuniculi*, were present within endothelial cells of brain and kidney, in renal tubular epithelium and hepatocytes. *Encephalitozoon cuniculi* DNA was detected by PCR in the kidney. Antibody titers to *E. cuniculi* in serum from the surviving puppies and the dam were $\geq 1:200$. This report contributes to our understanding of neurologic disease in puppies. Encephalitozoonosis should be considered as a differential diagnosis in cases of fatal encephalitis in puppies.

Keywords

Encephalitozoon cuniculi; canine; puppy; encephalitis; nephritis

1. Introduction and objective

Encephalitozoon cuniculi is an obligate, intracellular microsporidian organism capable of establishing infection in a wide variety of animals including mice (Malherbe and Munday, 1958), rats (Müller-Doblies et al., 2002), rabbits (Malherbe and Munday, 1958), guinea pigs (Moffatt and Schiefer, 1973), non-human primates (Seibold and Fussell, 1973; Zeman and Baskin, 1985; Guscetti et al., 2003), horses (Patterson-Kane et al., 2003) and carnivores (Plowright, 1952; Basson et al., 1966; van Rensburg and du Plessis, 1971; Vavra et al., 1971; Shadduck et al., 1978; Bjerkas and Nesland, 1987; Snowden et al., 2009; Greene, 2012; Cantile and Youssef, 2015). This organism may also affect immunocompromised humans (Franzen et al., 1995; Mertens et al., 1997; Tosoni et al., 2002). Subclinical asymptomatic infection is common in rabbits and laboratory rodents. Conversely, in carnivores *E. cuniculi* may cause a sporadic, severe disease during the first months of life, that usually culminates in death (Wasson and Peper, 2000; Greene, 2012; Cantile and Youssef, 2015). Carnivores most often infected with *E. cuniculi* include the farmed arctic fox (*Vulpes lagopus*), in which high mortality may occur (Mohn et al., 1974; Bjerkas and Nesland, 1987), and occasionally dogs (*Canis lupus familiaris*) (Basson et al., 1966; Shadduck et al., 1978; Snowden et al., 2009), and cats (van Rensburg and du Plessis, 1971). Spontaneous canine encephalitozoonosis has been reported in Europe (Vavra et al., 1971), Africa (Plowright, 1952; Basson et al., 1966), and North America (Shadduck et al., 1978; Cole et al., 1982; Snowden et al., 2009). The objective of this study was to report a spontaneous fatal case of canine encephalitozoonosis in Argentina.

2. Materials and methods

2.1 Case

A one month old female puppy was submitted for necropsy to the Pathology Veterinary Service of Buenos Aires University, Buenos Aires, Argentina. The clinical history was provided by the referring veterinarian. A pregnant stray bitch, with her litter of six puppies was adopted. One puppy died at the age of one month presumably due to cranial trauma, and was not examined. Three other puppies became ill, showing neurologic signs. Clinical signs included reduced appetite, depression, constant crying, weight loss, weakness, convulsions and recumbency. Two of the sick puppies died spontaneously, one of which was submitted for necropsy.

2.2 Samples

A complete necropsy was performed. Tissues were collected and fixed in 10% neutral buffered formalin, routinely embedded in paraffin wax, sectioned at 5 μm , and stained with haematoxylin and eosin, and Gram (Gram-Twort Technique). Samples of kidney were stored at $-20\text{ }^{\circ}\text{C}$ until processed for molecular diagnosis for *E. cuniculi* detection (see below). Serum samples were obtained from the dam and her three surviving puppies for serology.

2.3 PCR

DNA was extracted from frozen kidney at the Immunoparasitology Laboratory (LAINPA) of the Faculty of Veterinary Sciences, La Plata University, Buenos Aires, Argentina, using a commercial kit (Promega Wizard Genomic DNA Purification Kit, Madison, USA) according to the manufacturer's instructions and was stored at -20°C until it was used for PCR analysis.

The nested PCR technique based on the small subunit ribosomal RNA (SSU-RNA) gene region was performed at the Department of Parasitology, INEI-ANLIS "Dr. Carlos G. Malbrán". The first round reactions were carried out employing the generic primers for Microsporidia 18f (5'-CACCAGGTTGATTCTGCC-3') and 1492r (5'-GGTACCTTGTTACGACTT-3') (Weiss and Vossbrinck, 1998). For the second round a set of *E. cuniculi* specific primers ECUNF (5'-ATGAGAAGTGA-TGTGTGTGCG-3'), and ECUNR (5'-TGCCATGCACTCACAGGCATC-3') were used (Visvesvara et al.,

1994). The PCR amplification conditions were as follows: initial denaturation of the DNA at 95 °C for 5 min, 35 cycles of denaturation at 95 °C for 30 s, primer annealing at 55 °C for 30 s (45 °C for 18f:1492r), elongation at 72 °C for 90 s, and final extension at 72 °C for 9 min. The PCR products were separated by agarose gel electrophoresis, and the resulting bands were visualized using ethidium bromide under UV light.

2.4 Serology

Serum samples were tested at LAINPA for *E. cuniculi*, *Toxoplasma gondii* and *Neospora caninum* antibodies. A commercial *E. cuniculi* antigen (designed for rabbits, Diagnostik Megacor, Hörbranz, Austria) was used to perform an indirect fluorescent antibody test (IFAT) with few modifications. Briefly, antigen was incubated with sera diluted at 1:25 to 1:200 in phosphate-buffered saline (PBS) at 37 °C for 30 min. Slides were then washed twice with PBS for 5 min. Anti-dog IgG fluorescein isothiocyanate conjugate (Sigma, Saint Louis, USA) diluted 1:100 in PBS was added and the slides were incubated at 37 °C for 30 min, and rinsed twice with PBS. Slides were examined with a fluorescent microscope. The interpretation of the serologic results was based on published reference values for dogs with encephalitozoonosis in other countries (Lindsay et al., 2009; Greene, 2012). Titers of 1:200 or higher were considered positive. PBS was included as negative control to test no specific reactions with anti-dog IgG conjugate. Domestic positive or negative control sera to *E. cuniculi* were not available, since canine encephalitozoonosis had not been recorded in Argentina previously. For detection of *Toxoplasma gondii* and *Neospora caninum* antibodies, slides with tachyzoites of RH (Silva et al., 2002) and NC-1 (Cavalcante et al., 2012) strains of these parasites were used as antigen, respectively. Sera were diluted in PBS from 1:50 to 1: 800 at 37 °C for 30 min. Slides were washed three times with PBS (*Toxoplasma gondii*) or carbonate buffer (*Neospora caninum*). Anti-dog IgG fluorescein isothiocyanate conjugate (FITC-Sigma, Saint Louis, USA) diluted 1:100 in PBS was added and the slides were incubated at 37 °C for 30 min, and rinsed as previously

described. Slides were examined using a fluorescent microscope. Titers of 1:50 were considered positive for either, *T. gondii* and *N. caninum*. Positive and negative control sera were included.

3. Results

3.1 Gross findings

Grossly, the carcass was icteric with orange liver, and moderate splenomegaly. No other gross lesions were observed.

3.2 Microscopic findings

Sections of brain showed severe, diffuse, lymphocytic encephalitis, affecting both gray and white matter (Figure 1). These lesions were present in all sections of the brain examined. Multifocal infiltrates of lymphocytes, plasma cells and fewer macrophages were accompanied by diffuse gliosis. Occasional perivascular cuffings of plasma cells and lymphocytes were seen. The endothelial cells were hypertrophied and had large cytoplasmic vacuoles containing several small (approximately 1 μm in diameter), rod-shape, gram-positive spores, morphologically compatible with *E. cuniculi* (Figures 2 and 3).

The kidney presented moderate interstitial nephritis, characterized by small foci of lymphocytes and plasma cells, mainly in the cortical interstitium. Numerous vacuoles with clusters of organisms were widely seen in the cytoplasm of renal tubular epithelial cells (Figure 4), and endothelium. The cells containing organisms were usually not associated with inflammatory infiltrate.

Microscopic examination of the liver revealed mild lymphoplasmocytic hepatitis. Occasional small collections of densely-packed spores were observed in the cytoplasm of hepatocytes, scattered randomly throughout the parenchyma, and not associated with inflammation.

Other microscopic lesions included extensive extra-medullary hematopoiesis and congestion of the spleen.

3.3 PCR Technique

An amplicon of 549 bp was visualized by gel electrophoresis after the second round of the nested PCR reaction. This was the expected size for the amplification product of *E. cuniculi*.

3.4 Serology

Antibody titers to *E. cuniculi* in serum from the three surviving puppies and the dam were \geq 1:200. Antibodies for *T. gondii* or *N. caninum* were not detected in either of the puppies. A titer of 1:400 for *T. gondii* was found in the dam. Serology for *N. caninum* was negative in the dam.

4. Discussion

Microscopic findings and molecular and serologic results confirmed a definitive diagnosis of encephalitozoonosis and allowed differentiation of microsporidial disease from other neurologic diseases of dogs, such as canine distemper, rabies, toxoplasmosis and neosporosis (Wasson and Peper, 2000).

The microscopic lesions found in this report were similar to those previously reported in dogs with acute and active infection by *E. cuniculi* (Shadduck et al., 1978; Mc Innes and Stewart, 1991). In chronic cases of encephalitozoonosis, severe granulomatous infiltration by lymphocytes, macrophages and epithelioid cells, accompanied by plasma cells in kidneys and brain, are characteristic. Vasculitis and fibrinoid necrosis of arteries in kidney, brain, heart, lymph node, mesentery and lungs have been noted in these cases. In general, *E. cuniculi* organisms were absent in late lesions (Shadduck et al., 1978).

Several fatal infectious diseases were ruled out based on histologic examination. Meningitis was not seen. Neurologic lesions of *Neospora caninum* and *Toxoplasma gondii* include necrotizing encephalomyelitis, with intralésional tachyzoites and cysts (Dubey et al., 2006; Cantile and Youssef, 2015). These organisms were also ruled out by serology. Canine distemper has distinguishing characteristics such as demyelination in white matter tracts, which is result of direct infection of oligodendroglia. Intranuclear and, less frequently, intracytoplasmic inclusions may be found in neurons, glial cells, and epithelial tissues (Lempp et al., 2014; Cantile and Youssef, 2015). Canid Herpesvirus type I is usually found in systemic infections in neonates. Focal necrosis in parenchymatous organs and intranuclear inclusion bodies may be present in these foci (Decaro et al., 2008; Cantile and Youssef, 2015). In Pseudorabies, eosinophilic intranuclear inclusion bodies are present in neurons and astroglia (Cantile and Youssef, 2015; Zhang et al., 2015). Rabies may develop without gross brain changes, but acidophilic cytoplasmic inclusion bodies in neurons, most commonly of hippocampus (Negri bodies), are always found (Lackay et al., 2008; Cantile and Youssef, 2015).

There was a humoral response to infection as determined by IFAT. Serologic results in this case suggest that intrauterine transmission could have occurred, or indicates that a simultaneous infection of puppies and dam from the same unknown source, could have happened. Transplacental infection of *E. cuniculi* has been reported in domestic rabbits (Owen and Gannon, 1980), mice (Perrin, 1943), squirrel monkey (*Saimiri sciureus*) (Zeman and Baskin, 1985), and arctic foxes (Mohn et al., 1974; Mohn and Nordstoga, 1982), and has been suggested in dogs (Mc Innes and Stewart, 1991). The pathogenesis of encephalitozoonosis in carnivores has not been established, and there are many gaps in our knowledge regarding the epidemiology and transmission of this disease in dogs. Once infection occurs, it appears that the organism is shed in the urine (Shadduck et al., 1978; Mc Innes and Stewart, 1991; Didier et al., 2004), and infective environmentally resistant microsporidial spores are acquired through ingestion by a susceptible host (Wasson and Peper, 2000; Greene, 2012; Cantile and Youssef,

2015). Some authors suggest that encephalitozoonosis may be a zoonotic risk for humans (Mathis et al., 1997; Deplazes et al., 2000; Didier et al., 2004; Didier, 2005), but the epidemiologic role of dogs as reservoirs of *E. cuniculi* has not been yet demonstrated. Isolates of *E. cuniculi* genotype III has been documented in people, dogs and non-human primates (Didier et al., 1995; Didier et al., 1996; Snowden et al., 1999; Tosoni et al., 2002; Snowden et al., 2009). However, direct evidence confirming dog to human transmission or viceversa has not been provided. There has been a single case of a girl who seroconverted after close contact with infected puppies (Mc Innes and Stewart, 1991).

To our knowledge, this is the first case report of canine encephalitozoonosis in Latin America, so there is scant information about the importance of this infection in dogs in this region. It is possible that this disease may frequently occur unrecognized since it is uncommon in dogs, causes of mortality in puppies are not always investigated, and central nervous system dysfunction in young dogs is frequently attributed to canine distemper, and more recently to neosporosis, among other pathogens (Snowden et al., 2009).

5. Conclusion

A limited number of reports describe spontaneous infection by *E. cuniculi* in dogs, and the significance of this organism as a pathogen of dogs in Argentina is not known. This report contributes to increasing our understanding of neurologic disease in puppies and raises awareness of encephalitozoonosis as a differential diagnosis in cases of fatal encephalitis.

Acknowledgments

We thank Dr. Francisco Uzal, M.V. Lorena De Felice, Dr. Gastón Moré and M.V. Diego Eiras for their academic and technical contribution.

This research did not receive any specific grant from funding agencies in the public, commercial, or not-for-profit sectors.

Conflict of interest statement

All authors disclose any actual or potential conflict of interest including any financial, personal or other relationships with other people or organizations that could inappropriately influence, or be perceived to influence, this work.

References

1. Basson, P.A., McCully, R.M., Warnes, W.E.J., 1966. Nosematosis: report of a canine case in the Republic of South Africa. *J. S. Afr. Vet. Med. Assoc.* 37, 3-9.
2. Bjerkas, I., Nesland J.M., 1987. Brain and spinal cord lesions in encephalitozoonosis in the blue fox. *Acta Vet. Scand.* 28, 15-22.
3. Cantile, C., Youssef, S., 2015. Chapter 4: Nervous system. In "Jubb, Kennedy, and Palmer's Pathology of domestic animals". 6th ed. M. Grant Maxie.
4. Cavalcante, G.T., Soares, R.M., Nishi, S.M., Hagen, S.C., Vannucchi, C.I., Maiorka, P.C., Paixao, A.S., Gennari, S.M., 2012. Experimental infection with *Neospora caninum* in pregnant bitches. *Rev. Bras. Parasitol. Vet.* 21, 232-236.
5. Cole, J.R., Sangster, L.T., Sulzer, C.R., Pursell, A.R., Ellinghausen, H.C., 1982. Infections with *Encephalitozoon cuniculi* and *Leptospira interrogans*, serovars grippotyphosa and ballum, in a kennel of foxhounds. *J. Am. Vet. Med. Assoc.* 180, 435-437.
6. Decaro, N., Martella, V., Buonavoglia, C. 2008. Canine adenoviruses and herpesvirus. *Vet. Clin. North Am. Small Anim. Pract.* 38, 799-814.
7. Deplazes, P., Mathis, A., Weber, R., 2000. Epidemiology and zoonotic aspects of microsporidia of mammals and birds. *Contrib. Microbiol.* 6, 236-260.

8. Didier, E.S., 2005. Microsporidiosis: An emerging and opportunistic infection in humans and animals. *Acta Trop.* 94, 61-76.
9. Didier, E.S., Vossbrink, C.R., Baker, M.D., Rogers, L.B., Bertucci, D.C., Shadduck, J.A., 1995. Identification and characterization of three *Encephalitozoon cuniculi* strains. *Parasitology* 111, 411-421.
10. Didier, E.S., Visvesvara, G.S., Baker, M.D., Rogers, L.B., Bertucci, D.C., De Groote, M.A., Vossbrinck, C.R., 1996. A microsporidian isolated from an AIDS patient corresponds to *Encephalitozoon cuniculi* III, originally isolated from domestic dogs. *J. Clin. Microbiol.* 34, 2835-2837.
11. Didier, E.S., Stovall, M.E., Green, L.C., Brindley, P.J., Sestak, K., Didier, P.J., 2004. Epidemiology of microsporidiosis: sources and modes of transmission. *Vet. Parasitol.* 126, 145-166.
12. Dubey, J.P., Chapman, J.L., Rosenthal, B.M., Mense, M., Schueler, R.L., 2006. Clinical *Sarcocystis neurona*, *Sarcocystis canis*, *Toxoplasma gondii*, and *Neospora caninum* infections in dogs. *Vet. Parasitol.* 137, 36-49.
13. Franzen, C., Schwartz, D.A., Visvesvara, G.S., Muller, A., Schwenk, A., Salzberger, B., Fatkenheuer, G., Hartmann, P., Mahrle, G., Diehl, V., Schrappe, M., 1995. Immunologically confirmed disseminated, asymptomatic *Encephalitozoon cuniculi* infection of the gastrointestinal tract in a patient with AIDS. *Clin. Infect. Dis.* 21, 1480-1484.
14. Greene, C.E., 2012. *Infectious diseases of the dog and cat*. 4th ed. St. Louis, WB Saunders.

15. Guscetti, F., Mathis, A., Hatt, J.M., Deplazes, P., 2003. Overt fatal and chronic subclinical *Encephalitozoon cuniculi* microsporidiosis in a colony of captive emperor tamarins (*Saguinus imperator*). J. Med. Primatol. 32, 111-119.
16. Lackay, S.N., Kuang, Y., Fu, Z.F., 2008. Rabies in small animals. Vet. Clin. North Am. Small Anim. Pract. 38, 851-861.
17. Lempp, C., Spitzbarth, I., Puff, C., Cana, A., Kegler, K., Techangamsuwan, S., Baumgärter, W., Seehusen, F., 2014. New aspects of the pathogenesis of canine distemper leukoencephalitis. Viruses. 6, 2571-2601.
18. Lindsay, D.S., Goodwin, D.G., Zajac, A.M., Cortés-Vecino, J.A., Gennari, S.M., Rosypal, A.C., Dubey, J.P., 2009. Serological survey for antibodies to *Encephalitozoon cuniculi* in ownerless dogs from urban areas of Brasil and Colombia. J. Parasitol. 95, 760-763.
19. Malherbe, H., Munday, V., 1958. *Encephalitozoon cuniculi* infection of laboratory rabbits and mice in South Africa. J. S. Afr. Vet. Med. Assoc. 29, 241-246.
20. Mathis, A., Michel, M., Kuster, H., Müller, C., Weber, R., Deplazes, P., 1997. Two *Encephalitozoon cuniculi* strains of human origin are infectious to rabbits. Parasitology 114, 29-35.
21. Mc Innes, E.F., Stewart C.G., 1991. The pathology of subclinical infection of *Encephalitozoon cuniculi* in canine dams producing pups with overt encephalitozoonosis. J. S. Afr. Vet. Assoc. 62, 51-54.
22. Mertens, R.B., Didier, E.S., Fishbein, M.C., Bertucci, D.C., Rogers, L.B., Orenstein, J.M., 1997. *Encephalitozoon cuniculi* microsporidiosis: infection of the brain, heart, kidneys, trachea, adrenal gland, and urinary bladder in a patient with AIDS. Mod. Pathol. 10, 68-77.

23. Moffatt, R.E., Schiefer B., 1973. Microsporidiosis (Encephalitozoonosis) in the guinea pig. *Lab. Anim. Sci.* 23, 282-284.
24. Mohn, S.F., Nordstoga, K., 1982. Experimental encephalitozoonosis in the blue fox. Neonatal exposure to the parasite. *Acta Vet. Scand.* 23, 344-360.
25. Mohn, S.F., Nordstoga, K., Krogsrud, J., Helgebostad, A., 1974. Transplacental transmission of *Nosema cuniculi* in the blue fox (*Alopex lagopus*). *Acta Pathol. Microbiol. Scand. [B]*. 82, 299-300.
26. Müller-Doblies, U.U., Herzog, K., Tanner, I., Mathis, A., Deplazes, P., 2002. First isolation and characterization of *Encephalitozoon cuniculi* from a free-ranging rat (*Rattus norvegicus*). *Vet. Parasitol.* 107, 279-285.
27. Owen, D.G., Gannon J., 1980. Investigation into the transplacental transmission of *Encephalitozoon cuniculi* in rabbits. *Lab. Anim.* 14, 35-38.
28. Patterson-Kane, J.C., Caplazi, P., Rurangirwa, F., Tramontin, R.R., Wolfsdorf, K., 2003. *Encephalitozoon cuniculi* placentitis and abortion in a quarterhorse mare. *J. Vet. Diag. Invest.* 15, 57-59.
29. Perrin, T.L., 1943. Spontaneous and experimental encephalitozoon infection in laboratory animals. *Arch. Pathol.* 36, 559-567.
30. Plowright, W., 1952. An encephalitis-nephritis syndrome in the dog probably due to congenital encephalitozoonosis infection. *J. Comp. Pathol.* 62, 83-92.
31. Seibold, H.R., Fusell E.N., 1973. Intestinal microsporidiosis in *Callicebus moloch*. *Lab. Anim. Sci.* 23, 115-118.
32. Shadduck, J.A., Bendele, R., Robinson, G.T., 1978. Isolation of the causative organism of canine encephalitozoonosis. *Vet. Pathol.* 15, 449-460.

33. Silva, D.A., Silva, N.M., Mineo, T.W., Pajuaba Neto, A.A., Ferro, E.A., Mineo, J.R., 2002. Heterologous antibodies to evaluate the kinetics of the humoral response in dogs experimentally infected with *Toxoplasma gondii* RH strain. Vet. Parasitol. 107, 181-195.
34. Snowden, K.F., Logan, K., Didier, E.S., 1999. *Encephalitozoon cuniculi* strain III is a cause of encephalitozoonosis in both humans and dogs. J. Infect. Dis. 180, 20186-2088.
35. Snowden, K.F., Lewis, B.C., Hoffman, J., Mansell, J., 2009. *Encephalitozoon cuniculi* infections in dogs: A case series. J. Am. Vet. Med. Assoc. 45, 225-231.
36. Tosoni, A., Nebuloni, M., Ferri, A., Bonetto, S., Antinori, S., Scaglia, M., Xiao, L., Moura, H., Visvesvara, G.S., Vago, L., Costanzi, G., 2002. Disseminated microsporidiosis caused by *Encephalitozoon cuniculi* III (dog type) in an Italian AIDS patient: a retrospective study. Mod. Pathol. 15, 577-583.
37. van Rensburg, I.B.J., du Plessis, J.L., 1971. Nosematosis in a cat: a case report. J. S. Afr. Vet. Med. Assoc. 42, 327-331.
38. Vavra, J., Blazek, K., Lavicka, N., K-czkova, I., Kalafa, S., Stehlik, M., 1971. Nosematosis in carnivores. J. Parasitol. 57, 923-924.
39. Visvesvara, G.S., Leitch, G.J., da Silva, A.J., Croppo, J.P., Moura, H., Wallace, S., Slemenda, S.B., Schwartz, D.A., Moss, D., Bryan, R.T., Pieniazek, N.J., 1994. Polyclonal and monoclonal antibody and PCR-amplified small-subunit rRNA identification of a microsporidian, *Encephalitozoon hellem*, isolated from an AIDS patient with disseminated infection. J. Clin. Microbiol. 32, 2760-2768.
40. Wasson, K., Peper R.L., 2000. Mammalian microsporidiosis. Vet. Pathol. 37, 113-128.

41. Weiss, L.M., Vossbrinck, C.R., 1998. Microsporidiosis: molecular and diagnostic aspects. *Adv. Parasitol.* 40, 351-395.
42. Zeman, D.H., Baskin G.B., 1985. Encephalitozoonosis in squirrel monkeys (*Saimiri sciureus*). *Vet. Pathol.* 22, 24-31.
43. Zhang, L., Zhong, C., Wang, J., Lu, Z., Liu, L., Yang, W., Lyu, Y., 2015. Pathogenesis of natural and experimental Pseudorabies virus infections in dogs. *Virology* 537, 44-52.

Figure captions

Fig. 1. Cerebral cortex showing gray and white matter. Note diffuse infiltrates of lymphoid and glial cells. HE. (100 x)

Fig. 2. Cerebral vascular endothelium. Note cytoplasmic vacuoles with several *E. cuniculi* spores in endothelial cells, which protrude into the lumen of vessels. HE. (400 X)

Figure 3. Cerebral vascular endothelium. A higher magnification demonstrating the characteristic posterior vacuole. Gram's stain. (1000 X)

Figure 4. Kidney, corticomedullary junction. Slight nonsuppurative nephritis and numerous microsporidia spores within renal tubular epithelium. HE. (400 X)

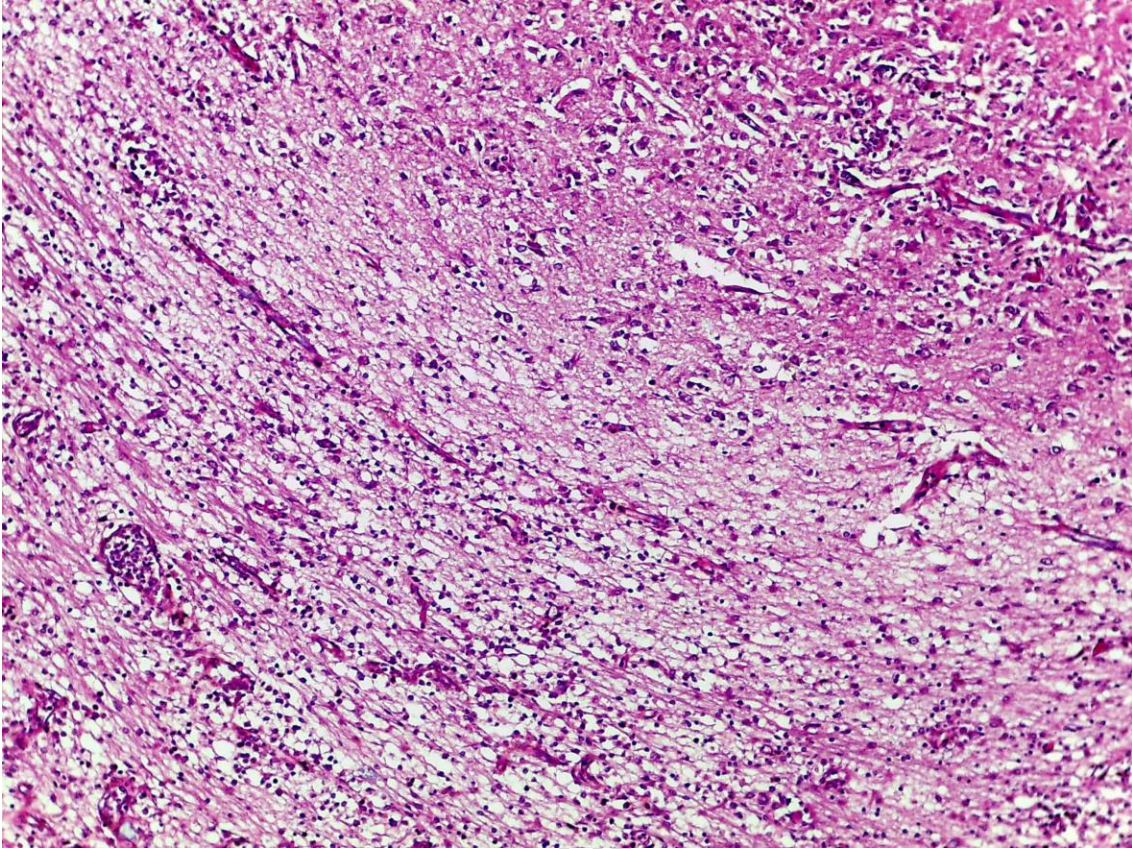


Figure 1

ACCEPTED MANUSCRIPT

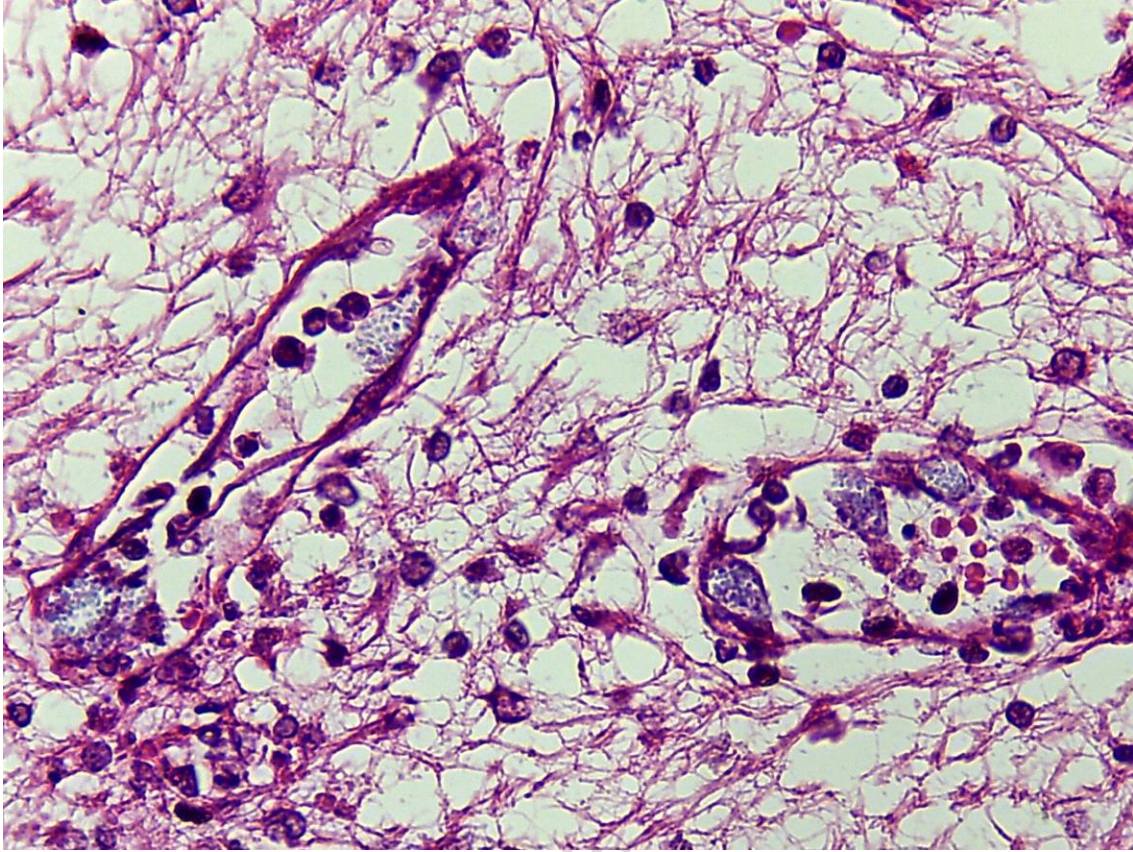


Figure 2

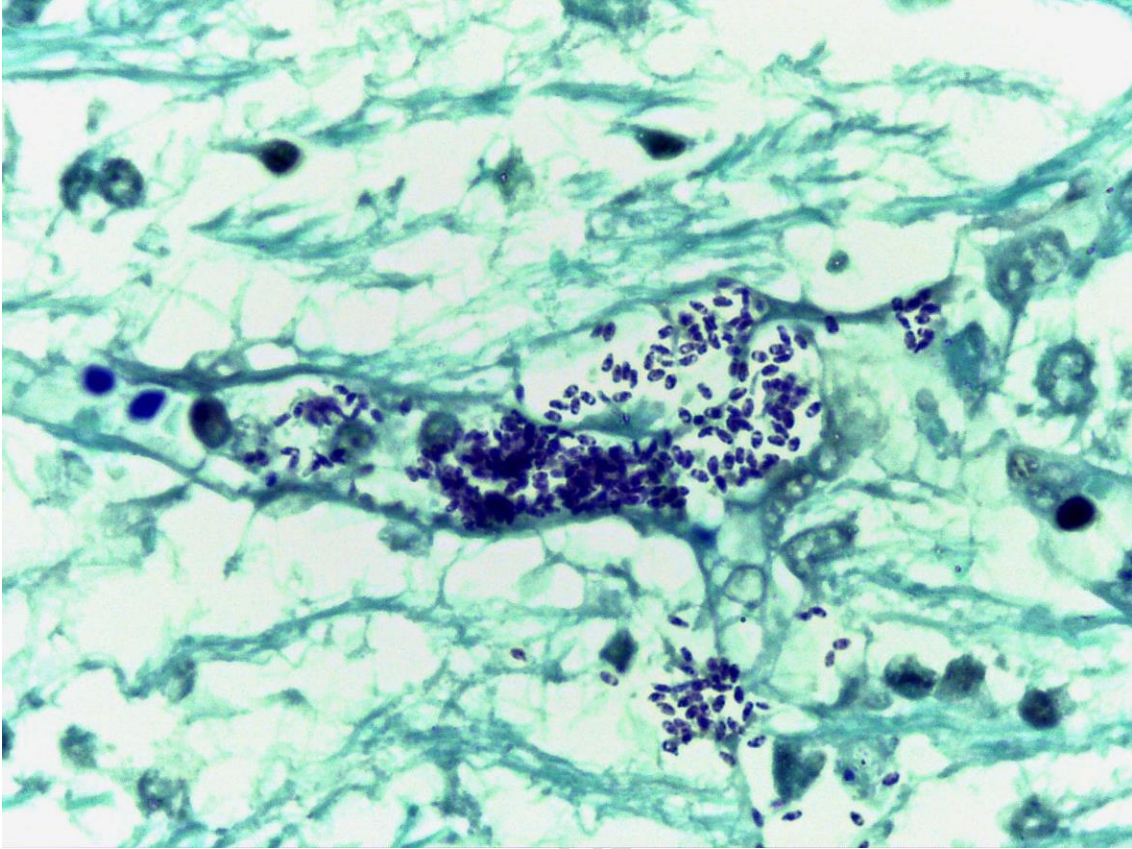


Figure 3

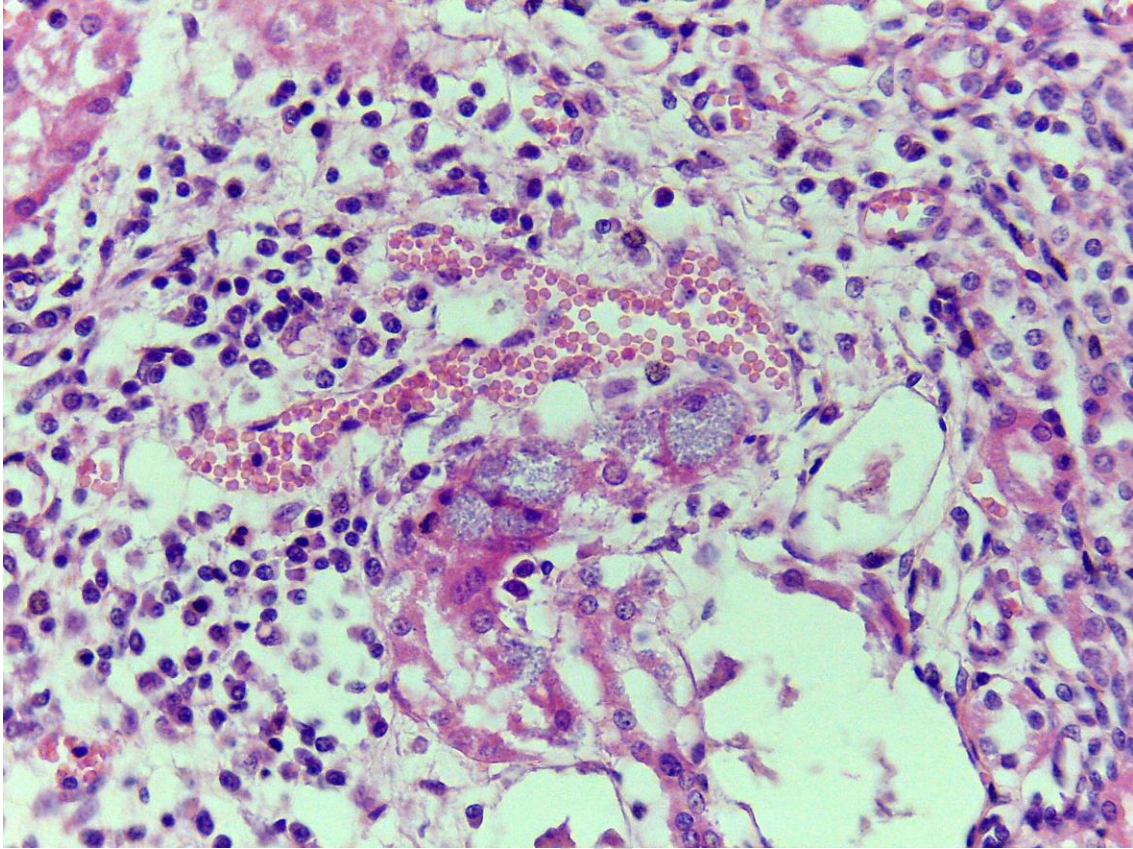


Figure 4

ACCEPTED MANUSCRIPT

Highlights

- Report of the first natural case in Latin America of encephalitozoonosis in a dog
- Microscopic lesions are typical of an acute infection, mainly in brain and kidney
- Encephalitozoonosis should be a differential diagnosis of encephalitis in puppies

ACCEPTED MANUSCRIPT