

kMucormycosis due to *Saksenaea vasiformis* in a dog



Francisco J. Reynaldi^{a,b,*}, Gabriela Giacoboni^c, Susana B. Córdoba^{b,d}, Julián Romero^e, Enso H. Reinoso^b, Ruben Abrantes^d

^a CCT-CONICET La Plata, Buenos Aires, La Plata 1900, Argentina

^b Universidad Nacional de La Plata, Facultad de Ciencias Veterinarias, Cátedra de Micología Médica e Industrial, La Plata 1900, Argentina

^c Universidad Nacional de La Plata, Facultad de Ciencias Veterinarias, Departamento de Microbiología, La Plata 1900, Argentina

^d Instituto Nacional de Enfermedades Infecciosas-ANLIS, “Dr. C. G. Malbrán”, Departamento Micología, Caba 1281, Argentina

^e Universidad Nacional de La Plata, Facultad de Ciencias Veterinarias, La Plata 1900, Argentina

ARTICLE INFO

Keywords:

Dermatitis

Dog

Immunocompetent

Mucormycosis

Saksenaea vasiformis

ABSTRACT

A 2-year-old female Border collie was examined for dermatitis with a partial alopecic zone around her left front member. Six months later the lesion became swollen, alopecic with ulcerated areas. Microscopy analysis of samples showed numerous non-septate, branching, thin-walled and irregular shaped hyphal elements. Fungal cultures and molecular studies identified *Saksenaea vasiformis*. Treatments with griseofulvin, itraconazole and surgical debridement were used, however, fourteen months later the dog was euthanatized because of the unfavorable clinical outcome.

1. Introduction

Mucormycosis is an uncommon fungal infection caused by fungi of the subphylum *Mucormicota*, order *Mucorales* [1]. The most common mucoralean fungi include the Genera *Mucor*, *Lichtheimia* (formerly *Absidia*), *Rhizopus*, *Rhizomucor*, *Mortierella*, *Apophysomyces* and *Saksenaea* [2–4]. This mycosis is most commonly associated with immunocompromised and diabetic patients or as a secondary infection in people who are undergoing prolonged antibiotic therapy [5]. In general, these infections are characterized by a rapid growing of the fungi with affinity to invade blood vessels, causing occlusion, infarction and also associated with vasculitis [2,6]. However, in occasional cases, *Saksenaea vasiformis*, *Apophysomyces elegans* and *Lichtheimia ramosa*, can infect immunocompetent individuals, usually after traumatic implantation of the fungus (7), or even through inhalation of spores [7], spider bites, insect's stings, and the use of indwelling catheters [8–11].

There are only three previous reports of veterinary cases caused by *S. vasiformis*. The first one was in 1992 in Australia, a cow was infected and developed weight loss, ptosis of the left eyelid, drooping of the left ear, and difficulty to swallow. The clinical history suggested that the infection had been present for at least two months [12]. Diazepam was administered to the cow to allow it to nurse the calf but, a week later, some ulcerated lesion and vesicles appeared on the dorsal and right lateral side of the calf. Despite supplemental feeding, the calf died 7 days after the first lesions were observed [13]. The second reported was in 2002, were 2 cases of infection of marine mammals were documen-

ted in USA. One of them was a pregnant 14-year-old killer whale that presented elevated total white blood cells and neutrophilia. Eleven days after those signs, the whale began to exhibit lethargy and slight inappetence, 13 days after onset of the initial clinical signs the animal died during labor [13]. The other one corresponded to a bottlenose dolphin. Her mother rejected to nurse her two days after giving birth. The third report corresponds to a 1-day-old mixed-breed bull calf from Texas, USA. The animal was 1 month premature and presented weakness, inability to ambulate, and the presence of multiple, circular, plaque-like skin lesions on the neck and front legs. Even though medical care was carried out, the calf died during the second day of hospitalization [14]. The purpose of the present case report is to provide the first clinical and mycological description of a mucormycosis due to *S. vasiformis* in a dog living in Argentina.

2. Case

A 2-year-old female Border collie was examined (day 0) for a slight dermatitis with a partial alopecic zone around her left front member. While culture results from scrapped of samples of the affected area were pending, the dog was given griseofulvin (50 mg/kg PO every 12 h). As the mycological culture were negative (day 15), the lesion did not worsen, and the dog had no history of dermatologic disease, the treatment with the antimicrobial drug was stopped. On day 16, the dog was served and became pregnant and 60 days later (day 72) twelve puppies were born. Supportive alimentation was administered in order

* Corresponding author at: CCT-CONICET La Plata, Buenos Aires, La Plata 1900, Argentina.
E-mail address: freynaldi@yahoo.com (F.J. Reynaldi).

<http://dx.doi.org/10.1016/j.mmcrr.2017.03.001>

Received 8 February 2017; Received in revised form 6 March 2017; Accepted 21 March 2017

Available online 22 March 2017

2211-7539/ © 2017 Published by Elsevier B.V. on behalf of International Society for Human and Animal Mycology. This is an open access article under the CC BY-NC-ND license (<http://creativecommons.org/licenses/by-nc-nd/4.0/>).

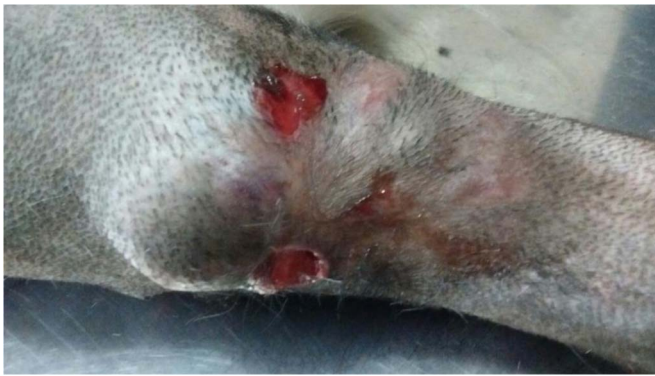

Fig. 1. Skin lesions in affected leg: alopecia, swollen and ulcerated vesicles.

to sustain the nursing of the puppies. Three months from the multiple birth (day 166) the patient presented the affected area (the same area of day 0) partially alopecic and slightly swollen, no samples were taken. A month later (day 196), the owner took the dog to the Micology Laboratory Service of the Faculty of Veterinary, National University of La Plata for consultation and sampling. At this moment, the dog presented the affected area clearly alopecic, swollen, with ulcerated vesicles, covered with a dry crust, under it, a serosanguineous exudate was observed (Fig. 1).

Aspirate from the vesicles and a biopsy were taken and the samples were sent to the Micology and Bacteriology Laboratory Service. Waiting for the results of the cultures, a treatment with cefalexin (30 mg/kg PO every 12 h) was started. Microscopic analysis of the exudates revealed the presence of numerous non-septate, dichotomous to irregular branching, thin-walled and irregular shaped hyphal elements of 5–9 μm in diameter (Fig. 2). Two days later, the results from the biopsy showed fungal hyphae, similar to those observed in the exudates from the affected skin, mucosa and submucosa.

Culture of the exudates, and tissues from the biopsy, on Sabouraud dextrose agar (SDA), potato dextrose agar (PDA), blood agar and chocolate blood agar yielded, in all cases, an uniform population of a rapidly growing, white to light grey aerial fungal colonies, scarce sporangiospores on substrate and reverse colorless at both 37 °C and 25 °C in room air. These characteristics allowed us to suspect a mucormycosis, particularly the mucoralean genera that are reluctant to fruit on SDA or PDA, namely *Apophysomyces* and *Saksenaea*. In order

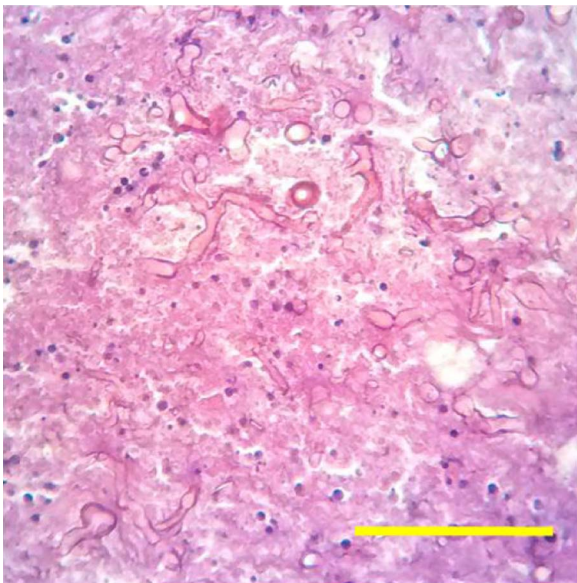

Fig. 2. Fungal hyphae with parallel walls and dichotomous to irregular branching are within the dermis. Hematoxylin and eosin stain, X400. Bar: 50 μm .

to induce sporulation, the isolates were subcultured in Czapek agar (CZA) and, the typical characteristics of one of the expected mucoralean, *Saksenaea* spp. were observed after 7 days of culture at 35 °C. Sporangiospore single, light brown, unbranched, with dichotomously branched, darkly pigmented rhizoids, sporangia single, terminal, flask-shaped, multi-spored and columella hemispherical and sporangiospores smooth-walled, cylindrical with rounded ends, hyaline, were observed (Fig. 3).

As soon as the isolate was identified (day 206), itraconazole (5 mg/kg PO every 12h) was administered. Also, the isolate was sent to the Department of Micology, National Institute of Infectious Disease, "Dr. Carlos Malbrán", Buenos Aires, Argentina, to determine the *in vitro* susceptibility testing, molecular identification and phylogenetic studies.

2.1. Antifungal susceptibility testing

The minimal inhibitory concentration (MIC) values were determined according to the Clinical and Laboratory Standards Institute (CLSI) M38-A2 broth microdilution reference document.

Amphotericin B, itraconazole (Sigma-Aldrich, Argentina), fluconazole, voriconazole (Pfizer, S.A, Argentina), terbinafine (Ladiland, Argentina) and posaconazole (Merck, Co., Argentina) were the antifungal drugs evaluated and were provided as standard powders of known potency. All the antifungal drug tested showed low MIC values, ranging from 0.03 to 0.5 mg/L.

2.2. Molecular identification

A conidial suspension (10^6 – 10^8 conidia/mL) was seeded in Petri dishes containing MEYA broth (1% malt extract, 0.4% yeast extract, 0.4% dextrose; 4 mL/plate) and incubated at 28 °C until abundant development. Mycelium was collected with a pipette tip and dried completely on sterile Whatmann filter paper No. 2. Dried mycelium was transferred to a 50 mL tube, where 4 mm glass beads were added. Mycelium was grounded by placing it in liquid nitrogen for 1 min and vortexing at maximum speed for 30 s. The mycelium powder was resuspended in 800 μL of lysis buffer (200 mM Tris–HCl, 500 mM NaCl, 10 mM EDTA, 1% SDS) and DNA was extracted with phenol–chloroform–isoamyl alcohol (25:24:1), precipitated with isopropanol and washed with 70% ethanol. Dried DNA pellet was resuspended in sterile distilled water. The ITS region was amplified in a 50 μL polymerase chain reaction assay. Briefly, amplification was carried out using 1.5 mM MgCl₂, 250 μM dNTPs, Tris–HCl 20 mM (pH 8.4), KCl 50 mM, 2.5 U Taq DNA polymerase (Invitrogen, Life Technologies, CA), 0.2 μM of each primer, ITS5 (5'-GGAAGTAAAAGTCGTAACAAGG-3') and ITS4 (5'-TCTCCGCTTATTGATATGC-3') [15] and 10 ng DNA template. Thermal cycling was performed using the Master Cycler EppGradient (Eppendorf, Hamburg, Germany) under the following conditions: an initial denaturing step at 94 °C for 10 min, followed by 35 cycles of denaturation at 94 °C for 1 min, annealing at 55 °C for 1 min and extension at 72 °C for 1 min, and a final extension step at 72 °C for 10 min. Polymerase chain reaction products were sequenced on both strands using a Big Dye Terminator kit and the 3500 ABI genetic analyzer (Applied Biosystems). The sequences obtained were edited using BioEdit Sequence Alignment Editor v 7.0.4.1 and sequence similarities were searched and retrieved from the NCBI GenBank database using the BLAST algorithm with automatically adjusted parameters. The nucleotide sequences obtained were compared with those available in the GenBank database using BLASTN [National Center for Biotechnology Information (NCBI)].

2.3. Phylogenetic analysis

Sequences of the ITS of the DMic 165171 isolate were aligned with sequences belonging to *Saksenaea* species deposited in GenBank, they were used to construct the phylogenetic tree. (Fig. 4).

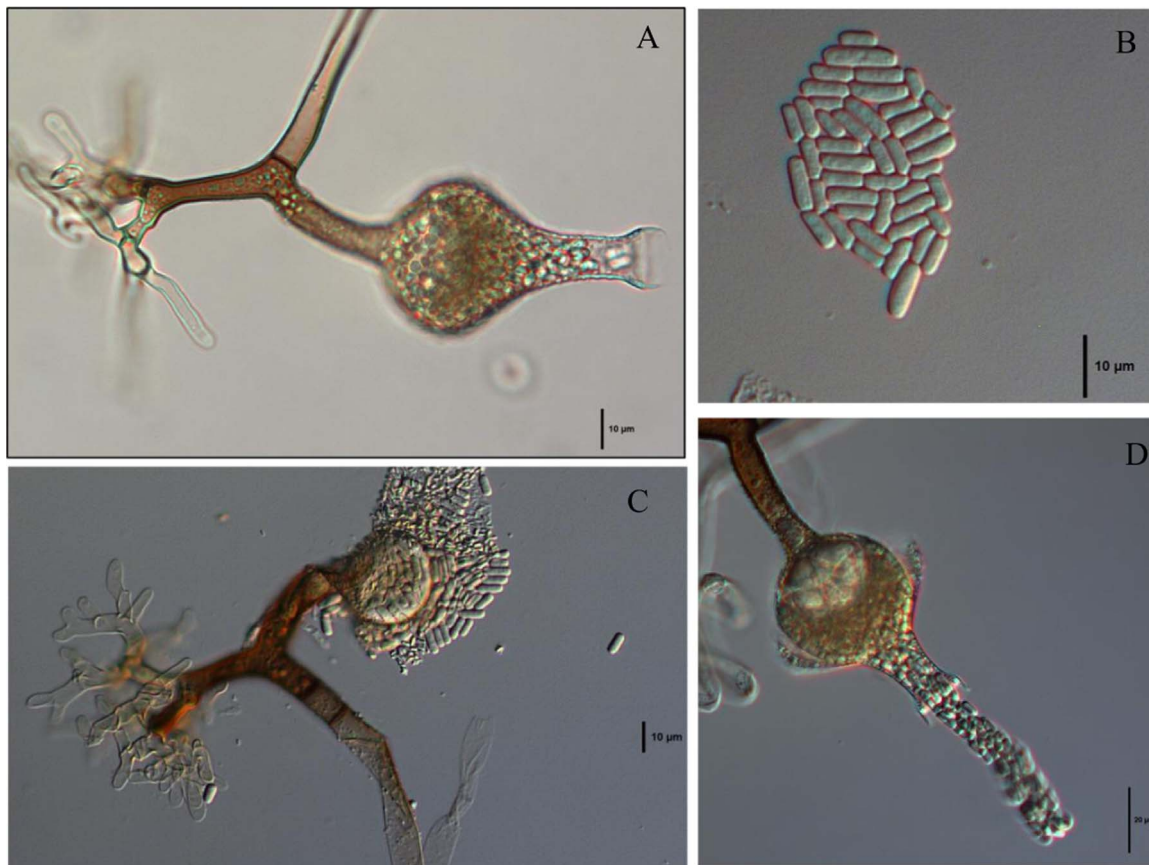


Fig. 3. Morphology of the sporangiosphere and sporangiospores of *S. vasiformis* complex DMic 165171 (A, B, C and D). (A) Sporangiosphere; (B) sporangiospores; (C) detail of the rhizoids, sporangia membrane ornamented and sporangiospores. (D) sporangiospores released from the neck.

The sequences were aligned using the Clustal X, Neighbor-Joining (NJ) and phylogenetic trees were constructed using the MEGA 6 package [16]. Bootstrap test (500 replicates), the best-fit model of nucleotide substitution was Tamura 3-parameter method, *A. elegans* (CBS 476.78) was chosen as out group. Alignment of over 525 bp corresponding to ITS1 (partial sequence), the 5.8 S ribosomal gene (complete sequence) and ITS2 (partial sequence) with *S. vasiformis* ATCC 28740, Sequence ID: FR687322.1, showed 97% similarity, query coverage 96% and an E-value of 0.0.

Two month later (day 267) we observed remission of the disease

with itraconazole treatment, thus, it was decided to stop the treatment. However, on day 297, slightly alopecic, swollen areas with ulcerated vesicles re-appeared on her front legs and therefore treatment with itraconazole (5 mg/kg PO every 12 h) was resumed. On day 315, new lesions became visible at the lymph nodes in the neck that appeared swollen, and two days later became ulcerated. In that moment, topical washing with chlorhexidine 5% was added to the treatment. From then on, the characteristics of the lesion never disappeared. On day 387, as the lesions worsened, treatment with surgical debridement was implemented. Finally, because of the extent and progression of the

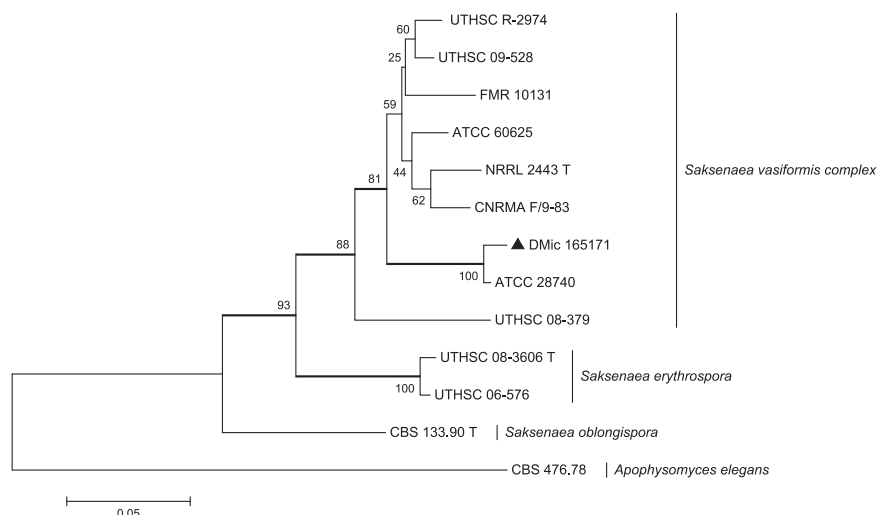


Fig. 4. Phylogenetic tree inferred from Neighbor-Joining analysis of partial ITS sequences (558 bp). DMic 165171 strain is located in the clade *Saksenaea vasiformis* complex. The tree generated from 500 replicates and the bar length represents 0.05 substitution per site. Bootstrap percentages are shown at the respective node. T: type strain.

disease, and the animal's deteriorating condition, the dog was euthanized 402 days after the initial lesions were observed.

3. Discussion

To our knowledge, this case is the fourth reported in the veterinary literature of *S. vasiformis* infection, and the first one in a dog living in Argentina. *S. vasiformis* complex represent filamentous fungi reported in soil, driftwood, and grains [17], characterized by flask-shaped sporangia, short sporangiophores, oval sporangiospores, and dark rhizoids. It is a thermotolerant fungus that grows between 25 °C and 44 °C.

This kind of infections caused by fungi of the order *Mucorales* are uncommon, but they are significant because of their aggressive nature, challenges in diagnosis and high mortality (40–100%) despite antifungal and surgical therapy [18]. To remark, in the present case all the antifungal drugs evaluated showed high *in vitro* activity against the strain tested, however, the clinical outcome was unfavorable.

Apophysomyces and *Saksenaea* are the mucoralean fungi that most frequently develop infection without a co-morbidity factor, and most cases are related to trauma or a major surgery [18]. This characteristic allows *S. vasiformis* to cause severe human and animal infections in both immunocompromised and immunocompetent hosts. Furthermore, most of the cases due to *S. vasiformis* complex occurred as cutaneous mycosis in immunocompetent patients after traumatic implantation [6].

Human cases of mucormycosis showed that the common sites of infection are the lungs (44.6%), followed by the sinuses (29.7%), and in third position the skin and soft tissue (20.3%) [18]. However, all the reported cases in the veterinary literature (including the present one) had their lesions in the skin and soft tissue, and developed a disseminated infection [12–14,18].

A recent multicenter retrospective study of proven and probable cases of 74 human mucormycosis in Australia, revealed that 77% of these mycoses were diagnosed by culture, but only 43% of the cases were diagnosed by both culture and histopathology. In contrast, almost 14% of the cases could not be identified and belonged to the "mucoralean probable cases". In addition, *S. vasiformis* complex contributed only in 5% of the cases [18]. Considering these figures and the cases of mucormycosis reported in the veterinary literature, reports of infections in animals due to *S. vasiformis* species complex are scarce [6,12–14]. The question is if infections due to *S. vasiformis* are certainly uncommon, or if the lack of sporulation on a variety of common media such as SDA, PDA, water agar [19] or Lactrimel, may negatively contribute in the correct identification of this fungus. The recommendation is that molecular identification should be carried out.

In conclusion, we report the first case of mucormycosis due to *S. vasiformis* complex in a dog, and the fourth in the veterinary literature. These figures let us suppose that there exists an important under-diagnosis of this unusual mucormycosis probably caused by the lack of sporulation in common culture medium. In contrast to all the reported veterinary cases, this case presented the longest survival period from the moment the pathogen was identified. Possibly, the implantation of the fungus was in the left front member around day 0, but the appropriate immunological status let the patient survive for more than a year, even given birth 12 puppies and nursing them in the meantime. The dog responded well to the initial therapy with griseofulvin, but later itraconazole treatment, even in combination with surgical debridement, failed.

We recognize our limitations, as we were unable to determine whether the fungal infection spread locally or via systemic dissemination. Also, an antifungal treatment with amphotericin B or posaconazole would probably have been more effective [20], however, these drugs are too expensive, and in Argentina they are mainly used in human medicine. We could speculate that the itraconazole treatment failed due to the drug having difficulties reaching the infection site, and perhaps the removal of the affected limb at the beginning of the

infection may have prevented the spread of the fungus and the death of the animal.

Conflict of interest

None.

Ethical Form

Please note that this journal requires full disclosure of all sources of funding and potential conflicts of interest. The journal also requires a declaration that the author(s) have obtained written and signed consent to publish the case report from the patient or legal guardian(s).

The statements on funding, conflict of interest and consent need to be submitted via our Ethical Form that can be downloaded from the submission site www.ees.elsevier.com/mmc. **Please note that your manuscript will not be considered for publication until the signed Ethical Form has been received.**

Acknowledgements

None.

References

- [1] R.M. Prabhu, R. Patel, Mucormycosis and entomophthoromycosis: a review of the clinical manifestations, diagnosis and treatment, *Clin. Microbiol Infect.* 10 (Suppl 1) (2004) 31–47.
- [2] W.U. Knudtson, C.A. Kirkbride, Fungi associated with bovine abortion in the northern plains states (USA), *J. Vet. Diagn. Invest* 4 (1992) 181–185.
- [3] F. Dromer, M.R. McGinnis, Zygomycosis, in: E.J. Anaissie, M.A. Pfaller, M. McGinnis (Eds.), *Clinical Mycology*, Churchill Livingstone, New York, 2003, pp. 297–308.
- [4] J.A. Ribes, C.L. Vanover-Sams, D.J. Baker, Zygomycetes in human disease, *Clin. Microbiol Rev.* 13 (2) (2000) 236–301.
- [5] M.A. Wieden, K.K. Steinbronn, A.A. Padhye, L. Ajello, F.W. Chandler, *J. Clin. Microbiol* 22 (1985) 522–526.
- [6] P.A. Wilson, Zygomycosis due to *Saksenaea vasiformis* caused by a magpie peck, *Med J. Aust.* 189 (9) (2008) 521–522.
- [7] E. Bibashi, G.S. de Hoog, T.E. Pavlidis, N. Symeonidis, A. Sakantamis, G. Walther, Wound infection caused by *Lichtheimia ramosa* due to a car accident, *Med. Mycol. Case Rep.* 2 (2013) 7–10, <http://dx.doi.org/10.1016/j.mmc.2012.12.001>.
- [8] J. García-Martínez, F. Lopez-Medrano, A. Alhambra, A. del Palacio, Rhinocerebral zygomycosis caused by *Saksenaea vasiformis* in a diabetic patient, *Mycoses* 51 (2008) 549–553.
- [9] A. Chakrabarti, P. Kumar P, A.A. Padhye, L. Chatha, S.K. Singh, A. Das, J.D. Wig, R.N. Kataria, Primary cutaneous zygomycosis due to *Saksenaea vasiformis* and *Apophysomyces elegans*, *Clin. Infect. Dis.* 24 (1997) 580–583.
- [10] J. Holland, Emerging zygomycosis of humans: *Saksenaea vasiformis* and *Apophysomyces elegans*, *Curr. Top. Med Mycol.* 8 (1997) 27–34.
- [11] P. Lechevalier, D. Garcia-Hermoso, A. Carol, S. Bonacorsi, L. Ferkdadjji, F. Fitoussi, O. Lortholary, A. Bourrillon, A. Faye, E. Dannaoui, F. Angoulvant, Molecular diagnosis of *Saksenaea vasiformis* cutaneous infection after scorpion sting in an immunocompetent adolescent, *J. Clin. Microbiol* 46 (2008) 3169–3172.
- [12] B.D. Hill, P.F. Black, M. Kelly, D. Muir, W.A.J. Mc Donald, Bovine cranial zygomycosis caused by *Saksenaea vasiformis*, *Aust. Vet. J.* 69 (1992) 173–174.
- [13] T.R. Robeck, L.M. Dalton, *Saksenaea vasiformis* and *Apophysomyces elegans* zygomycotic infections in bottlenose dolphins (*Tursiops truncatus*), a killer whale (*Orcinus orca*), and pacific white-sided dolphins (*Lagenorhynchus obliquidens*), *J. Zoo. Wildl. Med* 33 (2002) 356–366.
- [14] S.D. Lawhon, W.V. Corapi, A. Rodriguez Hoffmann, M.C. Libal, E. Alvarez, J. Guarro, B.L. Wickes, J. Fu, E.H. Thompson, D.A. Sutton, In utero infection of a calf by *Saksenaea erythrospora* resulting in neonatal abomasitis and dermatitis, *J. Vet. Diag Invest* 24 (5) (2012) 990–993.
- [15] E. Alvarez, D. Garcia-Hermoso, D.A. Sutton, J.F. Cano, A.M. Stchigel, D. Hoinard, A.W. Fothergill, M.G. Rinaldi, F. Dromer, J. Guarro, Molecular phylogeny and proposal of two new species of the emerging pathogenic fungus *Saksenaea*, *J. Clin. Microbiol* 48 (2010) 4410–4416.
- [16] K. Tamura, G. Stecher, D. Peterson, A. Filipksi, S. Kumar, MEGA6: Molecular Evolutionary Genetics Analysis version 6.0, *Mol. Biol. Evol.* 30 (2013) 2725–2729.
- [17] C.M. Pillai, R. Ahmed, *Saksenaea vasiformis*, an ecologically important fungus on rice from India, *Curr. Sci.* 65 (1993) 291.
- [18] K.J. Kennedy, K. Daveson, M.A. Slavín, S.J. van Hal, T.C. Sorrell, A. Lee, et al., Mucormycosis in Australia: contemporary epidemiology and outcomes, *Clin. Microbiol Inf.* (2016). <http://dx.doi.org/10.1016/j.cmi.2016.01.005>.
- [19] A.A. Padhye, L. Ajello, Simple method of inducing sporulation by *Apophysomyces elegans* and *Saksenaea vasiformis*, *J. Clin. Microbiol* 26 (1988) 1861–1863.
- [20] O.A. Cornely, S. Arikan-Akdagli, E. Dannaoui, A.H. Groll, K. Lagrou, A. Chakrabarti, et al., ESCMID and ECMM joint clinical guidelines for the diagnosis and management of mucormycosis 2013, *Clin. Microbiol Infect.* 20 (Suppl. 3) (2014) 5–26.