

## Copro-parasitological study of European starling nestlings (*Sturnus vulgaris*) in Argentina

Lucía Mariel IBÁÑEZ<sup>1\*</sup>, María Inés GAMBOA<sup>2</sup>, Vanina Dafne FIORINI<sup>3</sup>, Diego MONTALTI<sup>1</sup>

<sup>1</sup>Ornithology Section, Zoology Vertebrate Division, Faculty of Natural Sciences and Museum, National University of La Plata, La Plata, Argentina

<sup>2</sup>Department of Compared Parasitology, Faculty of Veterinary Sciences, National University of La Plata, La Plata, Argentina

<sup>3</sup>Department of Ecology, Genetics and Evolution IEGEBA-CONICET, Faculty of Exact and Natural Sciences, University of Buenos Aires, Buenos Aires, Argentina

Received: 24.11.2015

Accepted/Published Online: 29.02.2016

Final Version: 09.06.2016

**Abstract:** We examined 71 fecal samples of European starling nestlings from Buenos Aires Province, Argentina, in the reproductive seasons of 2012 and 2013 to detect the presence of intestinal parasites and determine their prevalence. Total parasite prevalence was 26.8%. We found one coccidial species (*Isoospora* sp.) with a prevalence of 25.35% and one cestode species with a prevalence of 1.4%. These values are lower than those reported for starlings from Europe and North America. Our results suggest that a reduction in the diversity of parasite species was likely to have occurred during the introduction process of this bird in Argentina, thus contributing to its invasive success.

**Key words:** Argentina, cestode, *Isoospora*, starling nestling

Coccidia and helminths are intestinal endoparasites widely spread among wild bird populations (Atkinson et al., 2008). Some of them are pathogenic and may cause death (Greiner, 2008; McLaughlin, 2008). Invasive species are particularly susceptible to certain natural enemies, such as the parasites they encounter in the introduced range. However, if invaders become resistant to these parasitic infections, they improve the likelihood of increasing their population (Blackburn et al., 2009). On the other hand, parasites may be lost during or soon after the introduction process (Torchin et al., 2003). This release from the effects of natural enemies may contribute to the rapid establishment and proliferation of nonindigenous species (Torchin and Mitchell, 2004).

The European starling *Sturnus vulgaris* (hereafter starling) is a bird native to Europe, Asia, and North Africa. It has been successfully established in New Zealand, Australia, South Africa, the United States, Mexico, Argentina, Uruguay, some Pacific islands, and the Caribbean (Feare, 1984; Peris et al., 2005; Álvarez-Romero et al., 2008; Mazzulla, 2013). The starling was first recorded in Argentina in 1987 (Pérez, 1988), probably introduced from North America (Navas, 2002). Starlings show a high prevalence of intestinal parasites in their native and introduced areas (Boyd, 1951; Hair and Forrester, 1970; Cooper and Crites, 1976; Bernard, 1987). In Argentina,

where the species was recently introduced, individuals are expected to have a lower parasite load than in their native areas and in North America, where it was introduced in 1890. In a recent study, Valente et al. (2014) reported 1 trematode, 1 acanthocephalan, and 4 nematodes in juvenile and adult starlings from Buenos Aires.

The objective of this work is to identify the intestinal parasites and determine their prevalence in fecal samples of European starling nestlings in Argentina.

The parasitological survey was conducted at the Wild Animal Breeding Station (Spanish abbreviation: ECAS; 34°50'N, 58°06'W), Berazategui, Buenos Aires, Argentina. We collected 48 and 23 fecal samples from nestlings hatched in nest boxes during the breeding seasons of 2012 and 2013 (October–December), respectively. Fifty-six samples (34 in 2012 and 22 in 2013) were obtained by placing individual glass containers near the nestlings' cloacae and 15 samples (14 in 2012 and one in 2013) were collected from the nests immediately after defecation. The study included nestlings of 17–18 days of age from different nests. Eleven samples from the 2012 breeding season were preserved in 2.5% dichromic potassium solution (K<sub>2</sub>Cr<sub>2</sub>O<sub>7</sub>) to allow sporulation of the oocysts. The remaining samples were preserved in 10% formalin. Two concentration methods were used for 26 samples (10 from 2012 and 16 from 2013): a concentrated sugar flotation technique and a

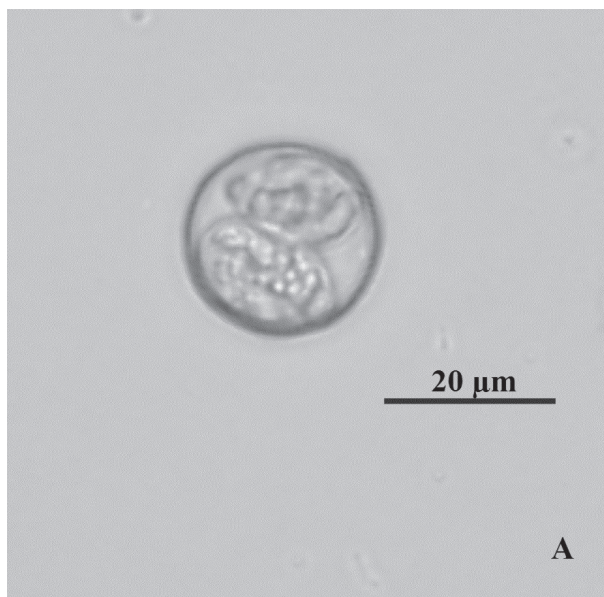
\* Correspondence: luciaibanez@fncym.unlp.edu.ar

modified Ritchie centrifugation procedure (Markell et al., 1999). Additionally, the samples were examined twice by direct observation. The low intensities of oocysts and eggs found in the samples prevented the use of a quantification technique. A Leica DM 2000 binocular microscope adapted with a digital photographic camera was used to detect and measure coccidial oocysts and helminth eggs. Prevalence (P) was defined and calculated according to Bush et al. (1997). Measurements are reported as mean  $\pm$  SE, and range is shown in parentheses.

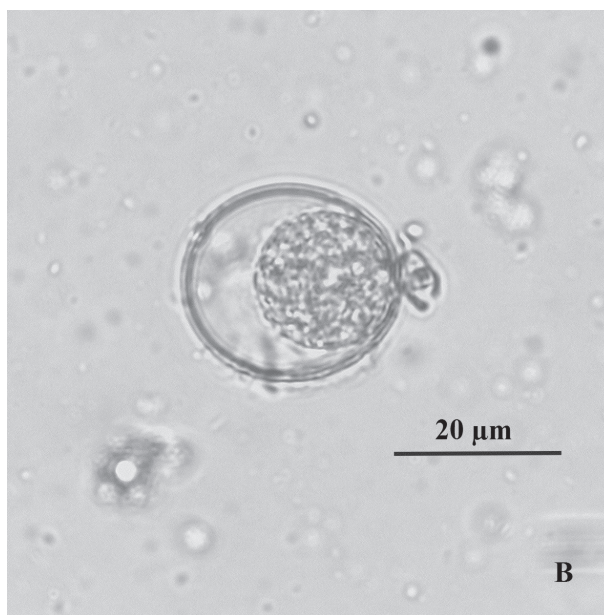
We found 2 species of parasites with an overall prevalence of 26.8%. These were represented by oocysts of coccidia and the eggs of an unidentified cestode, with a prevalence of 25.35% and 1.4%, respectively. Sporulated (Figure 1A) and unsporulated (Figure 1B) oocysts were observed. All oocysts were spherical to slightly oval in shape. Sporulated oocysts had 2 sporocysts, each of which contained four sporozoites (Figure 1A), thus indicating that they belonged to the genus *Isospora* (Schneider, 1881). The oocyst wall consisted of a 1- $\mu$ m outer layer and a thicker inner layer. Stieda and substieda bodies were present. The oocysts were  $23.4 \pm 1.7 \mu\text{m}$  (19.5–28.0  $\mu\text{m}$ ) in length and  $22.6 \pm 1.6 \mu\text{m}$  (19.5–25.5  $\mu\text{m}$ ) in width ( $n = 51$ ). The sporocysts were pear-shaped and measured  $16.9 \pm 1.8 \mu\text{m}$  (10.3–19.6  $\mu\text{m}$ ) in length and  $11.6 \pm 0.8 \mu\text{m}$  (10.3–13.4  $\mu\text{m}$ ) in width.

In 2012, overall parasite prevalence was 29.2% (14/48) and coccidial prevalence was 27.1% (13/48), with 53.8% of the infected samples containing 1–2 oocysts. The other samples also showed low infection intensity, with less than 10 oocysts per field of vision at 20 $\times$  magnification. Cestode eggs were found in a single sample ( $P = 2\%$ ). They measured  $56 \pm 3.2 \mu\text{m}$  (51–59  $\mu\text{m}$ ) in length and  $54 \pm 2.9 \mu\text{m}$  (50–57  $\mu\text{m}$ ) in width ( $n = 7$ ), and the hooks of the hexacanth embryo were  $13.81 \pm 0.51 \mu\text{m}$  (12.53–14.78  $\mu\text{m}$ ) in length (Figures 2A and 2B). In 2013, we only found oocysts of *Isospora* sp. with a prevalence of 21.7% (5/23). Four samples contained only one oocyst, and one sample contained less than 10 oocysts per field of vision at 20 $\times$  magnification.

The prevalence of intestinal parasites in starling nestlings from Argentina (26.8%) is the lowest reported so far, compared to other surveys from North America, northeastern Africa, Europe, and western Asia (Sommer, 1937; Boyd, 1951; Ballard and Ollsen, 1966; Hair and Forrester, 1970; Vincent, 1972; Bernard, 1987; Mazgajski and Kedra, 1998). Using coprological methods, *Isospora* sp. was detected in 67% of nests with starling nestlings in Poland (Mazgajski and Kedra 1998), and in 75% of adult starlings from different locations in the northeastern United States (Boyd, 1951). The intensity of parasite infection in starlings recorded in this study is the lowest reported in the literature. In fact, we did not use a quantification



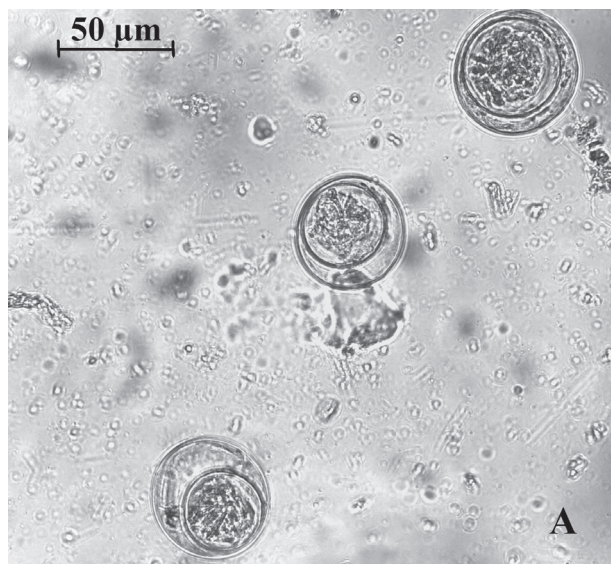**Figure 1A.** Sporulated oocyst of *Isospora* sp. with 2 pear-shaped sporocysts containing 4 sporozoites each.



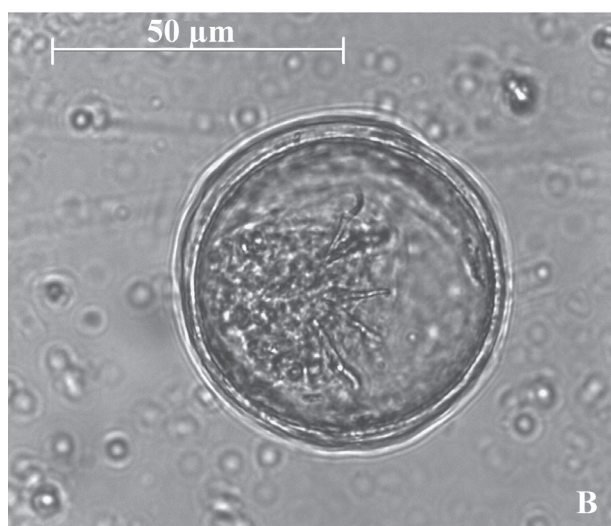
**Figure 1B.** Unsporulated oocyst.

technique because there was an average of less than 10 oocysts per field of vision at 20 $\times$  magnification. In Poland, Mazgajski and Kedra (1998) reported high intensities of infection (more than 10 oocysts per average field of vision) with *Isospora* sp. in 23.8% of fecal samples collected from starling nestlings.

Two reasons may explain the low prevalence and intensity of coccidia recorded in this study. First, a coccidial prevalence of 22.8% was found in 190 species of ground-feeding birds from South America (McQuiston,



**Figure 2A.** Three eggs of the cestode found in the fecal sample of a starling nestling.



**Figure 2B.** Egg of a cestode containing the hexacanth embryo with 6 hooks.

2000). If bird species in the same area as the starlings had lower coccidial prevalences than those in other parts of the world, then starlings are also expected to show lower values. Second, nestlings are usually less infected than adults, which are more exposed to contaminated feces, because they forage on the ground in heterospecific flocks (Rebolo and Fiorini, 2010). Nevertheless, the risk of oocyst transmission is higher in nestlings of 17–18 days of age than in younger ones, because parents only remove feces from the nest during the first 10–12 days after hatching (Feare, 1984). This would increase the likelihood of oocyst detection in chicks at the age under study.

*Isoospora* is the only genus of coccidia known to parasitize the starling (Boyd, 1951; Mazgajski and Kedra, 1998; Dolnik, 1999; Carlson et al., 2011). *Isoospora dilatata* (Schwalbach, 1959) was present in the feces of starlings in Europe (Dolnik, 1999), whereas *Isoospora lacazei* (Labbé, 1893) was found in the feces of adult starlings from Poland (Mazgajski and Kedra, 1998) and the United States (Boyd, 1951). The species of coccidia found in Berazategui appears to belong to the species *I. paroariae*. Upton et al. (1985) described *I. paroariae* from birds in the United States imported from Argentina.

With regard to cestodes, starlings from Argentina showed a substantial decrease in the number of species in comparison to starling populations from the United States (8 species) and eastern Europe (12 species); of these, 3 species were found on both continents and 2 were acquired in the newly colonized area (Boyd, 1951; Hair and Forrester, 1970; Cooper and Crites, 1976). In contrast, in Argentina, Valente et al. (2014) did not find cestodes in the gastrointestinal tract of 76 adult and juvenile starlings from Bernal, Buenos Aires (17 km from our study area), and in the present study we observed eggs of only one species. Cestode prevalence in fecal samples was 71% in adult starlings from the United States (Boyd, 1951) and 2% in starling nestlings from Argentina. These differences can be attributed to different age groups, although the lack of cestodes in the samples studied by Valente et al. (2014) provides evidence of low infection levels in the starlings of Argentina.

Hair and Forrester (1970) compared the helminthic fauna of invasive starlings in North America with that of starlings in Europe, northeastern Africa, and western Asia. They reported that the introduced specimens lost 26 species from 15 genera of trematodes, 24 species from 14 genera of nematodes, and 6 species from 4 genera of acanthocephalans. Moreover, 5 species of trematodes, 11 species of nematodes, and 3 species of acanthocephalans were found for the first time in starlings from the United States (Hair and Forrester, 1970; Cooper and Crites, 1976). In Argentina, only one trematode (*Echinostoma revolutum*), one acanthocephalan (*Plagiorhynchus cylindraceus*), and 4 nematodes (*Synhimantus nasuta*, *Microtetrameres* sp., *Pterothominx exilis*, and *Ornithocapillaria ovopunctata*) were found in juvenile and adult starlings from Bernal, Buenos Aires (Valente et al., 2014).

Our results suggest that starlings may have lost a large number of parasite species during the colonization process in Argentina, which in turn could have facilitated their establishment and population growth.

#### Acknowledgments

We thank Juliana Notarnicola for her valuable suggestions on improving the manuscript and Luis Alberto Giambelluca for his help in preparing the digital photographs.

## References

- Álvarez-Romero JG, Medellín RA, Oliveras de Ita A, Gómez de Silva H, Sánchez O (2008). Animales Exóticos en México: una Amenaza para la Biodiversidad. Mexico City, Mexico: Comisión Nacional para el Conocimiento y Uso de la Biodiversidad (in Spanish).
- Atkinson CT, Thomas NJ, Hunter DB (2008). Parasitic Diseases of Wild Birds. 1st ed. Ames, IA, USA: Wiley-Blackwell.
- Ballard NB, Olsen OW (1966). Helminths of the starling, *Sturnus vulgaris* L., from Northeastern Colorado. J Parasitol 52: 372.
- Bernard J (1987). Parasitic helminthes of flying starlings (*Sturnus vulgaris* L.) in their nesting area. Arch Inst Pasteur Tunis 64: 477-499.
- Blackburn TM, Lockwood JL, Casey P (2009). Avian Invasions: The Ecology and Evolution of Exotic Birds. 1st ed. Oxford, UK: Oxford University Press.
- Boyd EM (1951). A survey of parasitism of the starling *Sturnus vulgaris* in North America. J Parasitol 37: 56-84.
- Bush A, Lafferty K, Lotz J, Shostak A (1997). Parasitology meets ecology on its own terms: Margolis et al. revisited. J Parasitol 83: 575-583.
- Carlson JC, Linz GM, Ballweber LR, Elmore SA, Pettit SE, Franklin A (2011). The role of European starlings in the spread of coccidia within concentrated animal feeding operations. Vet Parasitol 180: 340-343.
- Cooper CL, Crites JL (1976). Additional checklist of helminthes of starlings (*Sturnus vulgaris* L.). Am Midl Nat 95: 191-194.
- Dolnik OV (1999). Diurnal periodicity of oocyst release of *Isospora dilatata* (Sporozoa: Eimeriidae) from the common Starling (*Sturnus vulgaris*) in nature. Parasitologiya 33: 74-80.
- Feare CJ (1984). The Starling. 1st ed. Oxford, UK: Oxford University Press.
- Greiner EC (2008). *Isospora*, *Atoxoplasma*, and *Sarcocystis*. In: Atkinson CT, Thomas NJ, Hunter DB, editors. Parasitic Diseases of Wild Birds. 1st ed. Ames, IA, USA: Wiley-Blackwell, pp. 108-119.
- Hair JD, Forrester DJ (1970). The helminth parasites of the starling (*Sturnus vulgaris*): a checklist and analysis. Am Midl Nat 83: 555-564.
- Markell EK, John DT, Krotoski WA (1999). Medical Parasitology. 8th ed. Philadelphia, PA, USA: WB Saunders.
- Mazgajski TD, Kedra AH (1998). Endoparasite *Isospora* sp. (Coccidia, Eimeriidae) affects the growth of starling *Sturnus vulgaris* nestling. Acta Parasitol 43: 214-216.
- Mazzulla J (2013). Primeros registros de estornino pinto *Sturnus vulgaris* (Linnaeus 1758) (Aves, Passeriformes, Sturnidae) en Uruguay. Nov Ornitol 3: 1-17 (in Spanish).
- McLaughlin JD (2008). Cestodes. In: Atkinson CT, Thomas NJ, Hunter DB, editors. Parasitic Diseases of Wild Birds. 1st ed. Ames, IA, USA: Wiley-Blackwell, pp. 108-119.
- McQuiston TE (2000). The prevalence of coccidian parasites in passerine birds from South America. Trans Ill Acad Sci 93: 221-227.
- Navas JR (2002). Introduced and naturalized exotic birds in Argentina. Rev Mus Arg Cienc Nat 4: 191-202.
- Pérez J (1988). Estornino pinto en la Capital Federal. Nuestras Aves 17: 14 (in Spanish).
- Peris S, Soave G, Camperi A, Darrieu C, Aramburu R (2005). Range expansion of the European starling *Sturnus vulgaris* in Argentina. Ardeola 52: 359-364.
- Rebolo N, Fiorini VD (2010). European starling (*Sturnus vulgaris*): population density and interactions with native species in Buenos Aires urban parks. Neotrop Ornithol 21: 507-518.
- Sommer JB (1937). Parasites of the European starling in Illinois. Auk 54: 50-54.
- Torchin ME, Lafferty KD, Dobson AP, McKenzie VJ, Kuris AM (2003). Introduced species and their missing parasites. Nature 421: 628-630.
- Torchin ME, Mitchell CE (2004). Parasites, pathogens, and invasions by plants and animals. Front Ecol Environ 2: 183-190.
- Upton SJ, Current WL, Clubb SL (1985). Two new species of *Isospora* (Apicomplexa: Eimeriidae) from passeriform birds of South America. Syst Parasitol 7: 227-229.
- Valente R, Ibañez LM, Fiorini VD, Montalti D, Díaz J (2014). Estudio de la helmintofauna del ave invasora estornino pinto (*Sturnus vulgaris*) en el noreste de la provincia de Buenos Aires. Parasitol Res 113: 2719-2724 (in Spanish).
- Vincent AL (1972). Parasites of the starling, *Sturnus vulgaris*, in San Diego County, California. J Parasitol 58: 1020-1022.