



Morphological and Molecular Characteristics of *Sarcocystis aucheniae* Isolated from Meat of Guanaco (*Lama guanicoe*)

C. Regensburger¹, M.L. Gos^{2,3}, J. Ctibor¹, G. Moré^{2,3*}

1. Unidad Académica Caleta Olivia, Universidad Nacional de la Patagonia Austral, Santa Cruz, Argentina

2. Laboratorio de Inmunoparasitología, Facultad de Ciencias Veterinarias, Universidad Nacional de La Plata, La Plata

3. Consejo Nacional de Investigaciones Científicas y Técnicas (CONICET), Buenos Aires, Argentina

Article type

Original article

Abstract

Keywords

Sarcocystis
Polymerase Chain Reaction
Sequence Analysis, DNA
Microscopy, Electron

Received: 5 Jul 2015

Revised: 25 Aug 2015

Accepted: 29 Sep 2015

Background: Sarcocystosis in South American camelids (SAC) is an important parasitic disease which results in economical loss due to carcass condemnation. Meat products from camelids are significant source of animal protein in several American countries. *Sarcocystis* spp. producing macroscopical cysts in these animals have been nominated as *S. aucheniae*, *S. tilopodi*, and *S. guanicoecanis*. The aim of the present study was to characterize morphologically and molecularly *Sarcocystis* spp. producing macroscopical cysts in guanacos (*Lama guanicoe*).

Methods: Samples of macroscopical cysts were dissected from guanaco muscles slaughtered in Santa Cruz province, Argentina. The samples were processed by transmission electron microscopy, polymerase chain reaction (PCR), cloning and sequencing studies.

Results: Cyst wall villar protrusions were irregular with a “tree” or “cauliflower-like” shape which measured 3-4.5 μm height by 2.5-3.5 μm width. A consensus *18S rRNA* full gene sequence of 1875 bp was obtained and showed the highest identity ($\geq 99\%$) with sequences of *S. aucheniae* reported in GenBank. The ultra structure of the cyst wall from macroscopical cysts and *18S rRNA* gene obtained from guanacos were identical and consistent with the descriptions of *S. aucheniae*.

Conclusion: This study confirms that guanacos are infected by the same *Sarcocystis* spp. affecting other SAC, named *S. aucheniae*, and reinforce the suggestion that nomination of new species should contain morphological and molecular data to reach validity. In future, this data could be useful to obtain proper identifications in post-mortem inspection and helpful to improve meat safety.

Introduction

Sarcocystosis is a worldwide distributed parasitic infection caused by apicomplexan protozoans from genus *Sarcocystis* (Fayer, 2004). These intracellular parasites have a heteroxenous obligate two-host life cycle, where most *Sarcocystis* spp. use carnivores or omnivores as definitive hosts (DH) and herbivores as intermediate hosts (IH). The infection of IH is generally asymptomatic

and chronic where parasites reproduce asexually producing muscle cysts or sarcocysts (Dubey et al., 2015). The DH expels oocysts within its feces as a source of infection for the IH. When a suitable IH ingests the oocysts, after some developmental stages, sarcocysts are produced in musculature organs e.g. diaphragm, intercostal muscle, esophagus, heart, tongue, etc. (Hajimohammadi et al., 2014a; More et al., 2011; Obijiaku et al., 2013; Oryan et al., 2011; Xiang et al., 2009). Several herbivore species have been found infected with high prevalence closer

* Corresponding author

E-mail: gastonmore@fcv.unlp.edu.ar

to 90-100% in all over the world (Bottner et al., 1987; Bucca et al., 2011; Dubey et al., 2015; Fukuyo et al., 2002; Hajimohammadi et al., 2014b; Jehle et al., 2009; Latif et al., 1999; More et al., 2011; Valinezhad et al., 2008).

South American camelids (SAC) are an important source of animal protein in several American countries, especially in small communities from rural regions. Sarcocystosis in SAC is an important parasitic disease which results in economical loss due to carcass condemnation (Leguia, 1991; Rooney et al., 2014). Among SAC, guanacos (*Lama guanicoe*) are particularly high concentrated in Argentina, distributed mainly in the south and west regions of the country. Sarcocystosis in guanacos has been reported as caused by *S. tilopodi* (syn. *S. guani-coecanis*), which produces macroscopical sarcocysts and consequent meat condemnation or depreciation (Dubey et al., 2015; Quiroga et al., 1969). However, most of the original studies nominated the species from guanacos without proper morphological descriptions and comparisons with other described *Sarcocystis* spp. in SAC, like *S. aucheniae* from llamas (Gorman et al., 1984; Quiroga et al., 1969; Rooney et al., 2014; Schnieder et al., 1983). Most *Sarcocystis* spp. have a particular cyst wall ultra structure as well as differences on sequences of *18S rRNA* and *cox-1* genes which made plausible proper identifications (Dubey et al., 2015; Gjerde, 2013; More et al., 2013; Odening, 1998).

The aim of the present study was to characterize morphologically and molecularly (*18S rRNA* gene) *Sarcocystis* spp. producing macroscopical cysts in guanacos from Argentina.

Materials and methods

Samples and microscopy

Macroscopical cysts were dissected from guanaco muscles slaughtered in Santa Cruz province, Argentina. The samples were transported to laboratory refrigerated at 4 °C and were further processed by light microscopy, fixed in 2% glutaraldehyde for transmission electron microscopy (TEM) and conserved at -20 °C for DNA extraction and molecular studies. TEM studies were conducted as previously for sarcocysts obtained from cattle samples (More et al., 2011).

PCR, cloning and sequencing of *18S rDNA*

Two individual cysts from different animals were submitted to DNA extraction with a commercial kit (Wizard genomics, Promega), according manufacturer instructions. Samples of DNA were amplified by PCR

to reach the full length of the *18S rRNA* gene, purified, cloned into plasmids and sequenced as previously (More et al., 2013). Briefly, primers ERIB1 and B were used with the following thermo cycler program: 94 °C (4 min), 40 cycles of 94 °C (40 s), 58 °C (1 min), 72 °C (2 min) and final extension of 72 °C (5 min). Amplification products were purified using the QIA quick purification kit (Qiagen, Germany). Purified products were cloned with a TA Cloning® kit (Invitrogen, USA) using One Shot® TOP10 chemically competent *Escherichia coli* according to the manufacturer's instructions. White colonies for each transformation were grown overnight at 37 °C in 4 ml luria bertani (LB) medium with ampicillin, and DNA was extracted from 2 ml of LB with Invisorb® Spin Plasmid Mini Two kit (Stratec Molecular GmbH, Germany), according to the manufacturer's instructions. Samples of 5 µl of each plasmid DNA preparation were submitted for sequencing with 6 primers to the light run service of GATC biotech as previously described by More et al. (2013).

Obtained sequences were aligned and analyzed with the GENEIOUS software. Finally, the sequences were compared by BLASTn function from NCBI (Altschul et al., 1997).

Results

Macroscopical cysts measured 2-7 mm and some were surrounded by a laminar layer or "capsule" of about 40-60 µm. Each sarcocyst contains about 10-15 million bradyzoites. By TEM, the sectioned cysts evidenced a solid package of bradyzoites within septa in the peripheral area, and fluid-like material without bradyzoites in the centre. The total thickness of cyst wall measured up to 10 µm including the ground substance layer (gs) which measured 3-5 µm and form the thick septa of about 2-3 µm. Cyst wall villar protrusions (vp) were irregular with a "tree" or "cauliflower-like" shape which measured 3-4.5 µm height by 2.5-3.5 µm width (Fig. 1). Bradyzoites measured 13-18 µm x 3-5 µm. Each bradyzoite contains several elongated micronemes (100 nm x 500 nm), dense granules (400-600 nm in diameter) and amylopectin granules (200-400 nm in diameter).

The PCR targeting, the full *18S rRNA* gene evidenced a strong product in both cyst samples as illustrated in Fig. 2. A total of two clones from each sample were sequenced and consensus sequences obtained (n=4) were identical. A complete gene sequence of 1875 bp was obtained and BLASTn comparison showed the highest identity (≥ 99%) with sequences of *S. aucheniae* reported in GenBank (KF3832666-KF3832668). The sequence obtained in the present study was registered in GenBank under the accession number KT382799.

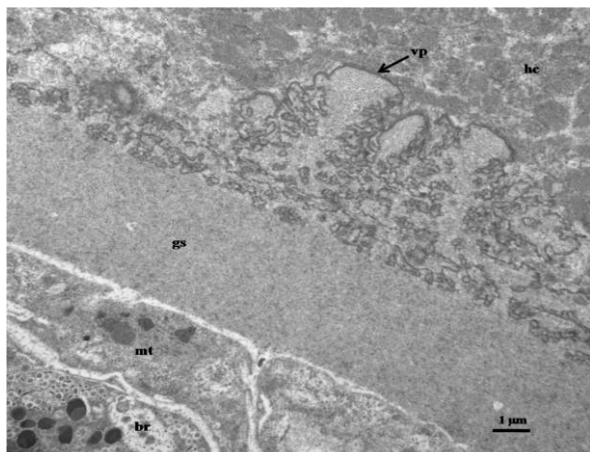


Fig. 1: TEM examination of the cyst wall from a macroscopical sarcocyst in guanaco (*Lama guanicoe*). Note villar protrusions (vp), a thick ground substance layer (gs), sectioned bradyzoite (br) and metrocyst (mt). Also, note the irregular distribution of the muscle proteins from muscle host cell (hc)

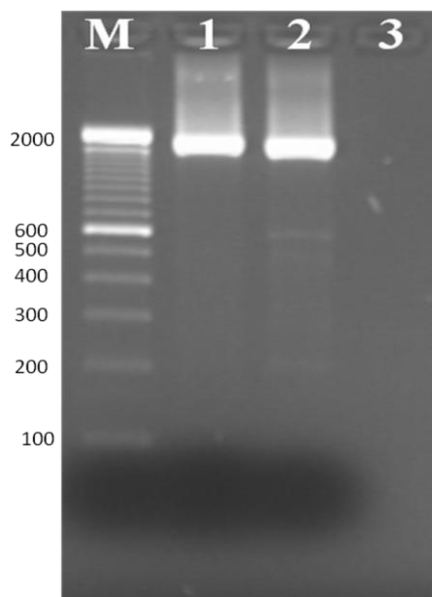


Fig. 2: Gel electrophoresis of samples amplified by PCR. Lanes 1 and 2: the amplification macroscopical cysts from guanaco muscles, the amplicons of ≈ 1850 bp in both samples. Lane 3: negative control. M: 100 bp DNA ladder (double concentrated bands correspond to 600 bp and 2000 bp)

Discussion

Meat and meat products from SAC are important sources of animal protein in the Andes and Patagonian regions from South America. Some farmers, zoo technical and veterinary practitioners related with SAC production as well as SAC meat consumers are aware about the sarcocystosis, mainly referred as the presence of macroscopical cysts (Rooney et al., 2014). The detection of macroscopical cysts caused meat and

carcasses condemnation, remaining as an important economical lost in several South American countries (Leguia, 1991; Rooney et al., 2014). The production of macroscopical cysts has been attributed to *S. aucheniae* in llamas, alpacas and vicuñas and *S. tilopodi* or *S. guanicoecanis* in guanacos. However, molecular and morphological studies are lacking. Moreover, the validity of these species names as well as other poorly described *Sarcocystis* spp. is under discussion (Dubey et al., 2015).

In the present study, the ultra structure of the cyst wall from macroscopical cysts obtained from guanacos was almost identical and consistent with the descriptions of *S. aucheniae* sarcocysts from llamas (Dubey et al., 2015; Schnieder et al., 1983). Additionally, the comparison of *18S rRNA* gene sequences from macroscopical cysts showed a high sequence identity ($\geq 99\%$) with the sequences reported on the GenBank as *S. aucheniae* from llamas (KF383266-KF3832668) from Argentina and an alpaca (AF017123) in Australia (Carletti et al., 2013; Holmdahl et al., 1999). Altogether, this study suggests that there is only one valid species producing macroscopical cysts in all SAC, which should be nominated as *S. aucheniae*. Therefore, the proposed nomenclature of *S. tilopodi* from Argentinean guanacos (Quiroga et al., 1969) and *S. guanicoecanis* should be replaced by *S. aucheniae*. According experimental infection results, this species use dogs as DH (Gorman et al., 1984; Schnieder et al., 1983). However, when analyzed phylogenetically, *S. aucheniae* aligned in a separated branch from other *Sarcocystis* spp. which used canids as DH (Carletti et al., 2013; Holmdahl et al., 1999; More et al., 2014). Therefore, more studies are needed in order to identify naturally infected DH of *S. aucheniae*.

Conclusion

This study confirms that guanacos are infected by the same *Sarcocystis* species affecting other SAC, named *S. aucheniae*, and reinforce the suggestion that nomination of new species should contain morphological and molecular data to reach validity. In future, this data could be useful to reach proper identifications in post-mortem inspection and also helpful to improve meat safety and quality.

Conflicts of interest

There is no conflict of interest.

Acknowledgements

We would like to thank Isidoro Ercoli and Roxana Peralta for their excellent technical assistance. Gaston More was supported by the Alexander von Humboldt

foundation through a George Forster Research Fellowship (ARG 1141453 STP).

References

- Altschul S.F., Madden T.L., Schäffer A.A., Zhang J., Zhang Z., Miller W., Lipman D.J. (1997). Gapped BLAST and PSI-BLAST: a new generation of protein database search programs. *Nucleic Acids Research*. 25: 3389-3402.
- Bottner A., Charleston W.A.G., Pomroy W.E., Rommel M. (1987). The prevalence and identity of *Sarcocystis* in beef cattle in New Zealand. *Veterinary Parasitology*. 24: 157-168.
- Bucca M., Brianti E., Giuffrida A., Ziino G., Cicciari S., Panebianco A. (2011). Prevalence and distribution of *Sarcocystis* spp. cysts in several muscles of cattle slaughtered in Sicily, Southern Italy. *Food Control*. 22: 105-108.
- Carletti T., Martin M., Romero S., Morrison D.A., Marcoppido G., Florin-Christensen M., Schnittger L. (2013). Molecular identification of *Sarcocystis aucheniae* as the macrocyst-forming parasite of llamas. *Veterinary Parasitology*. 198: 396-400.
- Dubey J.P., Calero-Bernal R., Rosenthal B.M., Speer C.A., Fayer R. (2015). *Sarcocystosis* of animals and humans. 2nd edition. CRC Press, Boca Raton.
- Fayer R. (2004). *Sarcocystis* spp. in human infections. *Clinical Microbiology Reviews*. 17: 894-902.
- Fukuyo M., Battsetseg G., Byambaa B. (2002). Prevalence of *Sarcocystis* infection in meat-producing animals in Mongolia. *Southeast Asian Journal of Tropical Medicine and Public Health*. 33: 490-495.
- Gjerde B. (2013). Phylogenetic relationships among *Sarcocystis* species in cervids, cattle and sheep inferred from the mitochondrial cytochrome c oxidase subunit I gene. *International Journal for Parasitology*. 43: 579-591.
- Gorman T.R., Alcaino H.A., Munoz H., Cunazza C. (1984). *Sarcocystis* spp. in guanaco (*Lama guanicoe*) and effect of temperature on its viability. *Veterinary Parasitology*. 15: 95-101.
- Hajimohammadi B., Dehghani A., Ahmadi M.M., Eslami G., Oryan A., Khamesipour A. (2014a). Prevalence and species identification of *Sarcocystis* in raw hamburgers distributed in Yazd, Iran using PCR-RFLP. *Journal of Food Quality and Hazards Control*. 1: 15-20.
- Hajimohammadi B., Eslami G., Zohourtabar A., Dehghani A., Oryan A., Pourmirzaei Tafti H., Radouani F. (2014b). High occurrence of *Sarcocystis* cysts in meat produced in Yazd, Central Iran. *Journal of Food Quality and Hazards Control*. 1: 95-101.
- Holmdahl O.J.M., Morrison D.A., Ellis J.T., Huong L.T. (1999). Evolution of ruminant *Sarcocystis* (Sporozoa) parasites based on small subunit rDNA sequences. *Molecular Phylogenetics and Evolution*. 11: 27-37.
- Jehle C., Dinkel A., Sander A., Morent M., Romig T., Luc P.V., De T.V., Thai V.V., Mackenstedt U. (2009). Diagnosis of *Sarcocystis* spp. in cattle (*Bos taurus*) and water buffalo (*Bubalus bubalis*) in Northern Vietnam. *Veterinary Parasitology*. 166: 314-320.
- Latif B.M.A., Al-Delemi J.K., Mohammed B.S., Al-Bayati S.M., Al-Amiry A.M. (1999). Prevalence of *Sarcocystis* spp. in meat-producing animals in Iraq. *Veterinary Parasitology*. 84: 85-90.
- Leguia G. (1991). The epidemiology and economic impact of llama parasites. *Parasitology Today*. 7: 54-56.
- More G., Abrahamovich P., Jurado S., Bacigalupe D., Marin J.C., Rambeaud M., Venturini L., Venturini M.C. (2011). Prevalence of *Sarcocystis* spp. in Argentinean cattle. *Veterinary Parasitology*. 177: 162-165.
- More G., Pantchev N., Herrmann D.C., Vrhovec M.G., Ofner S., Conraths F.J., Schares G. (2014). Molecular identification of *Sarcocystis* spp. helped to define the origin of green pythons (*Morelia viridis*) confiscated in Germany. *Parasitology*. 141: 646-651.
- More G., Schares S., Maksimov A., Conraths F.J., Venturini M.C., Schares G. (2013). Development of a multiplex real time PCR to differentiate *Sarcocystis* spp. affecting cattle. *Veterinary Parasitology*. 197: 85-94.
- Obijaku I.N., Ajogi I., Umoh J.U., Lawal I.A., Atu B.O. (2013). *Sarcocystis* infection in slaughtered cattle in Zango abattoir, Zaria, Nigeria. *Veterinary World*. 6: 346-349.
- Odening K. (1998). The present state of species-systematics in *Sarcocystis* Lankester, 1882 (Protista, Sporozoa, Coccidia). *Systematic Parasitology*. 41: 209-233.
- Oryan A., Sharifiyazdi H., Khordadmehr M., Larki S. (2011). Characterization of *Sarcocystis fusiformis* based on sequencing and PCR-RFLP in water buffalo (*Bubalus bubalis*) in Iran. *Parasitology Research*. 109: 1563-1570.
- Quiroga D., Lombardero O., Zorrilla R. (1969). *Sarcocystis tilopodi* Nsp. en guanacos (*Lama guanicoe*) de la Republica Argentina. *Gaceta Veterinaria*. 31: 67-70.
- Rooney A.L., Limon G., Vides H., Cortez A., Guitian J. (2014). *Sarcocystis* spp. in llamas (*Lama glama*) in Southern Bolivia: a cross sectional study of the prevalence, risk factors and loss in income caused by carcass downgrades. *Preventive Veterinary Medicine*. 116: 296-304.
- Schnieder T., Kaup F.J., Drommer W., Thiel W., Rommel M. (1983). Fine structure and development of *Sarcocystis aucheniae* in llamas. *Zeitschrift für Parasitenkunde (Berlin, Germany)*. 70: 451-458.
- Valinezhad A., Oryan A., Ahmadi N. (2008). *Sarcocystis* and its complications in camels (*Camelus dromedarius*) of eastern provinces of Iran. *Korean Journal of Parasitology*. 46: 229-234.
- Xiang Z., Chen X., Yang L., He Y., Jiang R., Rosenthal B.M., Luan P., Attwood S.W., Zuo Y., Zhang Y.P., Yang Z. (2009). Non-invasive methods for identifying oocysts of *Sarcocystis* spp. from definitive hosts. *Parasitology International*. 58: 293-296.