

ORIGINAL ARTICLE

***Sarcocystis rommeli*, n. sp. (Apicomplexa: Sarcocystidae) from Cattle (*Bos taurus*) and its Differentiation from *Sarcocystis hominis***

Jitender P. Dubey<sup>a</sup>, Gastón Moré<sup>b,c</sup>, Erna van Wilpe<sup>d</sup>, Rafael Calero-Bernal<sup>a</sup>, Shiv K. Verma<sup>a</sup> & Gereon Schares<sup>e</sup>

a U.S. Department of Agriculture, Agricultural Research Service, Beltsville Agricultural Research Center, Animal Parasitic Diseases Laboratory, Building 1001, Beltsville, Maryland 20705-2350, USA

b Laboratorio de Inmunoparasitología, Facultad de Ciencias Veterinarias, Universidad Nacional de La Plata, Calle 60 y 118, 1900, La Plata, Argentina

c Consejo Nacional de Investigaciones Científicas y Técnicas (CONICET), Av. Rivadavia 1917, C1033AAJ, Buenos Aires, Argentina

d Department of Anatomy and Physiology, Faculty of Veterinary Science, University of Pretoria, Onderstepoort, South Africa

e Institut für Epidemiologie, Friedrich-Loeffler-Institut, Bundesforschungsinstitut für Tiergesundheit, Federal Research Institute for Animal Health, Südufer 10, 17493 Greifswald-Insel Riems, Germany

**Keywords**

Definitive host; Intermediate host; Molecular; Ultrastructure.

**Correspondence**

J.P. Dubey, Animal Parasitic Diseases Laboratory, Building 1001, BARC, USDA, Beltsville, MD 20705, USA

Telephone number: +1 301 504 8128; FAX number: +1 301 504 9222; e-mail: jitender.dubey@ars.usda.gov

Received: 5 May 2015; revised 22 May 2015; accepted June 22, 2015.

doi:10.1111/jeu.12248

**ABSTRACT**

Cattle (*Bos taurus*) are intermediate hosts for three named species of *Sarcocystis*, *S. cruzi*, *S. hirsuta*, and *S. hominis*. Recently, a fourth species was identified and named *S. sinensis*. However, *S. sinensis* originally named a species of *Sarcocystis* in water buffalo (*Bubalus bubalis*) in China. Based on unverifiable evidence, it was suggested that the same parasite infects cattle. In addition, *S. sinensis* was recently declared as *nomen nudum* because its naming violated the rules of International Code of Zoological Nomenclature. Thus, the fourth species using cattle as an intermediate host does not have a valid name. Here, we propose a new name, *Sarcocystis rommeli* for the *S. sinensis*-like parasite from cattle in Argentina, and differentiate it ultrastructurally from *S. hominis* sarcocysts from experimentally infected cattle. *Sarcocystis rommeli* sarcocysts were microscopic with a 5- $\mu$ m-thick wall with slender villar protrusions (Vp); the Vp were up to 5  $\mu$ m long, up to 0.5  $\mu$ m wide, and of uneven thickness, often bent at an angle. The ground substance layer (Gs) was up to 0.8  $\mu$ m thick and smooth. Vesicular structures were seen at the base of the Vp. The bradyzoites were 10–12  $\mu$ m long. *Sarcocystis hominis* sarcocysts had Vp that were often upright, up to 7.5  $\mu$ m long, and up to 1.8  $\mu$ m wide; the Gs was up to 2  $\mu$ m thick and without vesicles. Its sarcocyst wall was up to 5.6  $\mu$ m thick, the vp were bent at an angle, up to 5.8  $\mu$ m long, the Gs was up to 2  $\mu$ m thick, but without vesicles seen in *S. rommeli*. Beef containing sarcocysts of *S. rommeli* was not orally infectious for two human volunteers and a red fox (*Vulpes vulpes*). The *Sarcocystis* described here is molecularly different from *S. cruzi*, *S. hirsuta*, and *S. hominis* based on 18S rRNA and *cox1* gene sequences.

SPECIES of *Sarcocystis* usually have a two-host, prey-predator life cycle, with herbivores as intermediate hosts and carnivores as definitive hosts (Dubey et al. 1989, 2015). The intermediate host becomes infected with *Sarcocystis* species by ingesting sporocysts excreted in the feces of the definitive host. After a brief period of schizogony, the parasite encysts in tissues and forms sarcocysts.

The definitive host becomes infected by ingesting sarcocysts encysted in tissues of intermediate hosts.

Most livestock are intermediate hosts for more than one species of *Sarcocystis*. There are uncertainties concerning the identity and intermediate host species specificity of *Sarcocystis* species of the water buffalo (*Bubalus bubalis*) and cattle (*Bos taurus*). Before the discovery of

the two-host life cycle of *Sarcocystis* species (Heydorn and Rommel 1972) only one species of *Sarcocystis*, *S. fusiformis*, was considered to parasitize cattle (*B. taurus*) and water buffalo (*B. bubalis*). Heydorn et al. (1975) conclusively showed that there were three species of *Sarcocystis* using cattle (*B. taurus*) as intermediate hosts: *S. cruzi* (with canine definitive host), *S. hirsuta* (feline definitive host), and *S. hominis* (primate definitive host). Recently, a fourth *Sarcocystis* species, *S. sinensis*, with an unknown life cycle has been reported using cattle as an intermediate host (Chen et al. 2011; Moré et al. 2014).

*Sarcocystis sinensis* originally named a species in water buffalo from China (Zuo and Yang 2015; Zuo et al. 1990, 1995). Subsequently, it was proposed that *S. sinensis* parasitizes both cattle and buffalo based on reports of transmission of *Sarcocystis* species between cattle and buffalo, but steps to preclude exogenous exposures were not reported (Dubey et al. 2014). Currently, all evidence indicates that *Sarcocystis* species parasitizing the livestock are host specific (Dubey et al. 2015). Recently, "*S. sinensis*", was declared as a *nomen nudum* because its naming violated the International Code of Zoological Nomenclature (Dubey et al. 2014). Here we propose a new name, *S. rommeli*, for the *S. sinensis* in cattle.

## MATERIALS AND METHODS

### Samples studied

Sarcocysts were isolated from beef loin samples from Argentina. Thick-walled sarcocysts ( $\geq 3 \mu\text{m}$ ) were identified microscopically and fixed in 2.5% glutaraldehyde solution as described previously (Moré et al. 2014). DNA was extracted from purified individual sarcocysts or cysts portions, amplified and sequenced with primers SarcoFext and SarcoRext as described (Moré et al. 2014). Epoxy-resin embedded tissues were transported to the Faculty of Veterinary Science, University of Pretoria, Onderstepoort, Republic of South Africa for this present study. Toluidine blue-stained resin sections of four microcysts were photographed with an Olympus BX63 compound microscope (Olympus, Wirsam, South Africa). Ultrathin resin sections were contrasted with uranyl acetate and lead citrate and examined in a Philips CM10 transmission electron microscope (FEI, Eindhoven, The Netherlands) operated at 80 kV. Digital images were captured with a Megaview III side-mounted digital camera and iTEM software (Olympus Soft Imaging Solutions GmbH, Münster, Germany). Electronic images (TIFF) were sent from South Africa to the senior author (JPD) at Beltsville, Maryland to avoid importation of tissues from cattle in the USA.

### Comparison of the present study with *Sarcocystis hominis* sarcocysts

Two newborn calves in 1983 were inoculated with *S. hominis* sporocysts from a human volunteer who had ingested

raw minced beef from Turkey (Dubey et al. 1988). The calves were euthanized 111 and 222 d postinoculation (p.i.). Tissues, including TEM blocks, from these two calves had been discarded, and were not available for resectioning. However, unpublished TEM graphs from the original study were found and were evaluated for the present study.

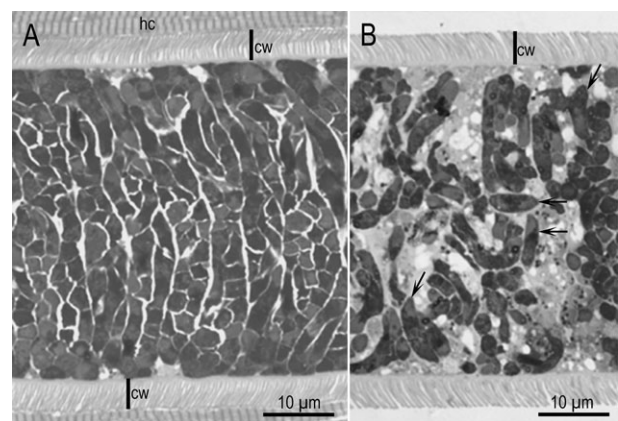
### Experimental infection of potential definitive hosts

Sarcocysts obtained from minced beef in Germany identified by morphological criteria, PCR and sequencing as "*S. sinensis*" (Moré et al. 2014) were used. Three isolated cysts were disrupted by passage in syringe and needle and stained with Trypan blue to verify bradyzoite viability. Two humans and one red fox (*Vulpes vulpes*) each ingested 300 purified sarcocysts from cattle in Germany (Moré et al. 2014). Human volunteers were two of the authors (GM and GS) who conducted this study knowing the potential risk involved. Stool samples were collected in alternate days during a 2-wk period before ingestion and daily during 35 d post ingestion. Samples were processed by an overnight water sedimentation followed by sucrose flotation technique. Clinical symptoms (if any) were recorded daily.

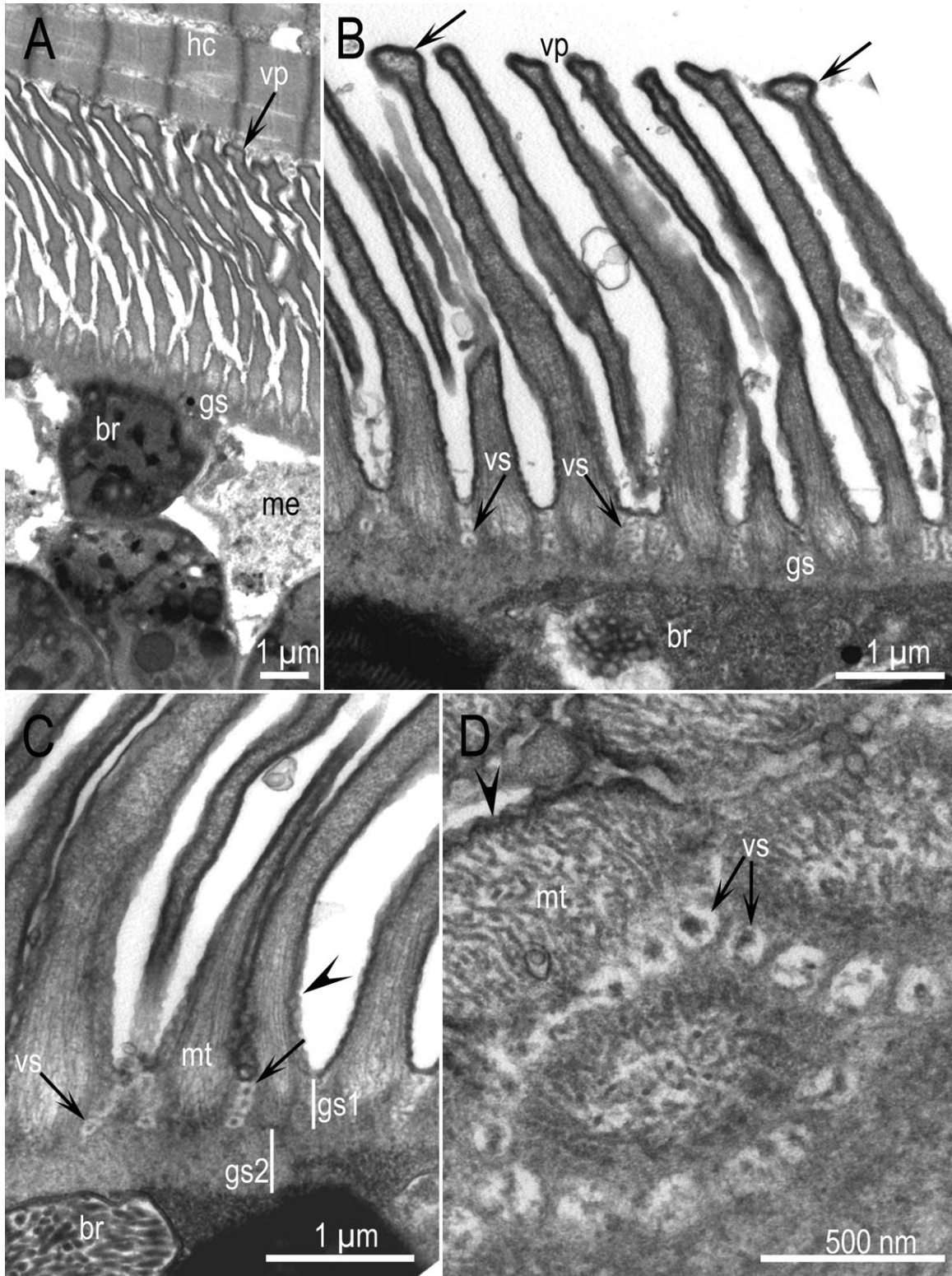
## RESULTS

### Sarcocysts from naturally infected cattle

In total, four sarcocysts (#4, 5, 6, 8) from the Argentinian beef were studied ultrastructurally. Sarcocysts were microscopic, and intact sarcocysts were not available for measurements. In 1- $\mu\text{m}$  Toluidine blue-stained sections the sarcocyst wall was 4.5–5.0  $\mu\text{m}$  thick. Representatives of intramuscular sarcocysts (Fig. 1A) and cysts freed from the muscle (Fig. 1B) are shown in Fig. 1.



**Figure 1** *Sarcocystis rommeli* n. sp. sarcocysts from beef from Argentinian cattle. 1- $\mu\text{m}$  section. Toluidine blue stain. **A.** Intramuscular sarcocyst (cyst #4). **B.** Sarcocyst freed from muscle (cyst #5). Note thick wall (cw) with villar protrusions, and numerous bradyzoites, some of them cut longitudinally (arrows).



**Figure 2** TEM of *Sarcocystis rommeli* n. sp. sarcocyst walls. Note bradyzoites (br), metrocyte (me), villar protrusions (vp), vesicles (vs), microtubules (mt), and ground substance (gs). Cyst #4. The parasitophorous vacuolar membrane is lined by 20–30 nm thick electron dense layer that is thin at places (arrowheads). **A**. Note irregular shaped vp juxtaposed with host cell (hc) and absence of inflammation. **B, C**. Higher magnification showing mt in the vp originating from the mid gs, and vs at the base of vp. Arrows point to broader tips of the vp. in Fig. 2B. **D**. Higher magnification of the base of vp showing vs. Cyst #6.



Ultrastructurally, the sarcocyst wall had elongated villar protrusions (Vp), often bent at an angle (Fig. 2). The Vp were up to 5  $\mu\text{m}$  long and of uneven width; they were up to 0.8  $\mu\text{m}$  wide at the base and up to 0.6  $\mu\text{m}$  wide at the tip (Fig. 2B). The parasitophorous vacuolar membrane (Pvm) covering the Vp was irregular and lined with an electron dense layer that was thin or absent at irregular distances giving appearance of empty spaces on the Pvm (Fig. 2C). The Vp contained microtubules (Mt) that were without granules; the Mt originated from the middle of the ground substance layer (Gs). The Gs was thin and not well demarcated (Fig. 2B, C). The total Gs thickness from the base of the Vp to the zoites was 0.6–0.8  $\mu\text{m}$ . The Gs width between the base of Vp and the origin of the microtubules (Gs1) was 0.3–0.4  $\mu\text{m}$  thick, and the Gs2 from the base of Mt and zoites was 0.3  $\mu\text{m}$  (Fig. 2C). Rows of vesicles (Vs) were seen at the base of Vp (Fig. 2C, D). These vesicles were approximately 120 nm in diam. and had an electron dense central area (Fig. 2D).

All sarcocysts were mature and contained numerous bradyzoites and a few metrocytes. The bradyzoites were elongated and packed, so it was difficult to measure them. They were 10–12  $\mu\text{m}$  long and 2.0–2.5  $\mu\text{m}$  wide. They contained a conoid (Co), two rhoptries (Rh1,2), numerous micronemes (Mn), a long twisted mitochondrion (Mc), numerous amylopectin granules (Am), a micropore (Mp), and 22 subpellicular (St) microtubules (Fig. 3).

### *Sarcocystis hominis*

Sarcocysts were microscopic. The Vp were 5.0–7.5  $\mu\text{m}$  long and up to 1.8  $\mu\text{m}$  wide (Fig. 4–6). The Vp were approximately same length at 111 vs. 222 d p.i. but thinner at 111 d p.i. (Fig. 4–6). The microtubules in the Vp originated at the base of the Gs, smooth, and filamentous. The Gs layer was up to 2  $\mu\text{m}$  thick, depending on the origin of septa; it was thicker at the origin of septa. The Gs was well demarcated and without microtubules, and had few granules (Fig. 4–6). The metrocytes were 6–10  $\mu\text{m}$  in greatest dimension and contained a nucleus, a few amylopectin granules, a mitochondrion, and lipid bodies (Fig. 5). The bradyzoites were 10–12  $\mu\text{m}$  long and 2.5–4.0  $\mu\text{m}$  wide. They contained a conoid (Co), two rhoptries, dense granules (Dg), numerous amylopectin granules (Am), a terminally located nucleus (Nu), and a long mitochondrion (Mc) (Fig. 6). These results supplement the description of the sarcocyst wall reported earlier by Dubey et al. (1988). Additionally, structures of metrocytes and bradyzoites were added.

### Experimental infection of potential definitive hosts

*Sarcocystis* sporocysts were not detected in the feces of both human volunteers and the fox, that ingested sarcocysts. Bradyzoites viability was 85% at moment of ingestion. Either humans or the fox remained asymptomatic.

### 18S rRNA gene partial sequences

A total of three consensus sequences of 577, 592 and 615 bp were obtained (KT193615, KT193616, KT193617). Comparison with other sequences reported on GenBank by BLASTn analysis revealed a 99–100% of homology with sequences designated as *S. sinensis* (Highest *e*-value with KF954730).

### Description of *Sarcocystis rommeli* n. sp

**Diagnosis.** Sarcocysts microscopic, sarcocyst wall 4.5–5.2  $\mu\text{m}$  thick. Villar protrusions (Vp) 4–5  $\mu\text{m}$  long, wavy, bent at an angle with microtubules extending from the tip to the middle of the ground substance layer (Gs), with vesicles at the base. The Gs thin (<1  $\mu\text{m}$  thick). Bradyzoites 10–12  $\mu\text{m}$  long.

**Etymology.** Species named after Dr Michel Rommel who, with Otto Heydorn, pioneered the discovery of the two-host life cycle of *Sarcocystis* in 1972.

**Intermediate host.** Cattle (*B. taurus*).

**Distribution.** Europe, Argentina, probably elsewhere.

**Definitive host.** Unknown.

### Remarks

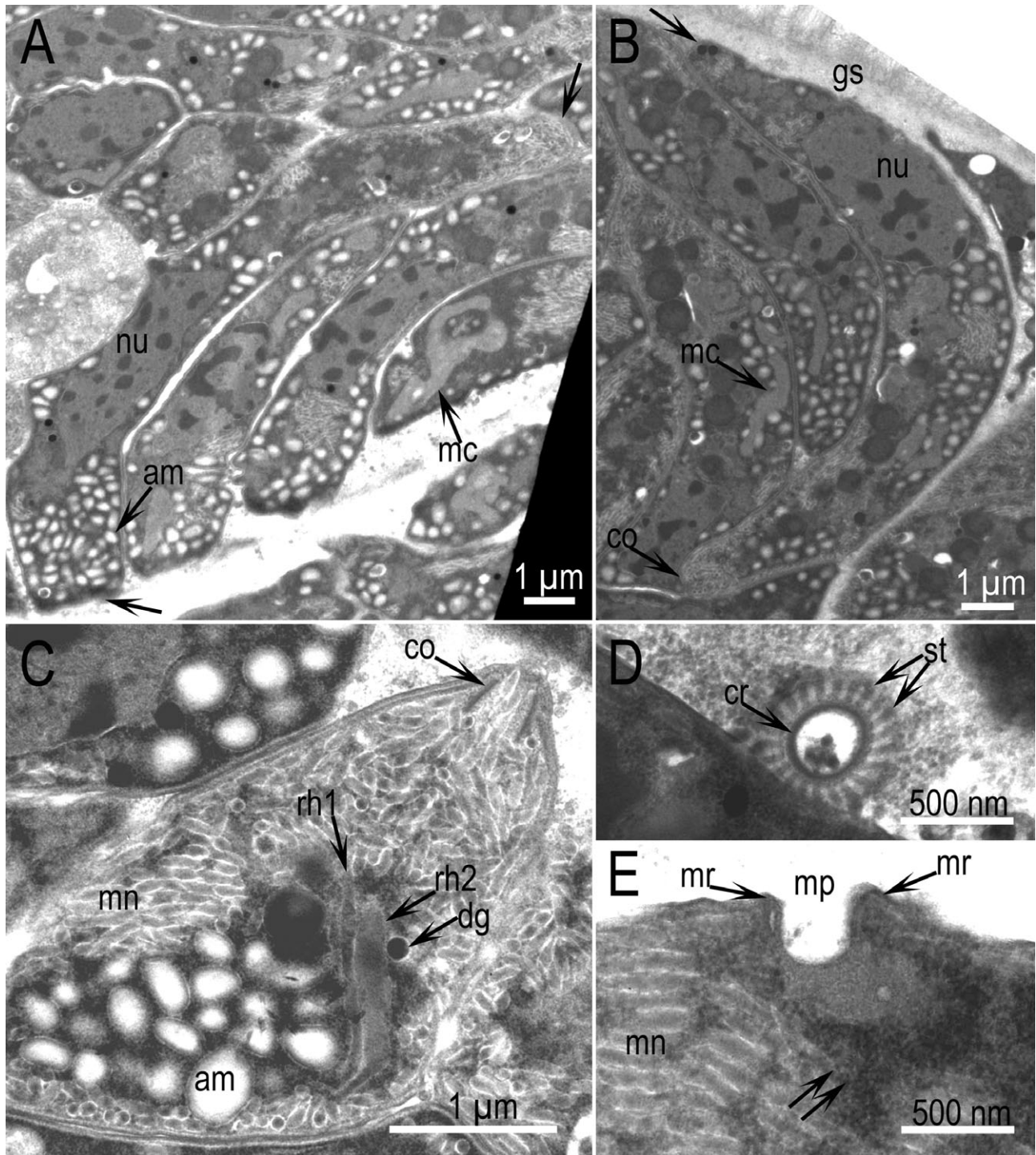
The presence of vesicles at the base of villar protrusions is the characteristic that separates *S. rommeli* from *S. cruzi*, *S. hominis*, and *S. hirsuta*.

**Specimens deposited.** Toluidine blue-stained histological sections of beef muscle syntypes deposited in the United States National Parasite Collection in the Division of Invertebrate Zoology and National Museum of Natural History, Smithsonian Institution, Washington, DC under (USNM-1283484). Sequences deposited in GenBank KT193615, KT193616, KT193617.

### DISCUSSION

The identification of *Sarcocystis* species in beef is of epidemiological interest because of the four species of bovine *Sarcocystis*, only *S. hominis* is proven to be zoonotic (Dubey et al. 2015). Of the species of *Sarcocystis* in cattle, only *S. hirsuta* sarcocysts can be macroscopic and they are relatively rare. Mixed *Sarcocystis* species infections are the rule rather than exception. Therefore, isolation of monospecies-specific DNA from naturally infected cattle is difficult. Unfortunately, DNA was not collected from the two calves experimentally infected with *S. hominis* sarcocysts (Dubey et al. 1988). Whether there are more than one zoonotic *Sarcocystis* species in cattle is unknown.

In this study, we have described the structures of the fourth *Sarcocystis* species in cattle, including its wall and bradyzoites and compared it with *S. hominis* sarcocysts from cattle experimentally infected sporocysts isolated from a human. The most distinguishing feature of *S. hominis* is the thick granular substance layer, and absence of vesicles at the base of the Vp. In summary, *S. rommeli* has a thin ground substance (<1  $\mu\text{m}$  thick), villar protrusions

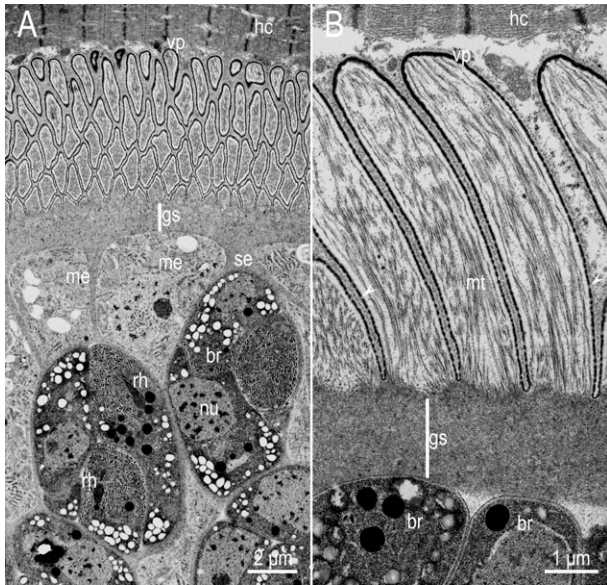


**Figure 3** TEM of *Sarcocystis rommeli* n. sp. bradyzoites. **A, B.** Longitudinal sections of bradyzoites (arrows at opposing ends). Note convoluted mitochondrion (mc). Cyst #8. **C.** Anterior end with a conoid (co), 2 rhoptries (rh1, rh2), numerous micronemes (mn), amylopectin granules (am), and dense granules (dg). Cyst #8. **D.** Conoidal end with subpellicular tubules (st) arising from the conoidal ring (cr). Cyst #4. **E.** Section through the micropore (mp). The pore is surrounded by micropore ring (mr). Also note dense granulated area (double arrows) below mp, and numerous micronemes (mn).

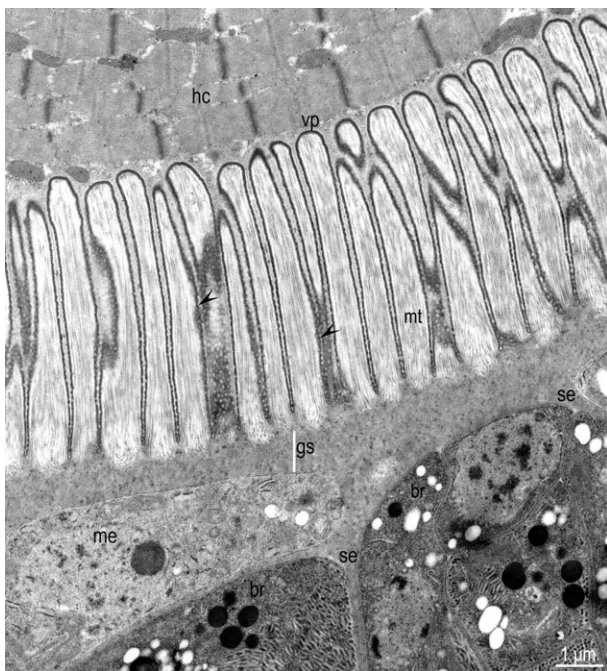
sions 4–5 µm long, wavy, bent at an angle with vesicles at the base. A similar feature was described for the “*S. sinensis*” sarcocysts reaching the conclusion that was a

separate species and morphologically distinguishable from *S. hominis* (Chen et al. 2011; Moré et al. 2013). Of the 384 cattle in Italy, Domenis et al. (2011) detected *S. cruzi*

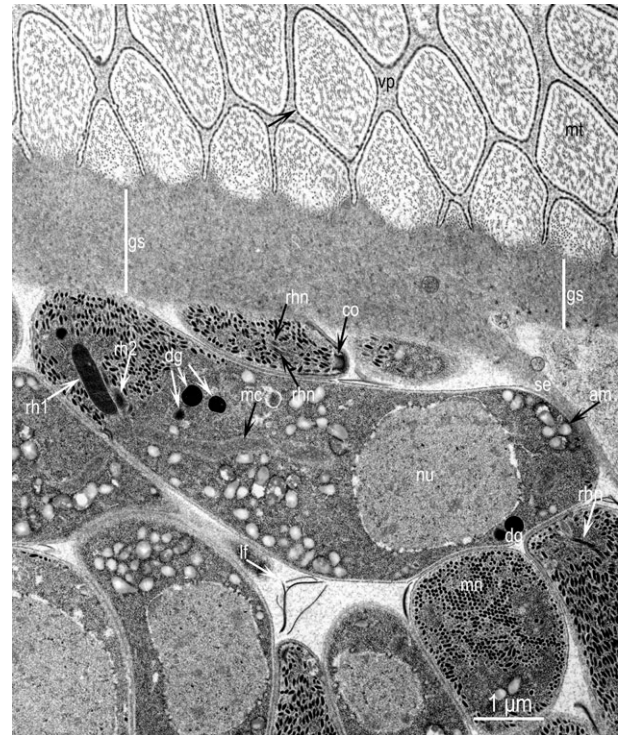



**Figure 4** TEM of *Sarcocystis hominis* sarcocyst in tongue of two calves after oral inoculation with sporocysts from the feces of a human volunteer who ate raw beef. Note elongated villar protrusions (vp) with thin microtubules (mt), ground substance layer (gs) without mt, metrocytes (me), bradyzoites (br) and the host cell (hc). The parasitophorous vacuolar membrane is lined by electron dense layer that is thinned out at places (arrowheads). The ground substance layer (gs) is thicker at the point of origination of septa (se). **A.** 111 d p.i. **B.** 222 d p.i. The vp are of the same length in both sarcocysts but thinner at day 111 p.i.



**Figure 5** Higher magnification of the sarcocyst in Fig. 4A 111 d.p.i. Note upright vp, a metrocyte (me), and several bradyzoites (br). The parasitophorous vacuolar membrane is lined by electron dense layer that is thinned out at places (arrowheads).



**Figure 6** TEM of *Sarcocystis hominis* sarcocyst in tongue of a calf in Fig. 4B. The villar protrusions (vp) are cut at an angle. The parasitophorous vacuolar membrane in vp is lined by electron dense layer that is thinned out at places (arrow). The microtubules (mt) are filamentous. The ground substance layer (gs) is thicker at the point of origination of septa (se). Also note bradyzoites with a conoid (co), 2 rhoptries (rh), few dense granules (dg), numerous amylopectin granules (am), a nucleus (nu), an elongated mitochondrion (mc), and leaflet-like structures (lf) between bradyzoites.

in 74.2%, *S. hirsuta* in 1.8%, *S. hominis* in 47.2%, and *S. hominis*-like sarcocysts in 18.5%. Sarcocysts from two animals had *S. hominis*-like sarcocysts with unusual features. Hook-like structures were described at the base and the tips of the villi and vesicles were present at the base of the villar protrusions. More information is needed to confirm if this *S. hominis*-like sarcocysts correspond to *S. rommeli* or to other species.

The *Sarcocystis* described here is molecularly different than *S. cruzi*, *S. hirsuta*, and *S. hominis* based on *18S rRNA* and *cox1* (mitochondrial cytochrome *c* oxidase subunit I) gene sequences (Gjerde 2013; Moré et al. 2013). Moreover, the sequences obtained in this study revealed the highest homology with the sequence KF954730 previously reported as "*S. sinensis*" from beef sample from Austria (Moré et al. 2014). Previous studies, which amplified and sequenced the *18S rRNA* gene full length sequence of *Sarcocystis* spp. affecting cattle, detected at least 3–5% of sequence differences between the formerly named *S. sinensis* and others (Gjerde 2013; Moré et al. 2013, 2014). All the sequences which correspond to *S. rommeli* from cattle were registered at GenBank as *S. sinensis*, including sequences for the *18S rRNA* gene (ac-

cession numbers KC209742–KC209744, KF954728–KF954730, JX679466, and JX679469) and the *cox 1* gene (accession numbers KC209690–KC209695) (Gjerde 2013; Moré et al. 2013, 2014). Therefore, to avoid confusions, a revision of the additional information including the species names provided with sequences obtained from *Sarcocystis* spp. in cattle is required. Phylogenetical analysis of the *18S rRNA* gene and *cox 1* sequences revealed a closer relation between “*S. sinensis*” and *S. hominis* (Gjerde 2013; Rosenthal et al. 2008). However, in the present study, attempts to infect two human volunteers and one red fox (*V. vulpes*) were unsuccessful. This indicates that neither humans nor red fox are likely definitive hosts of *S. rommeli*. A study conducted in China claimed that “*S. sinensis*” from water buffalo did not use humans as definitive hosts but could represent a cause of foodborne illness (Chen et al. 2011). Here, we showed that using purified viable cysts of *S. rommeli* no symptoms were recorded. Future studies on *Sarcocystis* spp. infections should use purified cysts to avoid misinterpretations of symptoms caused by other potential pathogens not evaluated in the used tissues. In addition, PCR and sequencing of *Sarcocystis* spp. *18S rRNA* gene fragments conducted from mucosal scrapings of red foxes (*V. vulpes*), raccoon dogs (*Nyctereutes procyonoides*) and dogs (*Canis familiaris*) lead to identification of several *Sarcocystis* spp. using these animals as definitive hosts but no *S. rommeli* (G. Moré et al.–unpubl. observations). The definitive host is still unknown and further studies are required to identify potential definitive hosts, especially considering the high prevalence rates detected for *S. rommeli* (published as “*S. sinensis*”) in cattle from Argentina and beef samples in Germany (Moré et al. 2013, 2014).

## ACKNOWLEDGMENTS

R. Calero-Bernal is a postdoctoral fellow (ref. PO12010) funded by the Department of Employment and Innovation of the Regional Government of Extremadura (Spain) and the European Social Fund.

## LITERATURE CITED

- Chen, X., Zuo, Y., Rosenthal, B. M., He, Y., Cui, L. & Yang, Z. 2011. *Sarcocystis sinensis* is an ultrastructurally distinct parasite of water buffalo that can cause foodborne illness but cannot complete its life-cycle in human beings. *Vet. Parasitol.*, 178:35–39.
- Domenis, L., Peletto, S., Sacchi, L., Clementi, E., Genchi, M., Felisari, L., Felisari, C., Mo, P., Modesto, P., Zuccon, F., Campanella, C., Maurella, C., Guidetti, C. & Acutis, P. L. 2011. Detection of a morphogenetically novel *Sarcocystis hominis*-like in the context of a prevalence study in semi-intensively bred cattle in Italy. *Parasitol. Res.*, 109:1677–1687.
- Dubey, J. P., Calero-Bernal, R., Rosenthal, B. M., Speer, C. A. & Fayer, R. 2015. *Sarcocystosis of Animals and Humans*. CRC Press, Boca Raton, FL. pp 1–510.
- Dubey, J. P., Fayer, R., Rosenthal, B. M., Calero-Bernal, R. & Uggla, A. 2014. Identity of *Sarcocystis* species of the water buffalo (*Bubalus bubalis*) and cattle (*Bos taurus*) and the suppression of *Sarcocystis sinensis* as a nomen nudum. *Vet. Parasitol.*, 205:1–6.
- Dubey, J. P., Fayer, R. & Speer, C. A. 1988. Experimental *Sarcocystis hominis* infection in cattle: lesions and ultrastructure of sarcocysts. *J. Parasitol.*, 74:875–879.
- Dubey, J. P., Speer, C. A. & Fayer, R. 1989. *Sarcocystosis of Animals and Man*. CRC Press, Boca Raton, FL. p. 1–215.
- Gjerde, B. 2013. Phylogenetic relationships among *Sarcocystis* species in cervids, cattle and sheep inferred from the mitochondrial cytochrome c oxidase subunit I gene. *Int. J. Parasitol.*, 43:579–591.
- Heydorn, A. O., Gestrich, R., Mehlhorn, H. & Rommel, M. 1975. Proposal for a new nomenclature of the Sarcosporidia. *Z. Parasitenkd.*, 48:73–82.
- Heydorn, A. O. & Rommel, M. 1972. Beiträge zum Lebenszyklus der Sarkosporidien. II. Hund und Katze als Überträger der Sarkosporidien des Rindes. *Berl. Münch. Tierärztl. Wochenschr.*, 85:121–123.
- Moré, G., Pantchev, A., Skuballa, J., Langenmayer, M. C., Maksimov, P., Conraths, F. J., Venturini, M. C. & Schares, G. 2014. *Sarcocystis sinensis* is the most prevalent thick-walled *Sarcocystis* in beef for consumers in Germany. *Parasitol. Res.*, 113:2223–2230.
- Moré, G., Schares, S., Maksimov, A., Conraths, F. J., Venturini, M. C. & Schares, G. 2013. Development of a multiplex real time PCR to differentiate *Sarcocystis* spp. affecting cattle. *Vet. Parasitol.*, 197:85–94.
- Rosenthal, B. M., Dunams, D. B. & Pritt, B. 2008. Restricted genetic diversity in the ubiquitous cattle parasite, *Sarcocystis cruzi*. *Infect. Genet. Evol.*, 8:588–592.
- Zuo, Y. X., Chen, X. W., Li, Y. J., Ma, T. C., Tang, D. H., Fan, L. X. & Zhao, M. L. 1995. *Studies on Sarcocystis Species of Cattle and Water Buffalo with Description of a New Species of Sarcocystis*. Chinese Science and Technology Press, Beijing. p. 20–24.
- Zuo, Y. X. & Yang, Z. Q. 2015. The validity of *Sarcocystis sinensis*. *Zoolog. Res.*, 36:109–111.
- Zuo, Y. X., Zhang, Y. H. & Yie, B. 1990. A new *Sarcocystis* species from water buffalo. *Sarcocystis sinensis* sp. nov. (Abstracts) In: Fifth Symposium of the Chinese Society of Protozoology, October 1990, Chinese Protozoological Society, Chongqing, China. p. 82–83 (in Chinese).