

## DRUG-INDUCED LIVER INJURY

**Cyproterone acetate induces a wide spectrum of acute liver damage including corticosteroid-responsive hepatitis: report of 22 cases**

Fernando Bessone<sup>1</sup>, Lucena MI<sup>2,3</sup>, Marcelo G. Roma<sup>4</sup>, Camilla Stephens<sup>2,3</sup>, Inmaculada Medina-Cáliz<sup>2,3</sup>, Bernardo Frider<sup>5</sup>, Guillermo Tsariktsian<sup>5</sup>, Nelia Hernández<sup>6</sup>, Miquel Bruguera<sup>7</sup>, Gisela Gualano<sup>8</sup>, Eduardo Fassio<sup>8</sup>, Joaquín Montero<sup>1</sup>, María V Reggiardo<sup>1</sup>, Sebastián Ferretti<sup>1</sup>, Luis Colombato<sup>9</sup>, Federico Tanno<sup>1</sup>, Jaime Ferrer<sup>1</sup>, Lelio Zeno<sup>10</sup>, Hugo Tanno<sup>1</sup> and Raúl J. Andrade<sup>2,3</sup>

1 Servicio de Gastroenterología y Hepatología, Facultad de Ciencias Médicas, Universidad Nacional de Rosario, Rosario, Argentina

2 Unidad de Hepatología y Servicio de Farmacología Clínica, Instituto de Investigación Biomédica de Málaga-IBIMA, Hospital Universitario Virgen de la Victoria, Universidad de Málaga, Málaga, Spain

3 Centro de Investigación Biomédica en Red de Enfermedades Hepáticas y Digestivas (CIBERehd), Madrid, Spain

4 Instituto de Fisiología Experimental (IFISE-CONICET), Facultad de Ciencias Bioquímicas y Farmacéuticas, Universidad Nacional de Rosario, Rosario, Argentina

5 Hospital Cosme Argerich, Buenos Aires, Argentina

6 Clínica de Gastroenterología, Hospital de Clínicas y Facultad de Medicina, Universidad de la República (UdelaR), Montevideo, Uruguay

7 Liver Unit, Hospital Clinic, Barcelona, Spain

8 Hospital Alejandro Posadas, Buenos Aires, Argentina

9 Hospital Británico, Buenos Aires, Argentina

10 Servicio de Urología, Facultad de Ciencias Médicas, Universidad Nacional de Rosario, Rosario, Argentina

Liver Int. 2016; 36: 302–310. DOI: 10.1111/liv.12899

**Abstract**

**Background & Aims:** Cyproterone acetate (CPA), an anti-androgenic drug for prostate cancer, has been associated with drug-induced liver injury (DILI). We aim to expand the knowledge on the spectrum of phenotypes and outcomes of CPA-induced DILI. **Methods:** Twenty-two males (70 ± 8 years; range 54–83) developing liver damage as a result of CPA therapy (dose: 150 ± 50 mg/day; range 50–200) were included. Severity index and causality by RUCAM were assessed. **Results:** From 1993 to 2013, 22 patients were retrieved. Latency was 163 ± 97 days. Most patients were symptomatic, showing hepatocellular injury (91%) and jaundice. Liver tests at onset were: ALT 18 ± 13 × ULN, ALP 0.7 ± 0.7 × ULN and total serum bilirubin 14 ± 10 mg/dl. International normalized ratio values higher than 1.5 were observed in 14 (66%) patients. Severity was mild in 1 case (4%), moderate in 7 (32%), severe in 11 (50%) and fatal in 3 (14%). Five patients developed ascites, and four encephalopathy. One patient had a liver injury that resembled autoimmune hepatitis. Eleven (50%) were hospitalized. Nineteen patients recovered after CPA withdrawal, although three required steroid therapy (two of them had high ANA titres). Liver biopsy was performed in seven patients (two hepatocellular collapse, one submassive necrosis, two cholestatic hepatitis, one cirrhosis with iron overload and one autoimmune hepatitis). RUCAM category was 'highly probable' in 19 (86%), 'probable' in 1 (4%), and 'possible' in 2 (9%). **Conclusions:** CPA-induced liver injury is severe and can be fatal, and may occasionally resemble autoimmune DILI. The benefit/risk ratio of this drug should be thoroughly assessed in each patient.

**Abbreviations**

ALH, autoimmune hepatitis; ALF, acute liver failure; ALP, serum alkaline phosphatase; ALT, alanine aminotransferase; AMA, antimicrobial antibodies; ANA, antinuclear antibodies; ASMA, antismooth muscle antibodies; AST, aspartate aminotransferase; CPA, cyproterone acetate; DILI, drug-induced liver injury; IgG, immunoglobulin G; INR, international normalized ratio; LKM-1anti, liver kidney microsomal antibodies; RUCAM, Roussel-Uclaf causality assessment method; TBL, total serum bilirubin; TGF-β1, transforming growth factor-β1; ULN, upper limit of normal.

**Correspondence**

Dr Fernando Bessone, Servicio de Gastroenterología y Hepatología, Facultad de Ciencias Médicas, Universidad Nacional de Rosario, 2000 Rosario, Argentina

Tel: +54341 4393511; Fax: +54341 4387014

e-mail: bessonefernando@gmail.com

Handling Editor: Mario Mondelli

Received 29 April 2015; Accepted 13 June 2015

Additional Supporting Information may be found at [onlinelibrary.wiley.com/doi/10.1111/liv.12899/supinfo](http://onlinelibrary.wiley.com/doi/10.1111/liv.12899/supinfo)

**Keywords**

acute liver failure – autoimmune hepatitis – cyproterone acetate – drug-induced liver injury – hepatitis

Cyproterone acetate (CPA) is an anti-androgenic drug commonly used for the treatment of advanced prostate cancer (1, 2). Unlike non-steroidal prostate cancer treatments, such as flutamide and bicalutamide, CPA is classified as a steroidal compound. CPA has also been employed in the treatment of breast cancer, acne, hirsutism, precocious puberty, priapism and hypersexual disorder (3–8). Because of its weak progestogen activity, CPA is also used to treat hot flushes, and is one component of several combined oral contraceptive pills marketed in the UK, Canada, Germany, Spain and South America.

Cyproterone acetate is known to inhibit the peripheral actions of testosterone and to suppress gonadotrophin secretion by maintaining negative feedback on the pituitary (9, 10), although the exact mechanism of action has not been fully established as yet.

Cyproterone acetate was introduced in Europe by Neumann and Hamada in 1964 (11), and it is currently marketed in 116 countries worldwide, not including USA. CPA is considered to be a low-degree inducer of liver-related adverse reactions. The small number of reports related to this drug described in the literature does not allow us to draw firm conclusions about the frequency of CPA hepatotoxicity. However, previous studies have demonstrated a strong association between hepatitis and flutamide, while bicalutamide and cyproterone acetate appear to have a weaker association with hepatotoxicity (12). Nevertheless, medicinal products containing the CPA/ethinylestradiol combination, were withdrawn in 2013 by the French Sanitary Agency (13), based on the results reported by Lidegaard *et al.* (14), showing a four-fold higher risk of developing venous thromboembolism in women treated with these compounds, as compared to untreated patients.

**Key points box**

- Cyproterone acetate is an anti-androgenic drug for advanced prostate cancer that has been associated with drug-induced liver injury (DILI).
- We describe here the phenotype and outcome of 22 patients with CPA-induced hepatotoxicity, the largest series of CPA hepatotoxicity cases reported to date.
- We observed a wide spectrum of acute liver injury associated with CPA therapeutic intake. It comprises three cases of corticosteroid-responsive hepatitis, including a first-reported, well-documented case of associated autoimmune hepatitis.
- Our results prompt physicians to assess the benefit/risk ratio of this drug in each patient.

As the first case of CPA-induced fulminant hepatitis was described in 1989 (15), to our knowledge, 25 cases have been reported to date, either as case reports or small series (16–32).

This study aims to describe the spectrum of phenotypes and outcomes of CPA-induced DILI, including, among others, features resembling immune-mediated disorders.

**Patients and methods**

Twenty-two cases of acute liver injury associated with the use of CPA were retrieved from the Spanish–Latin American Drug-Induced Liver Injury (DILI) Network (19 cases) and the Spanish DILI Registry (three cases) databases. The Latin American cases originated from Argentina (17 cases) and Uruguay (two cases). The study protocol was approved by the Local Ethics Committee of the coordinating centre at the ‘Virgen de la Victoria’ University Hospital (Malaga, Spain), the Ethics Committee at the ‘Centenario’ University Hospital (Rosario, Argentina) and the Ethics Committee at the Faculty of Medicine of the University of the Republic (Montevideo, Uruguay). A written informed consent was systematically obtained.

All these patients had advanced prostate cancer. Clinical and laboratory data were carefully documented in all cases. Liver biopsy findings were reviewed in patients 3, 5, 6, 14, 16, 21 and 22. The diagnosis of acute hepatitis was established on the basis of a detailed drug history, physical examination on admission, laboratory tests and histological findings. Underlying liver or biliary tract disease, drug addiction, alcohol abuse, blood transfusions or surgery within 6 months prior to the onset of hepatitis were investigated and ruled out in all patients.

A comprehensive examination of present and previous use of drugs, herbal remedies and over-the-counter medication was done by questioning both patients and relatives. Duration of therapy with CPA, time to onset of symptoms and clinical features of DILI were also investigated. Finally, the clinical and laboratory course of the disease following drug withdrawal was recorded. Serological markers of viral hepatitis were tested in all patients, including IgM antibody to hepatitis A virus, hepatitis B surface antigen, IgM anti-HBc, antihepatitis C virus, IgM anticytomegalovirus and IgM anti-Epstein–Barr virus. Screening for autoimmune liver disorders (antinuclear [ANA], antimitochondrial [AMA], antismooth muscle [ASMA] and antiliver kidney microsomal [LKM-1]) was systematically performed. Simplified diagnostic criteria for autoimmune hepatitis (AIH) were used in three patients with suspected immunological liver injury (patients 3, 15 and 16) (33). At least one

abdominal ultrasound or computed tomography scan was performed in all patients, in order to rule out evidences of chronic liver or biliary tract disease, and space-occupying lesions. The pattern of liver injury was calculated according to the criteria of the International Consensus Meeting for drug-induced liver injury (34). The DILI Severity Index was employed to classify DILI cases as mild, moderate, severe or fatal/transplantation (34). The Roussel-Uclaf Causality Assessment Method (RUCAM) was used to evaluate causality in all patients (35). Data were expressed as mean  $\pm$  SD.

## Results

Demographic characteristics, and clinical and laboratory parameters in 22 patients with CPA-induced liver injury are summarized in Tables 1 and 2 (for each patient) and in Table 3 (as mean values with ranges). The mean age was  $70 \pm 8$  (range: 54–83) years. None of the patients had a BMI  $> 32$  kg/m<sup>2</sup>, or showed evidence of metabolic syndrome; similarly, no malnutrition was apparent. There were no significant co-morbidities, except for patient 15, who consumed approximately 60 g of alcohol/day, and patient 22, in whom cirrhosis likely induced by a concomitant iron overload was detected on liver biopsy. Only a few associated medications were known to have significant hepatotoxic potential, but all of them were prescribed several months to 5 years before hepatitis symptom onset. The CPA dose was  $150 \pm 50$  mg/day (range 50–200). Eleven (50%) of the patients were treated with a daily dose of 200 mg of CPA (300 mg/day is the manufacturer's maximum recommended dose). There was no correlation between the daily dose and severity of liver injury (data not shown). Mean time from initial CPA initial intake to onset of symptoms was  $168 \pm 97$  (range: 33–425) days. All patients except one (case 22) developed jaundice. The most frequent clinical symptoms were asthenia (77%), upper abdominal pain (36%) and pruritus (14%).

Serum alanine aminotransferase (ALT) and aspartate aminotransferase (AST) activities were increased in all patients, ranging from 6 to 59 times the upper limit of normal (ULN). Total serum bilirubin (TBL) was also increased in all patients, ranging from 1.7 to 40 mg/dl. International normalized ratio (INR) was assessed in 21 of the 22 patients. The INR values higher than 1.5 were observed in 14 (66%) patients. Serum alkaline phosphatase (ALP) activity was only increased in three cases.

In twenty patients (91%), the type of liver injury was hepatocellular, and only two patients developed a cholestatic hepatitis. In addition, 11 (50%) and 3 (14%) of the 22 patients had severe and fatal liver damage, respectively, according to the DILI severity index. Only one (4%) and seven (32%) cases were defined as 'mild' or 'moderate' respectively. Eleven patients (50%) were hospitalized. Five of them developed ascites (patients 6, 15, 16, 17 and 18), which was associated with hepatic encephalopathy in four of

them (6, 16, 17 and 18). Non-tumoral, heterogeneous echotexture of liver parenchyma was demonstrated by liver ultrasound in four patients (6, 16, 17 and 18). The liver-related deaths (patients 6, 17 and 18) were adjudicated to sepsis, multi-organ failure and hepatorenal syndrome respectively.

Three patients recovered after a dramatic clinical improvement after corticosteroid therapy (patients 3, 15 and 16) (see Data S1 in 'Supporting Information' for clinical histories). The liver biochemical profiles of these three patients are depicted in Fig. 1. Sustained high levels of transaminases beyond 1–2 months after CPA withdrawal in these patients led us to suspect an

**Table 1.** Demographic and clinical characteristics of 22 male patients with cyproterone acetate-induced idiosyncratic liver injury

Case	Age (years)	Time to onset (days)	Total daily dose (mg)	Associated medications	Hospital admission
1	80	122	150	Leuprolide	No
2	73	63	200	Leuprolide	Yes
3	54	123	200	Leuprolide	No
4	60	33	200	Leuprolide Enalapril	No
5	74	154	200	Leuprolide Colchicine	No
6	66	96	150	Leuprolide Ibuprofen	Yes
7	77	246	100	Leuprolide Simvastatin	No
8	72	151	200	Atorvastatin Colchicine	Yes
9	80	119	200	Allopurinol Enalapril	Yes
10	69	125	100	Leuprolide	No
11	58	308	200	Enalapril Glibenclamide	No
12	83	64	100	Leuprolide Diazepam	No
13	75	149	200	Leuprolide Alprazolam	No
14	72	242	100	Losartan	No
15	72	180	50	Diltiazem Atorvastatin Allopurinol	Yes
16	66	425	100	Leuprolide Omeprazol	Yes
17	58	153	200	Ranitidine Atorvastatin	Yes
18	75	240	200	Omeprazol	Yes
19	74	301	150	Ramipril Iron therapy	Yes
20	64	100	100	Diltiazem Acetylsalicylic acid Testosterone Glibenclamide Glutamic acid	Yes
21	64	150	150	Leuprolide	Yes
22	64	150	150	Goserelin acetate	No

**Table 2.** Laboratory, histopathological findings and outcome of 22 patients with cyproterone acetate-induced idiosyncratic liver injury

Case	TBL (mg/dl)	ALT (IU/L)	AST (IU/L)	ALP (IU/L)	PT (%) / INR	Biopsy findings	DILI severity index	Pattern of liver injury	Outcome
1	15.3	271	578	92	44/1.88		Severe	Hepatocellular	Resolution 115 days
2	20	741	505	116	53/1.59		Severe	Hepatocellular	Resolution 122 days
3	8.9	570	386	91	82/1.12	Piecemeal necrosis, periportal rosettes, mild lobular necrosis	Moderate	Hepatocellular	ANA 1/160 AMA 1/80 AIH Corticosteroids responsive hepatitis
4	11.5	641	296	154	44/1.88		Severe	Hepatocellular	Resolution 95 days
5	11	660	630	128	44/1.88	Severe lobular necrosis, collapsed areas	Severe	Hepatocellular	Resolution 61 days
6	32	550	320	184	29/2.74	Submassive necrosis	Fatal	Hepatocellular	Death SIRS
7	5.7	377	338	92	69/1.31		Moderate	Hepatocellular	Resolution 92 days
8	7.2	319	557	775	39/2.20		Severe	Mixed	Resolution 63 days
9	20.2	490	630	62	44/1.88		Severe	Hepatocellular	Resolution 75 days
10	26	776	540	67	82/1.12		Moderate	Hepatocellular	Resolution 64 days
11	8	233	171	60	97/1.02		Moderate	Hepatocellular	Resolution 54 days
12	16	302	110	62	82/1.12		Moderate	Hepatocellular	Resolution 46 days
13	6	402	283	72	82/1.12		Moderate	Hepatocellular	Resolution 44 days
14	6.1	1086	999	87	53/1.59	Severe panlobular necrosis with hepatocyte collapse	Severe	Hepatocellular	Resolution 88 days
15	8.9	682	838	90	29/2.74		Severe	Hepatocellular	Steroid- responsive hepatitis
16	40	2400	1870	267	29/2.74	Severe acute hepatitis with cholestasis	Severe	Hepatocellular	Steroid- responsive hepatitis
17	26	1336	1036	292	44/1.88		Fatal	Hepatocellular	Death/ sepsis
18	17	1070	848	223	33/2.56		Fatal	Hepatocellular	Death, HRS
19	11.8	604	991	484	46/1.69		Severe	Hepatocellular	Resolution 59 days
20	3.6	1947	1282	262	88/1.09		Moderate	Hepatocellular	Resolution 58 days
21	15.6	373	74	70	36/2.39	Hepatitis with cholestasis	Severe	Hepatocellular	Resolution 66 days
22	1.7	509	638	663	–	Liver cirrhosis	Mild	Mixed	ANA 1/640 AMA 1/640 Resolution 299 days

Laboratory data were obtained at the peak level of the hepatotoxicity.

TBL, total bilirubin (ULN: 1.2 mg/dl); ALT, alanine aminotransferase (ULN: 41 IU/L); AST, aspartate aminotransferase (ULN: 38 IU/L); ALP, alkaline phosphatase (ULN: 270 IU/L); PT, prothrombin time (normal: 70–100%); INR, international normalized ratio (abnormal: > 1.5); ANA, antinuclear antibodies; ASMA, smooth muscle antibodies; HRS, Hepatorenal Syndrome; SIRS, Systemic Inflammatory Response Syndrome.

**Table 3.** Demographic characteristics, clinical and laboratory parameters in 22 patients with cyproterone acetate-induced idiosyncratic liver injury (mean; range)

Age, mean years (range)	70 (54–83)
Time to onset, mean days (range)	168 (33–425)
Total daily dose, mean mg (range)	150 (50–200)
Hospital admission, <i>n</i> (%)	11 (50)
Severity, <i>n</i> (%)	
Mild	1 (4)
Moderate	4 (32)
Severe	11 (50)
Fatal	3 (14)
Laboratory parameters ( $\times$ ULN), mean (range)	
TBL	14 (1.7–40)
ALT	18 (5.7–58.5)
AST	17 (1.9–49.2)
ALP	0.7 (0.2–2.9)
INR ( <i>n</i> = 21)	1.8 (1.02–2.74)
RUCAM scale, <i>n</i> (%)	
Highly probable	19 (86)
Probable	1 (4)
Possible	2 (9)
Outcome	
Time to resolution, mean days (range)*	88 (44–299)
Resolution data, <i>n</i> (%)†	16 (73)

ULN, upper limit normal; TBL, total bilirubin; ALT, alanine aminotransferase; AST, aspartate aminotransferase; ALP, alkaline phosphatase; INR, international normalized ratio (abnormal: >1.5).

Severity criteria: Mild: ALT  $\geq 5 \times$  ULN or ALP  $\geq 2 \times$  ULN, and TBL  $< 2 \times$  ULN; Moderate: ALT  $\geq 5 \times$  ULN or ALP  $\geq 2 \times$  ULN, and TBL  $\geq 2 \times$  ULN; Severe: ALT  $\geq 5 \times$  ULN or ALP  $\geq 2 \times$  ULN, and TBL  $\geq 2 \times$  ULN and one of the following: (i) international normalized ratio  $\geq 1.5$ , (ii) ascites and/or encephalopathy, disease duration  $< 26$  weeks and absence of underlying cirrhosis, (iii) other organ failure considered to be because of DILI; Fatal: death or transplantation.

\*Mean values were calculated based on the total number of episodes available information. Resolution: complete normalisation of the analytical liver profile.

†16/22 patients, normalized liver enzyme values spontaneously after CPA withdrawal. Three patients died and three were considered to have steroid-responsive hepatitis.

immunological mechanism of liver toxicity, which prompted us to prescribe corticosteroid therapy. In patient 3, prednisone was administered after a sustained increase in serum transaminase values, resulting in biochemical normalization; while the patient was receiving a maintenance dose of prednisone, an inadvertent rechallenge of CPA occurred, resulting in a rapid increase in transaminase values, which normalized again with prednisone administration. Patients 15 and 16 received prednisone after ascites appearance, and clinical and biochemical resolution was achieved after around 2 months of treatment.

Out of the 22 patients in this series, 16 obtained normal liver enzyme values spontaneously after CPA withdrawal ( $88 \pm 61$  days, range: 44–299 days), while three patients died, and three were considered to have steroid-responsive toxic hepatitis (Tables 2 and 3).

Interestingly, TBL normalization was achieved in three cases (patients 11, 12 and 13) in a time period shorter than 55 days, despite one of them having high level of TBL (16 mg/dl) (patient 12). All of these cases had a normal INR value, and transaminase levels  $\leq 402$  UI/L. Furthermore, in one case (patient 22), it took a substantial time for ALT to normalize (299 days).

Except for patients 3 and 22, in whom ANA (1/160–1/640) and ASMA (1/80–1/640) were observed, respectively, none of the patients developed auto-antibodies. Hypergammaglobulinaemia was only detected in patient 16.

Liver histology was obtained from seven (30%) patients. It showed severe liver injury with hepatocellular collapse in two of them (5 and 14), and submassive necrosis in an additional patient who died. Severe acute hepatitis with cholestasis was documented in only two patients (16 and 21). Histological changes suggested AIH (piecemeal necrosis, lymphoplasmacytic infiltrate and rosettes) in patient 3 (Fig. 2), and cirrhosis associated with iron overload in patient 22.

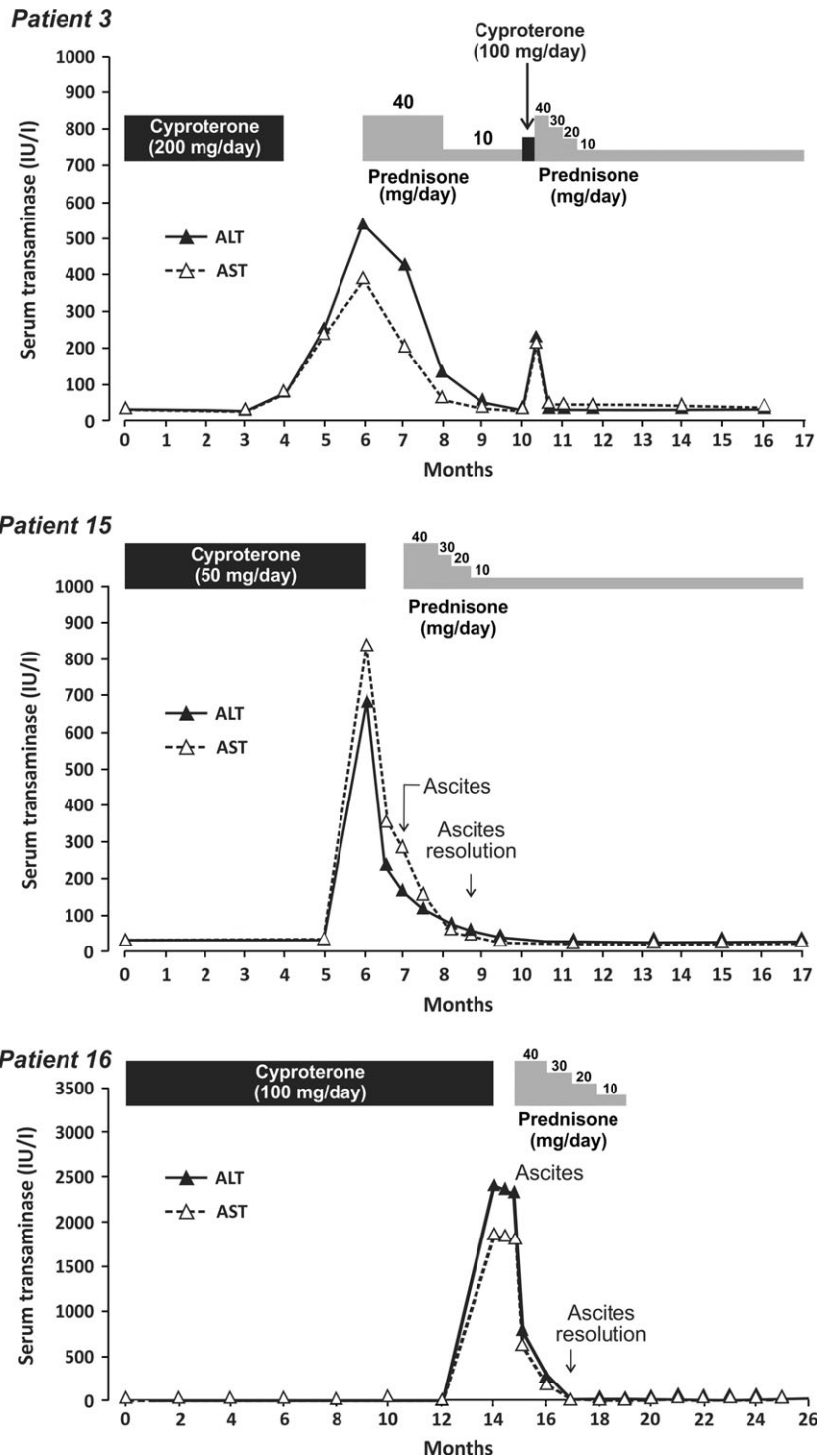
Nineteen of the 22 patients (86%) fell into the ‘highly probable’, one (4%) in the ‘probable’ and two (9%) in the ‘possible’ categories, when causality was assessed by the RUCAM scale. Although three patients were diagnosed as having steroid-responsive toxic hepatitis, only patient 3 qualified as DILI-induced AIH. Neither a longer latency period nor a higher dose of CPA was found in the subgroup of patients with steroid-responsive toxic hepatitis compared to those with spontaneous recovery.

## Discussion

Our series of 22 patients developing acute hepatitis induced by CPA represents the largest case series reported to date. It also includes three patients with CPA-induced corticosteroid-responsive hepatitis. This series is composed exclusively of men receiving CPA for advanced prostate cancer (90% of cases aged over 60 years). Although patients requiring prostate cancer treatment are generally elderly, it has been previously suggested that age itself is a risk factor for CPA hepatotoxicity, based on the lower incidence figures of DILI found in younger patients receiving CPA for acne or hirsutism (3, 36, 37).

In keeping with previous findings in this field (38), onset of hepatic symptoms usually occurred after 100 days from starting the CPA therapy in our case series (70% of patients). In accordance with the results reported by Savidou *et al.* (30) in a review of 14 cases from the literature, all patients fall within a time frame ranging 2–15 months, except for one case in which latency was shorter (33 days). The previous report also showed time frames from withdrawal of the causative agent to liver enzyme normalization of 2–3 months, similar to that seen in our series. Noteworthy, in our series, TBL normalization was achieved in a time period

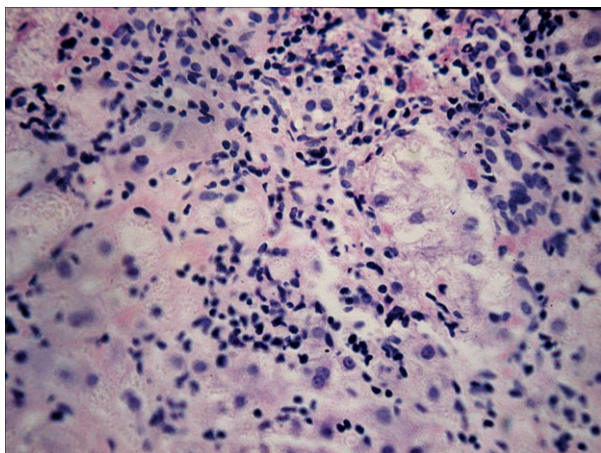




**Fig. 1.** Biochemical response in the three patients (3, 15 and 16) who had corticosteroid-responsive hepatitis induced by CPA (see Data S1 in ‘Supporting Information’ for the clinical history of each patient).

shorter than 55 days in three patients. However, all these cases had a normal INR value, and the transaminase levels at presentation were not higher than 402 IU/L. On the other hand, the delayed time for transaminase

normalization observed in one patient (299 days), might be explained, at least in part, by the fact that the toxic acute liver injury occurred in a cirrhotic rather than in a previously normal liver.



**Fig. 2.** Percutaneous liver biopsy of a 54-year-old man with autoimmune hepatitis induced by CPA (patient 3), showing interface hepatitis associated with portal and lobular lymphoplasmacytic infiltration (see Data S1 in 'Supporting Information' for the clinical history of this patient).

Acute hepatocellular injury associated with jaundice was the predominant phenotype in our case series. Previous reports on CPA-induced liver injury had demonstrated that this condition occurred more commonly in elderly patients (age range: 60–92 years), and that it was linked to prostate cancer therapy with doses ranging from 100 to 300 mg over a prolonged period of time (2–15 months). Most of these patients showed features of severe hepatitis or acute liver failure (ALF) at presentation, with a fatal outcome in 90% of the cases developing ALF (30, 32). In agreement with our results, the time interval from the onset of jaundice to death was 2–8 weeks. Hospitalization was required in 50% of patients, and an abnormal INR was observed in 60% of the cases. Surprisingly, four patients (19%) in our series developed ALF, and three of them died. These data are in accordance with the literature, where only one of the 14 patients with CPA-induced ALF reported so far has survived (32). In addition, no apparent relationship between dose and severity was detected in our study, in keeping with other reports (30, 38). This epidemiological analysis indicates that, despite its low incidence, the prognosis of CPA-induced ALF is mainly fatal.

Interestingly, a heterogeneous echostructure of the liver was observed on ultrasound examination in four of our cases. A non-cirrhotic liver was documented in two of them, through a *postmortem* liver biopsy in one (acute submassive necrosis), and through ultrasound in the remaining patient, which showed a normal liver echostructure after 1 year of follow-up. These findings are in accordance with Romero *et al.* (39), who demonstrated that the majority of patients with ALF had abnormal radiographic findings. Liver surface nodularity correlated with massive hepatic necrosis on histology, and with wrinkled capsule on visual inspection of the explanted liver specimen (39).

Potential hepatotoxic drugs, such as ibuprofen, atorvastatin or allopurinol, were consumed by several patients when starting CPA therapy. However, the latency periods in these cases did not fit with those generally described for the above-mentioned concomitant medications. In addition, 36% of our patients had taken leuprolide acetate, a luteinizing hormone-releasing analogue that is commonly administered concomitantly with CPA therapy. However, to our knowledge, this drug has never been associated with acute toxic hepatitis.

Liver biopsies performed in seven patients contributed to the diagnosis by confirming severe hepatocellular injury, submassive necrosis, cirrhosis associated with iron overload and, in one case, changes suggesting AIH, such as interface hepatitis, plasmacytes, eosinophils and rosettes (see Fig. 2). The coexistence of autoantibodies and iron overload associated with cirrhosis, as seen in patient 22, makes it difficult to ascertain whether CPA was the main cause of the liver disease or whether the acute liver injury induced by CPA occurred on a previous cirrhotic liver. Interestingly, cirrhosis linked to CPA has been previously reported twice in the literature, namely in a child with hypothalamic syndrome and central precocious puberty treated with CPA over 50 months (40) and in an adult CPA-treated patient who developed sub-acute hepatitis followed by a rapid evolution to cirrhosis (31).

To the best of our knowledge, no more than 25 cases of CPA-induced liver injury have been reported in the literature as the first reported case of CPA-induced fulminant hepatic failure in 1989 (15), all of them being single case reports or series with a small number of patients (16–32). Although most of these reports describe severe liver injury induced by CPA, our case series shows a broad spectrum of hepatocellular damage. Five of our patients presented ascites, and four of them had hepatic encephalopathy at presentation, associated with a fatal outcome in three of them. Interestingly, a clinical improvement with disappearance of ascites and liver enzyme normalization after corticosteroid treatment was observed in two of our cases. No liver enzyme elevation relapses were observed in any of these patients after immunosuppressive therapy withdrawal. A similar association had only been reported once in the literature. In this case, CPA-induced sub-acute hepatitis with a rapid evolution to cirrhosis required a course of corticosteroid therapy for liver enzyme normalization (31).

In addition, one of our patients (patient 3) showed both typical histological features of AIH and a clinical outcome without reactivation after corticosteroid withdrawal. The diagnosis of AIH-DILI was reinforced in this case by ALT elevations after an inadvertent challenge with CPA. To our knowledge, this is the first case of AIH induced by CPA monotherapy. Only one poorly documented case of AIH induced by CPA and ethinylestradiol combination therapy had been reported in a 17-year-old girl treated for hirsutism, who failed to achieve ALT normalization during treatment and after

corticosteroid therapy. Liver histology in this patient showed cirrhosis associated with ductular proliferation, without evidence of autoimmune disease (41).

It is always challenging to make differential diagnosis among drug-induced autoimmune liver disease, *de novo* AIH unmasked by a drug, and a flare-up of pre-existing AIH unrelated to drug therapy. From a clinical standpoint, lack of liver enzyme elevation following corticosteroid therapy withdrawal, as in our cases, points to AIH-DILI rather than classical AIH, and should, therefore, be taken into account in the differential diagnosis (42, 43).

The mechanisms of CPA-induced DILI are not clearly understood. Immunological reactions have been hypothesized in anti-androgenic drug-induced hepatotoxicity (44, 45), and here we are providing compelling evidence that this may be the case for CPA. However, lack of evidence of this mechanism in most of our cases suggest that a direct toxic effect of the drug itself or its metabolites may occur as well, as has been shown for the anti-androgenic drug, flutamide (46).

In conclusion, although according to the literature CPA is only occasionally linked to severe liver disease, our results show that the administration of this drug indeed entails a risk of eliciting severe, even fatal liver injury. In addition, we observed the development of a typical AIH pattern in one patient, suggesting CPA-induced immune-mediated mechanism of hepatocellular damage. This was reinforced by an apparent corticosteroid therapy benefit in two other cases of CPA-induced hepatotoxicity, where liver test normalization had not been achieved despite CPA withdrawal. Based on our findings, the benefit/risk ratio of CPA treatments can be unfavourable in certain medical situations and should, therefore, be thoroughly evaluated for each patient prior to treatment initiation.

### Acknowledgements

We thank Lucía Hernández and Fernanda Méndez, from the Faculty of Economy and Statistics, University of Rosario, Rosario, Santa Fe, Argentina, for statistical assistance.

**Financial support:** This study was supported by the research grant P10-CTS-6470, PI12-00620, PI12-00378 and the Agencia Española del Medicamento y Productos Sanitarios (AEMPS). CIBERehd is funded by Instituto de Salud Carlos III.

**Conflict of interest:** The authors do not have any disclosures to report.

### References

- Baltogiannis D, Giannakopoulos X, Charalabopoulos K, *et al.* Monotherapy in advanced prostate cancer: an overview. *Exp Oncol* 2004; **26**: 185–91.
- Anderson J. The role of antiandrogen monotherapy in the treatment of prostate cancer. *BJU Int* 2003; **91**: 455–61.
- Carmina E. A risk-benefit assessment of pharmacological therapies for hirsutism. *Drug Saf* 2001; **24**: 267–76.
- Lopez M, Natali M, Di Lauro L, *et al.* Combined treatment with buserelin and cyproterone acetate in metastatic male breast cancer. *Cancer* 1993; **72**: 502–5.
- Wiegatz I, Kuhl H. Managing cutaneous manifestations of hyperandrogenic disorders: the role of oral contraceptives. *Treat Endocrinol* 2002; **1**: 372–86.
- Laron Z, Kauli R. Experience with cyproterone acetate in the treatment of precocious puberty. *J Pediatr Endocrinol Metab* 2000; **13**(Suppl 1): 805–10.
- Munee A, Minhas S, Arya M, Ralph DJ. Stuttering priapism – a review of the therapeutic options. *Int J Clin Pract* 2008; **62**: 1265–70.
- Assumpção AA, Garcia FD, Garcia HD, Bradford JM, Thibaut F. Pharmacologic treatment of paraphilias. *Psychiatr Clin North Am* 2014; **37**: 173–81.
- Schroder FH. Cyproterone acetate – mechanism of action and clinical effectiveness in prostate cancer treatment. *Cancer* 1993; **72**: 3810–5.
- Barradell LB, Faulds D. Cyproterone. A review of its pharmacology and therapeutic efficacy in prostate cancer. *Drugs Aging* 1994; **5**: 59–80.
- Neumann F, Hamada H. Intrauterine Feminisierung männlicher Rattenfeten durch das stark gestagen wirksame 6-chlor- $\Delta^6$ -1,2-methylen-17  $\alpha$ -hydroxyprogesteronacetat. Schilddrüsenhormone und Körperperipherie/Regulation der Schilddrüsenfunktion Symposium der Deutschen Gesellschaft für Endokrinologie Volume 10, 1964, Springer Berlin Heidelberg, pp 301–4.
- Manso G, Thole Z, Salgueiro E, Revuelta P, Hidalgo A. Spontaneous reporting of hepatotoxicity associated with antiandrogens: data from the Spanish pharmacovigilance system. *Pharmacoevidenciol Drug Saf* 2006; **15**: 253–9.
- Chabbert-Buffet N, Amy JJ. The combination ethinylestradiol/cyproterone acetate is temporarily withdrawn from the market in France. Is the measure justified? *Eur J Contracept Reprod Health Care* 2013; **18**: 75–8.
- Lidegaard Ø, Nielsen LH, Skovlund CW, Skjeldestad FE, Løkkegaard E. Risk of venous thromboembolism from use of oral contraceptives containing different progestogens and oestrogen doses: Danish cohort study, 2001–9. *BMJ* 2011; **343**: d6423.
- Levesque H, Trivalle C, Manchon ND, *et al.* Fulminant hepatitis due to cyproterone acetate. *Lancet* 1989; **1**: 215–6.
- Blake JC, Sawyerr AM, Dooley J, Scheuer PJ, McIntyre N. Severe hepatitis caused by cyproterone acetate. *Gut* 1990; **31**: 556–7.
- Drakos PE, Gez E, Catane R. Hepatitis due to cyproterone acetate. *Eur J Cancer* 1992; **28**: 1931–2.
- Roila F, Crino L, Carloni G, Natalini G. Cyproterone acetate: hepatotoxicity and prostatic cancer treatment. *Ann Oncol* 1993; **4**: 701.
- Murphy BJ, Collins BJ. Severe hepatitis and liver failure induced by cyproterone acetate. *Aust N Z J Med* 1996; **26**: 724.
- Bessone F, Passamonti ME, Ferrer J, *et al.* Severe hepatocellular damage-induced by cyproterone. *Hepatology* 1998; **28**(Suppl): 1895A.
- Meijers WH, Willemsse PH, Sleijfer DT, Mulder NH, Grond J. Hepatocellular damage by cyproterone acetate. *Eur J Cancer Clin Oncol* 1986; **22**: 1121–2.
- Parys BT, Hamid S, Thomson RG. Severe hepatocellular dysfunction following cyproterone acetate therapy. *Br J Urol* 1991; **67**: 312–3.



23. Castellani P, Bernardini D, Renou C, *et al.* Fatal sub-fulminant hepatitis caused by cyproterone acetate. A new case. *Gastroenterol Clin Biol* 1996; **20**: 915–6.
24. Friedman G, Lamoureux E, Sherker AH. Fatal fulminant hepatic failure due to cyproterone acetate. *Dig Dis Sci* 1999; **44**: 1362–3.
25. Hirsch D, Kovatz S, Bernheim J, Shenkman L. Fatal fulminant hepatitis from cyproterone acetate. *Isr J Med Sci* 1994; **30**: 238–40.
26. Lombardi A, Ferrazza P, Castaldi F, *et al.* Acute hepatic necrosis in a patient treated with cyproterone acetate. *G Chir* 1998; **19**: 161–3.
27. Bressollette L, Dubois A, Carlhant D, *et al.* Fatal hepatitis caused by cyproterone acetate. *Therapie* 1994; **49**: 153.
28. Antoni M, Bourliere M, Toullec J, *et al.* Fatal subfulminant hepatitis caused by cyproterone acetate. *Gastroenterol Clin Biol* 1991; **15**: 772–3.
29. Vodička M, Sálek T, Röderová E, Cerný D. Hepatotoxicity induced by cyproterone acetate in the prostate carcinoma treatment – a case report. *Klin Onkol* 2013; **26**: 47–8.
30. Savidou I, Deutsch M, Soultati A, *et al.* Hepatotoxicity induced by cyproterone acetate: a report of three cases. *World J Gastroenterol* 2006; **12**: 7551–5.
31. Abenavoli L, Milic N, Beaugrand M. Severe hepatitis induced by cyproterone acetate: role of corticosteroids. A case report. *Ann Hepatol* 2013; **12**: 152–5.
32. Kim JH, Wook Yoo B, Yang WJ. Hepatic failure induced by cyproterone acetate: a case report and literature review. *Can Urol Assoc J* 2014; **8**: e458–61.
33. Hennes EM, Zeniya M, Czaja AJ, *et al.* Simplified criteria for the diagnosis of autoimmune hepatitis. *Hepatology* 2008; **48**: 169–76.
34. Aithal GP, Watkins PB, Andrade RJ, *et al.* Case definition and phenotype standardization in drug-induced liver injury. *Clin Pharmacol Ther* 2011; **89**: 806–15.
35. Benichou C, Danan G, Flahault A. Causality assessment of adverse reactions to drugs–II. An original model for validation of drug causality assessment methods: case reports with positive rechallenge. *J Clin Epidemiol* 1993; **46**: 1331–6.
36. Arowojolu AO, Gallo MF, Lopez LM, Grimes DA. Combined oral contraceptive pills for treatment of acne. *Cochrane Database Syst Rev* 2012; **7**: CD004425.
37. Falsetti L, Gambera A, Platto Q, Legrenzi L. Management of hirsutism. *Am J Clin Dermatol* 2000; **1**: 89–99.
38. Thole Z, Manso G, Salgueiro E, Revuelta P, Hidalgo A. Hepatotoxicity induced by antiandrogens: a review of the literature. *Urol Int* 2004; **73**: 289–95.
39. Romero M, Palmer SL, Kahn JA, *et al.* Imaging appearance in acute liver failure: correlation with clinical and pathology findings. *Dig Dis Sci* 2014; **59**: 1987–95.
40. Garty BZ, Dinari G, Gellvan A, Kauli R. Cirrhosis in a child with hypothalamic syndrome and central precocious puberty treated with cyproterone acetate. *Eur J Pediatr* 1999; **158**: 367–70.
41. Kacar S, Akdogan M, Kosar Y, *et al.* Estrogen and cyproterone acetate combination-induced autoimmune hepatitis. *J Clin Gastroenterol* 2002; **35**: 98–100.
42. Björnsson E, Talwalkar J, Treeprasertsuk S, *et al.* Drug-induced autoimmune hepatitis: clinical characteristics and prognosis. *Hepatology* 2010; **51**: 2040–8.
43. Lucena MI, Kaplowitz N, Hallal H, *et al.* Recurrent drug-induced liver injury (DILI) with different drugs in the Spanish Registry: the dilemma of the relationship to autoimmune hepatitis. *J Hepatol* 2011; **55**: 820–7.
44. Moller S, Iversen P. Severe toxic hepatitis during flutamide (Eulexin) treatment. *Ugeskr Laeger* 1989; **151**: 173–4.
45. Pontiroli L, Sartori M, Pittau S, *et al.* Flutamide-induced acute hepatitis: investigation on the role of immunological mechanisms. *Ital J Gastroenterol Hepatol* 1998; **30**: 310–4.
46. Fau D, Eugene D, Berson A, *et al.* Toxicity of the antiandrogen flutamide in isolated rat hepatocytes. *J Pharmacol Exp Ther* 1994; **269**: 954–62.

## Supporting information

Additional Supporting Information may be found at [onlinelibrary.wiley.com/doi/10.1111/liv.12899/supinfo](http://onlinelibrary.wiley.com/doi/10.1111/liv.12899/supinfo)