

Disorders of Sex Development with Testicular Differentiation in *SRY*-Negative 46,XX Individuals: Clinical and Genetic Aspects

Romina P. Grinspon^a Rodolfo A. Rey^{a, b}

^aCentro de Investigaciones Endocrinológicas 'Dr. César Bergadá' (CEDIE), CONICET-FEI-División de Endocrinología, Hospital de Niños Ricardo Gutiérrez, and ^bDepartamento de Histología, Biología Celular, Embriología y Genética, Facultad de Medicina, Universidad de Buenos Aires, Buenos Aires, Argentina

Key Words

Disorders of sex development · *SRY* · XX maleness

Abstract

Virilisation of the XX foetus is the result of androgen excess, resulting most frequently from congenital adrenal hyperplasia in individuals with typical ovarian differentiation. In rare cases, 46,XX gonads may differentiate into testes, a condition known as 46,XX testicular disorders of sex development (DSD), or give rise to the coexistence of ovarian and testicular tissue, a condition known as 46,XX ovotesticular DSD. Testicular tissue differentiation may be due to the translocation of *SRY* to the X chromosome or an autosome. In the absence of *SRY*, overexpression of other pro-testis genes, e.g. *SOX* family genes, or failure of pro-ovarian/anti-testis genes, such as *WNT4* and *RSPO1*, may underlie the development of testicular tissue. Recent experimental and clinical evidence giving insight into *SRY*-negative 46,XX testicular or ovotesticular DSD is discussed.

© 2016 S. Karger AG, Basel

gonadal (ovarian) development, but it occurs more frequently in individuals with typical ovarian differentiation (table 1). In humans, congenital adrenal hyperplasia, deficiencies in aromatase activity, androgen-secreting tumours and consumption of drugs with androgenic potential belong to the second group and represent the vast majority of cases of 46,XX disorders of sex development (DSD).

Ovarian differentiation is the normal pathway in 46,XX fetuses (fig. 1). However, in rare cases, 46,XX gonads may either completely differentiate into testes, a condition known as 46,XX testicular DSD (previously called XX male) [de la Chapelle et al., 1964], or give rise to the coexistence of ovarian and testicular tissue in the same individual, a condition known as 46,XX ovotesticular DSD (previously true hermaphroditism) [Lee et al., 2006]. In this review, we will address the latest discoveries regarding the causes, underlying genetic mechanisms and clinical aspects of 46,XX DSD with testicular tissue development.

Normal Foetal Sex Differentiation

Virilisation of the XX foetus is the result of excessive androgen action during intrauterine development. Androgen excess may be the consequence of a disorder of

The pioneering experiments of Alfred Jost [1953] more than 60 years ago established our understanding about the determining effect of the gonadal ridge devel-

Fig. 1. Genetic control of sexual differentiation. The bipotential gonadal ridges may differentiate into testes, ovaries or ovotestes, depending on the pathway prevailing in the delicate dosage balance of expression of the genes involved in testicular and ovarian differentiation. SRY upregulates SOX9, which drives testicular differentiation. SOX3, SOX8 and SOX10 can also upregulate SOX9, when overexpressed. SOX9 induces FGF9 and PDG2, which in turn up-regulate SOX9, thus establishing a positive feedback loop. WNT4 and RSP01 stabilise β -catenin, encoded by CTNNB1, which promotes the expression of ovarian genes, such as FOXL2. WNT4, RSP01, FOXL2, and DAX1 counteract SOX9, and vice versa, in gonadal development.

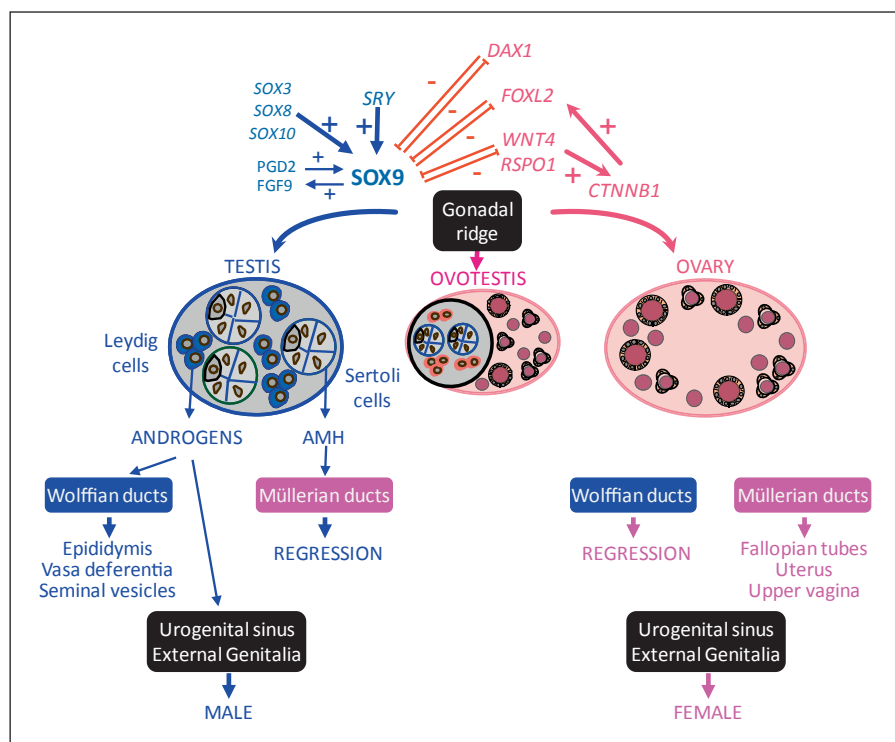


Table 1. 46,XX DSD

Abnormal gonadal (ovarian) differentiation

Testicular DSD

With no overt gonadal dysgenesis (previously known as XX male)

With overt gonadal dysgenesis: DSD with ambiguous genitalia

Ovotesticular DSD

Normal gonadal (ovarian) differentiation

Androgen excess

Foetal

Congenital adrenal hyperplasia: deficiencies of 21-hydroxylase, 11-hydroxylase deficiency, or 3 β -hydroxysteroid dehydrogenase
Glucocorticoid receptor mutations

Foeto-placental: aromatase deficiency, POR (P450 oxidoreductase)

Maternal (luteoma, exogenous, etc.)

Malformative DSD

Defective Müllerian duct formation

Defects of the urogenital sinus and external genitalia: cloacal exstrophy, vaginal atresia, etc.

opment into a testis for the male differentiation of the internal and external genitalia, due to the secretion of testosterone and a second testicular factor, subsequently characterised as the anti-Müllerian hormone (AMH)

[Josso, 2008]. In their absence, internal and external genitalia follow the female pathway. The degree of virilisation of the internal and external genitalia and of the regression of Müllerian ducts depends on the mass of functional testicular tissue present in the narrow window of foetal dimorphic sex differentiation [Rey and Grinspon, 2011]. A few years after Jost's work, the determining role of the Y chromosome for testicular development was established [Ferguson-Smith, 2009].

During the indifferent stage, the gonads are bipotential irrespective of their XX or XY karyotype. Gonadal differentiation into a testis or an ovary requires a delicate dosage balance in the timing and levels of expression of several genes [Lin and Capel, 2015]. In most mammalian embryos, the transient expression of SRY, which maps to the Y chromosome, triggers a cascade of gene interactions ultimately leading to the formation of a testis from the indifferent gonadal ridge [Larney et al., 2014]. SRY expression initiates in the middle of the gonad and expands toward the poles [Bullejos and Koopman, 2001]. The timing and level of SRY expression are critical for proper testis differentiation: delayed or decreased expression results in dysgenetic testicular or ovotesticular differentiation in the mouse [Nagamine et al., 1999; Bullejos and Koopman, 2005]. In most mammals, the SRY-box gene

SOX9 is the earliest upregulated gene in the testis pathway downstream of *SRY*, followed by *CITED4* and other members of the SOX family, including *SOX3*, *SOX10* and *SOX13*, and many other genes that are critical for testicular differentiation [Quinn and Koopman, 2012; Munger et al., 2013; Lin and Capel, 2015].

Genes involved in ovarian differentiation of the bipotential gonad increase their expression somewhat later. WNT4 and RSPO1 stabilise β -catenin, encoded by *CTNNB1*, which promotes the expression of ovarian genes, such as *FST* (follistatin) and *FOXL2*. The latter also counteracts SOX9 and other pathways involved in early testis development [Carré and Greenfield, 2014; Biason-Lauber and Chaboissier, 2015; Lin and Capel, 2015; Suzuki et al., 2015] (fig. 1).

46,XX Ovotesticular and Testicular DSD

Ovotesticular DSD is a rare form of DSD, with variable prevalence and karyotypes in different regions of the world. However, all studies agree that 46,XX is the most common karyotype observed in blood samples, ranging from ~65 to 90% [Verkauskas et al., 2007; Wiersma and Ramdial, 2009; Matsui et al., 2011]. The remaining cases carry a Y chromosome (46,XY, 46,XX/46,XY or other mosaicisms), which explains the development of testicular tissue. In 46,XX patients with testicular or ovotesticular DSD, the *SRY* gene may be present, owing to an abnormal translocation to the X chromosome or more rarely to an autosome. A precise frequency of *SRY*-positive 46,XX DSD is difficult to estimate due to inclusion and/or ascertainment biases of the various studies. In unselected samples of limited numbers (between 30 and 33 patients), the reported prevalence of *SRY*-positive 46,XX ovotesticular DSD cases ranges from 10% [McElreavey et al., 1992] to 33% [Verkauskas et al., 2007]. Yet, frequencies may range from 0% of cases when *SRY* was studied in blood cells of 46,XX ovotesticular DSD patients with ambiguous genitalia [Matsui et al., 2011] to 100% of cases when *SRY* was determined in blood cells of 46,XX testicular DSD with complete virilisation [Vorona et al., 2007] or in gonadal tissue of 46,XX ovotesticular DSD cases with ambiguous genitalia [Ortenberg et al., 2002]. Despite imprecision, evidence that *SRY* could not explain all cases of 46,XX maleness became progressively stronger.

When testicular tissue differentiates in an *SRY*-negative XX gonad, 2 different mechanisms can be envisaged: the increased expression of pro-testis genes or the insuf-

ficient expression of pro-ovarian/anti-testis genes (fig. 1). An effort to make an accurate diagnosis is important for the provision of proper genetic counselling and long-term management. In the next sections, we will review recent evidence on the genetic mechanisms underlying XX maleness in *SRY*-negative individuals and on the clinical management of these patients.

Mechanisms Underlying Testis Differentiation in *SRY*-Negative Individuals

Increased Expression of Pro-Testis Genes

SOX9

The SOX (SRY-related HMG box) protein family includes a group of transcriptional regulators containing a highly conserved high-mobility-group domain [Lefebvre et al., 2007]. This domain was first identified in *SRY*. SOX9, mapping to 17q24.3 in the human, is expressed in several tissues including chondrocytes and testes but also in bile duct, the central nervous system, hair follicles, heart, lung, pancreas, and retina. In the XY mouse embryo, an increase in SOX9 expression is induced by *SRY* in the gonadal ridge. SOX9 then upregulates FGF9 and PGD2, and a positive feedback loop is established to further upregulate SOX9, which progressively becomes independent of *SRY* (fig. 1). SOX9 is responsible for Sertoli cell specification, thus initiating testis differentiation [Eggers et al., 2014], and for triggering AMH production [de Santa Barbara et al., 1998; Arango et al., 1999]. SOX9 haploinsufficiency results in dysgenetic 46,XY DSD associated with campomelic dysplasia [Foster et al., 1994; Wagner et al., 1994].

Conversely, ectopic SOX9 expression in undifferentiated gonads of transgenic XX mice results in sex reversal with testis development and male phenotype, demonstrating that high SOX9 expression suffices to trigger testis differentiation in the absence of *Sry* [Vidal et al., 2001]. Adult gonads contain seminiferous tubules with Sertoli cells but no spermatogenesis, as expected in a male with 2 X chromosomes. Similarly, XX dogs with an interstitial duplication of chromosome 9 which carry the SOX9 locus develop through the male pathway [Rossi et al., 2014].

Testicular and ovotesticular DSD in 46,XX *SRY*-negative patients have been described in association with duplications of chromosome 17 carrying the SOX9 locus. The first infant with ambiguous genitalia and scrotal gonads, who carried a de novo mosaic 46,XX,dup(17)(q23.1q24.3) containing the SOX9 gene, as revealed by FISH, was reported in 1999 [Huang et al., 1999]. The

Table 2. Genetics and phenotypes of *SRY*-negative 46,XX DSD with testicular tissue

Proposed pathogenesis	Genetic findings	Genitalia	Gonadal histology	Hormone analysis	References
Increased SOX9 expression	duplication of <i>SOX9</i> gene	ambiguous genitalia (n = 1) male genitalia (n = 1)	not reported testes	not reported normal FSH, LH, AMH and post-hCG T	Huang et al., 1999 Lee et al., 2014
	duplications/triplications of <i>SOX9</i> regulatory sequences	infertile male ± gynaecomastia (n = 8) ambiguous genitalia (n = 4)	testes with germ cell depletion ovotestes/testes	high FSH and LH low to normal T low T post-hCG	Cox et al., 2011 Vetro et al., 2011 Vetro et al., 2015 Kim et al., 2015 Vetro et al., 2015
Increased SOX3 expression	duplication of <i>SOX3</i> gene	infertile male (n = 2)	not reported	high FSH and L low to normal T	Sutton et al., 2011
		male genitalia (n = 2)	not reported	not reported	Sutton et al., 2011 Vetro et al., 2015
		ambiguous genitalia (n = 1)	not reported	normal FSH, LH and T	Moalem et al., 2012
	rearrangement of <i>SOX3</i> regulatory regions	ambiguous genitalia (n = 4)	testes	not reported	Mizuno et al., 2014
		ambiguous genitalia (n = 1) ambiguous genitalia (n = 1)	one testis/one ovary ovotestes	normal FSH, LH and T for male normal FSH and LH, low AMH and T for male	Haines et al., 2015 Grinspon et al., 2015
Increased SOX10 expression	duplication of chromosome 22q	normal male (n = 1) ambiguous genitalia (n = 1)	not reported one testis/one ovary	not reported low T for male	Seeherunvong et al., 2004 Aleck et al., 1999
	trisomy 22	ambiguous genitalia (n = 1)	dysgenetic testes	low T for male post-hCG	Nicholl et al., 1994
Decreased WNT4 expression	<i>WNT4</i> point mutation	ambiguous genitalia in SERKAL syndrome (n = 2)	dysgenetic testes (n = 1) ovotestes (n = 1)	not reported	Mandel et al., 2008
Decreased RSPO1 expression	<i>RSPO1</i> 2.7-kb deletion	ambiguous genitalia, palmoplantar keratoderma (n = 4)	dysgenetic testes (n = 1) rest not available	not reported	Parma et al., 2006
	<i>RSPO1</i> point mutation	ambiguous genitalia, palmoplantar keratoderma, onychodystrophy, hearing impairment (n = 1)	ovotestes	normal FSH, LH and oestradiol for female	Tomaselli et al., 2008

hCG = Human chorionic gonadotropin; T = testosterone.

study suggested that the extra dose of *SOX9* is sufficient to initiate testis differentiation in the absence of *SRY*; however, the gonadal histology was not described. A recent case of a boy with normal genitalia has also been reported with a *SOX9* duplication [Lee et al., 2014].

In line with the previous observation and with data in mice identifying relevant *cis*-activating elements within a *SOX9* gonad-specific enhancer [Sekido and Lovell-Badge, 2008], duplications or triplications of potential *SOX9* regulatory sequences have subsequently been identified associated with XX maleness. In fact, a 178-kb duplication 600 kb upstream [Cox et al., 2011] and a 96-kb triplication 500 kb upstream [Vetro et al., 2011] of the *SOX9* coding sequence were initially identified as the cause of familial 46,XX testicular DSD in *SRY*-negative patients with small testes and azoospermia (table 2). Also, a 148-kb tandem duplication of the region –595 to –447 kb upstream of *SOX9* was found in an *SRY*-negative 46,XX patient with ovotesticular DSD, who presented with ambiguous geni-

italia. Two further cases with partially overlapping 17q24.3 duplications ~500 kb upstream of *SOX9* presented with dissimilar phenotypes: one was an infertile male with testes, while the other was an ovotesticular DSD with ambiguous genitalia [Vetro et al., 2015]. Finally, 3 recent reports [Xiao et al., 2013; Hyon et al., 2015; Kim et al., 2015] have identified 7 further *SRY*-negative patients with 46,XX testicular or ovotesticular DSD, who carried duplications ranging from 68 to 83.8 kb, located ~510–600 kb upstream of *SOX9*, which overlapped with previously reported rearrangements and allowed refining the minimal region to a 40.7–41.9-kb element.

SOX3

SOX3 is a single exon gene located in Xq27.1, which encodes a protein that is most similar to *SRY* and that is required for normal brain, pituitary and craniofacial development in mice and humans. Although *SOX3* is not required for normal testicular differentiation, as revealed

by mutations in humans and mice [Weiss et al., 2003], its ectopic overexpression in the developing XX gonads provokes testicular development in a transgenic mouse model. Elegant experimental studies have shown that, just as SRY, SOX3 can act synergistically with SF1 to upregulate SOX9 expression and trigger Sertoli cell differentiation in the bipotential gonad [Sutton et al., 2011].

Concordantly, different rearrangements of the SOX3 locus have been associated with 46,XX testicular DSD, suggesting that overexpression of SOX3 can cause XX male sex reversal in humans. Duplications encompassing SOX3 have been reported in 5 SRY-negative 46,XX patients with male or ambiguous genitalia and functional evidence of the existence of testicular tissue [Sutton et al., 2011; Moalem et al., 2012; Vetro et al., 2015], although no histological study of the gonads was reported in most of them. In 5 other patients, the condition was associated with rearrangements involving the regulatory region of SOX3. A duplication of a common 206-kb region, located 566 kb upstream of the SOX3 coding sequence, was found in four 46,XX patients with testicular DSD [Mizuno et al., 2014], while a 773-kb duplication of chromosome 1 integrated ~82 kb distal to SOX3 was described in a patient with testicular differentiation on one side and an ovary on the other side [Haines et al., 2015]. We have recently reported the first case of an SRY-negative 46,XX patient with ambiguous genitalia associated to a SOX3 duplication presenting with bilateral ovotestes [Grinson et al., 2015]. It should, however, be mentioned that a SOX3 duplication may not be sufficient to induce testicular differentiation when normal regulatory sequences are lacking in the duplicated DNA fragment [Igarashi et al., 2015].

SOX10

SOX10, a gene closely related to SOX9, maps to chromosome 22q13.1 in humans and is involved in neural crest and glial development. As for SOX3, a functional role for SOX10 has not been established in normal gonadal development [Pingault et al., 2013], presumably because loss-of-function during gonadal development is likely to be masked by the action of other members of the SOX family. However, overexpression of *Sox10* in the gonads of transgenic XX mice results in the development of testes and a male phenotype [Polanco et al., 2010]. Interestingly, complete or partial duplications of chromosome 22 have been reported in a number of SRY-negative XX cases with ovarian dysgenesis and/or testicular tissue differentiation [Polanco et al., 2010]. Relevant to the present review are a patient with masculinised external genitalia, dysgenetic testes and Müllerian remnants with a

47,XX,+22 karyotype [Nicholl et al., 1994], a patient with ambiguous genitalia (ovotesticular DSD) associated to an inverted duplication of 22q13.122qter [Aleck et al., 1999], and a patient showing only mild hypospadias and bilaterally palpable testes in whom a duplication of 22q11.222q13 was reported [Seeherunvong et al., 2004].

DMRT1

The *DMRT* gene cluster is located in human chromosome 9p24.3 and comprises *DMRT2*, *DMRT3* and *DMRT1* [Brunner et al., 2001]. *DMRT* genes have a conserved DNA-binding motif, the DM domain, and play critical roles in gonadal differentiation and gametogenesis. *DMRT1* encodes a male-specific transcription factor and has the most prominent role – amongst *DMRT* genes – in regulating testicular differentiation in all vertebrates. Distal 9p deletions encompassing the *DMRT* cluster are associated with dysgenetic and ovotesticular DSD in 46,XY patients [Matson and Zarkower, 2012].

Although no SRY-negative 46,XX DSD patients with testicular tissue and *DMRT1* overexpression have as yet been identified, increased expression of *Dmrt1* in the foetal gonads of transgenic XX mice is sufficient to drive testicular differentiation and male sex development [Zhao et al., 2015].

Insufficient Expression of Pro-Ovarian Genes

WNT4

WNT4 belongs to the WNT family, a large group of secreted glycoproteins encoded by 19 distinct genes that are expressed in a tissue-specific fashion. *WNT4* maps to 1p36.12, and there is clinical and experimental evidence of its role in sex differentiation. WNT4 cooperates with RSPO1, leading to a reduction in the phosphorylation and degradation of β -catenin. The consequent increase in β -catenin induces WNT-responsive genes and antagonises SOX9 [Carré and Greenfield, 2014; Biason-Lauber and Chaboissier, 2015]. WNT4 upregulates DAX1 expression, which antagonises SF1, and thereby inhibits steroidogenic enzymes. WNT4 overexpression has been associated to sex reversal in a XY patient [Jordan et al., 2001]. Apart from its role in ovarian differentiation, WNT4 is also directly involved in Müllerian duct formation [Biason-Lauber and Chaboissier, 2015] and plays a critical role in the formation of the kidneys, adrenals, pituitary gland, and mammary tissue.

The first experimental evidence of the role of WNT4 in sex development derives from the inactivation of the *Wnt4* gene in mice [Vainio et al., 1999]. *Wnt4* knockout XX mice are virilised, the Müllerian duct is absent, and

the development of the Wolffian ducts resembles that of the male. The gonads are also masculinised, as revealed by the enhanced expression of the steroidogenic enzymes 3 β -hydroxysteroid dehydrogenase and 17 α -hydroxylase, required for testosterone synthesis and normally suppressed in the foetal ovary.

Heterozygous loss-of-function mutations of *WNT4* have been described in three 46,XX patients with mild virilisation. The main complaint was primary amenorrhoea due to Müllerian defects characteristic of the Mayer-Rokitansky-Kuster-Hauser syndrome and clinical signs of androgen excess [Biason-Lauber et al., 2004, 2007], but no testicular tissue could be identified [Philibert et al., 2008]. Conversely, the inactivation of both copies of *WNT4* results in a severe clinical condition, known as the SERKAL syndrome, characterised by 46,XX DSD with ambiguous genitalia, renal agenesis, adrenal hypoplasia, and pulmonary and cardiac abnormalities. The presence of testicular DSD and ovotesticular DSD were reported in the same family [Mandel et al., 2008].

RSPO1

RSPO1 is one of the 4 members of the R-spondin family, expressed during foetal development in the central nervous system, the limb buds and the body trunk, and the proximal posterior part of the anterior limb bud [Chassot et al., 2008]. The human *RSPO1* gene is located in chromosome 1p34.3. As already mentioned, several lines of evidence have demonstrated that RSPO1 synergises with *WNT4* in XX gonads to stabilize β -catenin, thus acting as an activator of the canonical signalling pathway in ovarian development [Biason-Lauber and Chaboissier, 2015].

In mice, the ovarian phenotype of the XX *Rspo1* knockout is strikingly similar to that of *Wnt4* knockout [Chassot et al., 2008]. Penetrance of the phenotype is slightly variable, and gonad morphology may range from dysgenetic gonads to ovotestes. Interestingly, β -catenin overexpression is able to rescue the abnormal masculinisation of the gonads of XX *Rspo1* knockout mice, thus confirming that RSPO1 acts through the β -catenin signalling pathway.

In humans, the first reported cases with loss-of-function mutations of the *RSPO1* gene were associated with *SRY*-negative 46,XX DSD, palmoplantar hyperkeratosis and squamous cell carcinoma of the skin [Parma et al., 2006]. The presence of 'functional' testes was assumed based on the absence of Müllerian derivatives and the masculinisation of the internal and external genitalia; however, no histological study of the gonads is reported.

A second case with 46,XX virilisation associated with palmoplantar keratoderma, congenital bilateral corneal opacities, onychodystrophy, and hearing impairment was reported later. Laparoscopy showed an apparently normal uterus and left fallopian tube. Histology of the gonad biopsy showed the presence of ovotestis and a seminoma [Tomaselli et al., 2008]. Notably, the normal reproductive phenotype of 46,XY individuals suggests that RSPO1 is not required for testis differentiation and function.

FOXL2

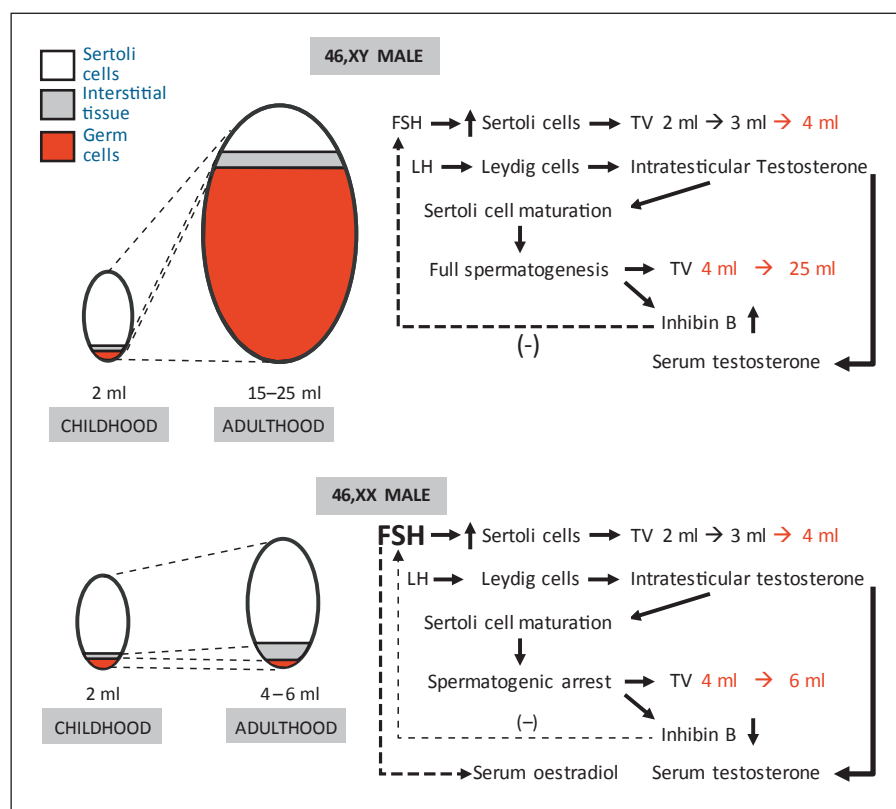
FOXL2 is a single exon gene encoding a forkhead/winged helix nuclear protein acting as a transcription factor, and mapping to 3q22.3 in humans. In most vertebrates, *FOXL2* is one of the earliest markers of foetal differentiation of the ovary. In mice, *Foxl2* does not seem essential for ovarian development in the XX foetus, but forced expression impairs testis differentiation in the XY foetus [Ottolenghi et al., 2007]. *FOXL2* continues to be expressed in the postnatal ovary, and ablation of *FOXL2* expression in the XX adult ovary results in its transdifferentiation to testis [Uhlenhaut et al., 2009]. In 46,XX patients, loss-of-function of *FOXL2* is associated with the blepharophimosis/ptosis/epicanthus inversus (BPES) syndrome with or without ovarian dysgenesis [Crisponi et al., 2001], but no development of testicular tissue or signs of virilisation have been reported.

Clinical Features

In the previous passages of this review, we analysed 46,XX DSD with testicular tissue differentiation from a pathogenic standpoint and referred to them as 'testicular' or 'ovotesticular' DSD according to whether ovarian tissue was present. In all cases, the testicular component could be more or less dysgenetic. While the existence of testicular tissue can be easily demonstrated, since it can be inferred from the assessment of genital virilisation and of the levels of circulating testosterone and AMH, the ascertainment of the existence of ovarian tissue is not always possible. In fact, the presence of the ovaries do not have any impact on foetal development of the genitalia [Jost, 1953], and there are no reliable markers of ovarian function in infants; therefore, the diagnosis of ovotesticular DSD may be missed.

From a clinical point of view, virilised 46,XX patients with testicular tissue can present with an apparently normal male phenotype or with variable degrees of genital

Fig. 2. Functional evolution of the gonads in 46,XX testicular DSD. In normal XY testes, at pubertal onset FSH promotes Sertoli cell proliferation, which results in a mild increase in testicular volume. LH induces Leydig cell testosterone production, which provokes Sertoli cell maturation. Consequently, meiosis is triggered; complete spermatogenesis results in the enlargement of the testes to adult size and the increase of inhibin B, which exerts a negative feedback on FSH. In the XX male, there is a meiotic arrest and germ cell degeneration. Consequently, testis size persists small and inhibin B production decreases, resulting in an increase of FSH levels. Oestrogen levels may increase from testosterone aromatisation induced by FSH.



ambiguity (table 1). Evidence exists that testicular and ovotesticular DSD are different manifestations of the same disorder of gonadal development, especially by the existence of different phenotypes in the same family and even in monozygotic twins [Maciel-Guerra et al., 2008]. Notwithstanding, we will separately address the clinical features of completely virilised patients and those with ambiguous genitalia.

46,XX DSD with Testicular Tissue and Complete Virilisation

According to the nomenclature suggested by the Chicago consensus [Lee et al., 2006], this includes 46,XX testicular DSD and, very rarely, 46,XX ovotesticular DSD. The former corresponds to the original concept of 'XX male', as defined by Albert de la Chapelle [1972], i.e. 'a male phenotype, male psychosexual identification, testes or gonads of testicular type without macroscopic or microscopic evidence of ovarian tissue, and absence of female genital organs'. It is estimated that 90% of XX males are SRY-positive [Vorona et al., 2007]; since no distinction has been made in most of early clinical descriptions of XX males regarding the existence or not of Y chromo-

some sequences including SRY, we are not able to make a detailed, specific characterisation of SRY-negative XX males. When testes have differentiated normally during foetal development, irrespective of the presence or absence of SRY, clinical features of XX males are expected to be the same.

In these typical cases, diagnosis is usually delayed until adult life when the male patient is examined because of infertility. Less frequently, boys may be referred to a paediatric endocrinologist for short stature or small testes at the age of puberty. In fact, the stature of XX boys is lower than that of age-matched XY pairs, and similar to that of age-matched XX girls, in spite of similar circulating levels of hormone of the growth axis, including IGF1 and IGFBP3 [Aksglaede et al., 2008]. The existence of Y-specific growth genes may be the explanation. Testes are smaller in these patients, as in patients with Klinefelter syndrome, in adulthood [Vorona et al., 2007]. Testicular volume does not differ from that of control boys during childhood. The underlying reason is that testicular volume depends mainly on Sertoli cells before puberty. Also at pubertal onset, testicular volume increases progressively to 4 ml, and even to 6–8 ml, mainly due to Sertoli

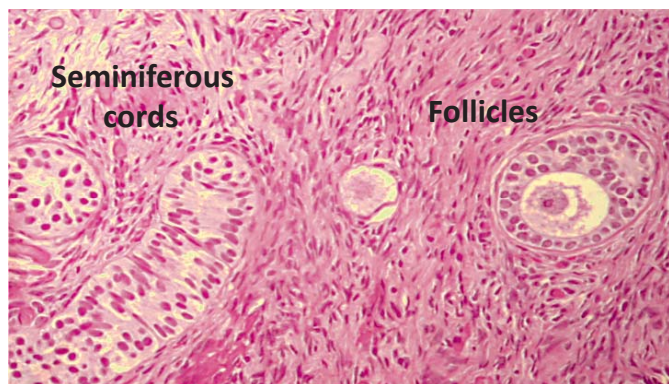


Fig. 3. Histology of ovotesticular DSD. Histological aspect of an ovotestis, whose diagnosis requires the presence of seminiferous cords (or tubules) and ovarian follicles with oocytes. The mere existence of a fibrous ovarian-like stroma, without follicles, is insufficient for the diagnosis. Modified with permission from Chemes et al. [2003].

cell proliferation [Rey, 2014]. Sertoli and Leydig cell function is normal in childhood and at the onset of puberty in 46,XX males, as revealed by normal testis hormone and gonadotropin levels [Boucekkine et al., 1994; Rey et al., 1999]. Testicular dysfunction occurs during pubertal development, when the normal increase in testicular volume is led by germ cell proliferation. The existence of 2 X chromosomes and the absence of a Y chromosome results in meiotic failure, leading to dramatic germ cell loss, regression of testicular volume, azoospermia and low semen volume (fig. 2) [Huang and Yen, 2008]. Seminiferous tubule dysfunction is reflected in low inhibin B and increasing FSH, whereas a mild Leydig cell dysfunction may exist in some cases leading to low-normal testosterone and increased LH. A typical feature is the elevation of oestrogen levels responsible for gynaecomastia [Vorona et al., 2007; Aksglaede et al., 2009].

46,XX DSD with Testicular Tissue and Ambiguous Genitalia

When the amount or functional capacity of the testicular tissue is insufficient, various degrees of genital ambiguity may occur. This applies to both testicular DSD and ovotesticular DSD. As already mentioned, the differential diagnosis between ovotesticular and testicular DSD is based on histological analysis. Ovotesticular DSD requires the existence of seminiferous cords and ovarian follicles with oocytes (fig. 3). The clinical presentation does not differ from that of other types of DSD, with a range going from a rather male phenotype with mild hy-

pospadias and cryptorchidism to a female presentation with clitoromegaly and minor labial fusion. Internal genitalia usually correlate with external virilisation, and Müllerian derivatives are present in less virilised patients. However, ultrasonographic assessment may be deceiving as a diagnostic tool in these newborns or infants. Histological analysis of the gonads is mandatory for diagnostic ascertainment; however, the small size of the biopsy may represent a pitfall.

Testosterone and AMH levels are usually intermediate between the normal male and female ranges [Boucekkine et al., 1994; Rey et al., 1999]. The levels of oestradiol may reflect the amount of functional ovarian tissue in newborns and in patients of pubertal age. Gonadotropins may be elevated or normal [Boucekkine et al., 1994; Maciel-Guerra et al., 2008], probably reflecting the action of ovarian oestrogens in the latter case, since testicular tissue is dysgenetic in most cases.

Sex assignment is an issue in these patients, and the considerations are similar to those in DSD in general [Lee et al., 2006]. A particular aspect may derive from the fact that the ovarian tissue may be normal enough to produce oocytes in patients with ovotesticular DSD. Therefore, female assignment with special attention to the preservation of ovarian tissue may be favoured in these cases. To date, there are less than 20 cases of pregnancy reported in patients with ovotesticular DSD raised as females, and the majority have had complications, such as preterm labor or morbidity related to the delivery process, as a consequence of defects in the female reproductive tract [Guericio and Rey, 2014].

Partial gonadectomy requires a special comment: in patients raised as boys, the ovarian portion needs to be removed before pubertal age to avoid oestrogen elevation resulting in gynaecomastia and other features of heterosexual pubertal development, and also to prevent complications of cystic follicles that may develop in response to elevated FSH. In rare cases, male patients with a history of hypospadias and cryptorchidism have been described to present with cyclical haematuria during adolescence. Subsequent ultrasonography, micturating cystourethrogram and cystoscopy confirmed the presence of the uterus and vagina draining into the urogenital sinus and the penile urethra [Dutta et al., 2014]. In patients raised as females, testicular tissue needs to be removed to avoid virilisation during puberty.

Concerning the risk of tumour development in the testicular portion, it has been reported to be low even if the tissue is dysgenetic, probably because of the absence of Y chromosome sequences [Cools et al., 2014].

Concluding Remarks

Evolving knowledge triggers changes in nomenclature. The old definitions of XX males and true hermaphroditism have left their place to the most recent 46,XX testicular DSD and ovotesticular DSD. However, this homology is not straightforward. Whereas the concept of XX males did not include genital ambiguity, XX testicular DSD includes all 46,XX patients with testes, irrespective of whether they have a normal capacity of producing androgens and AMH or whether they are dysgenetic. Clearly, a male phenotype results in the former case, and ambiguous genitalia in the latter. Also, with the availability of new technologies, we have gained insight into the

mechanisms underlying testicular tissue development in 46,XX SRY-negative individuals. Thus, inadequate expression of *SOX3*, *SOX9*, *SOX10*, *WNT4*, and *RSPO1* have already been associated with XX testicular or ovotesticular DSD in humans, while other candidate genes are being considered on the basis of knowledge derived from experimental models. The impact on clinical practice of the complete unveiling of the genetic aetiologies of XX maleness is as yet only partially appraised.

Disclosure Statement

The authors have no conflicts of interest to declare.

References

- Aksglaede L, Skakkebaek NE, Juul A: Abnormal sex chromosome constitution and longitudinal growth: serum levels of insulin-like growth factor (IGF)-I, IGF binding protein-3, luteinizing hormone, and testosterone in 109 males with 47,XXY, 47,XYy, or sex-determining region of the Y chromosome (SRY)-positive 46,XX karyotypes. *J Clin Endocrinol Metab* 93:169–176 (2008).
- Aksglaede L, Jorgensen N, Skakkebaek NE, Juul A: Low semen volume in 47 adolescents and adults with 47,XXY Klinefelter or 46,XX male syndrome. *Int J Androl* 32:376–384 (2009).
- Aleck KA, Argueso L, Stone J, Hackel JG, Erickson RP: True hermaphroditism with partial duplication of chromosome 22 and without SRY. *Am J Med Genet* 85:2–4 (1999).
- Arango NA, Lovell-Badge R, Behringer RR: Targeted mutagenesis of the endogenous mouse *Mis* gene promoter: in vivo definition of genetic pathways of vertebrate sexual development. *Cell* 99:409–419 (1999).
- Biason-Laubier A, Chaboissier MC: Ovarian development and disease: the known and the unexpected. *Semin Cell Dev Biol* 45:59–67 (2015).
- Biason-Laubier A, Konrad D, Navratil F, Schoenle EJ: A *WNT4* mutation associated with Müllerian-duct regression and virilization in a 46,XX woman. *N Engl J Med* 351:792–798 (2004).
- Biason-Laubier A, De Filippo G, Konrad D, Scarano G, Nazzaro A, Schoenle EJ: *WNT4* deficiency – a clinical phenotype distinct from the classic Mayer-Rokitansky-Kuster-Hauser syndrome: a case report. *Hum Reprod* 22:224–229 (2007).
- Boucekkine C, Toubian JE, Abbas N, Chaabouni S, Ouahid S, et al: Clinical and anatomical spectrum in XX sex reversed patients. Relationship to the presence of Y specific DNA-sequences. *Clin Endocrinol (Oxf)* 40:733–742 (1994).
- Brunner B, Hornung U, Shan Z, Nanda I, Kondo M, et al: Genomic organization and expression of the doublesex-related gene cluster in vertebrates and detection of putative regulatory regions for *DMRT1*. *Genomics* 77:8–17 (2001).
- Bullejos M, Koopman P: Spatially dynamic expression of *Sry* in mouse genital ridges. *Dev Dyn* 221:201–205 (2001).
- Bullejos M, Koopman P: Delayed *Sry* and *Sox9* expression in developing mouse gonads underlies B6-Y^{DOM} sex reversal. *Dev Biol* 278:473–481 (2005).
- Carré GA, Greenfield A: Characterising novel pathways in testis determination using mouse genetics. *Sex Dev* 8:199–207 (2014).
- Chassot AA, Gregoire EP, Magliano M, Lavery R, Chaboissier MC: Genetics of ovarian differentiation: *Rspo1*, a major player. *Sex Dev* 2:219–227 (2008).
- Chemes H, Muzulin PM, Venara MC, Mulhmann Mdel C, Martínez M, Gamboni M: Early manifestations of testicular dysgenesis in children: pathological phenotypes, karyotype correlations and precursor stages of tumour development. *APMIS* 111:12–23 (2003).
- Cools M, Looijenga LH, Wolffenbuttel KP, T'Sjoen G: Managing the risk of germ cell tumourigenesis in disorders of sex development patients. *Endocr Dev* 27:185–196 (2014).
- Cox JJ, Willatt L, Homfray T, Woods CG: A *SOX9* duplication and familial 46,XX developmental testicular disorder. *N Engl J Med* 364:91–93 (2011).
- Crisponi L, Deiana M, Loi A, Chiappe F, Uda M, et al: The putative forkhead transcription factor *FOXL2* is mutated in blepharophimosis/ptosis/epicanthus inversus syndrome. *Nat Genet* 27:159–166 (2001).
- de la Chapelle A: Analytic review: nature and origin of males with XX sex chromosomes. *Am J Hum Genet* 24:71–105 (1972).
- de la Chapelle A, Hortling H, Niemi M, Wennstroem J: XX sex chromosomes in a human male. First case. *Acta Med Scand* 175:Suppl 412:25–28 (1964).
- de Santa Barbara P, Bonneaud N, Boizet B, Desclozeaux M, Moniot B, et al: Direct interaction of SRY-related protein SOX9 and steroidogenic factor 1 regulates transcription of the human anti-Müllerian hormone gene. *Mol Cell Biol* 18:6653–6665 (1998).
- Dutta D, Shivaprasad KS, Das RN, Ghosh S, Chatterjee U, et al: Ovotesticular disorder of sexual development due to 47,XXY/46,XY/45,X mixed gonadal dysgenesis in a phenotypic male presenting as cyclical haematuria: clinical presentation and assessment of long-term outcomes. *Andrologia* 46:191–193 (2014).
- Eggers S, Ohnesorg T, Sinclair A: Genetic regulation of mammalian gonad development. *Nat Rev Endocrinol* 10:673–683 (2014).
- Ferguson-Smith MA: It is 50 years since the discovery of the male determining role of the Y chromosome! *Sex Dev* 3:233–236 (2009).
- Foster JW, Dominguez-Steglich MA, Guioli S, Kowk G, Weller PA, et al: Campomelic dysplasia and autosomal sex reversal caused by mutations in an SRY-related gene. *Nature* 372:525–530 (1994).
- Grinspon R, Nevado J, Mori Alvarez MA, Rey R, del Rey G, Chiesa A: 46,XX ovotesticular DSD in the absence of SRY gene associated to *SOX3* duplication (abstract). *Horm Res Paediatr* 84 Suppl1:96 (2015).
- Guercio G, Rey RA: Fertility issues in the management of patients with disorders of sex development. *Endocr Dev* 27:87–98 (2014).
- Haines B, Hughes J, Corbett M, Shaw M, Innes J, et al: Interchromosomal insertional translocation at Xq26.3 alters *SOX3* expression in an individual with XX male sex reversal. *J Clin Endocrinol Metab* 100:E815–E820 (2015).

- Huang B, Wang SB, Ning Y, Lamb AN, Bartley J: Autosomal XX sex reversal caused by duplication of *SOX9*. *Am J Med Genet* 87:349–353 (1999).
- Huang WJ, Yen PH: Genetics of spermatogenic failure. *Sex Dev* 2:251–259 (2008).
- Hyon C, Chantot-Bastaraud S, Harbuz R, Bhouiri R, Perrot N, et al: Refining the regulatory region upstream of *SOX9* associated with 46,XX testicular disorders of sex development (DSD). *Am J Med Genet A* 167A:1851–1858 (2015).
- Igarashi M, Mikami H, Katsumi M, Miyado M, Izumi Y, et al: *SOX3* overdosage permits normal sex development in females with random X inactivation. *Sex Dev* 9:125–129 (2015).
- Jordan BK, Mohammed M, Ching ST, Delot E, Chen XN, et al: Up-regulation of *WNT-4* signaling and dosage-sensitive sex reversal in humans. *Am J Hum Genet* 68:1102–1109 (2001).
- Josso N: Professor Alfred Jost: the builder of modern sex differentiation. *Sex Dev* 2:55–63 (2008).
- Jost A: Problems of fetal endocrinology: the gonadal and hypophyseal hormones. *Rec Prog Horm Res* 8:379–418 (1953).
- Kim GJ, Sock E, Buchberger A, Just W, Denzer F, et al: Copy number variation of two separate regulatory regions upstream of *SOX9* causes isolated 46,XY or 46,XX disorder of sex development. *J Med Genet* 52:240–247 (2015).
- Larney C, Bailey TL, Koopman P: Switching on sex: transcriptional regulation of the testis-determining gene *Sry*. *Development* 141:2195–2205 (2014).
- Lee GM, Ko JM, Shin CH, Yang SW: A Korean boy with 46,XX testicular disorder of sex development caused by *SOX9* duplication. *Ann Pediatr Endocrinol Metab* 19:108–112 (2014).
- Lee PA, Houk CP, Ahmed SF, Hughes IA; International Consensus Conference on Intersex organized by the Lawson Wilkins Pediatric Endocrine Society and the European Society for Paediatric Endocrinology: Consensus statement on management of intersex disorders. *Pediatrics* 118:e488–e500 (2006).
- Lefebvre V, Dumitriu B, Penzo-Méndez A, Han Y, Pallavi B: Control of cell fate and differentiation by *Sry*-related high-mobility-group box (*SOX*) transcription factors. *Int J Biochem Cell Biol* 39:2195–2214 (2007).
- Lin YT, Capel B: Cell fate commitment during mammalian sex determination. *Curr Opin Genet Dev* 32:144–152 (2015).
- Maciel-Guerra AT, de Mello MP, Coeli FB, Ribeiro ML, Miranda ML, et al: XX maleness and XX true hermaphroditism in *SRY*-negative monozygotic twins: additional evidence for a common origin. *J Clin Endocrinol Metab* 93:339–343 (2008).
- Mandel H, Shemer R, Borochowitz ZU, Okopnik M, Knopf C, et al: *SERKAL* syndrome: an autosomal-recessive disorder caused by a loss-of-function mutation in *WNT4*. *Am J Hum Genet* 82:39–47 (2008).
- Matson CK, Zarkower D: Sex and the singular DM domain: insights into sexual regulation, evolution and plasticity. *Nat Rev Genet* 13:163–174 (2012).
- Matsui F, Shimada K, Matsumoto F, Itesako T, Nara K, et al: Long-term outcome of ovotesticular disorder of sex development: a single center experience. *Int J Urol* 18:231–236 (2011).
- McElreavey K, Rappaport R, Vilain E, Abbas N, Richaud F, et al: A minority of 46,XX true hermaphrodites are positive for the Y-DNA sequence including *SRY*. *Hum Genet* 90:121–125 (1992).
- Mizuno K, Kojima Y, Kamisawa H, Moritoki Y, Nishio H, et al: Elucidation of distinctive genomic DNA structures in patients with 46,XX testicular disorders of sex development using genome wide analyses. *J Urol* 192:535–541 (2014).
- Moalem S, Babul-Hirji R, Stavropoulos DJ, Wherrett D, Bāgli DJ, et al: XX male sex reversal with genital abnormalities associated with a de novo *SOX3* gene duplication. *Am J Med Genet A* 158A:1759–1764 (2012).
- Munger SC, Natarajan A, Looger LL, Ohler U, Capel B: Fine time course expression analysis identifies cascades of activation and repression and maps a putative regulator of mammalian sex determination. *PLoS Genet* 9:e1003630 (2013).
- Nagamine CM, Morohashi K, Carlisle C, Chang DK: Sex reversal caused by *Mus musculus domesticus* Y chromosomes linked to variant expression of the testis-determining gene *Sry*. *Dev Biol* 216:182–194 (1999).
- Nicholl RM, Grimsley L, Butler L, Palmer RW, Rees HC, et al: Trisomy 22 and intersex. *Arch Dis Child Fetal Neonatal Ed* 71:F57–F58 (1994).
- Ortenberg J, Oddoux C, Craver R, McElreavey K, Salas-Cortes L, et al: *SRY* gene expression in the ovotestes of XX true hermaphrodites. *J Urol* 167:1828–1831 (2002).
- Ottolenghi C, Pelosi E, Tran J, Colombino M, Douglass E, et al: Loss of *Wnt4* and *Foxl2* leads to female-to-male sex reversal extending to germ cells. *Hum Mol Genet* 16:2795–2804 (2007).
- Parma P, Radi O, Vidal V, Chaboissier MC, Delambra E, et al: R-spondin1 is essential in sex determination, skin differentiation and malignancy. *Nat Genet* 38:1304–1309 (2006).
- Philibert P, Bignon-Laubert A, Rouzier R, Pienkowski C, Paris F, et al: Identification and functional analysis of a new *WNT4* gene mutation among 28 adolescent girls with primary amenorrhea and müllerian duct abnormalities: a French collaborative study. *J Clin Endocrinol Metab* 93:895–900 (2008).
- Pingault V, Bodereau V, Baral V, Marcos S, Watanabe Y, et al: Loss-of-function mutations in *SOX10* cause Kallmann syndrome with deafness. *Am J Hum Genet* 92:707–724 (2013).
- Polanco JC, Wilhelm D, Davidson TL, Knight D, Koopman P: *Sox10* gain-of-function causes XX sex reversal in mice: implications for human 22q-linked disorders of sex development. *Hum Mol Genet* 19:506–516 (2010).
- Quinn A, Koopman P: The molecular genetics of sex determination and sex reversal in mammals. *Semin Reprod Med* 30:351–363 (2012).
- Rey RA: Mini-puberty and true puberty: differences in testicular function. *Ann Endocrinol (Paris)* 75:58–63 (2014).
- Rey RA, Grinspon RP: Normal male sexual differentiation and aetiology of disorders of sex development. *Best Pract Res Clin Endocrinol Metab* 25:221–238 (2011).
- Rey RA, Belville C, Nihoul-Fékété C, Michel-Calemard L, Forest MG, et al: Evaluation of gonadal function in 107 intersex patients by means of serum antimüllerian hormone measurement. *J Clin Endocrinol Metab* 84:627–631 (1999).
- Rossi E, Radi O, De Lorenzi L, Vetro A, Groppetti D, et al: *SOX9* duplications are a relevant cause of *SRY*-negative XX sex reversal dogs. *PLoS One* 9:e101244 (2014).
- Seeherunvong T, Perera EM, Bao Y, Benke PJ, Benigno A, et al: 46,XX sex reversal with partial duplication of chromosome arm 22q. *Am J Med Genet* 127A:149–151 (2004).
- Sekido R, Lovell-Badge R: Sex determination involves synergistic action of *SRY* and *SF1* on a specific *Sox9* enhancer. *Nature* 453:930–934 (2008).
- Sutton E, Hughes J, White S, Sekido R, Tan J, et al: Identification of *SOX3* as an XX male sex reversal gene in mice and humans. *J Clin Invest* 121:328–341 (2011).
- Suzuki H, Kanai-Azuma M, Kanai Y: From sex determination to initial folliculogenesis in mammalian ovaries: morphogenetic waves along the anteroposterior and dorsoventral axes. *Sex Dev* 9:190–204 (2015).
- Tomaselli S, Megiorni F, De Bernardo C, Felici A, Marrocco G, et al: Syndromic true hermaphroditism due to an R-spondin1 (*RSPO1*) homozygous mutation. *Hum Mutat* 29:220–226 (2008).
- Uhlenhaut NH, Jakob S, Anlag K, Eisenberger T, Sekido R, et al: Somatic sex reprogramming of adult ovaries to testes by *FOXL2* ablation. *Cell* 139:1130–1142 (2009).
- Vainio S, Heikkilä M, Kispert A, Chin N, McMahon AP: Female development in mammals is regulated by *WNT-4* signalling. *Nature* 397:405–409 (1999).
- Verkauskas G, Jaubert F, Lortat-Jacob S, Malan V, Thibaud E, Nihoul-Fékété C: The long-term followup of 33 cases of true hermaphroditism: a 40-year experience with conservative gonadal surgery. *J Urol* 177:726–731 (2007).
- Vetro A, Ciccone R, Giorda R, Patricelli MG, Della ME, et al: XX males *SRY* negative: A confirmed cause of infertility. *J Med Genet* 48:710–712 (2011).

- Vetro A, Dehghani MR, Kraoua L, Giorda R, Beri S, et al: Testis development in the absence of SRY: chromosomal rearrangements at *SOX9* and *SOX3*. *Eur J Hum Genet* 23:1025–1032 (2015).
- Vidal VP, Chaboissier MC, de Rooij DG, Schedl A: *Sox9* induces testis development in XX transgenic mice. *Nat Genet* 28:216–217 (2001).
- Vorona E, Zitzmann M, Gromoll J, Schüring AN, Nieschlag E: Clinical, endocrinological, and epigenetic features of the 46,XX male syndrome, compared with 47,XXY Klinefelter patients. *J Clin Endocrinol Metab* 92:3458–3465 (2007).
- Wagner T, Wirth J, Meyer J, Zabel B, Held M, et al: Autosomal sex reversal and campomelic dysplasia are caused by mutations in and around the SRY-related gene *SOX9*. *Cell* 79:1111–1120 (1994).
- Weiss J, Meeks JJ, Hurley L, Raverot G, Frassetto A, Jameson JL: *Sox3* is required for gonadal function, but not sex determination, in males and females. *Mol Cell Biol* 23:8084–8091 (2003).
- Wiersma R, Ramdial PK: The gonads of 111 South African patients with ovotesticular disorder of sex differentiation. *J Pediatr Surg* 44:556–560 (2009).
- Xiao B, Ji X, Xing Y, Chen YW, Tao J: A rare case of 46,XX SRY-negative male with ~74-kb duplication in a region upstream of *SOX9*. *Eur J Med Genet* 56:695–698 (2013).
- Zhao L, Svingen T, Ng ET, Koopman P: Female-to-male sex reversal in mice caused by transgenic overexpression of *Dmrt1*. *Development* 142:1083–1088 (2015).