Exp. Eye Res. (2002) **75**, 731–744
doi:10.1006/exer.2002.2055, available online at http://www.idealibrary.com on IDEAL®

Histology, Histochemistry and Fine Structure of the Lacrimal and Nictitans Gland in the South American Armadillo *Chaetophractus villosus* (Xenarthra, Mammalia)

HERNÁN JAVIER ALDANA MARCOS*, CARINA CINTIA FERRARI, CLAUDIO CERVINO AND JORGE MARIO AFFANNI

[a]*Instituto de Neurociencia (INEUCI-CONICET), Universidad de Buenos Aires, Argentina and* [b]*Cátedra de Histología, Cátedra de Fisiología. Facultad de Medicina, Universidad de Morón, Argentina*

(*Received 19 February 2002 and accepted in revised form 29 July 2002*)

The anatomical, histological, histochemical and ultrastructural characteristics of the lacrimal gland (LG) and nictitans gland (NG) of the armadillo *Chaetophractus villosus* were described. The histochemical and histological features of both glands in male and female adult animals were compared. The tissues were processed with conventional techniques for light and transmission electron microscopy. Fixed specimens were submitted to a battery of tests for glycans, glycosaminglycans, glycoconjugates, proteins, and lipids. The LG of the armadillo may be considered within the set of *glandulae lacrimales superior* in which primates, carnivores, perisodactyls and artiodactyls are included. The localization of the NG was similar to that of other mammals. Lacrimal and NG were histologically and histochemically identical. The secretory endpieces consisted of three cell types: (1) Mucous cells (MC) with different types of mucous secretory granules with neutral and sialic acid-containing glycoconjugates (GCs). (2) Seromucous cells (SMC) showing a variety of moderately electron dense secretory granules with flocculent material with carboxylated acidic, neutral, and sialic acid-containing GCs. Intercellular canaliculi with junctional complexes and basolateral intercellular spaces were frequent. (3) Serous cells (SC) with electron dense secretory granules. Histochemically, they showed the strongest reaction for proteins and neutral, weakly acid and carboxylated acidic GCs.

The epithelium of the intra- and inter-lobular excretory ducts showed secretory activity, junctional complexes, and wide basolateral intercellular spaces with lateral folds. The endpieces and ducts were surrounded by myoepithelial cells. The stroma was characterized by fenestrated endothelium, unmyelinated axons, and abundant plasma cells. MC, SMC, and the duct system were richly innervated by hypolemmal nerve terminals.

Key words: ocular glands; lacrimal gland; nictitans gland; comparative study; accessory lacrimal gland; ultrastructure; histochemistry.

1. Introduction

The subconjunctival glands are distributed as two groups of major exocrine glands. One group, situated in the inner canthus, includes the Harderian gland (HG) and the nictitans gland (NG) (Sakai, 1981, 1989, 1992, Payne, 1994). The other consists of what generally is regarded as the lacrimal gland (LG), and is located in the outer canthus (Sakai, 1989, 1992).

The LG are compound-branched tubulo-acinar glands. Their secretion is usually mucoserous in Artiodactyla, Carnivora, Insectivora, Lagomorpha, Perissodactyla, Primates, and Rodentia (Prince et al., 1960; Kühnel, 1968a,b,c,d,e; Martin et al., 1988; Sakai, 1989; Iwamoto and Jakobiec, 1990; Sullivan et al., 1996).

The main LG function is the production of the aqueous layer, the thickest and major constituent of the precorneal tear film (Iwamoto and Jakobiec, 1990; Stein and Hurwitz, 1996). It also participates in the production of a component of the mucin layer of that film (Steuhl, 1989; Arango et al., 2001), which plays an essential role in maintaining the normal corneal, as well as the optical, integrity of the eye (Stein and Hurwitz, 1996). The LG also has an important function in the defense system of the ocular surface, forming a part of the conjunctival-associated lymphoid tissue (Obata et al., 1995).

The NG (membrana NG, third eyelid gland) was considered an ectopic or accessory LG (Sakai, 1981). Its presence was reported in Artiodactyla, Carnivora, Insectivora, Lagomorpha, Marsupials, Perissodactyla and Primates (Loewenthal, 1892a,b, 1896; Prince et al., 1960; Jarial and Jen, 1979; Sakai, 1981; Sakai and van Lennep, 1984; Martin et al., 1988; Hraste et al., 1995). The canine NG has been estimated to produce 29–57% of the aqueous layer of the precorneal tear film (Helper et al., 1974).

As far as we are able to ascertain, the LG and NG have not been described in the Order Xenarthra. This mammalian Order is a small but morphologically

* Address correspondence to: H. J. Aldana Marcos, Laboratorio de Histología, Facultad de Medicina, Universidad de Morón, Machado 914, (1708) Morón, Argentina. E-mail: haldana@unimoron.edu.ar

0014-4835/02/$35.00/0

varied Neotropical group of 14 genera and 30 species (Wetzel, 1985). Its living representatives are armadillos, sloths, and ant-eaters. The Xenarthra are eutherians, but they retain a number of primitive mammalian characters and lack derived features present in other placental mammals (Eisenberg, 1981). Molecular studies indicate that Xenarthra diverged from other eutherians nearly at the same time as the marsupial-eutherians split occurred (Engelman, 1985; Novacek, 1994). That is why some authors (Mc Kenna, 1975; Novacek, 1994) suggested that xenarthrans represent the sister-group to all other placental mammals.

Structural and ultrastructural studies of mammalian periorbital glands of those taxonomic groups possessing the three principal periocular glands appear especially interesting. These studies might be helpful in determining inter-relationships, similarities and differences between the orbital glands. The aim of this paper is to describe the macroscopic, microscopic and ultrastructural features of the LG and NG of the South American armadillo *Chaetophractus villosus*. This is the first study of such organs in a Xenarthran species.

2. Materials and Methods

Thirty adult armadillos *Chaetophractus villosus* (Dasypodidae, Xenarthra) (18 males and 12 females) were used. Their weight ranged from 3·5 to 5 kg. They were housed in individual cages, received tap water and Purina dog chow ad libitum, and were subjected to a 0012 hr light-cycle with lights on at 0700 hr. Previously they were adapted to captivity for 30 days. The animals were killed during spring, summer, autumn, and winter. All procedures had the relevance clearance from the local ethical committee for the use of animal experiments.

Histology

Under anaesthesia with ketamine hydrochloride (40 mg kg^{-1}, i.m.) and sodium thiopental (60 mg kg^{-1}, i.p.), the animals were perfused with saline followed by fixative via the ascending aorta. Bouin's fluid and neutral buffered saline formalin were used as fixatives for routine microscopical studies. The LG and NG of some animals were dissected and fixed by immersion in those fixatives. Serial transversal, sagittal or horizontal paraffin sections (8 μm) were cut throughout the entire orbital contents. Tissues were stained with haematoxylin and eosin, Masson trichrome and Holme's technique.

Histochemistry

The histochemical characterization of glycans, glycoconjugates (GCs) and glycosaminoglycans (GAGs) was performed with tissues fixed in neutral buffered saline formalin. Tissues were embedded in paraffin and sectioned at 8 μm. We follow the carbohydrate terminology of Pearse (1985) and Spicer and Schulte (1992).

The periodic acid-Schiff (PAS) method was used for the identification of glycans and GCs containing hydroxyl groups occurring in glycogen and neutral or weakly acidic glycoproteins (Pearse, 1985). The possibility of the PAS reaction being blocked by acetyl groups (O-acetyl esters) in the 7th, 8th and 9th carbon of the sialic acid residues or in the 1–2 glycol groups of the neutral sugars was eliminated by removing them with KOH (saponification) (Culling et al., 1974). We did not accept the specificity of the PAS reaction for detection of carbohydrates without qualification. We looked for glycolipids, phospholipids, and ethylenic linkages of unsaturated lipids to discount the presence of PAS reactive aldehyde groups in those substances. For that purpose, we employed the following methods: (1) the modified Bruckner reaction for glycolipids (Pearse, 1985); (2) the copper phtalocyanin method for phospholipids and glycolipids (Pearse, 1985) and (3) bromination prior to the PAS reaction for ethylenic linkages in unsaturated lipids (Cohn, 1955).

PAS after diastase digestion was used for glycogen. Sialic acid in GCs was detected using a low concentration of periodic acid according to Volz's method (Volz et al., 1987a). Neutral GCs were demonstrated by blocking any presence of sialic acid residues with the modified PAS method (Volz et al., 1987b). Simultaneous demonstration of acidic and neutral GCs and GAGs was accomplished using the Alcian blue 8GX (AB)-PAS method. AB at pH 2·5 was used for simultaneously testing of sulfate esters and carboxyl groups in GCs and GAGs, and AB at pH 0·5 for the characterization of sulfated GCs and GAGs (Spicer and Schulte, 1992).

Proteins were tested with the mercury-bromophenol blue method (Pearse, 1985).

Lipids were studied in tissues fixed in Baker's formalin-calcium. Frozen sections were stained with Sudan III in propilenglycol (Sheehan and Hrapchak, 1980), and Nile blue sulfate (Pearse, 1985).

In most instances the histochemical reactions were validated by their positive reactions in tissues known to contain the particular substance.

Ultrastructure

Seven adult armadillos *Chaetophractus villosus* (four females, three males), weighing between 3·5 and 5 kg, were anaesthetized. The LG and NG were fixed by perfusion through the thoracic aorta with a modified saline solution (0·8 % NaCl, 0·8 % sucrose, 0·4 % glucose), followed by 2 l of 2 % glutaraldehyde fixative in 0·1 M Na-cacodylate buffer, pH 7·2. Small pieces of LG and NG, dissected under cold fixative, were fixed for 4 hr in the same fixative. The tissues were stored

overnight in the same buffer with 0·2 M sucrose. Following three 5 min washes in the buffer, they were post-fixed for 1 hr in 1 % O_sO_4 in the same buffer, at a pH of 7·2, washed as previously, dehydrated through an ethanol series, cleared in acetone, and infiltrated with Araldite. Ultrathin sections were stained with uranyl acetate and lead citrate and observed in a Siemens ELMISKOP I or Zeizz M-109 turbo electron microscope. Semithin sections (about 1 μm thick) were stained with toluidine blue for light microscopy.

3. Results

The LG is located in the posterolateral and external portion of the bony orbit (Fig. 1). Its approximate dimensions are 0·5 cm in length and 14 mm in width. The long axis runs in an mediolateral direction. The mean weight of each gland was 133·7 ± 24 mg ± S.D.; $N = 15$. There was no statistically significant difference in the weight between sexes. The LG is distinctly lobulated (Fig. 2(a) and (b)) and appears homogeneous in colour (pink) and texture.

The NG is located in the anterolateral and external portion of the bony orbit (Fig. 1). It has several lobes.

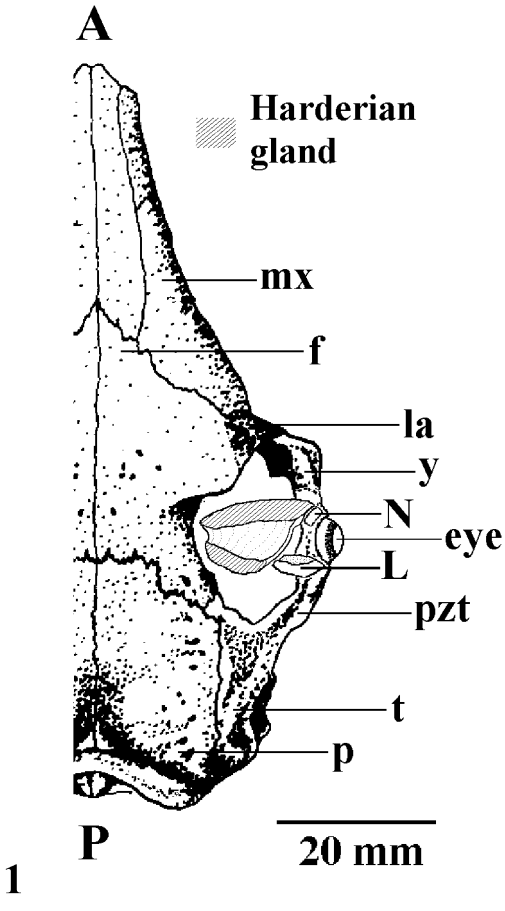

FIG. 1. Schematic representation of the dorsal view of the skull of the armadillo *Ch. Villosus* showing the position of the ocular glands. A, anterior; L, lacrimal gland; N, nictitans gland; P, posterior. Bones: f, frontal; mx, maxilla; la, lacrimal; y, jugal; pzt, zygomatic process of the temporal; t, temporal; p, parietal.

Most of them are closely wrapped around the posterior extension of the cartilaginous shaft of the nictitating membrane (Fig. 2(a), (b) and (c)). Others are located near the anterior extension of the HG, far from the cartilage. However, it is clearly separated from the HG by connective tissue septae. Owing to its non-circumscribed character, the weight is highly variable, being approximately of 11·25 mg for each gland. Similar to LG, NG is homogeneous in colour (pink) and texture.

LG and NG tissues exhibit identical structural, ultrastructural, and histochemical characteristics. Therefore, our description applies to both glands. There are no obvious differences between males and females, and none between the different seasons of the year in both glands.

They are compound branched tubulo-acinar mixed glands (Fig. 3).

Endpieces

The tubulo-acini are composed of a monolayer of columnar or truncated-conical secretory cells surrounded by a discontinuous layer of flattened myoepithelial cells. Three cell types can be distinguished according to morphologic and histochemical characteristics: (1) mucous cells (MC); (2) seromucous cells (SMC) and (3) serous cells (SC). They are clearly discernible in semithin sections (Fig. 3) and with electron microscopy. The branched tubulo-acini are predominantly lined by MC, but the SMC forms small acini with a very narrow lumen near the end. Moreover, it is common to find endpieces entirely lined by SMC. The SC appear randomly located between MC and SMC (Fig. 3).

Secretory Cells

(1) The MC are columnar with a basally located oval or flattened nucleus. These cells are characterized by an apical cytoplasm filled with large, closely packed and ill-defined secretory granules (Fig. 3). Usually, three distinct types of reactive mucous granules are seen to coexist within the same cell at the electron microscopy level: electron-lucent granules (ELG); electron dense granules of low density (LEG), and moderately electron dense granules (MDG). All types of granules are sometimes singly distributed and appear as discrete, rounded and membrane bounded profiles (Fig. 4(a) and (b)). Their contents appear to be either homogeneous or finely granular. However, the ELG exhibit signs of extensive coalescence becoming fused into a single, large confluent secretory mass (Fig. 4(a)). The Golgi apparatus is predominantly observed in the apical and middle portions, generally associated with putative ELG, LEG and MDG immature secretory granules. Secretory

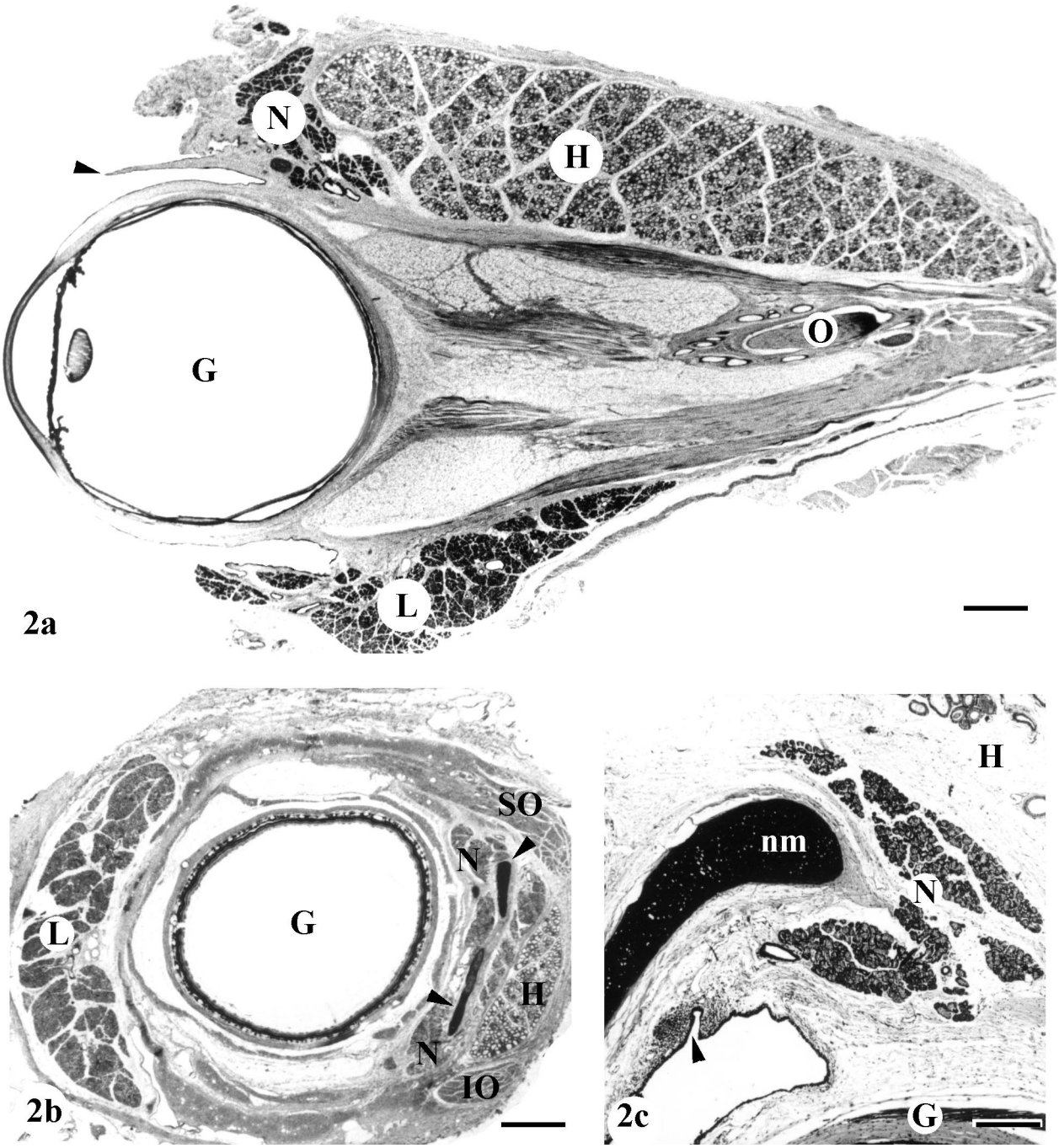

FIG. 2. Light micrographs of the eye of *Ch. villosus* and surrounding orbital contents. Haematoxylin and eosin. (a) Horizontal section including on the medial (nasal) side the Harderian gland (H) and the nictitans gland (N), and on the lateral (external) side the lacrimal gland (L). G, ocular globe; O, optic nerve; nictitating membrane (arrowhead). Bar = 1·23 mm. (b) Transverse section including the lacrimal gland (L), the nictitans gland (N) and the Harderian gland (H). IO, SO, inferior and superior obliques muscles; G, ocular globe; cartilage of the nictitating membrane (arrowhead). Bar = 1·35 mm. (c) Longitudinal section showing the anterolateral portion of the orbit. Note the close relationship of the nictitans gland (N) to the posterior extent of the cartilaginous shaft of the nictitating membrane (nm). The arrowhead points to the end of the excretory duct, associated with lymphatic nodules, in the concave internal surface of the nictitating membrane in the tarsal conjunctiva. G, ocular globe; H, Harderian gland. Bar = 0·19 mm.

granules appear to be discharged by a typical merocrine mechanism (Fig. 4(c)). The glandular lumen is entirely filled with material similar in electron density to the ELG. Intact rounded masses without limiting membranes with similar contents to those found in the LEG and MDG can also be seen in the lumen (Fig. 4(d)). The basal region contains sparse specific granules and flattened cisternae of rough endoplasmic reticulum (RER), which tend to be arranged in parallel stacks (Fig. 4(a)). Some cells contain dilated cisternae of RER filled with light, structureless material (Fig. 4(b)). Free ribosomes,

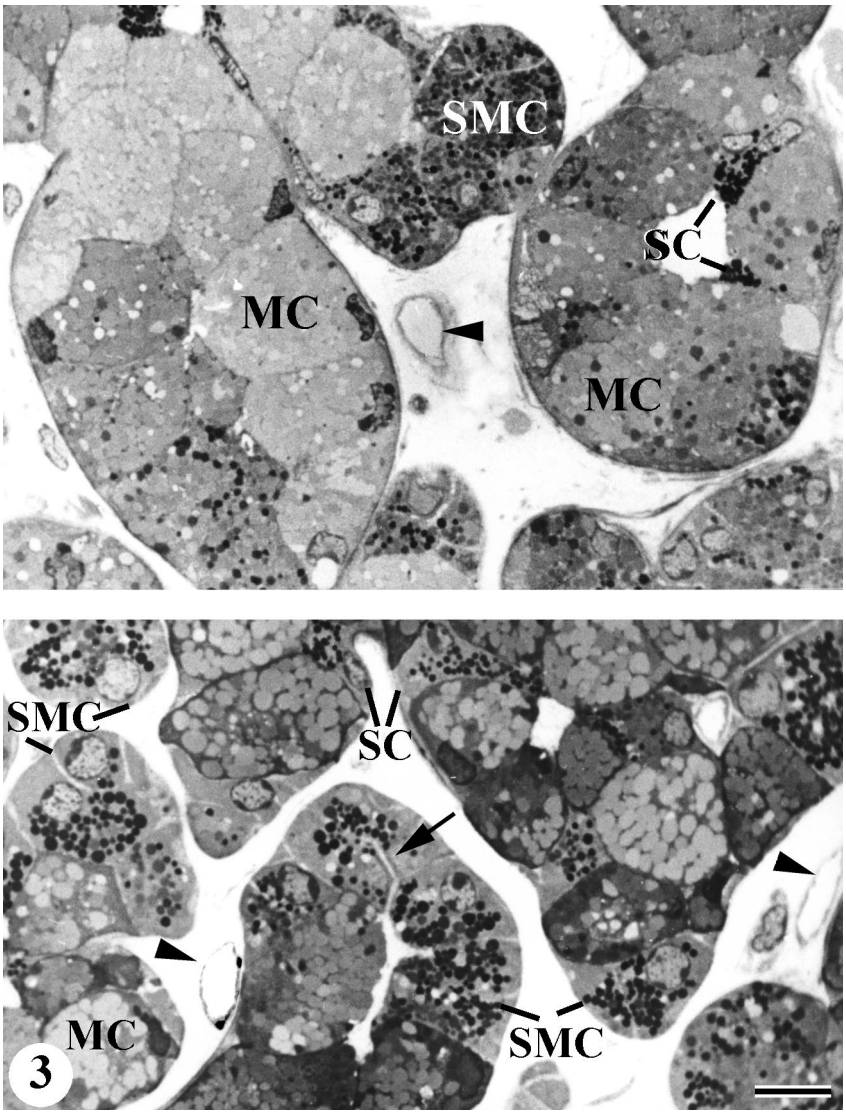

FIG. 3. Photomicrographs of epoxy-embedded lacrimal (upper) and nictitans (bottom) glands. Note the similar histological organization of both glands with branched tubulo-acinar mixed secretory endpieces containing mucous cells (MC), seromucous cells (SMC) and serous cells (SC). The presence of intercellular canaliculus (arrow) between seromucous cells can be seen. Capillaries (arrowheads). Toluidine blue. Bar = 11 μm.

tubular mitochondria, some tubules and vesicles of the RER lie between the secretory granules. The luminal surface is lined with short microvilli. Laterally the plasmalemma is joined to adjacent cells by typical junctional complexes.

Histochemical staining methods reveal (Table I) the presence of neutral and sialic acid containing GCs, although some cells without reaction can be seen between the MC (Figs. 5 and 6). PAS-reactive material is also present in the tubulo-acinar lumina forming vacuolated clumps, which react moderately or intensely to the Schiff reagent. The different reactions for protein moieties show a weakly positive reaction.

(2) The SMC are pyramidal and smaller than the MC. They are characterized by a large round or irregularly shaped nucleus basally located and deep blue stained apical secretory granules (Fig. 3). They are also characterized by the presence of wide intercellular spaces. At the ultrastructural level, the secretory granules are round, membrane bounded and tend to be separated (Fig. 7). These granules have flocculent aggregates of varied appearance and electron density. Within the same cell we have seen transitions in the electron density of the flocculent material. Low electron dense granules appear intimately associated with the Golgi apparatus, whereas, most electron dense granules occupy the apical region (Fig. 7). Secretory granules appear to be discharged by a typical merocrine mechanism. Large amounts of RER are spread throughout the cytoplasm with scarce tubular mitochondria. The apical membrane, in close apposition to typical junctional complexes, borders a small lumen lined with small microvilli. Intercellular canaliculi with junctional

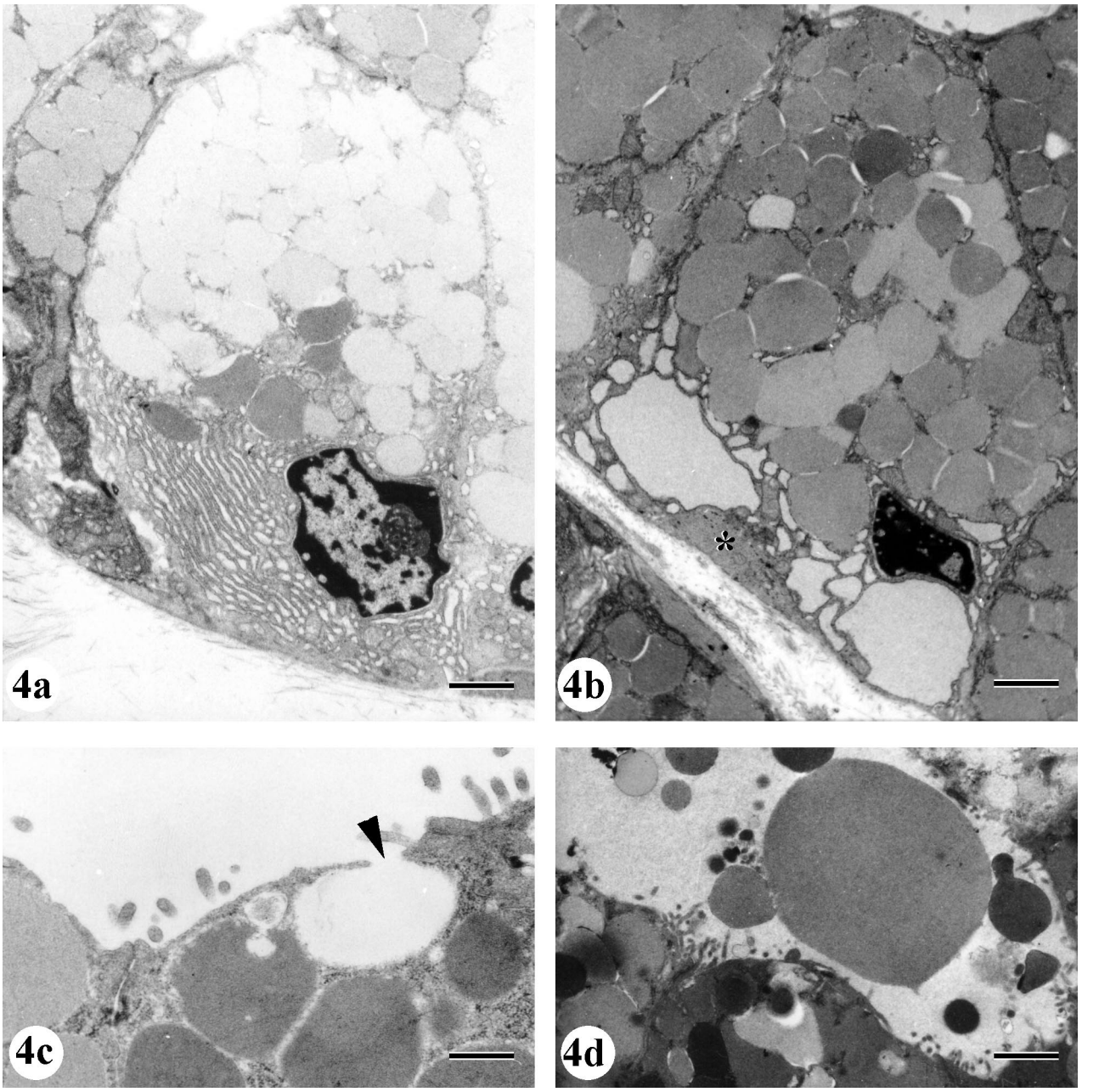

FIG. 4. Survey electron micrograph of (a) LG mucous cell. Note the presence of electron-lucent and moderate electron dense secretory granules and a highly developed RER situated mainly in the basal cytoplasm. Bar = 2 μm. (b) Survey electron micrograph of LG mucous cell with dilated cisterns of RER. The heterogeneous secretory granules appear composed of materials with different electron densities. A myoepithelial cell is present at the base of the secretory cell (*). Bar = 2·2 μm. (c) A typical baylike indentation (arrowhead) of the luminal surface of the LG mucous secretory cell represents the remains of a discharged secretory granule by a merocrine mechanism. Bar = 0·65 μm. (d) An acinar lumen of LG mucous acini replete with electron lucent secretory material and intact low and moderate electron dense rounded masses without limiting membranes, representing exocytosed mucous granules. Bar = 1·67 μm.

complexes (Figs. 3 and 7) and intercellular space with lateral folds are commonly observed between adjacent epithelial cells (Fig. 7).

Histochemically (Table I), SMC react more strongly than MC with PAS reaction (Fig. 5). The modified PAS reaction for neutral sugars and for sialic acid shows the same pattern than the PAS reaction with normal oxidation. The staining with AB at pH 2·5 shows a strong alcianophilia in the SMC (Fig. 6). A few SMC show no reaction. The AB positive reaction at pH 2·5 and the negative reaction at pH 0·5 suggest the carboxylic nature of the acidic GCs and GAGs in the SMC. The combined AB-PAS technique shows glandular cells with acidic GCs and GAGs (blue cells), cells with neutral and weakly acidic GCs (bright-rose cells) and cells with acidic and neutral GCs and GAGs (purple-blue cells). The SMC show strongly positive reaction for proteins.

(3) The SC shows the same morphologic and histochemical characteristics of the ductular epithelium.

TABLE I

Histochemistry of the lacrimal and nictitans gland of the armadillo Ch. villosus

	Secretory cells			
	MC	SMC	SC	Duct cells
GCs and GAGs				
PAS	+	+++	++++	++++
Koh-PAS (saponification)	+	+++	++++	++++
PAS-without prior oxidation	–	–	–	–
Diastase-PAS	+	+++	++++	++++
Bromination prior to PAS	+	+++	++++	++++
PAS for sialic acid detection	+	++	++++	++++
PAS for neutral GCs detection	+	++	++++	++++
AB-PAS	R	B/R/P	P	P
AB pH 2·5	–	B	B	B
AB pH 0·5	–	–	–	–
Proteins				
Mercury-bromophenol blue method	+	++	++++	++++

However, serial sections indicate that these cells are separated from the ductal system. In semithin sections, SC contain heavily blue stained secretory granules. They are oval or round in shape, discrete and smaller than the secretory granules described in the SMC (Fig. 3). At the ultrastructural level, the secretory granules appear as only one type with homogeneous and finely granular material. Most of the granules are highly electron dense (Fig. 8). However, varying degrees of electron density are observed. The Golgi apparatus is limited to the apical region. Association between the Golgi apparatus and putative immature secretory granules can be seen. Free ribosomes, tubular mitochondria, RER tubules lie between the secretory granules. The luminal surface is lined with microvilli. The apices are held in close apposition by typical junctional complex. Lateral cell membranes show elaborate infoldings with lateral folds (Fig. 8).

Histochemically (Table I), SC show the strongest reaction for neutral and weakly acid GCs (Fig. 5(b)).

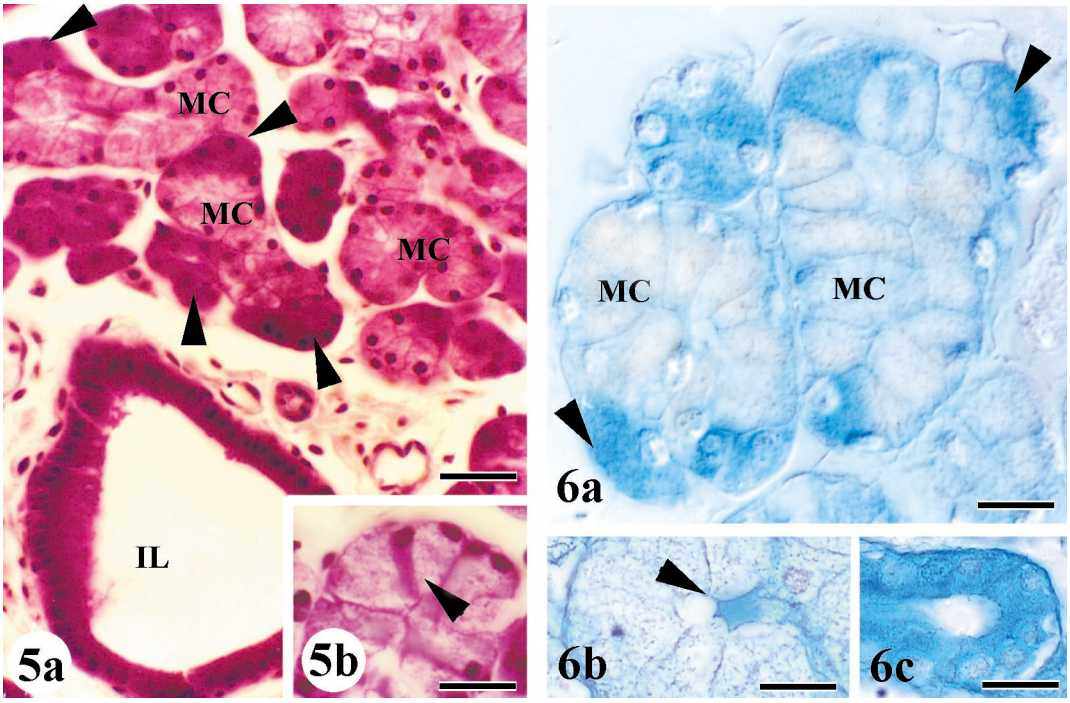

FIG. 5. (a) Section of LG showing the different PAS reactivities of mucous (MC) and seromucous (arrowhead) cells. The interlobular duct cells (IL) react strongly to PAS staining. Bar = 31·4 μm. (b) A strongly PAS stained serous cell (arrowhead) appears between mucous cells in the glandular acini. Bar = 18 μm.

FIG. 6. Alcian blue pH 2·5 reaction. (a) Positive staining of seromucous cells (arrowheads) and no staining in mucous cells (MC). (b) An Alcian blue positive serous cell between mucous cells can be seen. (c) The apical region of the intercalated duct cells appears positively stained. Bar = 15 μm.

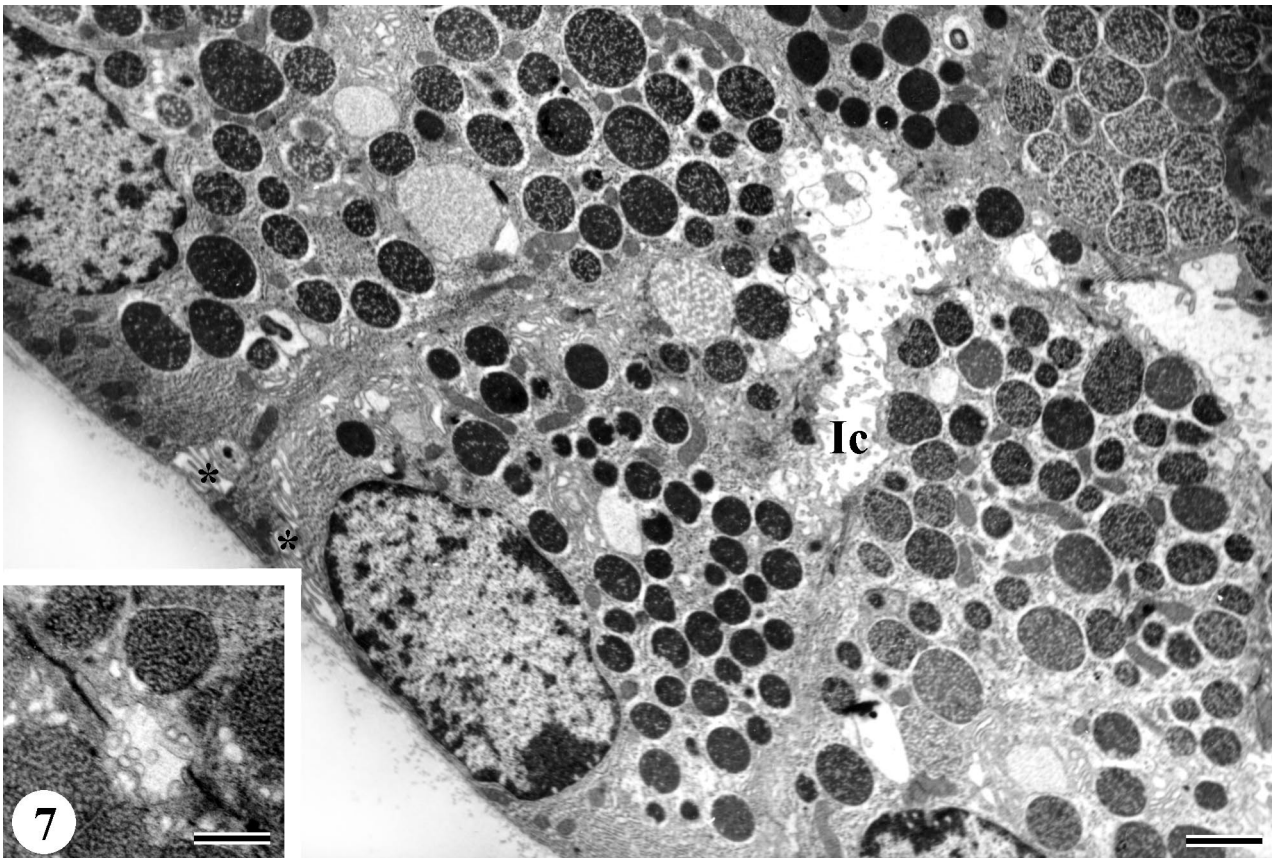

FIG. 7. Survey electron micrograph of several NG seromucous cells. The cytoplasm shows numerous secretory granules with flocculent aggregates of varied appearance and electron density. The basolateral cell membranes show intercellular spaces with lateral folds (*), and intercellular canaliculi (Ic) are common. Bar = 1·7 μm. Inset: seromucous cells of LG bordering a transversally sectioned intercellular canaliculus with microvilli. Note that it is flanked by junctional complexes. Bar = 1·7 μm.

They also show fairly uniform staining with AB pH 2·5 (Fig. 6(b)) and negative staining with AB pH 0·5 that indicate the presence of carboxylated acidic GCs. The combined AB-PAS technique shows that these cells contain acidic and neutral GCs and GAGs (purple-blue cells). The secretory granules are rich in proteins.

Myoepithelial Cells

Typical myoepithelial cells are found between secretory cells and the basal lamina. They are stellate with several processes extending in all directions and embracing the tubulo-acini (Fig. 9(a)). Many processes project to neighbouring endpieces and are in contact with other myoepithelial cells.

Duct System

The intercalated or intralobular ducts start in the tubulo-acini. They are lined by a single layer of cuboidal to columnar epithelial cells (Fig. 10). These cells are morphologically and histochemically similar to SC (Figs. 6(c) and 13). The ductal cells are joined by apical junctional complexes and lack intercellular canaliculi. The intercalated ducts form interlobular ducts. These ducts have the same type of epithelial cells (Fig. 11). They differ from the previous ones by having moderate electron dense secretory granules, wider lumina, and more abundant interlobular connective tissue (Figs. 11 and 14). Both intra- and inter-lobular ducts have myoepithelial cells sandwiched between the base of the epithelial cells and the basal lamina. In contrast to the stellate myoepithelial cells in glandular endpieces, the majority of the myoepithelial cells in the duct system are fusiform. They are longitudinally oriented and arranged in parallel to one another in close proximity (Fig. 9(b) and (c)), their processes sometimes being branched. The interlobular ducts come together to form the main excretory ducts situated in the interlobar connective tissue. They are lined by a simple columnar or pseudostratified epithelium, which consists mainly of columnar cells with sparse secretory granules apically located (Fig. 12). Tubular glands lined by SC are associated with excretory ducts (Fig. 12). They are more developed in the transitional area between interlobular and excretory ducts.

The LG excretory ducts are about 16 in number and most of them open between lymphatic nodules into the conjunctival sac near the lateral canthus or even above it, in the superotemporal portion of the forniceal

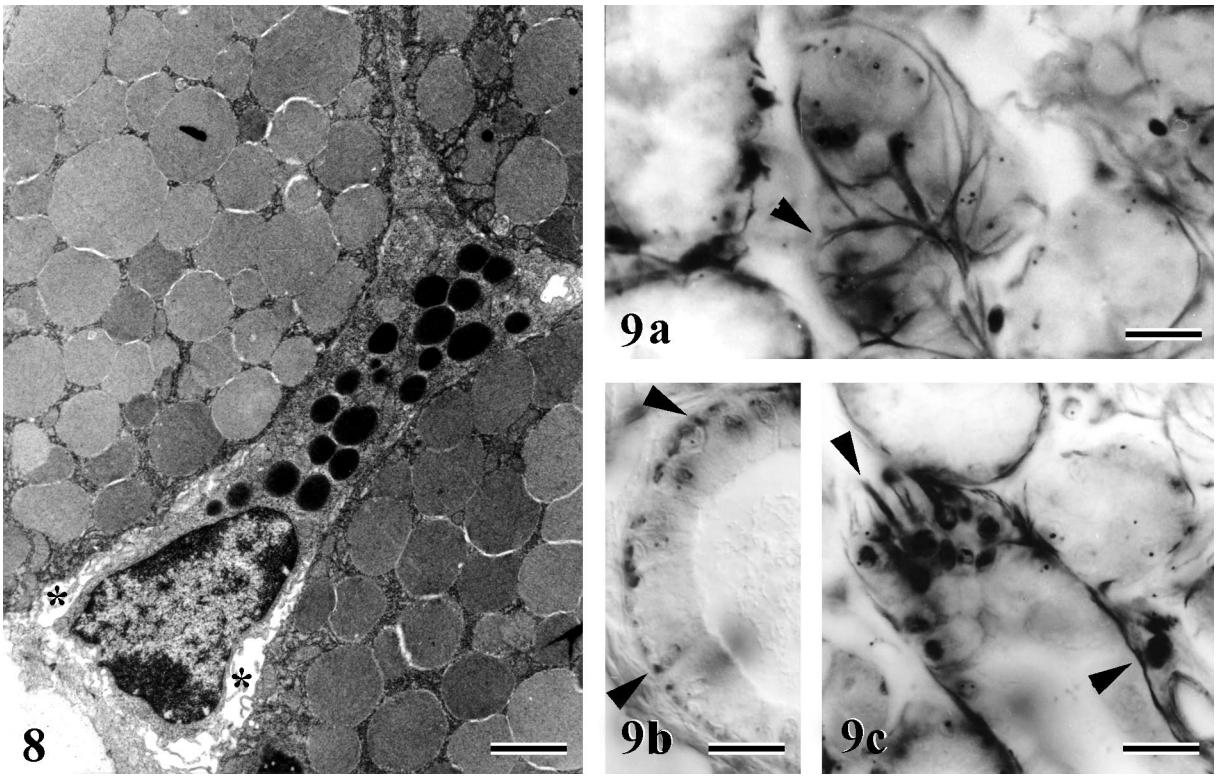

FIG. 8. Survey electron micrograph of LG serous cell in close relation to three mucous cells. Note the presence of apically located highly electron dense secretory granules and basolateral spaces with lateral folds (*). Bar = 1·5 μm.

FIG. 9. Myoepithelial cells of LG stained with Holme's method. Bar = 10 μm. (a) Stellate myoepithelial cell embracing the tubulo-acini. Note that cell processes can extend to neighboring endpieces (arrowhead). (b) Transverse section of the interlobular duct with longitudinally-oriented myoepithelial cell processes (arrowheads). (c) Obliquely-sectioned intercalated duct that clearly shows the longitudinal orientation of myoepithelial cells (arrowheads).

conjunctiva. The lobules of the NG, including those located in the palpebral side of the nictitating membrane, convey the secretion onto the concave internal surface of the nictitating membrane in the tarsal conjunctiva (Fig. 2(c)). Some ducts also end in the fornix conjunctiva. There are approximately two to four ducts. All of them open surrounded by lymphatic nodules (Fig. 2(c)).

Stroma

The stroma near the endpieces shows numerous plasma cells, scarce randomly distributed fibroblasts, mast cells, macrophages, and lymphoid cells. Most capillaries found in the connective tissue septa consist of fenestrated endothelium, but occasionally, some attenuated and non-fenestrated endothelium is also present. The interlobular and excretory ducts possess a rich fenestrated capillary network (Figs. 11 and 14).

Unmyelinated axons profiles are present in the interstitial connective tissue around the LG and NG endpieces. Most of the axons are located in the interspace between the basal halves of the secretory cells and have clear synaptic vesicles; a smaller number of larger, dense-cored vesicles may also be present. The same type of contact is also observed in ductal cells.

4. Discussion

The LG of *Ch. villosus* is close to the outer canthus in the anterolateral portion of the orbit. The LG may be assigned to the set *glandulae lacrimales superior* because its multiple secretory ducts open into the lateral half of the superior conjunctival sac. This assignment is made according to the criterion that exocrine glands should be identified on the basis of the site of the ductal opening, instead of the gland location (Sakai, 1989). This set includes the LG of primates, carnivores, perisodactyls, and artiodactyls (Prince et al., 1960; Sakai, 1989; Sullivan et al., 1996).

The localization of the armadillo's NG coincides with that of other mammals. It is closely wrapped around the cartilaginous shaft of the nictitating membrane. The number of excretory ducts varies between species. Their excretory ducts open into the nictitating membrane's inner surface. This characteristic has been observed in most of studied mammals (Loewenthal, 1892b, 1896; Prince et al., 1960; Jarial and Jen, 1979; Sakai, 1981; Sakai and van Lennep, 1984; Martin et al., 1988; Hraste et al., 1995). An exception is the NG of the European hedgehog, in which the excretory ducts convey the secretion to the outer surface of the nictitating membrane (Loewenthal, 1892a).

Histology, histochemistry, and electron microscopy did not reveal qualitative differences between the LG and the NG in the armadillo. Similar results were obtained in canines (Martin et al., 1988). Immunohistochemistry, lectin histochemistry, and quantitative histomorphology studies will be required to improve the comparison between LG and NG in armadillos.

The LG is described as a compound tubulo-acinar gland producing a mucous-serous secretion. If we adopt the morphological and histochemical criteria established by some authors (Pinkstaff, 1993; Tandler, 1993; Tandler and Phillips, 1993; Tandler et al., 1994), our armadillos possess three types of glandular cells: MC, SMC and SC. The MC mainly show three types of mucous secretory granules. These might

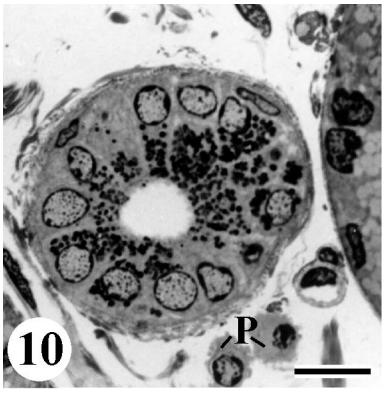

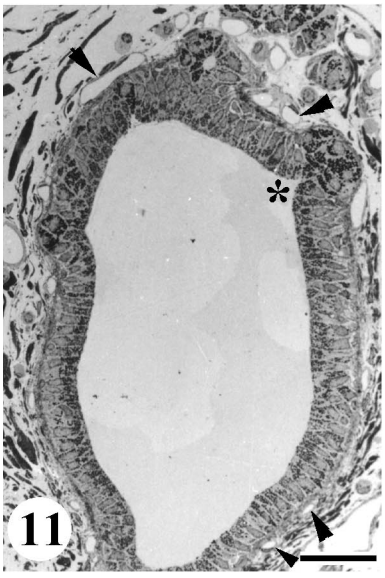

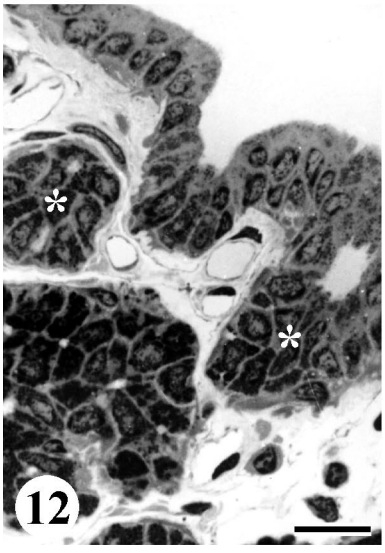

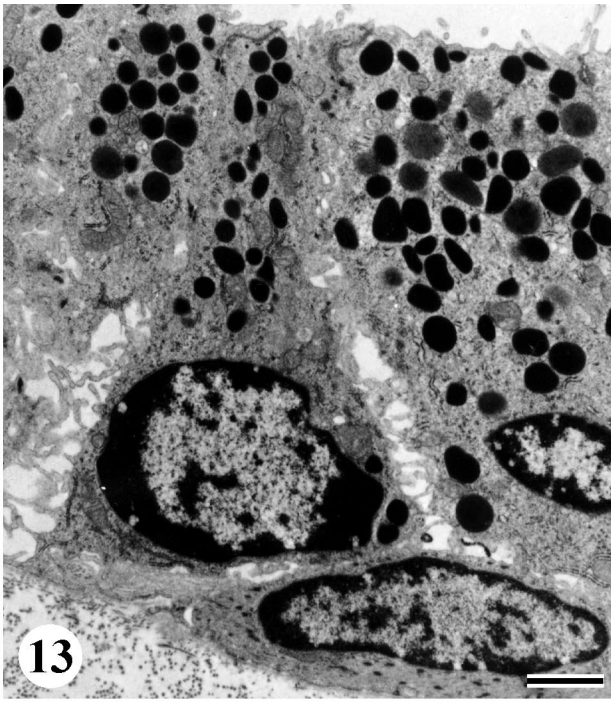

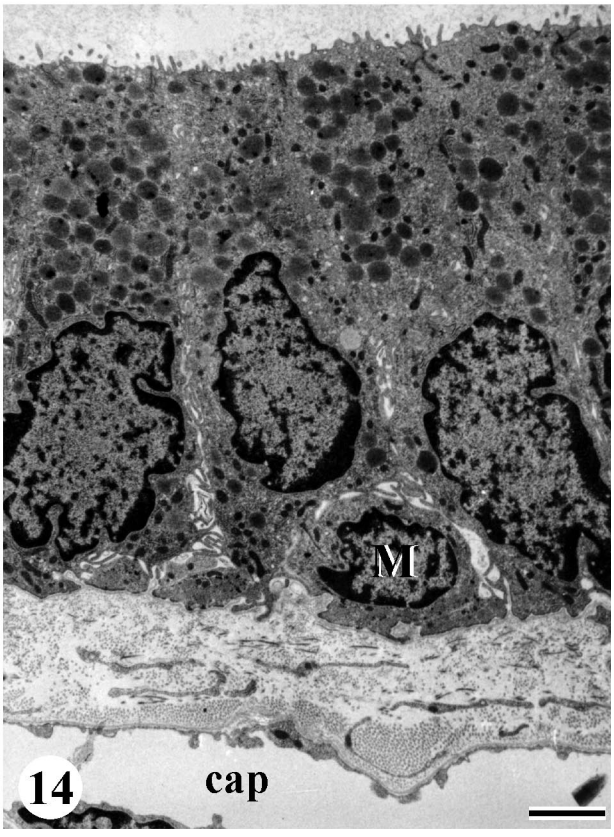

reflect different stages of the secretory cycle or the maturity of individual granules. However, this variability might indicate different secretory products. This hypothesis is supported by our observation of immature secretory granules similar to the mature ones near the Golgi sacs. The presence of three types of secretory material similar to that of secretory granules in the MC apical region and glandular lumen gives further support to the hypothesis.

The SMC have a variety of moderately to highly electron-dense secretory granules with flocculent material. These differences in electron density may be attributed to varying stages of their maturation. Low electron density granules appear intimately associated with the Golgi apparatus. This fact might be interpreted as a storage phase. The increase in electron density of the secretory granules may correspond to condensation and maturation processes (Tandler and Phillips, 1993). Whereas apical granules have the same density in most cells, those from other parts of the cell are extremely variable. This gives further support to our view.

An interesting feature of the LG and NG of *Ch. villosus* is the presence of intercellular canaliculi between the SMC. According to Sakai (1989) true intercellular canaliculi are absent in the LG of eutherian mammals. However, several authors claimed the presence of intercellular canaliculi in LG (Ichikawa and Nakajima, 1962; Kühnel 1968b,c,d; Ruskell, 1975; Iwamoto and Jakobiec, 1990), although not showing convincing morphologic evidence. Our results, as far as we know, provide the first clear demonstration of intercellular canaliculi in the LG. The presence of these structures and basolateral intercellular spaces suggests that the seromucous components of the armadillo LG could be involved in bulk fluid/ion transport similarly to what occurs in salivary glands (Pinkstaff, 1993).

The SC granules match those of exocrine pancreas secretory cells at the light and electron microscopic level. Their concentration of neutral and acidic GCs and proteins is higher than in SMC. This agrees with the presence of more electron dense mature secretory granules in SC. We observed transitions in the electron density of secretory granules in the same way as in SMC. Thus we are inclined to interpret them as different growth stages. SC show the same histochemical and ultrastructural characteristics as ductal cells. However, a serial section analysis indicated that these cells do not belong to the ductal system. Therefore, the existence of a third cellular type must be considered.

Within the limits of our methodology we did not find appreciable difference, if any, neither in the number of mitochondria nor in the pattern of their distribution among the three cell types. Immunohistochemistry, lectin histochemistry, and quantitative histomorphology studies will be required in order to go deeper into this point.

A variety of epithelial glandular cells was described in the mammalian LG (Sakai, 1981). However, it is controversial whether these cell types represent different cells or are only different maturational stages of a single granule type in a single type of secretory cell. Regarding this point, there is evidence suggesting that the rat acinar cells undergo progressive alterations with age. The acinar age changes progress from serous to seromucous acini towards mucous acini (Draper et al., 1999).

In the armadillo *Dasypus novemcinctus*, Weaker (1981) reported the presence of HG located in the medioposterior aspect of the orbit. This gland is divided in two portions, the minor one (the proximal point) contains mucous-secreting acini. The other one (the distal point) contains lipid-secreting acini. Both portions form a single excretory duct, which empties into the fornix of the conjunctiva associated with the nictitating membrane. The glandular cells of the proximal portion are histochemically (PAS positive) and ultrastructurally similar to the MC of the NG or LG in *Chaetophractus*. However, in the latter species the NG and HG are anatomically distinct glands, each one possessing its own secretory duct. Additionally, the HG of *Chaetophractus* possesses tubulo-alveolar endpieces with wide lumina and with lipid contents and secretion by exocytosis (Aldana Marcos et al., 1995; Aldana Marcos, 1996; Cavagnari et al., 1998; 2001). These characteristics are shared with all mammals possessing HG (Sakai, 1981). NG-like tissue mixed with HG was described in hedgehogs, pigs, rabbits

FIG. 10. Photomicrograph of epoxy-embedded intercalated duct of NG. The apical portion of the duct cells contains densely stained secretory granules. P, plasma cells. Bar = 11 μm.

FIG. 11. Semithin epoxy section showing a transversally sectioned NG interlobular duct. Its identification is confirmed by the mantle of surrounding connective tissue and the wider lumina. Note the presence of a rich network of capillaries (arrowheads) and of endpieces lined by serous cells (*). Bar = 32 μm.

FIG. 12. Photomicrograph of a portion of the wall of an excretory duct of LG embedded in epoxy resin. Note the presence of tubular glands lined by serous cells (*). Bar = 11 μm.

FIG. 13. A portion of the wall of an intercalated duct of NG. The cytoplasm of the columnar duct cells shows numerous secretory granules, some of which vary in electron-density. The basolateral membrane shows intercellular spaces with lateral folds. A flat myoepithelial cell is present adjacent to the basement membrane. Bar = 1·46 μm.

FIG. 14. Several LG interlobular duct cells provided with an abundance of medium electron dense secretory granules. The basal portion is in contact with a myoepithelial cell (M). Basolateral membranes shows intercellular spaces. A fenestrated capillary (cap) extends along the bottom of the micrograph. Bar = 2·14 μm.

(Loewenthal, 1892a,b), some marsupials (Sakai and van Lennep, 1984; Krause and McMenamin, 1992), and some rodents (Sakai, 1981; Sakai and Yohro, 1981; Antolin-Gonzalez et al., 1993). However, no studies were performed to demonstrate that this tissue belongs to nictitans endpieces.

LG and NG glandular cells show neutral and weakly acid (carboxylated) GCs and GAGs. The same results were obtained in the most of the species studied (Martin et al., 1988; Sakai, 1989; Millar et al., 1996). The negative staining with alcian blue pH 0·5 indicates the probable absence of sulfated GC and GAGs. However, sulfate uptake in organ cultures and the localisation of sulfated GAGs in human and sheep LG glandular cells was clearly demonstrated (Allen et al., 1972; Yoshida et al., 1996; Gargiulo et al., 2000). This suggests that sulfate masking could explain the absence of sulfate staining (Spicer and Duvenci, 1964). According to Sakai (1989) the PAS and alcian blue pH 2·5 positive LG staining does not necessarily mean that the lacrimal secretion contains mucin. However, according to Steuhl (1989) mucins in the inner mucous layer of the tear film are produced not only by conjunctival goblet cells but also by LG elements. This was clearly demonstrated by Arango et al. (2001) who showed that the rat LG, together with the corneal and conjunctival epithelia, synthesizes and secretes sialomucin complex to the tear film. The LG was thought to be responsible only for the secretion of electrolytes, water, and tear fluid proteins. However, the studies of Arango et al. (2001) indicate that mucins must be added to the existing list of secretory products. Mucus and lipids in tears are of major importance in the ability of the tear film to wet the cornea (Holly and Lemp, 1989; Nagyova and Tiffany, 1999). Additionally, mucus plays a role as protective agent and produces a further reduction in surface tension. It also shows even greater affinity for the water/oil interface than proteins (Allen et al., 1972; Holly and Lemp, 1989; Gargiulo et al., 2000; Arango et al., 2001).

We did not find lipid-containing acini. Martin et al. (1988) reported lipid-laden cells in the canine NG that are similar to glandular cells of the HG.

Alexander et al. (1973) reported that the intercalated LG duct of rats is presumably involved in water and electrolyte transport. This is suggested by its folds of basal and lateral plasma membranes together with abundant mitochondria. The armadillo's duct system shows scarce microvilli, no basal striations and a few mitochondria. However, the presence of highly developed lateral spaces with an underlying network of capillaries suggest that the LG duct system might be involved in bulk fluid/ion transport.

The intercalated and interlobular ducts of the armadillo contain apical secretory granules. These features were also reported in most of the species studied (Sakai, 1981; Martin et al., 1988; Iwamoto and Jakobiec, 1990).

In some animals the LG contains melatonin (Mhatre et al., 1988) and porphyrins (Hugo et al., 1989). We have detected melatonin in the LG, NG, and HG of the armadillo *Ch. villosus* (Aldana Marcos, 1996). The function of these substances in the gland is unknown. The presence of melatonin in the periocular glands of the armadillo is particularly interesting especially if we consider that in this animal the pineal gland is lacking (Benítez et al., 1994). However, the reported presence of pinealocytes in the diencephalon should be considered (Kenny and Scheelings, 1979).

We wish to stress the fact that this South American species of armadillo is extraordinarily resistant to all kinds of surgical procedures contrasting with what happens with armadillos of the species Dasypus. This fact makes this animal a very suitable one for experimental studies. Last but not least we must consider that the eyes of armadillos are always at risk, being exposed to the dangerous action of soil particles since these animals are powerful diggers. Comparative studies on the structure and properties of LG and NG could help to gain a deeper understanding of the eye protective mechanisms.

Acknowledgements

This work was supported by a grant from the National Research Council (CONICET-Argentina). Lopez, Rotondaro, and Farias provided expert technical assistance. The authors are indebted to Dr Tandler for reading this manuscript.

References

Aldana Marcos, H. J. (1996). *Experimental study of two peculiar structures of the armadillo chaetophractus villosus: the Onuf's nucleus and the harderian gland*. Doctoral thesis. University of Buenos Aires: Buenos Aires, T2853.

Aldana Marcos, H. J., Benítez, I. and Affanni, J. M. (1995). New and peculiar cytoplasmic membranous bodies in the acinar cells of the Harderian gland of the Armadillo *Chaetophractus villosus*. *Biocell* **19**, 85–93.

Alexander, J. H., Young, J. A. and van Lennep, E. W. (1973). The ultrastructure of the duct system in the rat extraorbital lacrimal gland. *Z. Zellforsch. Mik. Ana.* **144**, 453–66.

Allen, M., Wright, P. and Reid, L. (1972). The human lacrimal gland. A histochemical and organ culture study of secretory cells. *Arch. Ophthalmol.* **88**, 493–7.

Antolin-Gonzalez, I., Uria, H., Tolivia, D. and Menéndez-Peláez, A. (1993). The Harderian gland of the rodent *Octodon degus*: a structural and ultrastructural study. *Tissue Cell* **25**, 129–39.

Arango, M. E., Li, P., Komatsu, M., Montes, C., Carothers Carraway, C. A. and Carraway, K. L. (2001). Production and localization of Muc4/Sialomucin complex and its receptor tyrosine kinase ErbB2 in the rat lacrimal gland. *IOVS* **42**, 2749–56.

Benítez, I., Aldana Marcos, H. J. and Affanni, J. M. (1994). The encephalon of *Chaetophractus villosus*. A general view of its most salient features. *Comun. Biol.* **12**, 57–73.

Cavagnari, B. M., Córdoba, O. L., Veerkamp, J. H., Santome, J. A. and Affanni, J. M. (1998). Presence of a fatty acid-binding protein in the armadillo Harderian gland. *Int. J. Biochem. Cell Biol.* **30**, 465–73.

Cavagnari, B. M., Sterin-Speziale, N., Affanni, J. M., Knudsen, J. and Santome, J. A. (2001). Acyl-CoA-binding protein in the armadillo Harderian gland: its primary structure and possible role in lipid secretion. *Biochim. Biophys. Acta* **1545**, 314–25.

Cohn, S. A. (1955). Histochemical observations on the Harderian gland of the albino mouse. *J. Histochem. Cytochem.* **3**, 342–53.

Culling, C. F. A., Reid, P. E., Dunn, W. L. and Clay, M. G. (1974). The histochemical demonstration of O-acylated sialic acids in gastrointestinal mucins. Their association with the potassium hydroxide-periodic acid-Schiff effect. *J. Histochem. Cytochem.* **22**, 826–31.

Draper, C. E., Adeghate, E. A., Singh, J. and Pallot, D. J. (1999). Evidence to suggest morphological and physiological alterations of lacrimal gland acini with ageing. *Exp. Eye Res.* **68**, 265–76.

Eisenberg, J. F. (1981). The Mammalian radiations. *An Analysis of Trends in Evolution, Adaptation, and Behaviour* pp 3–56. University of Chicago: Chicago, IL, U.S.A.

Engelman, G. (1985). The phylogeny of the Xenarthra. In: *The Ecology and Evolution of Armadillos, Sloths and Vermilinguas*. (Montgomery, G. G., Ed.). pp. 51–64. Smithsonian Institution: Washington, DC, U.S.A.

Gargiulo, A. M., Dall'Aglio, C., Coliolo, P., Ceccarelli, P. and Pedini, P. (2000). Complex carbohydrate histochemistry and ultracytochemistry of sheep lacrimal gland. *Anat. Histol. Embryol.* **29**, 19–23.

Helper, L. C., Magrane, W. G., Koehm, J. and Johnson, R. (1974). Surgical induction of Keratoconjunctivitis Sicca in the dog. *J. Am. Vet. Med. Assoc.* **165**, 172–4.

Holly, F. J. and Lemp, M. A. (1989). Tear physiology and dry eyes. *Surv. Ophthalmol.* **22**, 69–87.

Hraste, A., Gjurcevic Kantura, V., Jakovac, M. and Jukic Brestovec, V. (1995). Morphological investigations of the *Glandulae Profundae Plicae Semilunares Conjuntivae* in the domestic swine (*Sus scrofa domesticus*) and the wild Hog (*Sus scrofa ferus*). *Anat. Histol. Embryol.* **24**, 223–6.

Hugo, J., Vokuraka, M., Sanitrak, J., Melkova, Z. and Janousek, V. (1989). First demonstration of porphyrins in the lacrimal glands: similarity to the Harderian gland. *Biomed. Biochim. Acta* **48**, k1–k4.

Ichikawa, A. and Nakajima, Y. (1962). Electron microscope study on the lacrimal gland of the rat. *Tohoku J. Exp. Med.* **77**, 136–49.

Iwamoto, T. and Jakobiec, F. A. (1990). Lacrimal glands In: *Duane's Foundations of Clinical Ophthalmology 1*. (Tasman, W., Ed.) pp 1–21. Lippincott: Philadelphia, PA, U.S.A.

Jarial, M. and Jen, L. (1979). The fine structure of the nictitans gland of the dog with particular reference to the formation and release of its secretory product. *Indian Acad. Sci.* **87**, 431–2.

Kenny, G. C. and Scheelings, F. T. (1979). Observations of the pineal region of non-eutherian mammals. *Cell Tissue Res.* **198**, 309–24.

Krause, W. J. and McMenamin, P. G. (1992). Morphological observations on the Harderian gland of the North American opossum (*Didelphis virginiana*). *Anat. Embryol.* **186**, 145–52.

Kühnel, W. (1968a). Vergleichende histologische, histochemische und elektronenmikroskopische Untersuchungen and Tränendrüsen: I. Kaninchen und Katze. *Z. Zellforsch. Mik. Ana.* **85**, 408–40.

Kühnel, W. (1968b). Vergleichende histologische, histochemische und elektronenmikroskopische Untersuchungen and Tränendrüsen: II. Ziege. *Z. Zellforsch. Mik. Ana.* **86**, 430–43.

Kühnel, W. (1968c). Vergleichende histologische, histochemische und elektronenmikroskopische Untersuchungen and Tränendrüsen: III. Schaf. *Z. Zellforsch. Mik. Ana.* **87**, 31–45.

Kühnel, W. (1968d). Vergleichende histologische, histochemische und elektronenmikroskopische Untersuchungen and Tränendrüsen: V. Rind. *Z. Zellforsch. Mik. Ana.* **87**, 504–25.

Kühnel, W. (1968e). Vergleichende histologische, histochemische und elektronenmikroskopische Untersuchungen and Tränendrüsen: II. Hund. *Z. Zellforsch. Mik. Ana.* **88**, 23–38.

Loewenthal, N. (1892a). Notiz über die HARDER'sche Drüse des Igels. *Anat. Anz.* **7**, 48–54.

Loewenthal, N. (1892b). Beitrag zur kenntnis der Harder'schen drüse bei den säugetieren. *Anat. Anz.* **7**, 546–56.

Loewenthal, N. (1896). Drüsenstudien. I. Die Harder'sche Drüse. *Internationale Monatsschrift für Anatomie und Physiologie* **13**, 27–65.

Martin, C. L., Munnell, J. and Kaswan, R. (1988). Normal ultrastructure and histochemical characteristics of canine lacrimal glands. *Am. J. Vet. Res.* **49**, 1566–72.

Mc Kenna, M. C. (1975). Toward a phylogenetic classification of the mammalian. In: *Phylogeny of Primates*. (Luckett, W. P. and Szalay, P. S., Eds.) pp 21–46. Plenum: New York, U.S.A.

Mhatre, M. C., van Jaarsveld, A. S. and Reiter, R. J. (1988). Melatonin in the lacrimal gland: first demonstration and experimental manipulation. *Biochem. Biophys. Res. Commum.* **153**, 1186–92.

Millar, T. J., Herok, G., Koutavas, H., Martin, D. K. and Anderton, P. J. (1996). Immunohistochemical and histochemical characterisation of epithelial cells of rabbit lacrimal glands in tissue sections and cell cultures. *Tissue Cell* **28**, 301–12.

Nagyova, B. and Tiffany, J. M. (1999). Components responsible for the surface tension of human tears. *Curr. Eye Res.* **19**, 4–11.

Novacek, M. J. (1994). The radiation of placental mammals. In: *Randall Spencer Series. Major Features of Vertebrate Evolution. Short Courses in Paleontology.* (Prothero, D., Schoch, R. and Spencer, R., Eds.) pp 220–37. Paleontological Society: London, U.K.

Obata, H., Yamamoto, S., Horiuchi, H. and Machinami, R. (1995). Histopathologic study of Human lacrimal gland. *Ophthalmology* **102**, 678–86.

Payne, A. P. (1994). The Harderian gland: a tercentennial review. *J. Anat.* **185**, 1–49.

Pearse, A. G. E. (1985). Carbohydrates and Mucosubstances. In: *Histochemistry. Theoretical and Applied, 2, Analytical Technology* pp 675–753. Churchil Livingstone: New York, U.S.A.

Pinkstaff, C. A. (1993). Serous, seromucous, and special serous cells in salivary glands. *Microsc. Res. Tech.* **26**, 21–31.

Prince, J. H., Diesem, C. D., Eglitis, I. and Ruskell, G. L. (1960). *Anatomy and Histology of the Eye and Orbit in Domestic Animals*. CC Thomas: Illinois, U.S.A.

Ruskell, G. L. (1975). Nerve terminals and epithelial cell variety in the human lacrimal gland. *Cell Tissue Res.* **158**, 121–36.

Sakai, T. (1981). The Mammalian Harderian gland: morphology, biochemistry, function and phylogeny. *Arch. Histol. Cytol.* **44**, 299–333.

Sakai, T. (1989). Major ocular glands (Harderian gland and lacrimal gland) of the Musk Shrew (*Suncus murinus*) with a review on the comparative anatomy and histology of the mammalian lacrimal glands. *J. Morphol.* **201**, 39–57.

Sakai, T. (1992). Comparative anatomy of mammalian Harderian glands. In: *Harderian Glands*. (Webb, S. M., Hoffman, R. A., Puig-Domingo, M. L. and Reiter, R. J., Eds.) pp 7–23. Springer: Berlin.

Sakai, T. and van Lennep, E. W. (1984). The Harderian gland in Australian marsupials. *J. Mammal.* **65**, 159–62.

Sakai, T. and Yohro, T. (1981). A histological study of the Harderian gland of Mongolian gerbils, *Meriones meridianus*. *Anat. Rec.* **100**, 259–70.

Sheehan, D. C. and Hrapchak, B. B. (1980). Lipids. In: *Theory and Practice of Histotechnology* pp 202–13. Mosby: London, U.K.

Spicer, S. S. and Duvenci, J. (1964). Histochemical characteristics of mucopolysaccharides in salivary and exorbital lacrimal glands. *Anat. Rec.* **149**, 333–58.

Spicer, S. S. and Schulte, B. A. (1992). Diversity of cell glycoconjugates shown histochemically: a perspective. *J. Histochem. Cytochem.* **40**, 1–38.

Stein, R. and Hurwitz, J. J. (1996). Anatomy and physiology of tear secretion. In: *The Lacrimal System*. (Hurwitz, J. J., Ed.) pp 1–8. Lippincott-Raven: New York, U.S.A.

Steuhl, K. P. (1989). Ultrastructure of the conjunctival epithelium. In: *Developments in Ophthalmology*. (Straub, W., Ed.) pp 1–9. Karger: London, U.K.

Sullivan, D. A., Block, L. and Pena, J. D. O. (1996). Influence of androgens and pituitary hormones on the structural profile and secretory activity of the lacrimal gland. *Acta Ophthalmol. Scand.* **74**, 421–35.

Tandler, B. (1993). Structure of mucous cells in salivary glands. *Microsc. Res. Tech.* **26**, 49–56.

Tandler, B. and Phillips, C. J. (1993). Structure of serous cells in salivary glands. *Microsc. Res. Tech.* **26**, 32–48.

Tandler, B., Pinkstaff, C. A. and Riva, A. (1994). Ultrastructure and histochemistry of human anterior lingual salivary glands (glands of Blandin and Nuhn). *Anat. Rec.* **240**, 167–77.

Volz, D., Reid, P. E., Park, C. M., Owen, D. A. and Dunn, W. L. (1987a). A new histochemical method for the selective periodate oxidation of total tissue sialic acids. *Histochem. J.* **19**, 311–8.

Volz, D., Reid, P. E., Park, C. M., Owen, D. A. and Dunn, W. L. (1987b). Histochemical procedures for simultaneous visualization of neutral sugars and either sialic acid and its side chain O-acyl variants or O-sulphate ester. Methods based upon the selective periodate oxidation of sialic acids. *Histochem. J.* **19**, 249–56.

Weaker, F. J. (1981). Light microscopic and ultra-structural features of the Harderian gland of the nine-banded armadillo. *J. Anat.* **133**, 49–65.

Wetzel, R. (1985). The identification and distribution of recent Xenarthra (Edentata). In: *The Ecology and Evolution of Armadillos, Sloths and Vermilinguas*. (Mongomery, G. G., Ed.) pp 5–21. Smithsonian Institution: Washington, DC, U.S.A.

Yoshida, K., Nitatori, Y. and Uchiyama, Y. (1996). Localization of glycosaminoglycans and CD44 in the human lacrimal gland. *Arch. Histol. Cytol.* **59**, 505–13.