



A first case of bilateral hermaphroditism in a wild-caught tadpole (*Scinax fuscovarius*)

Javier Goldberg

CONICET-Instituto de Bio y Geociencias, Museo de Ciencias Naturales, Universidad Nacional de Salta, Mendoza 2, 4400 Salta, Argentina

True hermaphroditism, the presence of both ovarian and testicular tissues in a single individual, has been recorded in several anuran species as a result of the experimental exposure of tadpoles and juveniles to chemicals. Here, a case of hermaphroditism is reported in a wild-collected *Scinax fuscovarius* tadpole from an ephemeral pond near a village. The tadpole, at larval stage 41, had both a well developed ovary on the left side and an incipient testis on the right side, representing a case of bilateral mixed gonadal tissue. Both gonadal morphologies are similar to those observed in normal tadpoles at the same stage. This finding represents the first case of true hermaphroditism in a wild-caught tadpole.

Key words: Anura, gonads, natural conditions, tadpole, true hermaphroditism

True hermaphroditism refers to individuals who have both unequivocal ovarian and testicular tissues/elements regardless of their karyotypes (Hecker et al., 2006). It has been recorded in all vertebrate groups, both in wild populations and in experimental assays (e.g., fishes: Bortone & Davis, 1994; amphibians: Swingle, 1922; Hayes et al., 2002; 2003; Carr et al., 2003; birds: Fitzgerald & Cardona, 1993; lizards: Brown, 2008; mammals: Jiménez et al., 1993). Hermaphrodites can be regarded as intersexual forms in which gonadal development gives rise to elements of both sexes, either through i) a genetic abnormality in the zygote, ii) a defective embryonic physiological mechanism during sex differentiation, iii) environmental influences, or iv) a combination of the above factors (Hecker et al., 2006). While intersex conditions are known in a range of vertebrate groups, their development has been particularly well studied in amphibians (Witschi, 1921; Swingle, 1922; Hayes et al., 2002; Storrs-Mendez & Semlitsch, 2010), and received considerable attention when linked to abnormal sexual development through exposure to agricultural herbicides (Hayes et al., 2002).

Abnormalities in the sex organs of anurans were first reported by Spengel (1876). Since then, several adult and juvenile cases have been recorded with different types of malformations (summarized in Hecker et al., 2006).

According to Hecker et al. (2006) there is a need for studies in different environments to broaden the knowledge on the natural occurrence of hermaphroditism in anuran species than can serve as reference scenarios for the assessment of the effects of pesticide exposure.

As a part of an ongoing research project describing and comparing gonadogenesis in different anuran species of semiarid environments in Argentina, a hermaphroditic tadpole of *Scinax fuscovarius* (Anura, Hylidae) at stage 41 of Gosner (1960) was collected on March 23, 2006, in an ephemeral pond in “El Tunal” (25°15'17.97”S, 64°23'33.31”W), Metán Department, Salta, a small village in the Chaco region surrounded by agricultural lands (mainly soy). The specimen was fixed in 10% formalin in the field and are deposited in the Herpetological Collection of the Museo de Ciencias Naturales (MCN), Universidad Nacional de Salta (Argentina) with the voucher number MCN 1088. For histological analysis, the tissue of interest was dissected and dehydrated in graded alcohols followed by infiltration of xylene and paraffin. Sections were cut at 4 mm and stained with hematoxylin-eosin. The nomenclature of Hecker et al. (2006) is followed, who, in an attempt to harmonize the terminology used to describe pathological changes in gonadal development in vertebrates, proposed a combined nomenclature based on histology and gross morphology that reduces ambiguous classifications.

Out of 73 tadpoles from stages 31 to 43 of *S. fuscovarius* observed, only one presented a hermaphroditic condition. This tadpole, at larval stage 41, had both a well developed ovary on the left side and an incipient testis on the right side. The ovary is distinguished by its lobed structure, while the testis, still undifferentiated in its external morphology, appears as a thin white cord located between the mesonephros (Fig. 1).

In the ovary, primary and secondary oogonia form isolated knots in low numbers in the periphery (Fig. 1C). The oogonia have large nuclei with chromatin uniformly distributed throughout the cytoplasm. Oocytes in diplotene are already present as globular cells with large, spherical and central nuclei with noncondensed chromatin, and many micronucleoli (Fig. 1C). The incipient testis contain both somatic tissue and primordial germ

Correspondence: Javier Goldberg (jgoldberg@conicet.gov.ar)

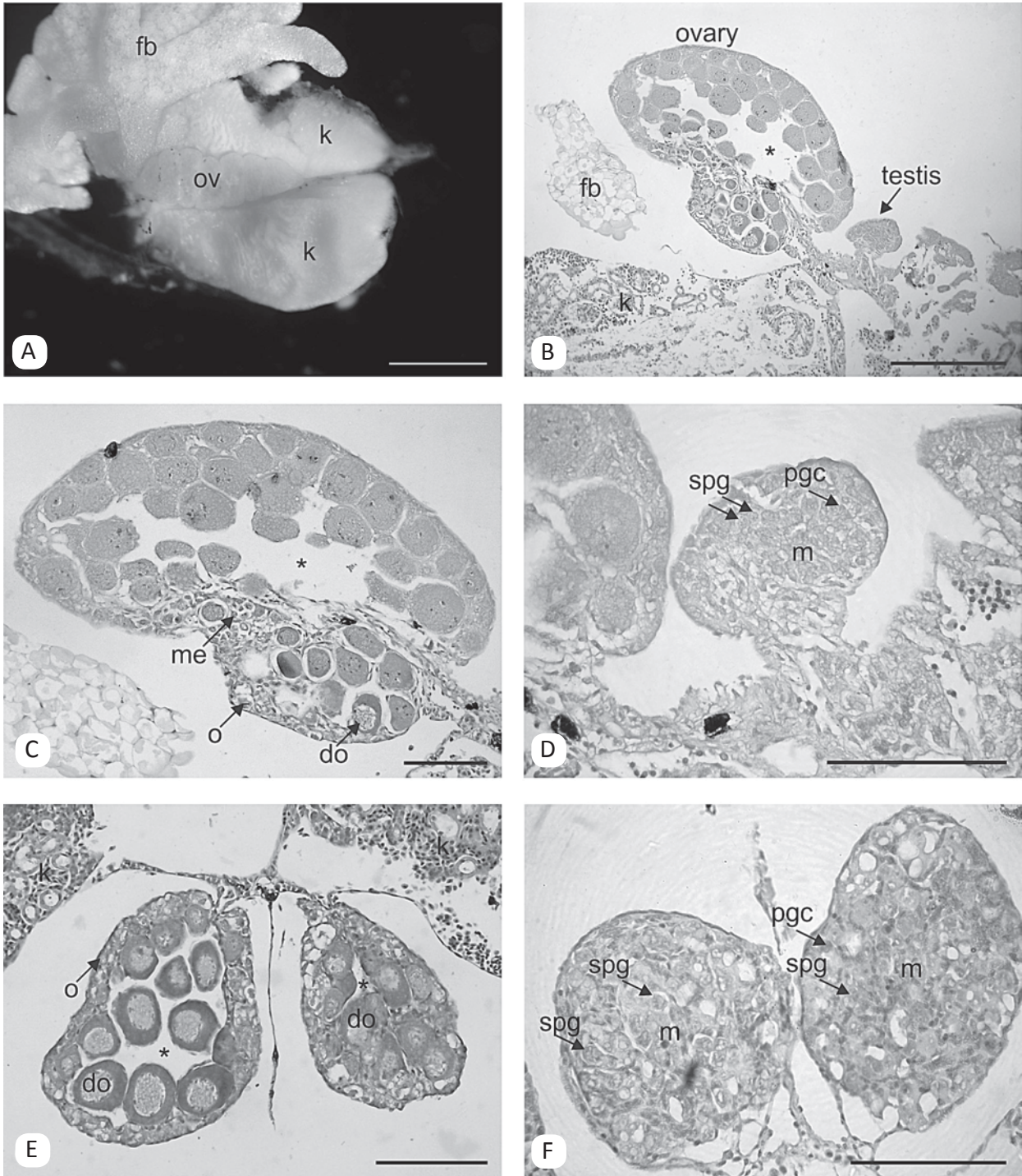


Fig. 1. Gonadal gross morphology and transverse sections in the hermaphrodite and normal specimens (at Gosner stage 41) of *Scinax fuscovarius*. A) Macroscopic gonadal abnormality. The ovary is characterized by its external lobulation while the undeveloped testis (not shown in the picture) appears as a thin cord below the ovary. The ovary was not dissected in the specimen (to show the testis) in order to prove the hermaphroditic condition in histological sections. B) Histological section where both gonads, an ovary and a testis, appear together. C) Histologically, the ovary is distinguished by the ovarian vesicle (asterisk) along its entire length and the presence of several diplotene oocytes, and primary oogonia and meicytes situated externally in the cortex. D) Testes appear as a massive structure with primordial germ cells in mitotic division and few spermatogonia. E) Ovarian tissue from a normal female based on gonadal morphology. (F) Testes from a normal male based on gonadal morphology. do: diplotene oocytes; fb: fat bodies; k: kidney; ov: ovary; m: medullary cells; me: meicytes; o: oogonia; pgc: primordial germ cells; spg: spermatogonia. Scale bar = 1 mm (A); 0.25 mm (B, E); 0.1 mm (C, D, F).

cells and few spermatogonia in the periphery (Fig. 1D). Both gonadal morphologies are similar to those observed in normal, female or male, tadpoles at the same stage (Fig. 1E, F).

This is the first report on the occurrence of histologically confirmed true hermaphroditism in wild-caught anuran tadpoles. Our finding represents a case of bilateral mixed gonadal tissue with a left-right separation

of ovarian and testicular tissues. Another term used to describe the same anomaly was lateral hermaphroditism (Witschi, 1921). This type of hermaphroditism has been previously reported only in experimental conditions that examined the response of larvae to estrogenic and antiestrogenic compounds in juveniles and adults of *Acris crepitans* (Reeder et al., 1998), *Lithobates pipiens* (Mackenzie et al., 2003), and *Xenopus laevis* (Carr et al., 2003). Reports in other vertebrates are scarce; bilateral mixed gonadal tissue represents a normal condition for a dozen fish families (Avisé & Mank, 2008), whereas in birds and reptiles there are only a few isolated reports (Fitzgerald & Cardona, 1993; Brown, 2008).

Temperature, pH and chemical agents can influence sexual differentiation in amphibians, the latter being the most often reported cause of abnormal development (Hayes et al., 2002). That only one out of 73 investigated tadpoles was a hermaphrodite suggests that it might represent a rare case of natural hermaphroditism. The site where the tadpole was collected is a pond located at the southern boundary of a village and domestic animals were seen near it. Data on pollution levels are unfortunately unavailable.

This reported case, even when the frequency is low, represents the first documented case of true hermaphroditism in a wild-caught tadpole. Further samples describing the gonadogenesis of more tadpole species should be collected in order to whether such anomalies have in the past been unnoticed.

Acknowledgements: Specimen collection permits were issued by Secretaría de Medio Ambiente y Desarrollo Sustentable, Gobierno de la Provincia de Salta. S. Quinzio and M. Fabrezi were involved in fieldwork. I am grateful to S. Quinzio and an anonymous reviewer for corrections on early drafts of the manuscript. This research was supported by Agencia Nacional de Promoción Científica y Tecnológica, PICT Bicentenario 638 and PICT Bicentenario 616.

REFERENCES

- Avisé, J.C. & Mank, J.E. (2009). Evolutionary perspectives on hermaphroditism in fishes. *Sexual Development* 3, 152–163.
- Bortone, S.A. & Davis, W.P. (1994). Fish intersexuality as indicator of environmental stress. *Bioscience* 44, 165–172.
- Brown, D. (2008). A Case of Hermaphroditism in the Ridge Tailed Monitor (*Varanus acanthurus*). *Biawak* 2, 87–88.
- Carr, J.A., Gentles, A., Smith, E.E., Goleman, W.L., Urquidi, L.J., Thuett, K., Kendall, R.J., Giesy, J.P., Gross, T.S., Solomon, K.R. & Van Der Kraak, G. (2003). Response of larval *Xenopus laevis* to atrazine: Assessment of growth, metamorphosis, and gonadal and laryngeal morphology. *Environmental Toxicology and Chemistry* 22, 396–405.
- Fitzgerald, S.D. & Cardona, C.J. (1993). True hermaphrodites in a flock of Cochin Bantams. *Avian Disease* 37, 912–916.
- Gosner, K.L. (1960). A simplified table for staging anuran embryos and larvae. *Herpetologica* 16, 183–190.
- Hayes, T.B., Collins, A., Lee, M., Mendoza, M., Noriega, N., Stuart, A.A. & Vonk, A. (2002). Hermaphroditic, demasculinized frogs after exposure to the herbicide atrazine at low ecologically relevant doses. *Proceedings of the National Academy of Sciences* 99, 5476–5480.
- Hayes, T.B., Haston, K., Tsui, M., Hoang, A., Haeffele, C. & Vonk, A. (2003). Atrazine-induced hermaphroditism at 0.1 ppb in American leopard frogs (*Rana pipiens*): laboratory and field evidence. *Environmental Health Perspectives* 111, 568–575.
- Hecker, M., Murphy, M.B., Coady, K.K., Villeneuve, D.L., Jones, P.D., Carr, J.A., Solomon, K.R., Smith, E.E., Van Der Kraak, G., Gross, T., Du Preez, L.H., Kendall R.J. & Giesy, J.P. (2006). Terminology of gonadal anomalies in fish and amphibians resulting from chemical exposures. *Reviews of Environmental Contamination and Toxicology* 187, 103–131.
- Jiménez, R., Burgos, M., Sánchez, A. Sinclair, A.H., Alarcón, F.J., Marín, J.J., Ortega, E. & Díaz de la Guardia, R. (1993). Fertile females of the mole *Talpa occidentalis* are phenotypic intersexes with ovotestes. *Development* 118, 1303–1311.
- MacKenzie, C.A., Berrill, M., Metcalfe, C. & Pauli, B.D. (2003). Gonadal differentiation in frogs exposed to estrogenic and antiestrogenic compounds. *Environmental Toxicology and Chemistry* 22, 2466–2475.
- Reeder, A.L., Foley, G.L., Nichols, D.K., Hansen, L.G., Wikoff, B., Faeh, S., Eisold, J., Wheeler, M.B., Warner, R., Murphy J.E. & Beasley, V.R. (1998). Forms and prevalence of intersexuality and effects of environmental contaminants on sexuality in Cricket Frogs (*Acris crepitans*). *Environmental Health Perspectives* 106, 261–266.
- Spengel, J.W. (1876). Das urogenitalsystem der amphibien. I. Theil. Der anatomische bau des. Urogenital systems. *Arbeiten aus dem Zoologisch-Zootomischen Institut in Würzburg* 3, 1–114.
- Storrs-Mendez, S.I. & Semlitsch, R.D. (2010). Intersex gonads in frogs: understanding the time course of natural development and role of endocrine disruptors. *Journal of Experimental Zoology* 314, 57–66.
- Swingle, W.W. (1922). Is There a Transformation of Sex in Frogs? *American Naturalist* 56, 193–210.
- Witschi, E. (1921). Development of gonads and transformation of sex in the frog. *American Naturalist* 55, 529–538.

Accepted: 17 April 2013

