

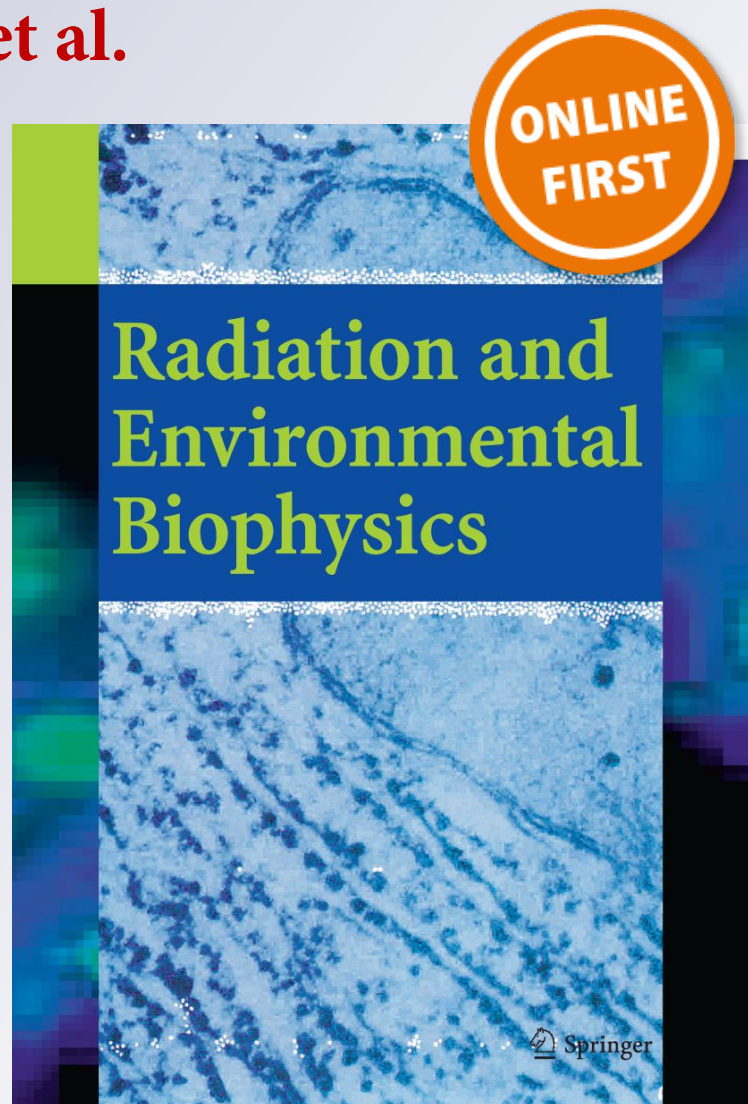
*Boron neutron capture therapy (BNCT)
translational studies in the hamster cheek
pouch model of oral cancer at the new “B2”
configuration of the RA-6 nuclear reactor*

**Andrea Monti Hughes, Juan Longhino,
Esteban Boggio, Vanina A. Medina,
Diego J. Martinel Lamas, Marcela
A. Garabalino, et al.**

**Radiation and Environmental
Biophysics**


ISSN 0301-634X

Radiat Environ Biophys
DOI 10.1007/s00411-017-0710-9



Your article is protected by copyright and all rights are held exclusively by Springer-Verlag GmbH Germany. This e-offprint is for personal use only and shall not be self-archived in electronic repositories. If you wish to self-archive your article, please use the accepted manuscript version for posting on your own website. You may further deposit the accepted manuscript version in any repository, provided it is only made publicly available 12 months after official publication or later and provided acknowledgement is given to the original source of publication and a link is inserted to the published article on Springer's website. The link must be accompanied by the following text: "The final publication is available at link.springer.com".

Boron neutron capture therapy (BNCT) translational studies in the hamster cheek pouch model of oral cancer at the new “B2” configuration of the RA-6 nuclear reactor

Andrea Monti Hughes^{1,2}  · Juan Longhino³ · Esteban Boggio³ · Vanina A. Medina^{2,4} · Diego J. Martinel Lamas^{2,4} · Marcela A. Garabalino¹ · Elisa M. Heber¹ · Emiliano C. C. Pozzi¹ · María E. Itoiz^{1,5} · Romina F. Aromando⁵ · David W. Nigg⁶ · Verónica A. Trivillin^{1,2} · Amanda E. Schwint^{1,2}

Received: 26 January 2017 / Accepted: 22 August 2017
© Springer-Verlag GmbH Germany 2017

Abstract Boron neutron capture therapy (BNCT) is based on selective accumulation of B-10 carriers in tumor followed by neutron irradiation. We demonstrated, in 2001, the therapeutic effect of BNCT mediated by BPA (boronophenylalanine) in the hamster cheek pouch model of oral cancer, at the RA-6 nuclear reactor. Between 2007 and 2011, the RA-6 was upgraded, leading to an improvement in the performance of the BNCT beam (B2 configuration). Our aim was to evaluate BPA-BNCT radiotoxicity and tumor control in the hamster cheek pouch model of oral cancer at the new “B2” configuration. We also evaluated, for the first time in the oral cancer model, the radioprotective effect of histamine against mucositis in precancerous tissue as the dose-limiting tissue. Cancerized pouches were exposed to: BPA-BNCT; BPA-BNCT + histamine; BO: Beam only; BO + histamine;

CONTROL: cancerized, no-treatment. BNCT induced severe mucositis, with an incidence that was slightly higher than in “B1” experiments (86 vs 67%, respectively). BO induced low/moderate mucositis. Histamine slightly reduced the incidence of severe mucositis induced by BPA-BNCT (75 vs 86%) and prevented mucositis altogether in BO animals. Tumor overall response was significantly higher in BNCT (94–96%) than in control (16%) and BO groups (9–38%), and did not differ significantly from the “B1” results (91%). Histamine did not compromise BNCT therapeutic efficacy. BNCT radiotoxicity and therapeutic effect at the B1 and B2 configurations of RA-6 were consistent. Histamine slightly reduced mucositis in precancerous tissue even in this overly aggressive oral cancer model, without compromising tumor control.

✉ Andrea Monti Hughes
montihug@cnea.gov.ar; andre.mh@gmail.com

- ¹ Department of Radiobiology, Constituyentes Atomic Center, National Atomic Energy Commission (CNEA), Avenida General Paz 1499, B1650KNA San Martín, Province Buenos Aires, Argentina
- ² National Research Council (CONICET), Ciudad Autonoma de Buenos Aires, Argentina
- ³ Department of Nuclear Engineering, Bariloche Atomic Center, CNEA, San Carlos de Bariloche, Province Rio Negro, Argentina
- ⁴ Laboratory of Tumoral Biology and Inflammation, School of Medical Sciences, Institute for Biomedical Research (BIOMED CONICET-UCA), Pontifical Catholic University of Argentina (UCA), Ciudad Autonoma de Buenos Aires, Argentina
- ⁵ Department of Oral Pathology, Faculty of Dentistry, UBA, Ciudad Autonoma de Buenos Aires, Argentina
- ⁶ Idaho National Laboratory, Idaho Falls, USA

Keywords Boron neutron capture therapy (BNCT) · RA-6 configuration · Hamster cheek pouch oral cancer model · Histamine · Mucositis · Precancerous tissue

Introduction

Boron neutron capture therapy (BNCT) is a binary treatment that combines the administration of boron carriers that are taken up preferentially by neoplastic tissue and irradiation with a thermal/epithermal neutron beam. The high-linear energy transfer (LET) α particles and recoiling lithium-7 (⁷Li) nuclei emitted during the capture of a thermal neutron by a boron-10 (¹⁰B) nucleus have a high relative biological effectiveness. Their short range in tissue (6–10 μ m) would limit the damage largely to cells containing ¹⁰B. In this way, BNCT would target neoplastic tissue selectively, sparing normal tissue (Coderre and Morris 1999; Trivillin et al. 2006). As BNCT is based on biological rather than

geometric targeting, it would be suited to treat undetectable micrometastases and diffuse, invasive tumors (Zonta et al. 2006; Pozzi et al. 2012; Andoh et al. 2015) and foci of malignant transformation in field-cancerized tissue (e.g., Monti Hughes et al. 2013).

Squamous Cell Carcinoma of the Head and Neck (SCCHN) is the sixth most common cancer worldwide; approximately, 600,000 new cases are diagnosed per year worldwide (Globocan, WHO, 2012, <http://globocan.iarc.fr/Default.aspx>). SCCHN generally begins in the mucosal surfaces of the head and neck. The most frequent tumor sites of SCCHN are the larynx, the pharynx, and the oral cavity. Despite multimodal treatment, including surgery, radiotherapy, chemotherapy, or some combination thereof, 40–60% of the patients with locally advanced SCCHN will relapse (Machiels et al. 2014). The prognosis of squamous cell carcinoma patients is adversely influenced by the development of new tumors, which may arise as a recurrence of an incompletely resected index tumor or may be a second field tumor (SFT) or a second primary tumor (SPT) that has arisen on a genetically altered premalignant field (Sabharwal et al. 2014). Further treatment intensification with these classic treatment modalities is almost impossible since the maximal tolerable toxicity is reached, limiting further improvement in treatment (Machiels et al. 2014). This poses the need for more effective and selective therapies. Studies in appropriate experimental models are pivotal to progress in this field.

The hamster cheek pouch model of oral cancer was previously proposed by our group for experimental BNCT studies (Kreimann et al. 2001a, b), and preceded the first clinical trial of BNCT for head and neck malignancies (Kato et al. 2004). Hamster cheek pouch carcinogenesis protocols induce premalignant and malignant changes that closely resemble spontaneous human oral mucosa lesions (Kreimann et al. 2001a; Vairaktaris et al. 2008; Heber et al. 2010; Monti Hughes et al. 2015a). The hamster cheek pouch oral cancer model is a widely accepted model of oral cancer that mimics the spontaneous process of malignant transformation in the human oral mucosa (Kreimann et al. 2001a; Vairaktaris et al. 2008; Chen and Lin 2010; Supsavhad et al. 2016).

Our tumor control studies (e.g., Molinari et al. 2011) were performed employing the classical carcinogenesis protocol that involves topical application of DMBA (7,12-dimethylbenz[a]anthracene) in the hamster cheek pouch twice a week for 12 weeks. This carcinogenesis protocol induces a very aggressive and hypersensitive precancerous tissue that gives rise in turn to multiple tumors surrounded by precancerous tissue, allowing short-term follow-up (1 month). This model is mainly used to study the therapeutic effect of BNCT on tumors. Despite the success of the BNCT protocols employed in these studies to treat tumors, the inhibition of tumor development in precancerous tissue remained an unresolved challenge. This

aggressive model precludes the long-term follow-up (Monti Hughes et al. 2015a) needed to evaluate the inhibitory effect of BNCT on tumor development from precancerous tissue. Therefore, we developed a model of oral precancer in the hamster cheek pouch that can be used for longer-term studies (8 months follow-up) (Heber et al. 2010) and that involves topical application of DMBA, twice a week, for 6 weeks. Being less aggressive, this model mimics human oral carcinogenesis more closely than the classical carcinogenesis protocol (Monti Hughes et al. 2015a). Long-term follow-up is favored as it reduces the number of applications of DMBA, which is known to cause liver disorders, such as enhanced oxidation of lipids and proteins, and results in compromised antioxidant defenses (Letchoumy et al. 2006), contributing to animal decline.

The hamster cheek pouch is also a widely accepted model of oral mucositis (OM) (Bowen et al. 2011). OM is the painful inflammation and ulceration of the mucous membranes lining the oral cavity, and is usually an adverse effect of cancer treatment (Koochi-Hosseiniabadi et al. 2015). In a clinical scenario, confluent oral mucositis is a frequent, dose-limiting side effect during conventional radiotherapy (Jensen and Peterson 2014) and is a consideration in BNCT for advanced head and neck cancers (Kankaanranta et al. 2012; Wang et al. 2014). Oral mucositis could also be considered an enhancer of tumorigenesis (Perez et al. 2005; Monti Hughes et al. 2013). Nowadays, it continues to represent an important unmet medical need in oncology practice, affecting patients' quality of life (Jensen and Peterson 2014).

In 2001, we reported significant tumor control by BNCT mediated by BPA (boronophenylalanine) in the classical hamster cheek pouch model of oral cancer, at the RA-6 nuclear reactor (Kreimann et al. 2001b). Next, we developed a model of oral precancer in hamster (as explained above) and demonstrated the inhibitory effect of BPA-BNCT at the RA-3 nuclear reactor on the development of new tumors from precancerous tissue, albeit associated with severe mucositis in precancerous tissue (Monti Hughes et al. 2013).

Administering a higher irradiation dose to tumor will conceivably lead to an improved therapeutic effect. To make this possible, the precancerous dose-limiting tissue should be protected from severe mucositis. The role of radioprotective compounds is of utmost importance in clinical radiotherapy (Medina et al. 2011a). Histamine [2-(4-imidazolyl)ethylamine] is an important regulator of a range of (patho) physiological conditions, acting through four histamine receptor subtypes (H1R, H2R, H3R, and H4R). In particular, H4R could be associated with inflammation and immune disorders (Medina et al. 2011a). Medina et al. (2011a, b) and Martinel Lamas et al. (2013) demonstrated that histamine prevented gamma radiation-induced toxicity in intestinal mucosa, bone marrow, and salivary glands of mice and rats. We then demonstrated that histamine (1 mg/kg in saline

solution, during 16 days) reduced the incidence of severe mucositis in this oral precancer model, without compromising the therapeutic effect of BPA-BNCT evaluated as the inhibitory effect on tumor development from precancerous tissue (Monti Hughes et al. 2015b). Subsequent studies demonstrated that a similar total dose of histamine administered during 5 days (5 mg/kg per day) also reduced the incidence of BNCT-induced severe mucositis in precancerous tissue (Monti Hughes et al. 2016). All of these studies were performed at the RA-3 nuclear reactor, in the hamster cheek pouch oral precancer model. Although histamine was able to protect precancerous tissue in the oral precancer model, the potential effect of histamine on BNCT-induced tumor control and associated mucositis in the more aggressive oral cancer model remained to be evaluated.

Between 2007 and 2011, the RA-6 nuclear reactor was not used for BNCT treatments. During that time period, the RA-6 core configuration, fuel enrichment and power level were upgraded. The performance of the BNCT beam was improved by enhancing positioning capabilities and field uniformity (B2 configuration) (Blaumann et al. 2008; Longhino and Blaumann 2010). All these modifications contribute to the restart of clinical and preclinical trials in Argentina. However, new radiobiological studies were needed to evaluate potential changes in the therapeutic effect of BNCT on tumors and associated mucositis in the dose-limiting precancerous tissue at the new B2 configuration of the RA-6 vs the old B1 configuration (Kreimann et al. 2001b).

The aim of the present study was to evaluate the radio-toxicity and tumor control of BPA-BNCT in the hamster cheek pouch model of oral cancer, at the “new” configuration of RA-6 (B2 configuration). These data were compared to their counterparts at the “old” configuration (B1). Finally, we also evaluated for the first time the potential influence of histamine on the therapeutic effect of BNCT on tumors and its protective effect in precancerous tissue in the oral cancer model.

Materials and methods

Tumor induction and radiobiological studies

The right cheek pouches of non-inbred young Syrian hamsters were treated with a topical application of 0.5% DMBA in mineral oil, twice a week, for 12 weeks (Molinari et al. 2011). The cancerized pouches were exposed to: (1) BPA-BNCT; (2) BPA-BNCT + histamine; (3) Beam only (BO); (4) BO + histamine. CONTROL group consisted of cancerized animals with no treatment. For all BNCT groups, neutron fluence was the same as that used in BNCT studies performed by Kreimann et al. (2001b) at the RA-6 B1 configuration: 1.1×10^{12} neutrons/cm². The animals in the BO groups were exposed to the same neutron fluence as the BNCT groups to study the effect of background dose (Table 1). We also treated non-cancerized animals with

Table 1 Irradiation conditions in Kreimann et al. (2001b) (“old” B1 configuration) and “new” B2 configuration (this study)

Protocols	Tissue	Boron concentration (Kreimann et al. 2001a) (ppm)	Irradiation time (min)	Total absorbed dose (Gy)
Cancerized animals				
BPA-BNCT	Tumor	30	62	5.16 ± 0.27
B1 RA-6	Precancerous tissue	10	62	3.48 ± 0.13
BPA-BNCT	Tumor	30	43.2	5.86 ± 0.18
B2 RA-6 (<i>n</i> = 7 animals)	Precancerous tissue	10	43.2	4.22 ± 0.15
BPA-BNCT + HISTAMINE	Tumor	30	43.2	5.86 ± 0.18
B2 RA-6 (<i>n</i> = 8 animals)	Precancerous tissue	10	43.2	4.22 ± 0.15
Beam only (BO)	Tumor/precancerous tissue	–	62	2.64 ± 0.10
B1 RA-6				
BO	Tumor/precancerous tissue	–	43.2	3.40 ± 0.15
B2 RA-6 (<i>n</i> = 6 animals)				
BO + HISTAMINE	Tumor/precancerous tissue	–	43.2	3.40 ± 0.15
B2 RA-6 (<i>n</i> = 5 animals)				
Non-cancerized animals				
BPA-BNCT	Normal tissue	10	62	3.48 ± 0.13
B1 RA-6				
BPA-BNCT	Normal tissue	10	71.2	6.96 ± 0.25
B2 RA-6 (<i>n</i> = 5 animals)				
BPA-BNCT + HISTAMINE	Normal tissue	10	71.2	6.96 ± 0.25
B2 RA-6 (<i>n</i> = 5 animals)				

BNCT and BNCT + histamine to assess the effect of BNCT on normal tissue. In this case, we doubled the dose prescribed in Kreimann et al. (2001b), seeking to induce some degree of mucositis and evaluate the protective effect of histamine in normal tissue (Table 1).

A global analysis of the background dose at the new B2 configuration shows that the non-thermal neutron dose is 35% lower than for B1 and the photon dose is 80% higher. These differences are described in more detail for each tissue in the Results section. The changes in the B2 configuration vs the B1 configuration reflect modifications in geometry and materials, expansion of the treatment room, inclusion

of a protruding collimator and an increase in neutron flux at the irradiation position. The new B2 configuration corresponds to a brand new source. The reactor's core configuration yields twice the power—up to 1 MW—with fewer fuel elements (Longhino et al. 2012; Santa Cruz et al. 2016). Figure 1a shows the RA-6 irradiation room, with the beam port with the external collimator and neutron reflector. The hamster's body was positioned in the periphery of the “new” therapeutic beam B2 for protection by the external collimator shielding (Fig. 1b). The everted pouch and, inevitably, part of the hamster's head were placed in a semicircle on the holder, near the beam axis (Fig. 2a, b), employing a similar

Fig. 1 **a** Irradiation room: beam port, external collimator (EC) and reflector (R); **b** schematic representation of the external collimator of the BNCT B2 beam, at RA-6: hamsters (H) positioned at the beam port; neutron reflector (R); external collimator (EC)

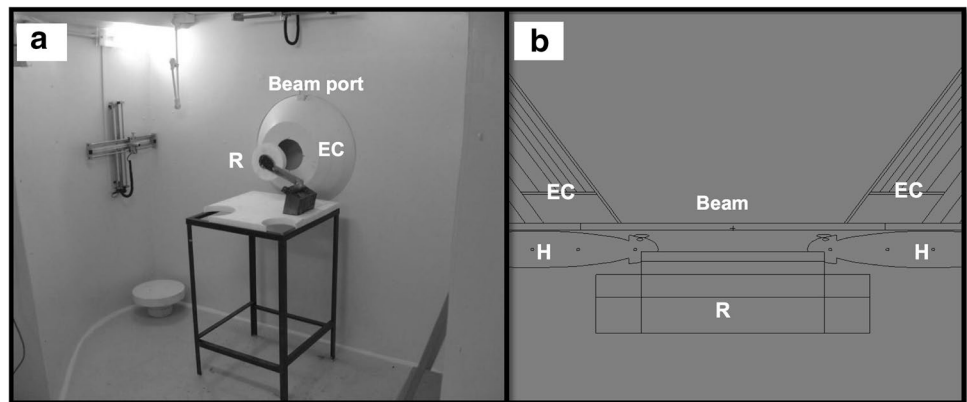



Fig. 2 Irradiation setup for the hamster cheek pouch model at the new BNCT B2 beam of the RA-6 Nuclear Reactor: **a, b** the everted pouch and, inevitably part of the head, were placed in a semi-circle on the holder; **c, d** the animals were placed on the holder, exposed to the beam, with a neutron reflector immediately behind the hamsters' heads



configuration and shielding features as for previous irradiations at B1 (Kreimann et al. 2001b; Santa Cruz et al. 2016). With this configuration, the pouches are not exposed to an important section of the beam. Thus, we added a neutron reflector immediately behind the hamster's head (Fig. 2c, d). The reflector consists of Teflon (PTFE) and acrylic (PMMA) discs. In the B1 beam configuration (year 2001), the reflector discs were made of lead.

BPA was administered intravenously [iv, 15.5 mg ¹⁰B/kg body weight (b.w.)]. The animals were irradiated 3 h post-injection. Boron concentration values in tumor, precancerous and normal tissue used herein for dose calculations were taken from Kreimann et al. (2001b) (Table 1). These values were similar to those reported in more recent biodistribution studies performed by Molinari et al. (2012). Irradiation conditions for this study at the B2 configuration and for previous studies at the B1 configuration (Kreimann et al. 2001b) are shown in Table 1. Table 2 shows the dose components for each study.

Irradiations, iv injections and follow-up were performed under anesthesia: ketamine 140 mg/kg b.w. and xilazine 21 mg/kg b.w., administered intraperitoneally. Histamine administration [5 mg/kg b.w. in saline solution] was subcutaneous (sc) in the dorsum of the neck, without anesthesia, during 5 days, starting the day before irradiation, on the day of irradiation (concomitantly with BPA injection in the BNCT groups) and daily for 3 days after irradiation.

Follow-up

The animals were followed during 1 month. The clinical signs and body weight of the animals were monitored weekly. The therapeutic effect of BNCT on those tumors that were present at the time of irradiation was evaluated as: % of tumors with complete response (CR: disappearance of the tumor on visual inspection); % of tumors with partial

response (PR: reduction in pre-treatment tumor volume); % of tumors with no response (NR); % of tumors with overall response (OR) = partial response (PR) + complete response (CR).

Potential radiotoxicity in terms of mucositis was monitored in precancerous tissue and in normal pouch tissue. The severity of mucositis was evaluated semi-quantitatively according to an adaptation of oral mucositis scales in hamsters and humans (Sonis et al. 2000; López Castaño et al. 2005), i.e., Grade 0: healthy appearance, no erosion or vasodilation; Grade 1 (slight): erythema and/or edema and/or vasodilation, no evidence of mucosal erosion; Grade 2 (slight): severe erythema and/or edema, vasodilation and/or superficial erosion; Grade 3 (moderate): severe erythema and/or edema, vasodilation and formation of ulcers <2 mm in diameter; Grade 4 (severe): severe erythema and/or edema, vasodilation and formation of ulcers ≥2 mm and <4 mm in diameter, and/or necrosis areas <4 mm in diameter; Grade 5 (severe): formation of ulcers ≥4 mm in diameter or multiple ulcers ≥2 mm in diameter, and/or necrosis areas ≥4 mm in diameter. Grading was based on the most severe macroscopic feature. The experiments with radioprotectors sought to minimize the incidence of severe mucositis Grades 4 and 5 (Monti Hughes et al. 2015b) and accelerate mucositis resolution. Duration of mucositis "Grade ≥ 3" will be considered a clinically significant end-point to evaluate, as in Wu et al. (2012).

BNCT-induced tumor control and percentage of animals with severe mucositis were analyzed with a contingency table and Fisher's exact test. Statistical significance was set at $p = 0.05$.

Animal experiments were carried out in accordance with the Guidelines laid down by the National Institute of Health (NIH) in the USA regarding the care and use of animals for experimental procedures and in accordance with protocols approved by the Argentine National Atomic

Table 2 Absorbed doses for each of the dose components of the experiments at the B1 configuration (Kreimann et al. 2001b) and at the "new" B2 configuration (this study) experiments

	Fast Neutrons (Gy)	Gamma photons (Gy)	Boron (Gy)	Induced protons (Gy)
B1 RA-6 (Kreimann et al. 2001b)				
Tumor	1.02 ± 0.08	1.40 ± 0.06	2.52 ± 0.25	0.22 ± 0.02
Precancerous/normal tissue	1.02 ± 0.08	1.40 ± 0.06	0.84 ± 0.08	0.22 ± 0.02
Head	0.72 ± 0.06	0.95 ± 0.04	0.61 ± 0.06	0.15 ± 0.02
Body	0.41 ± 0.03	0.50 ± 0.02	0.31 ± 0.03	0.08 ± 0.01
B2 RA-6 (this study)				
Tumor	0.66 ± 0.10	2.53 ± 0.11	2.46 ± 0.11	0.21 ± 0.01
Precancerous/normal tissue	0.66 ± 0.10	2.53 ± 0.11	0.82 ± 0.04	0.21 ± 0.01
Head	0.60 ± 0.09	2.04 ± 0.11	0.51 ± 0.05	0.128 ± 0.012
Body—thorax	0.52 ± 0.08	1.08 ± 0.06	0.12 ± 0.02	0.030 ± 0.004
Body—abdomen	0.30 ± 0.05	0.07 ± 0.02	0.05 ± 0.01	0.012 ± 0.001

Energy Commission Animal Care and Use Committee (CICUAL-CNEA).

Results

Regarding the irradiation conditions, the dose rate was higher in the present studies at the B2 beam than for the previous studies at the B1 beam. Accordingly, the irradiation time was shorter for the “new” B2 configuration to reach the same fluence as for the B1 configuration (Kreimann et al. 2001b) (43.2 vs 62 min, respectively; Table 1).

In Table 2, we compared each absorbed dose component for the RA-6 B1 configuration (Kreimann et al. 2001b) with the B2 “new” configuration (this study): (a) Induced protons and boron dose components were similar to the dose components reported in 2001; (b) The fast neutron component was lower for B2 than for B1 (0.66 ± 0.10 vs 1.02 ± 0.08 Gy, respectively); (c) The gamma photon dose component was 81% higher than in 2001 in tumor, precancerous and normal tissue (2.53 ± 0.11 vs 1.40 ± 0.06 Gy, respectively). Regarding the hamster’s head, if boron concentration in all tissues was considered to be approximately 10 ppm, the head received a slightly higher dose than in 2001 (3.28 ± 0.15 vs 2.43 ± 0.10 Gy, respectively). However, no significant radiotoxic effects in the hamster’s head were observed.

BNCT induced severe mucositis (G4/G5) in all BNCT groups (Table 3). The incidence of severe mucositis in the “new” B2 configuration beam was slightly higher than in the “old” configuration experiments (86 vs 67%, respectively), but this difference did not reach statistical significance (NS). In the group of cancerized animals treated with BNCT + histamine, we observed a slight reduction (NS) in the percentage of animals with severe mucositis vs the group treated with BPA-BNCT (75 vs 86%, Table 3). We also observed that histamine accelerated the resolution of

mucositis, i.e., at 19 days post-BNCT, 86% of the animals of the BNCT group exhibited a score \geq G3, whereas in the BNCT + histamine group only 50% of the animals had a score \geq G3 (Fig. 3). As an example, Fig. 4 shows one of our best examples of the tendency of histamine to reduce severe mucositis in precancerous tissue and accelerate the resolution of mucositis.

Regarding the beam only groups (with or without histamine), none of the animals reached severe mucositis. Nevertheless, in the beam only group, 2 of 6 animals (33%) reached Grade 2/3 mucositis. Conversely, histamine prevented mucositis altogether in BO animals (the animals only exhibited Grade 0/1 mucositis) (Table 3). None of the non-cancerized (normal) animals treated with BPA-BNCT or BPA-BNCT + histamine exhibited mucositis, although they were exposed to a high total absorbed dose of almost 7 Gy.

Regarding tumor control induced by BNCT (Table 4), the percentage of tumor overall response (OR) 1 month after

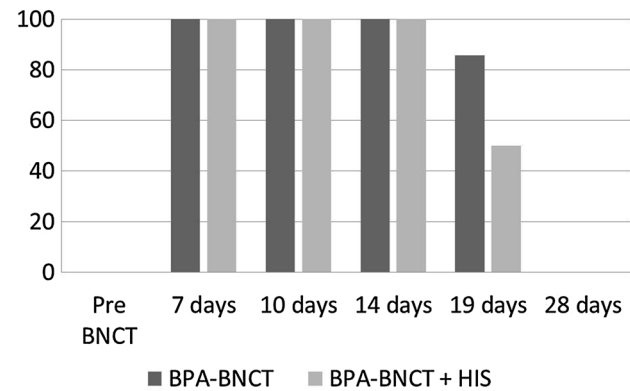


Fig. 3 Percentage of animals with a mucositis score \geq Grade 3. Histamine accelerated the resolution of mucositis: At 19 days, the BPA-BNCT group exhibited a higher % of animals with a mucositis score \geq Grade 3 than BPA-BNCT + histamine hamsters

Table 3 Percentage (%) of animals with severe mucositis at the B1 RA-6 configuration (Kreimann et al. 2001b) vs the “new” B2 RA-6 configuration (this study)

Protocols		% Animals with severe mucositis (Grade 4–Grade 5)	Grade incidence
B1 RA-6 (Kreimann et al. 2001b)	Beam only (BO)	0% (0 of 3 animals)	G0–G1: 3 animals
	BPA-BNCT	67% (4 of 6 animals)	G3: 2 animals G4–G5: 4 animals
B2 RA-6	BO	0% (0 of 6 animals)	G1: 4 animals G2: 1 animal G3: 1 animal
	BO + histamine	0% (0 of 5 animals)	G0–G1: 5 animals
	BPA-BNCT	86% (6 of 7 animals)	G3: 1 animal G4–G5: 6 animals
	BPA-BNCT + histamine	75% (6 of 8 animals)	G3: 2 animals G5: 6 animals

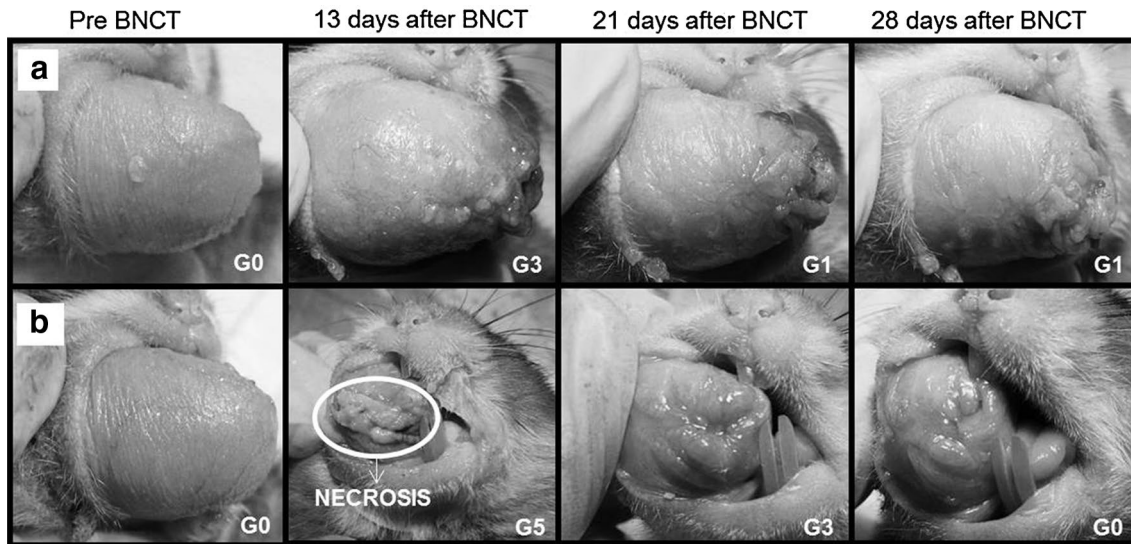


Fig. 4 One of our best examples of the trend of histamine to reduce severe mucositis in precancerous tissue: **a** hamster treated with BNCT + histamine that reached a maximum mucositis of G3; **b** ham-

ster treated with BNCT without histamine that exhibited mucositis G5, with pouch tissue loss (necrosis)

Table 4 Tumor response after BNCT at the B1 RA-6 configuration (Kreimann et al. 2001b) vs the “new” B2 RA-6 configuration (this study)

Protocols		Overall response (OR: CR + PR)	Complete response (CR)
Control (cancerized, without treatment) N = 77 tumors		16% (12/77)	0% (0/77)
B1 RA-6 (Kreimann et al. 2001b)	BPA-BNCT N = 23 tumors	91% (21/23)	78% (18/23)
	Beam only (BO) N = 3 tumors	33% (1/3)	0% (0/3)
B2 RA-6 (this study)	BPA-BNCT N = 16 tumors	94% (15/16)	69% (11/16)
	BPA-BNCT + histamine N = 25 tumors	96% (24/25)	88% (22/25)
	BO N = 16 tumors	38% (6/16)	13% (2/16)
	BO + histamine N = 11 tumors	9% (1/11)	0% (0/11)

N number of tumors

BNCT (with/without histamine) at the B2 configuration (this study) was similar to the B1 configuration results (Kreimann et al. 2001b) (96%/94% vs 91%). OR induced by BNCT at the B2 configuration was similar with or without histamine (96 and 94%, respectively) and was significantly higher than for control (16%; $p = 0.0001$) and beam only, with or without histamine (9%, $p = 0.0001$ and 38%, $p = 0.0021$, respectively). Thus, the “New” RA-6 B2 configuration did not affect the tumor overall response achieved previously at B1. Treatment with histamine did not compromise tumor overall response induced by BNCT.

Tumor complete response (CR) induced by BNCT was similar at B1 and B2, i.e., 78 vs 69%, respectively. Treatment with histamine did not compromise BNCT efficacy in terms of complete response. Moreover, treatment with histamine induced a higher percentage of CR (88%) vs BNCT at B1 and B2 configurations without histamine (78 and 69%, respectively). This difference did not reach statistical significance. Finally, OR and CR for the beam only groups were similar for B1 and B2 configurations. However, treatment with histamine in the Beam Only groups at B2 configuration exhibited a tendency, albeit not statistically significant, to reduce OR (9 vs 38%, respectively) and CR (0 vs 13%,

respectively) (Table 4). Differences in OR and CR for beam only + histamine vs control were not statistically significant (9 vs 16%, $p = 1.0000$ and 0 vs 0%, $p = 0.1720$). Instead, for Beam Only at the B2 configuration vs control, the difference in OR was not quite statistically significant (38 vs 16%, $p = 0.0753$) and the difference in CR was significantly different (13 vs 0%, $p = 0.0281$) (Table 4). Histamine could be enhancing the therapeutic effect of BNCT but compromising the therapeutic effect of Beam Only on tumors.

As an example, Fig. 5 shows one of our best examples of tumor complete response and the complete resolution of severe mucositis.

Discussion

In this study, we compared BNCT radiotoxicity and tumor control in the oral cancer hamster model, at the “new” RA-6 B2 configuration beam vs the “old” B1 configuration beam (Kreimann et al. 2001b). This comparative study is centrally important in the context of the recent restart of the clinical studies in humans and preclinical studies in dogs and cats at the RA-6 nuclear reactor. Besides, we evaluated, for the first time in the oral cancer model, if histamine could protect this overly aggressive precancerous tissue from BNCT-induced mucositis, without compromising BNCT therapeutic effect.

Regarding radiotoxicity, in both B1 and B2 configurations, we observed a high percentage of animals with severe mucositis, regardless of treatment with histamine. The classical cancerization protocol employed in the present study and the studies at B1 described above and reported previously (Kreimann et al. 2001b) consists of 24 DMBA applications. The resulting oral cancer model allows for the study of the therapeutic effect of BNCT on tumors. However, this aggressive cancerization protocol induces a highly aggressive precancerous tissue which does not mimic the human

precancerous tissue adequately (Monti Hughes et al. 2015a). In this sense, this precancerous tissue is hypersensitive to radiation and would lead to an overestimation of BPA-BNCT radiotoxicity (Monti Hughes et al. 2015a). However, in this study, we were able to observe that BNCT at B2 configuration exhibited a slightly higher radiotoxicity than at the “old” B1 RA-6 configuration. Besides, treatment with histamine exhibited a slight protective effect against mucositis in precancerous tissue.

Regarding the irradiation conditions of the B2 configuration studies vs B1 (Kreimann et al. 2001b), we reported a higher dose rate for all irradiated groups at B2 (and a concomitant shorter irradiation time) and a higher absorbed dose in precancerous tissue at B2. The slightly higher BNCT radiotoxicity effect in studies at B2 vs B1 could be due not only to a higher dose to precancerous tissue but also to a higher dose rate. A number of biological processes take place during irradiation and modify the radiation response: DNA damage repair, redistribution in the cell cycle, repopulation and reoxygenation. Repair, repopulation, and reoxygenation are the main factors determining outcome. Also radiosensitivity varies along the cell cycle, S being the most resistant phase, and G2 and M the most sensitive (Mazeron et al. 2002). Oral mucosa has a fast rate of basal cell proliferation, being more liable to develop mucositis. These cells, exposed to radiation, are inhibited from proliferating, resulting in an atrophic oral mucosa which is easily damaged and fails to regenerate (Sonis et al. 2000). Low-LET radiation and BNCT are strongly dependent upon the rate of dose delivery (Hopewell et al. 2011; Kinashi et al. 2014). Kinashi et al. (2014) suggested that the dose rate effect of the neutron mixed beam for BNCT would contribute to a higher cytotoxicity reaction in tumor cells. Both the higher dose rate and higher absorbed dose to precancerous tissue at B2 (present study) could be enhancing cytotoxicity, leading to a higher percentage of animals with severe mucositis.

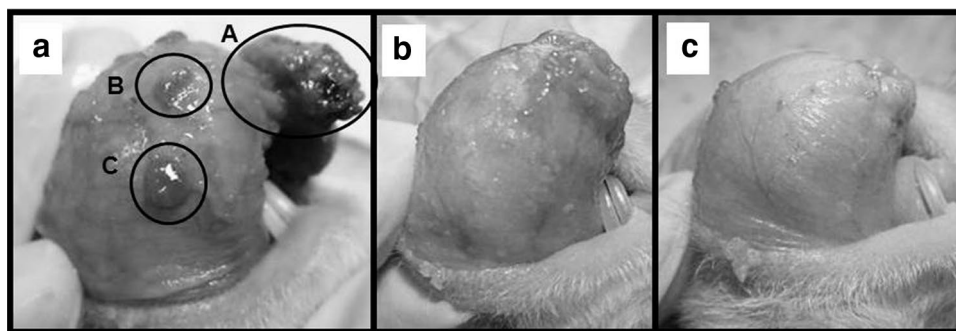


Fig. 5 One of our best examples of tumor complete response and resolution of severe mucositis in an animal treated with BPA-BNCT and histamine: **a** pre BNCT: Grade 1 mucositis in precancerous tissue and 3 tumors. Tumor volume: A 447 mm³; B 6 mm³; C 10 mm³; **b** 12 days after BNCT (time of peak mucositis): G4 mucositis in precancerous

tissue, with no identifiable tumors; **c** 28 days after BNCT (end of follow-up): mucositis in precancerous tissue has resolved completely (G1), with no identifiable tumors (complete response of those tumors that were present pre BNCT). Histamine reduced the incidence of severe mucositis without compromising BNCT tumor control

We observed that histamine exhibited a slight protective effect against mucositis in precancerous tissue, although this tissue was very radiosensitive due to the cancerization protocol employed. Medina et al. (2007) observed that histamine (0.1 mg/kg) prevents gamma radiation-induced toxicity on intestinal mucosa by suppressing apoptosis that was in turn associated with an enhanced antioxidant capacity in intestinal cells. Radiation, chemotherapy, and BNCT induce DNA strand breaks and reactive oxygen species which react with DNA and other cellular molecules causing cell dysfunction and mortality (Sonis 2009; Medina et al. 2011a; Faião-Flores et al. 2013). Free radical production is the initial stage of mucositis (Elad et al. 2006; Sonis 2009). Thus, histamine could be enhancing the antioxidant system in oral mucosa, helping to reduce mucositis in some of the animals and accelerating the resolution of mucositis (Monti Hughes et al. 2015b). In fact, histamine is capable of reducing the levels of ROS by modulating antioxidant enzymes, suppressing proinflammatory cytokines, and increasing blood flow which may favor healing (Treede et al. 1990; Hellstrand et al. 1998; Agarwala and Sabbagh 2001; Azuma et al. 2001; Elad et al. 2006). Also, histamine could act as a growth factor, favoring proliferation and repair and inhibiting apoptosis (Medina et al. 2007; Medina and Rivera, 2010).

Beam modification and histamine treatment (5 mg/kg, during 5 days) did not affect BNCT therapeutic efficacy in terms of the tumor response parameters evaluated: overall response (OR = PR + CR) and complete response (CR). Moreover, treatment with histamine could be enhancing the therapeutic effect of BNCT on tumors. This effect could be related to the fact that BNCT + histamine group exhibited a lower percentage of animals with severe mucositis, with a quick resolution of mucositis. It is known that inflammation and cancer can be interrelated (Anuja et al. 2017). Tumor microenvironment orchestrated by inflammatory cells is an indispensable participant in cancer initiation, promoting cellular proliferation, survival and migration. Chemokines are used for tumor cells to enhance their growth and development. Chemokines are soluble factors that regulate bidirectional migration of leukocytes during inflammation, and the chemokine receptor system is reported to be altered in tumor tissue (Anuja et al. 2017). Histamine was able to reduce the severity of inflammation, conceivably leading to less tumor cell proliferation and survival and a concomitant increase in partial and complete tumor response.

Regarding the animals treated with beam only and beam only + histamine, we observed that histamine reduced mucositis, but also reduced, although not significantly, overall tumor response and complete response. The Beam only + histamine group exhibited similar OR and CR values compared to the control group. It is clear that histamine could be affecting the therapeutic effect of Beam Only on tumors. As explained above, histamine could be enhancing

the antioxidant system in oral mucosa (Monti Hughes et al. 2015b), helping to reduce mucositis in all Beam Only treated animals. A free radical scavenger effect of histamine, which could be positive to reduce mucositis, would be negative in terms of partially inhibiting the low LET radiation effect on tumors, in which tumor control is mainly exerted through free radical production (Monti Hughes et al. 2015b). In the beam only groups (\pm histamine) where the low LET component is prevalent (74%), this effect could be represented as an effective reduction in tumor response. In the case of BNCT, where the main components of the dose are high LET (Hopewell et al. 2011), a significant proportion of the damage occurs directly via DNA double-strand breaks, inducing cell death and inhibiting the proliferation of surviving cells (Aromando et al. 2009). In this context, the therapeutic effect of BNCT would not be affected.

The modification of the RA-6 beam configuration did not affect the therapeutic effect of BNCT. Radiotoxicity and tumor control results at the “new” and “old” configurations of RA-6 were consistent. Histamine exhibited a slight radio-protective effect in this aggressive oral cancer model without compromising BNCT tumor control. It is well known that histamine regulates several key events in the immune response and is implicated in allergic reactions (Faustino-Rocha et al. 2017). However, we demonstrated that histamine was able to reduce severe mucositis in the oral precancer model in hamster, with only a reversible irritation at the site of injection (Monti Hughes et al. 2015b). Besides, the protective effect of histamine was demonstrated in an experimental model of intestinal irradiation (Medina et al. 2007) and in submandibular glands in rats after ionizing radiation, with no local or systemic side effects (Medina et al. 2011b). Finally, histamine dihydrochloride is currently safely used in clinical trials as an adjuvant for the potential treatment of different cancers, exhibiting no unexpected or irreversible side effects (Romero et al. 2009; Yang and Perry 2011). In the context of cancer treatment, certain side effects are acceptable as a trade-off for therapeutic efficacy. These results are very important in the context of the new preclinical studies of BNCT in dogs and cats with spontaneous head and neck cancer and the restart of clinical trials. The fact that both histamine and boronophenylalanine are approved for use in humans bridges the gap between experimental work and potential clinical application.

Acknowledgements This work was partially supported by the U.S. Department of Energy through Idaho National Laboratory and grants from the National Agency for the Promotion of Science and Technology of Argentina and the National Institute of Cancer, Argentina. The authors acknowledge the expert advice of Dr. Sara J. González (CNEA, CONICET).

Compliance with ethical standards

Funding Partially supported by the U.S. Department of Energy through Idaho National Laboratory (no. 00011369) and grants from the National Agency for the Promotion of Science and Technology of Argentina (no. 2010-0175) and the National Institute of Cancer (no. 1006/2016), Argentina.

Conflict of interest The authors declare that they have no conflict of interest.

Ethical approval All applicable international, national and/or institutional guidelines for the care and use of animals were followed. All procedures performed in studies involving animals were in accordance with the ethical standards of the National Atomic Energy Commission (CNEA).

References

- Agarwala SS, Sabbagh MH (2001) Histamine dihydrochloride: inhibiting oxidants and synergising IL-2-mediated immune activation in the tumour microenvironment. *Expert Opin Biol Ther* 1:869–879
- Andoh T, Fujimoto T, Suzuki M, Sudo T, Sakurai Y, Tanaka H, Fujita I, Fukase N, Moritake H, Sugimoto T, Sakuma T, Sasai H, Kawamoto T, Kirihata M, Fukumori Y, Akisue T, Ono K, Ichikawa H (2015) Boron neutron capture therapy (BNCT) as a new approach for clear cell sarcoma (CCS) treatment: trial using a lung metastasis model of CCS. *Appl Radiat Isot* 106:195–201
- Anuja K, Roy S, Ghosh C, Gupta P, Bhattacharjee S, Banerjee B (2017) Prolonged inflammatory microenvironment is crucial for pro-neoplastic growth and genome instability: a detailed review. *Inflamm Res* 66(2):119–128
- Aromando RF, Heber EM, Trivillin VA, Nigg DW, Schwint AE, Itoiz ME (2009) Insight into the mechanisms underlying tumor response to boron neutron capture therapy in the hamster cheek pouch oral cancer model. *J Oral Pathol Med* 38(5):448–454
- Azuma Y, Shinohara M, Wang PL, Hidaka A, Ohura K (2001) Histamine inhibits chemotaxis, phagocytosis, superoxide anion production, and the production of TNF α and IL-12 by macrophages via H₂-receptors. *Int Immunopharmacol* 1:1867–1875
- Blaumann H, Longhino J, Calzetta O (2008) Redesign of the RA-6 reactor BNCT facility. Dissertation, 13th ICNCT Congress, Florence, Italy
- Bowen JM, Gibson RJ, Keefe DM (2011) Animal models of mucositis: implications for therapy. *J Support Oncol* 9(5):161–168
- Chen YK, Lin LM (2010) DMBA-induced hamster buccal pouch carcinoma and VX₂-induced rabbit cancer as a model for human oral carcinogenesis. *Expert Rev Anticancer Ther* 10(9):1485–1496
- Coderre JA, Morris GM (1999) The radiation biology of boron neutron capture therapy. *Radiat Res* 151:1–18
- Elad S, Ackerstein A, Bitan M, Shapira MY, Resnick I, Gesundheit B, Cohen Y, Diss O, Barak D, Dray L, Or R (2006) A prospective, double-blind phase II study evaluating the safety and efficacy of a topical histamine gel for the prophylaxis of oral mucositis in patients post hematopoietic stem cell transplantation. *Bone Marrow Transplant* 37:757–762
- Faião-Flores F, Coelho PR, Arruda-Neto JD, Maria-Engler SS, Maria DA (2013) Cell cycle arrest, extracellular matrix changes and intrinsic apoptosis in human melanoma cells are induced by boron neutron capture therapy. *Toxicol In Vitro* 27:1196–1204
- Faustino-Rocha AI, Ferreira R, Gama A, Oliveira PA, Ginja M (2017) Antihistamines as promising drugs in cancer therapy. *Life Sci* 172:27–41
- Heber EM, Monti Hughes A, Pozzi EC, Itoiz ME, Aromando RF, Molinari AJ, Garabalino MA, Nigg DW, Trivillin VA, Schwint AE (2010) Development of a model of tissue with potentially malignant disorders (PMD) in the hamster cheek pouch to explore the long-term potential therapeutic and/or toxic effects of different therapeutic modalities. *Arch Oral Biol* 55(1):46–51
- Hellstrand K, Hermodsson S, Naredi P, Mellqvist UH, Brune M (1998) Histamine and cytokine therapy. *Acta Oncol* 37:347–353
- Hopewell JW, Morris GM, Schwint A, Coderre JA (2011) The radiobiological principles of boron neutron capture therapy: a critical review. *Appl Radiat Isot* 69(12):1756–1759
- Jensen SB, Peterson DE (2014) Oral mucosal injury caused by cancer therapies: current management and new frontiers in research. *J Oral Pathol Med* 43(2):81–90
- Kankaanranta L, Seppälä T, Koivunoro H, Saarilahti K, Atula T, Collan J, Salli E, Kortseniemi M, Uusi-Simola J, Välimäki P, Mäkitie A, Seppänen M, Minn H, Revitzer H, Kouri M, Kotiluoto P, Seren T, Auterinen I, Savolainen S, Joensuu H (2012) Boron neutron capture therapy in the treatment of locally recurred head-and-neck cancer: final analysis of a phase I/II trial. *Int J Radiat Oncol Biol Phys* 82(1):e67–e75
- Kato I, Ono K, Sakurai Y, Ohmae M, Maruhashi A, Imahori Y et al (2004) Effectiveness of BNCT for recurrent head and neck malignancies. *Appl Radiat Isot* 61:1069–1073
- Kinashi Y, Okumura K, Kubota Y, Kitajima E, Okayasu R, Ono K, Takahashi S (2014) Dose-rate effect was observed in T98G glioma cells following BNCT. *Appl Radiat Isot* 88:81–85
- Koohi-Hosseinabadi O, Andisheh-Tadbir A, Bahadori P, Sepahmanesh M, Mardani M, Tanideh N (2015) Comparison of the therapeutic effects of the dietary and topical forms of Zizyphus jujuba extract on oral mucositis induced by 5-fluorouracil: a golden hamster model. *J Clin Exp Dent* 7(2):e304–e309
- Kreimann EL, Itoiz ME, Dagrosa A, Garavaglia R, Fariás S, Batistoni D, Schwint AE (2001a) The hamster cheek pouch as a model of oral cancer for boron neutron capture therapy studies: selective delivery of boron by boronophenylalanine. *Cancer Res* 61(24):8775–8781
- Kreimann EL, Itoiz ME, Longhino J, Blaumann H, Calzetta O, Schwint AE (2001b) Boron neutron capture therapy for the treatment of oral cancer in the hamster cheek pouch model. *Cancer Res* 61(24):8638–8642
- Letchoumy PV, Chandra Mohan KV, Kumaraguruparan R, Hara Y, Nagini S (2006) Black tea polyphenols protect against 7,12-dimethylbenz[a]anthracene-induced hamster buccal pouch carcinogenesis. *Oncol Res* 16:167–178
- Longhino J, Blaumann H (2010) Current Status of the RA-6 reactor BNCT facility. Dissertation, 14th ICNCT Congress, Bs As, Argentina
- Longhino J, Fernandez C, Santa Cruz G (2012) BNCT hyperthermal beam B2 at RA-6 reactor: Configuration and performance of the new therapeutic facility. Dissertation, 15th ICNCT Congress, Tsukuba, Japan
- López Castaño F, Oñate-Sánchez RE, Roldán-Chicano R, Cabrerizo-Merino MC (2005) Measurement of secondary mucositis to oncohematologic treatment by means of different scale. *Med Oral Patol Oral Cir Bucal* 10:412–421
- Machiels JP, Lambrecht M, Hanin FX, Duprez T, Gregoire V, Schmitz S, Hamoir M (2014) Advances in the management of squamous cell carcinoma of the head and neck. *F1000Prime Rep* 6:44
- Martinel Lamas DJ, Carabajal E, Prestifilippo JP, Rossi L, Elverdin JC, Merani S, Bergoc RM, Rivera ES, Medina VA (2013) Protection of radiation-induced damage to the hematopoietic system, small

- intestine and salivary glands in rats by JNJ7777120 compound, a histamine H4 ligand. *PLoS One* 8:e69106
- Mazon JJ, Scalliet P, Van Limbergen E, Lartigau E (2002) Radiobiology of brachytherapy and the dose-rate effect. The GEC-ESTRO handbook of brachytherapy, Brussels: ESTRO. pp 95–121
- Medina VA, Rivera ES (2010) Histamine receptors and cancer pharmacology. *Br J Pharmacol* 161:755–767
- Medina VA, Croci M, Mohamad NA, Massari N, Garbarino G, Cricco GP, Núñez MA, Martín GA, Crescenti EJ, Bergoc RM, Rivera ES (2007) Mechanisms underlying the radioprotective effect of histamine on small intestine. *Int J Radiat Biol* 83(10):653–663
- Medina VA, Martinel Lamas DJ, Brenzoni PG, Massari N, Carabajal E and Rivera ES (2011a) Histamine receptors as potential therapeutic targets for cancer drug development, drug development—a case study based insight into modern strategies. In: Dr. Chris Rundfeldt (ed). doi: [10.5772/27773](https://doi.org/10.5772/27773). <http://www.intechopen.com/books/drug-development-a-case-study-based-insight-into-modern-strategies/histamine-receptors-as-potential-therapeutic-targets-for-cancer-drug-development>
- Medina VA, Prestifilippo JP, Croci M, Carabajal E, Bergoc RM, Elverdin JC, Rivera ES (2011b) Histamine prevents functional and morphological alterations of submandibular glands induced by ionising radiation. *Int J Radiat Biol* 87(3):284–292
- Molinari AJ, Pozzi ECC, Monti Hughes A, Heber EM, Garabalino MA, Thorp SI, Miller M, Itoiz ME, Aromando RF, Nigg DW, Quintana J, Santa Cruz GA, Trivillin VA, Schwint AE (2011) “Sequential” boron neutron capture therapy (BNCT): a novel approach to BNCT for the treatment of oral cancer in the hamster cheek pouch model. *Radiat Res* 175:463–472
- Molinari AJ, Pozzi EC, Monti Hughes A, Heber EM, Garabalino MA, Thorp SI, Miller M, Itoiz ME, Aromando RF, Nigg DW, Trivillin VA, Schwint AE (2012) Tumor blood vessel “normalization” improves the therapeutic efficacy of boron neutron capture therapy (BNCT) in experimental oral cancer. *Radiat Res* 177(1):59–68
- Monti Hughes A, Pozzi EC, Thorp S, Garabalino MA, Farías RO, González SJ, Heber EM, Itoiz ME, Aromando RF, Molinari AJ, Miller M, Nigg DW, Curotto P, Trivillin VA, Schwint AE (2013) Boron neutron capture therapy for oral precancer: proof of principle in an experimental animal model. *Oral Dis* 19(8):789–795
- Monti Hughes A, Aromando R, Pérez MA, Schwint AE, Itoiz ME (2015a) The hamster cheek pouch model for field cancerization studies. *Periodontology* 2000 67(1):292–311
- Monti Hughes A, Pozzi E, Thorp SI, Curotto P, Medina VA, Martinel Lamas DJ, Rivera ES, Garabalino MA, Farías RO, Gonzalez SJ, Heber EM, Itoiz ME, Aromando RF, Nigg DW, Trivillin VA, Schwint AE (2015b) Histamine reduces boron neutron capture therapy-induced mucositis in an oral precancer model. *Oral Dis* 21(6):770–777
- Monti Hughes A, Pozzi ECC, Thorp S, Curotto P, Medina VA, Martinel Lamas DJ, Rivera ES, Garabalino MA, Farías RO, González SJ, Heber EM, Itoiz ME, Aromando RF, Nigg DW, Trivillin VA, Schwint AE (2016) Histamine reduces the incidence of severe mucositis induced by boron neutron capture therapy (BNCT) in field cancerized tissue in the hamster cheek pouch oral precancer model without compromising therapeutic efficacy. Poster, 45th EHRs (European Histamine Research Society) meeting, Florence, Italy
- Perez MA, Raimondi AR, Itoiz ME (2005) An experimental model to demonstrate the carcinogenic action of oral chronic traumatic ulcer. *J Oral Pathol Med* 34:17–22
- Pozzi EC, Cardoso JE, Colombo LL, Thorp S, Monti Hughes A, Molinari AJ, Garabalino MA, Heber EM, Miller M, Itoiz ME, Aromando RF, Nigg DW, Quintana J, Trivillin VA, Schwint AE (2012) Boron neutron capture therapy (BNCT) for liver metastasis: therapeutic efficacy in an experimental model. *Radiat Environ Biophys* 51:331–339
- Romero AI, Thoren FB, Aurelius J, Askarieh G, Brune M, Hellstrand K (2009) Post-consolidation immunotherapy with histamine dihydrochloride and interleukin-2 in AML. *Scand J Immunol* 70:194–205
- Sabharwal R, Mahendra A, Moon NJ, Gupta P, Jain A, Gupta S (2014) Genetically altered fields in head and neck cancer and second field tumor. *South Asian J Cancer* 3(3):151–153
- Santa Cruz GA, Longhino JM, Provenzano L, Boggio EF, Roth BMC, Pereira MD, Monti Hughes A, Farías RO, Olivera MS, Garabalino M, Nievas SI, Menéndez PR, Cantarelli MA, Rao M, Casal MR, Feld D, Trivillin VA, Pozzi E, Heber E, Brollo F, Herrera M, Kessler J, Bortolussi S, Schwint AE, González SJ (2016) Re-start of clinical and pre-clinical BNCT activities at the Argentine RA-6 Nuclear Reactor. Dissertation, 16th ICNCT Congress, Missouri, USA
- Sonis ST (2009) Mucositis: the impact, biology and therapeutic opportunities of oral mucositis. *Oral Oncol* 45:1015–1020
- Sonis ST, Peterson RL, Edwards LJ, Lucey CA, Wang L, Mason L, Login G, Ymamkawa M, Moses G, Bouchard P, Hayes LL, Bedrosian C, Dorner AJ (2000) Defining mechanisms of action of interleukin-11 on the progression of radiation-induced oral mucositis in hamsters. *Oral Oncol* 36(4):373–381
- Supsavhad W, Dirksen WP, Martin CK, Rosol TJ (2016) Animal models of head and neck squamous cell carcinoma. *Vet J* 210:7–16
- Treede RD, Meyer RA, Davis KD, Campbell JN (1990) Intradermal injections of bradykinin or histamine cause a flare-like vasodilatation in monkey. Evidence from laser Doppler studies. *Neurosci Lett* 115:201–206
- Trivillin VA, Heber EM, Nigg DW, Itoiz ME, Calzetta O, Blaumann H, Longhino J, Schwint AE (2006) Therapeutic success of boron neutron capture therapy (BNCT) mediated by a chemically non-selective boron agent in an experimental model of oral cancer: a new paradigm in BNCT radiobiology. *Radiat Res* 166(2):387–396
- Vairaktaris E, Spyridonidou S, Papakosta V, Vylliotis A, Lazaris A, Perrea D, Yapijakis C, Patsouris E (2008) The hamster model of sequential oral oncogenesis. *Oral Oncol* 44(4):315–324
- Wang LW, Chen YW, Ho CY, Hsueh Liu YW, Chou FI, Liu YH, Liu HM, Peir JJ, Jiang SH, Chang CW, Liu CS, Wang SJ, Chu PY, Yen SH (2014) Fractionated BNCT for locally recurrent head and neck cancer: experience from a phase I/II clinical trial at Tsing Hua open-pool reactor. *Appl Radiat Isot* 88:23–27
- Wu X, Chen P, Sonis ST, Linggen MW, Berger A, Toback FG (2012) A novel Peptide to treat oral mucositis blocks endothelial and epithelial cell apoptosis. *Int J Radiat Oncol Biol Phys* 83(3):e409–e415
- Yang LPH, Perry CM (2011) Spotlight on histamine dihydrochloride in acute myeloid leukaemia. *Drugs Aging* 28(4):325–329
- Zonta A, Prati U, Roveda L, Ferrari C, Zonta S, Clerici AM, Zonta C, Pinelli T, Fossati F, Altieri S, Bortolussi S, Bruschi P, Nano R, Barni S, Chiari P, Mazzini G (2006) Clinical lessons from the first applications of BNCT on unresectable liver metastases. In: *Journal of Physics: Conference Series*, vol 41, Institute of Physics Publishing, Bristol, UK, pp 484–495. doi:[10.1088/1742-6596/41/1/054](https://doi.org/10.1088/1742-6596/41/1/054)