



ORIGINAL ARTICLE

Pharmacological targeting of histamine H₄ receptor in periodontal disease

JP Prestifilippo¹, J Fernández-Solari^{1,2}, DJ Martinel Lamas^{3,4}, CE Rios¹, C Mohn^{1,2}, JC Perazzo⁵, ES Rivera³, JC Elverdin¹, VA Medina^{3,4}

¹Physiology Department, School of Dentistry, University of Buenos Aires, Buenos Aires; ²National Scientific and Technical Research Council (CONICET), Buenos Aires; ³Laboratory of Radioisotopes, School of Pharmacy and Biochemistry, University of Buenos Aires, Buenos Aires; ⁴Laboratory of Cellular and Molecular Biology, Institute for Biomedical Research (BIOMED), School of Medical Sciences, CONICET, Pontifical Catholic University of Argentina (UCA), Buenos Aires; ⁵Pathophysiology, School of Pharmacy and Biochemistry, University of Buenos Aires, Buenos Aires, Argentina

OBJECTIVE: The objective of this study was to investigate whether histamine H₄ receptor (H₄R) antagonists could prevent experimental periodontitis (EP)-induced histological, functional and inflammatory alterations in submandibular gland (SMG), periodontal bone and gingiva.

METHODS: Bilateral EP was induced for 2 weeks in anaesthetized male rats. The effect of systemic and local administration of H₄R antagonists (JNJ777120, JNJ10191584) on histopathology and functionality of SMG, bone loss and gingival inflammation was evaluated.

RESULTS: The subcutaneous administration of JNJ777120 prevented periodontitis-induced SMG histological injury, reducing vacuolization and apoptosis and additionally reversed the increased prostaglandin E₂ (PGE₂) levels in SMG while it partially reversed the methacholine-induced salivation reduction produced by periodontitis. JNJ777120 attenuated bone loss and the increased PGE₂ levels and inflammatory infiltration in gingival tissue of rats with periodontitis. Finally, local administration of JNJ777120 and JNJ10191584 was also beneficial for improving periodontal parameters.

CONCLUSIONS: H₄ receptor antagonists are able to ameliorate periodontitis-induced injury on SMG, gingival tissue and bone structure, suggesting that pharmacological targeting of H₄R could be an attractive strategy to improve periodontal health.

Oral Diseases (2016) 22, 423–429

Keywords: JNJ777120; periodontitis; submandibular gland; apoptosis; inflammation; gingivitis

Introduction

Periodontitis is an infectious disease understood as a response to the challenge of the bacterial subgingival dental biofilm, leading to inflammation with periodontal pocket formation, alveolar bone resorption and, in many cases, teeth loss (Taubman *et al*, 2005; Kinney *et al*, 2007). Complex interactions between pathogenic bacteria and host-derived inflammatory mediators [e.g. interleukin (IL)-1, tumour necrosis factor alpha (TNF α) and prostaglandins (PG)] are involved in the destruction of periodonto (Tatakis, 1993; Rink and Kirchner, 1996; Kinney *et al*, 2007).

Saliva plays a critical role in local and systemic oral protection and derives predominantly from submandibular (SMG), sublingual and parotid glands (Dodds *et al*, 2005; Forde *et al*, 2006). Diminished salivary output is called hyposialia, and it compromises oral health and quality of life (Atkinson *et al*, 2005; Dodds *et al*, 2005). Numerous evidence shows that some pathologies (e.g. Sjögren syndrome, SS), therapeutic modalities (drugs, chemo- and radiotherapy) and contaminants' intake are able to induce salivary gland dysfunction (Guggenheimer and Moore, 2003; Atkinson *et al*, 2005; Dodds *et al*, 2005; Prestifilippo *et al*, 2011). Moreover, it was previously reported that periodontitis produced hyposialia, worsening the evolution of periodontal disease (Amer *et al*, 2011; Prestifilippo *et al*, 2012). It is worth mentioning that recent evidence supports the hypothesis that periodontitis is a risk factor for several pathologies, including atherosclerotic cardiovascular disease (Kholy *et al*, 2015), Alzheimer's disease and type 2 diabetes (Shaik *et al*, 2014). Therefore, periodontitis-associated morbidity points towards the development of effective

Correspondence: Vanina A. Medina, Ph.D, School of Pharmacy and Biochemistry, University of Buenos Aires, Junín 956, Buenos Aires, ARGENTINA (1113). Tel: +54-11-4964-8277/8202, Fax: +54-11-4964-8277 Ext. 31, E-mail: vmedina@ffyb.uba.ar

Received 30 September 2015; revised 8 January 2016; accepted 10 February 2016

treatments. In this regard, it was reported that histamine subcutaneous administration at low concentration is able to ameliorate morphological and functional experimental periodontitis (EP)-induced injury on salivary glands and also reduces alveolar bone resorption (Prestifilippo *et al*, 2012).

Histamine is a well-known pleiotropic mediator in both numerous physiological processes and diseases. This endogenous amine produces its actions through the binding to four histamine receptor subtypes (Medina and Rivera, 2010). The histamine H₄ receptor (H₄R) was identified in human and rat salivary glands (Stegaev *et al*, 2012; Martinel Lamas *et al*, 2013). H₄R is located in acinar and ductal epithelial cells and its expression was not detected in tubuloacinar cells of patients with primary SS, which suggests H₄R's involvement in salivation (Stegaev *et al*, 2012).

JNJ7777120 and JNJ10191584, which are potent and selective H₄R ligands that bind with almost identical affinity to the human, rat and mouse H₄R, exhibited anti-inflammatory effects and have been extensively used to evaluate the action of H₄R in both physiological and pathological conditions (Thurmond *et al*, 2004; Leurs *et al*, 2009; Deiteren *et al*, 2015).

Based on the presented evidence, the aim of the present work was to investigate whether H₄R antagonists could prevent periodontitis-induced histological, functional and inflammatory alterations in SMG, periodontal bone and gingiva.

Materials and methods

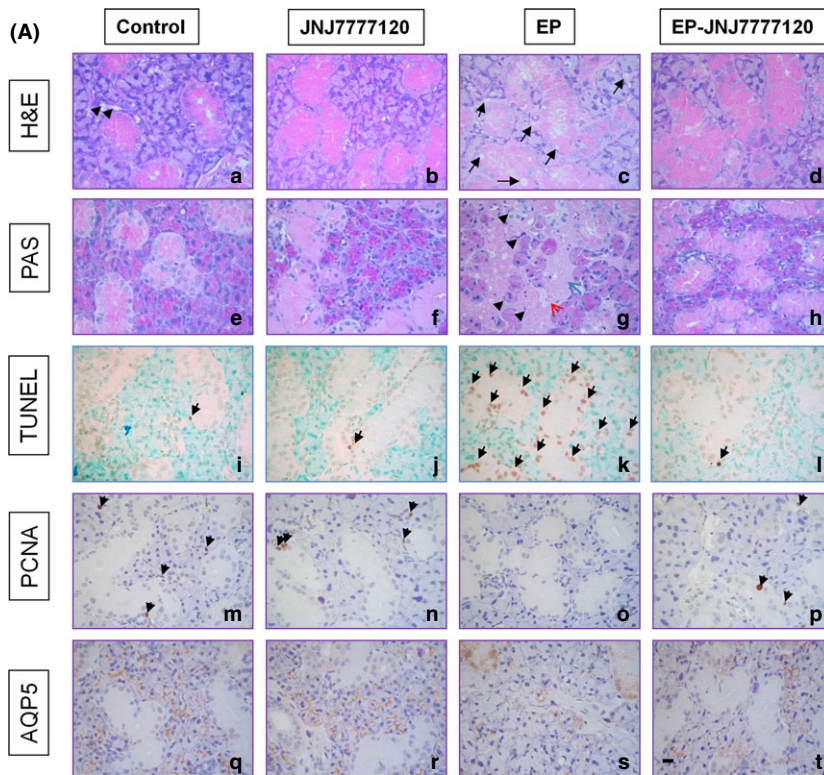
Animals, experimental periodontitis and treatments

Male Sprague Dawley rats weighing between 230 and 250 g (4 groups, *n* = 12 each) were kept in our animal facility as previously reported (Prestifilippo *et al*, 2012). Bilateral EP was induced as earlier described (Prestifilippo *et al*, 2012).

Control group received saline and JNJ7777120 group received a daily JNJ7777120 injection (dissolved in saline, 10 mg kg⁻¹) the last week (experimental period were 2 weeks) by subcutaneous administration on the dorsal flank. EP group exhibited bilateral periodontitis and received saline, while EP-JNJ7777120 group exhibited bilateral periodontitis and received a daily JNJ7777120 injection. JNJ7777120 concentration was selected according to previous studies (Martinel Lamas *et al*, 2013).

Salivation was evaluated (*n* = 6 each group), or SMG and gingival tissue were obtained for histological and histochemical determination (*n* = 6 each group). Microscopic evaluation of vestibular and lingual bone loss was performed on stained hemimandibles.

Additionally, another experiment was performed to evaluate the effect of the local administration of H₄R antagonists (*n* = 6 each group).



Group	Histological Changes	TUNEL	PCNA
Control	-	3.0 ± 0.9	4.7 ± 0.3
JNJ7777120	-	3.7 ± 0.9	4.5 ± 0.2
EP	Vacuolization, necrosis, pyknosis	70.3 ± 3.4***	0.4 ± 0.1***
EP-JNJ7777120	-	2.1 ± 0.8###	2.9 ± 0.2###

Figure 1 JNJ7777120 prevents EP-induced morphological, proliferative and apoptotic alterations in the rat SMG. (A, B) Normal tissue histology of (a, e) untreated and (b, f) JNJ7777120-treated SMG. (c, g) SMG of EP group showed histological changes, as partial loss of secretor granular material, micro-macrovacuolization (black arrow), necrotic focal area (blue arrow), intra- and extraglandular pyknotic nuclei (black arrow head) and focal haemorrhage (red arrow). (d, h) SMG JNJ7777120-EP showed preserved structure organization of the gland and prevented histological alterations. (a–d) H&E stain. (e–h) PAS stain. (i) Low number of TUNEL-positive cells in glandular cells of control and (j) JNJ7777120-treated rats. (k) Increased number of TUNEL-positive cells in glands of EP group. (l) Significant decrease in TUNEL-positive cells in glands derived from EP-JNJ7777120 group. (m, n) Similar PCNA immunoreactivity in SMG from control and JNJ7777120-treated rats. (o) Decreased PCNA immunoreactivity in SMG of EP group. (p) Partial preservation of PCNA-positive cells in glands derived from EP-JNJ7777120 group. Arrows indicate positive cells. AQP5 was localized mainly in the apical membranes of acinar cells of (q) control and (r) JNJ7777120-treated SMG. (s) EP diminished AQP5 immunoreactivity and changed its localization. (t) AQP5 showed recovery of localization and immunoreactivity in SMG of JNJ7777120-EP group. 630× magnification. Scale bar= 20 μm. (B) Histopathological characteristics and average number of apoptotic and proliferative cells in SMG. Data are expressed as means ± SEM. ****P* < 0.001 vs control; ###*P* < 0.001 vs EP

JNJ777120 (2.5%) and JNJ10191584 (2.5%) or saline in the form of gel (hydroxypropyl methylcellulose 3%) were administered locally between the buccal side of mandibular first molar and the cheek (0.1 ml each side), using a syringe in another group of animals.

All procedures were performed in agreement with international recommendations (Guide for the Care and Use of Laboratory Animals of the National Research Council, USA, 1996, 2011) and were approved by the Ethical Committee for the Use and Care of Laboratory Animals of the School of Pharmacy and Biochemistry (#131211-2).

Salivary secretion

The methods used herein are similar to those reported by us earlier (Prestifilippo *et al*, 2012). Briefly, salivary secretion samples were collected and weighed after stimulation with different concentrations of methacholine (0.3, 1, 3 and 10 µg/kg, in saline) (FLUKA, Berlin, Germany).

Histopathological and immunohistochemical analysis

Tissues were removed, fixed with buffered formalin and paraffin-embedded. Histological features were determined in tissue sections stained with haematoxylin–eosin staining or with periodic acid schiff (PAS) staining and counterstained with haematoxylin. Histopathological and immunohistochemical analyses were performed blindly by an expert pathologist (JCP).

Immunohistochemical studies were performed as previously reported (Prestifilippo *et al*, 2012; Martinel Lamas *et al*, 2013), employing mouse anti-proliferating cell nuclear antigen (PCNA, 1:100, Dako Cytomation, Glostrup, Denmark) or rabbit anti-aquaporin 5 (AQP5, 1:50, Abcam, Cambridge, MA, USA) antibodies. Apoptosis was evaluated by terminal deoxynucleotidyl transferase (TdT)-mediated deoxyuridine triphosphate biotin nick end labelling (TUNEL) assay, using Apoptag Kit (CHEMICON International, Temecula, CA, USA) according to the manufacturer's instructions.

Light microscopy was performed on an Axiolab Karl Zeiss microscope (Göttingen, Germany), and pictures were taken using a Canon PowerShot G5 camera (Tokyo, Japan). The number of TUNEL and PCNA-positive stained cells were quantified by counting 10 random fields using ImageJ, NIH software.

Evaluation of periodontal bone loss (distance method)

The methods used herein were previously reported by us (Prestifilippo *et al*, 2012). Three lingual and three vestibular distances (mesial, central, distal) were measured from the cemento-enamel junction (CEJ) to the most apical area of theca (Amer *et al*, 2011). Alveolar bone loss in mm was represented as the mean value of the 6 recordings on each molar.

Evaluation of PGE level

PGE content was evaluated as described by Amer *et al* (2011). Briefly, gingiva and SMG were homogenized in ethanol and centrifuged, and the supernatants were collected and evaporated. PGE content was evaluated by radioimmunoassay.

Determination of TNFα

Submandibular gland was homogenized in PBS containing protease inhibitor cocktail (Sigma Chemical Co., St. Louis, MO, USA). The concentration of rat TNFα was determined using a sandwich ELISA according to the manufacturer's instructions (BD Pharmingen, USA).

Statistical analysis

Evaluations were performed with ANOVA followed by Newman–Keuls' multiple comparison test using GraphPad Prism version 5.00 software (San Diego, CA, USA). *P* values <0.05 were considered significant.

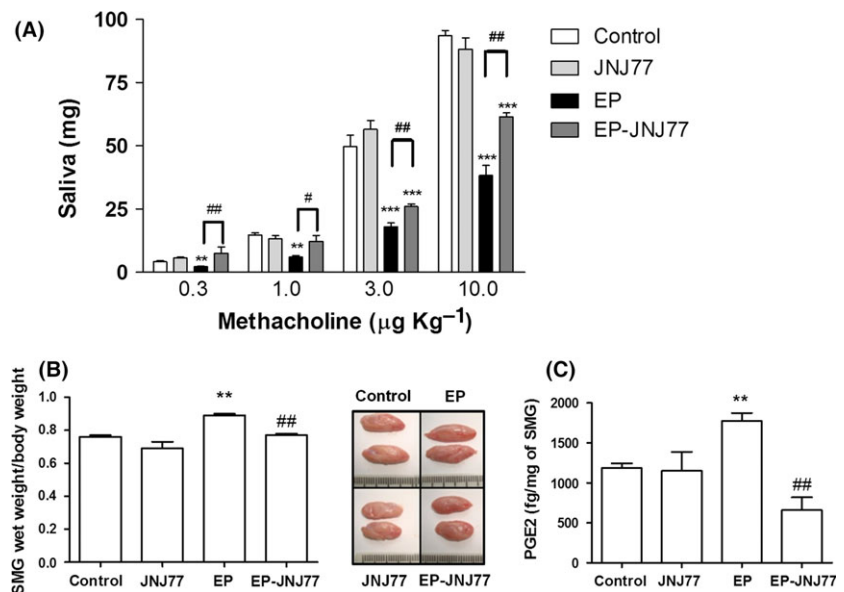
Results

JNJ777120 reduces periodontitis-induced impairment of SMG

Histopathological studies show that periodontitis induced alteration of the epithelial architecture of SMG and produced numerous histological changes, which include enhanced vacuolization, necrosis, morphologically typical apoptosis and focal haemorrhage. All periodontitis-induced histological changes were reduced with subcutaneous JNJ777120 treatment (Figure 1). Also, a significant increase in wet weight and size of the gland based on hyperplastic process without inflammatory cell mobilization (Figure 2B) and an increase in PGE2 content were observed in SMG of EP group, while JNJ777120 blocked these effects (Figure 2C).

The preservation of the histological characteristics of the SMG produced by JNJ777120 in periodontitis model was related to the preservation of SMG functionality. Periodontitis produced a two-fold decrease in methacholine-induced salivation, while JNJ777120 partially prevented that effect (Figure 2A).

Figure 2 JNJ777120 reverses periodontitis-induced salivary dysfunction and inflammatory mediator in the rat SMG. (A) Mean methacholine-stimulated salivary secretion in the untreated (Control), JNJ777120 (JNJ77), experimental periodontitis (EP) and JNJ77-experimental periodontitis (EP-JNJ77) groups expressed as mg of saliva/gland. Error bars represent the means ± SEM. ***P* < 0.01, ****P* < 0.001 vs control; #*P* < 0.05, ##*P* < 0.01 vs EP. (B) Submandibular gland (SMG) wet weight measured as SMG's percentage of body weight. Data represent the means ± SEM. ***P* < 0.01 vs control; ##*P* < 0.01 vs EP. Inset: macroscopic view of SMG. (C) Mean PGE2 content expressed in fg/mg of SMG. Error bars represent the means ± SEM. ***P* < 0.01 vs control; ##*P* < 0.01 vs EP



Aquaporin 5 (AQP5), a water channel involved in salivation (Ishikawa *et al*, 2005), was expressed mainly in the apical membranes of SMG acinar cells in all groups except for EP group, which showed reduced and impaired localization of AQP5 immunoreactivity in SMG (Figure 1A).

In addition, PCNA expression was scarce in SMG of untreated and JNJ7777120 groups. Periodontitis reduced PCNA-positive cells per field, while JNJ7777120 treatment partially blocked that effect (Figure 1).

We further evaluated the TUNEL positivity as an indicator of apoptosis. Periodontitis increased the number of glandular apoptotic cells and JNJ7777120 prevented that outcome (Figure 1).

JNJ7777120 ameliorates periodontitis-induced bone loss and gingival inflammation

Together with a decrease in salivation, EP increased alveolar bone loss, effect that was prevented by JNJ7777120 (Figure 3A,B).

Histological studies on gingival tissue demonstrated normal characteristics in untreated or JNJ7777120-treated animals. Gingival tissue derived from EP group revealed hyperkeratosis, acanthosis and injury of epithelial layers with inflammatory infiltrates. On the other hand, JNJ7777120 reduced EP-induced inflammatory infiltration and hyperkeratosis in gingival tissue (Figure 3C).

We also evaluated PGE2 content, a well-known mediator of periodontal disease (Kinney *et al*, 2007). Periodonti-

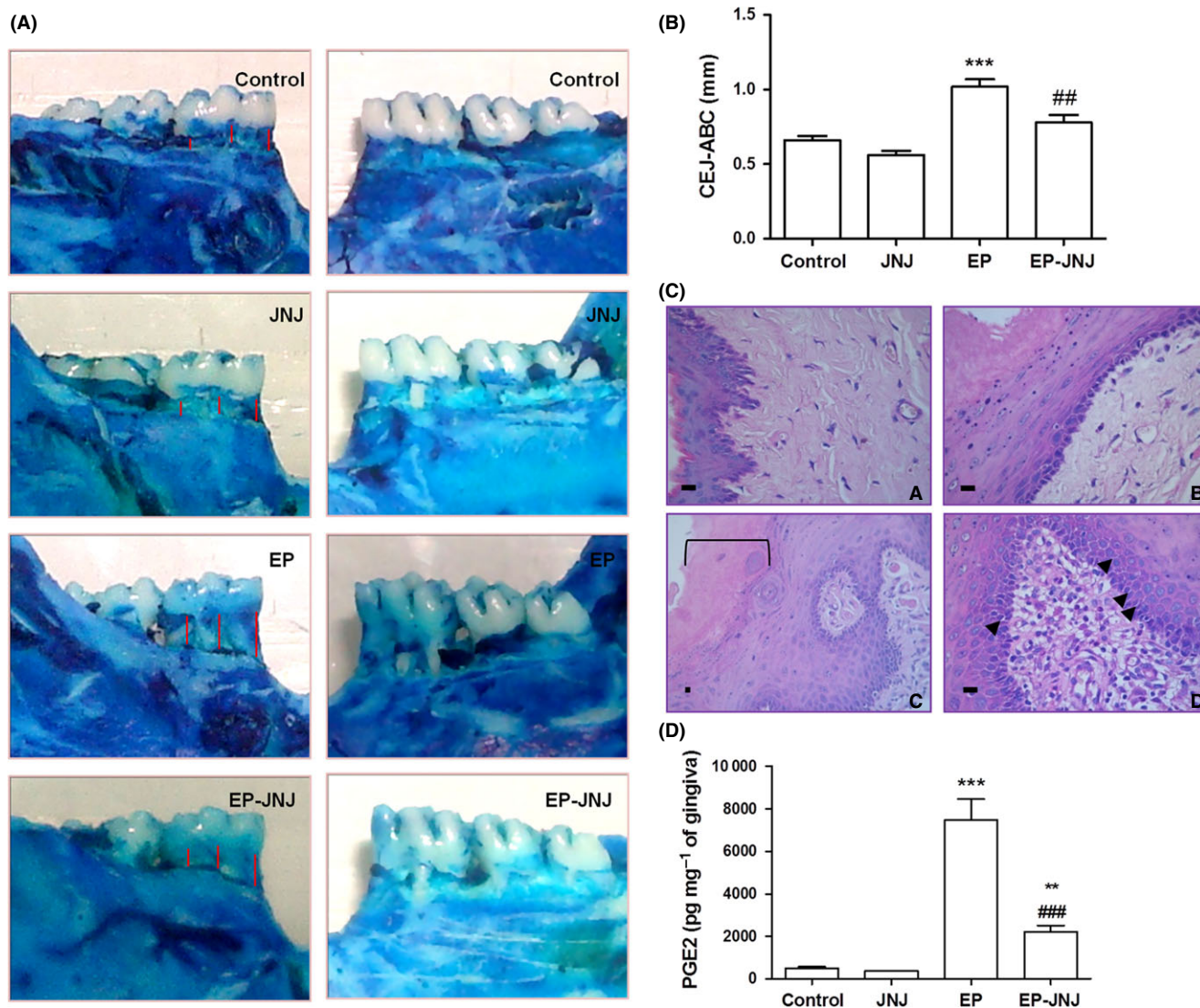


Figure 3 JNJ7777120 reduces EP-induced bone loss and inflammation of gingival tissue. (A) Photographs of mandibles showing lingual (left column) and vestibular (right column) sections of lower first molars in the untreated (Control), experimental periodontitis (EP), JNJ7777120 (JNJ77) and experimental periodontitis-JNJ7777120-(EP-JNJ77) groups. (B) Measures of lingual and vestibular bone loss, as distances between the CEJ-ABC (I), are expressed as means \pm SEM. *** P < 0.001 vs control, ## P < 0.01 vs EP. (C) Histopathological analysis of gingival tissue. (a) Muco-gingival epithelium displaying normal characteristics in untreated or JNJ7777120-treated animals. (b) Almost normal epithelial features without inflammatory infiltrates and reduced hyperkeratosis in EP-JNJ7777120 gingiva. (c) Hyperkeratosis (Π) and impairment of epithelial layers are observed at lower magnification, in gingival tissue of EP group. (d) Inflammatory infiltrates with neutrophils and lymphocytes and also acanthosis (arrow) and increased cellularity in the basal layer are shown at higher magnification. H&E stain. 400 \times and 630 \times magnification. Scale bar= 20 μ m. (D) Mean PGE2 content expressed in pg/mf of gingiva. Error bars represent the means \pm SEM. ** P < 0.01, *** P < 0.001 vs control; ### P < 0.001 vs EP

tis augmented PGE₂ gingival level, while JNJ777120 treatment reduced it and preserved gingival histological features of rats with EP (Figure 3C,D).

Local H₄R ligands' administration improves bone and gingiva of rat with periodontitis

We additionally evaluated whether the local administration of JNJ777120 and, also another H₄R antagonist, JNJ10191584 in the form of gel could be effective in preventing EP-induced alterations. Results indicate that both compounds diminished the alveolar bone loss and preserved histological features of gingiva (Figure 4A,C). They also reduced the inflammatory infiltrates in the subepithelial areas and blocked EP-induced increased gingival PGE₂ and TNF α levels (Figure 4B,C).

Discussion

The evidence presented showed that 2 weeks of EP produced a considerable decrease in SMG salivary secretion, indicating that SMG functionality is severely altered and suggesting the development of anatomical and/or mechanistic alterations under this pathological condition. Accordingly, we previously reported that EP caused a marked reduction in the capacity of SMG to secrete saliva in response to cholinergic stimulation (Amer *et al*, 2011; Prestifilippo *et al*, 2012). The inhibitory effect on salivation induced by periodontitis was partially prevented by subcutaneously administered JNJ777120 treatment. In this line, we have earlier reported that JNJ777120

compound improved radiation-induced hyposialia (Martinel Lamas *et al*, 2013).

The periodontitis-induced altered functionality of SMG was associated with several histological changes of SMG, increased apoptosis and also decreased PCNA levels. In agreement with these results, other authors hypothesize that periodontitis-induced vacuolization and apoptosis of the acinar cells may alter salivation (Ekuni *et al*, 2010). Furthermore, similar histological features are observed after irradiation that also leads to hyposialia (Medina *et al*, 2011). JNJ777120 compound prevented both periodontitis-induced histological and functional SMG's impairments.

H₄ receptor expression has been recently identified in salivary glands of healthy subjects, in glandular epithelial cells as well as in infiltrating immune cells. It is not detected in patients with primary SS, a well-known autoimmune pathology that manifests itself with an altered quality and quantity of saliva (Atkinson *et al*, 2005), suggesting that H₄R may be involved in salivary gland function (Stegaev *et al*, 2012).

Channel AQP5 regulates water secretion (Ishikawa *et al*, 2005) and plays a key role in salivation, since it was demonstrated that mice lacking AQP5 show decreased salivary gland functionality (Ma *et al*, 1999). In addition, SS-induced hyposialia is associated with altered AQP5 translocation to the luminal side (Tsubota *et al*, 2001). AQP5 is normally located at the apical plasma membrane of rat SMG (Gresz *et al*, 2004). Present results show that JNJ777120 seemed to block periodontitis-induced alteration of AQP5 immunoreactivity and localization. In

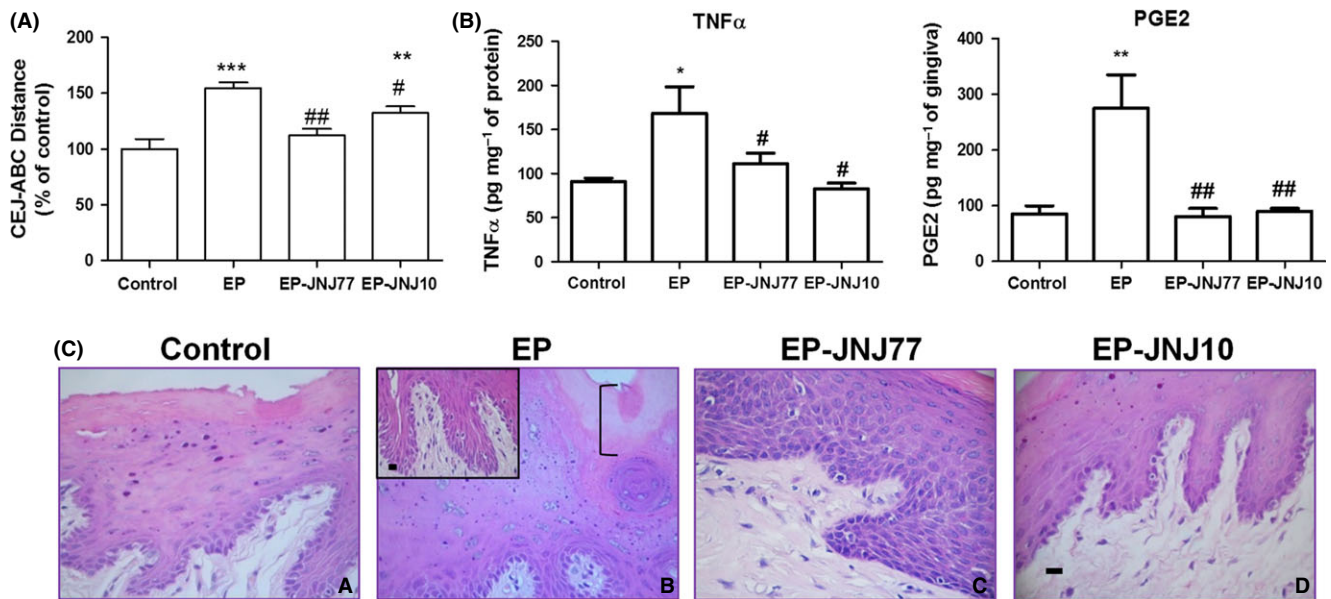


Figure 4 Local administration of JNJ777120 and JNJ10191584 improves EP-induced altered parameters. (A) Measures of lingual and vestibular bone loss, as distances between the CEJ-ABC are expressed as percentage of control values. Data represent the means \pm SEM. ***P* < 0.01, ****P* < 0.001 vs control; #*P* < 0.05, ###*P* < 0.001 vs EP. (B) Mean PGE₂ content expressed in pg/mg of gingiva and TNF α levels expressed in pg/mg of protein. Data represent the means \pm SEM. **P* < 0.05, ***P* < 0.01 vs control; #*P* < 0.05, ##*P* < 0.01 vs EP. (C) Histopathological analysis of gingival tissue. (a) Mucogingival epithelium displaying normal characteristics in control animals. (b) Hyperkeratosis (I) and impairment of epithelial layers with increased cellularity in the basal layer. Inset of the subepithelial area: Inflammatory infiltrates and increased intercellular space with possible detachment are observed in gingival tissue of EP group. Almost normal epithelial features without inflammatory infiltrates and reduced hyperkeratosis in (c) EP-JNJ777120 and (d) EP-JNJ10191584 gingiva. H&E stain. 630 \times magnification. Scale bar = 20 μ m

agreement with these results, ionizing radiation significantly induced salivary dysfunction (Burlage *et al*, 2008; Medina *et al*, 2011) and also downregulated AQP5 expression in the SMG, effects that were blocked by JNJ777120 administration (Martinel Lamas *et al*, 2013). AQP5 immunoreactivity was also reduced at day 7 of ligation-induced SMG atrophy (Silver *et al*, 2010). Furthermore, lipopolysaccharide (LPS) administration inhibits salivary secretion and also downregulates AQP5 mRNA expression through NF- κ B activation via TLR4 (Yao *et al*, 2010). JNJ777120 could interfere with the activation of this pathway, blocking the effect of LPS (Thurmond *et al*, 2004; Cowden *et al*, 2013).

As mentioned, JNJ777120 treatment significantly prevents SMG and alveolar bone injury taking place during periodontitis. In agreement with these results, submandibulectomy deleteriously affects alveolar bone, favouring the development of pathological bacteria (Hiroto *et al*, 2008; Vacas *et al*, 2008).

PGE2 is a pro-inflammatory mediator involved in periodontitis and numerous inflammatory diseases (Kinney *et al*, 2007). Results indicate that PGE2 is significantly increased in gingival and SMG tissues of animals with EP, suggesting an inflammatory response that correlates with the bone loss observed. JNJ777120 treatment partially and completely blocks the higher EP-induced PGE2 level in gingiva and SMG, respectively. Also, altered histological features and inflammatory infiltrates are observed in gingiva-mucosal tissues of the periodontitis group, effects that were prevented by JNJ777120. These findings and the fact that the local application of JNJ777120 and JNJ10191584 in the form of gel not only reduced alveolar bone loss but also decreased the increased PGE2 and TNF α levels and inflammatory infiltrates in gingival tissue of rats with periodontitis, also suggest a direct effect of the compounds on periodontal tissues as anti-inflammatory agents. These results are consistent with the well-established anti-inflammatory properties of these compounds in different preclinical models of inflammatory diseases (Thurmond *et al*, 2004; Suwa *et al*, 2011; Cowden *et al*, 2013; Deiteren *et al*, 2015). Nonetheless, we cannot discard the action of the compounds on salivary gland epithelial cells that could contribute to the observed effects.

It is important to highlight that previously reported data paradoxically showed similar improvements of periodontal disease employing subcutaneous histamine at low concentration (0.1 mg/kg), indicating that other histamine receptor subtype could also be involved in periodontal healthiness (Prestifilippo *et al*, 2012).

Conclusions

The H₄R antagonists ameliorate periodontitis-induced injury on SMG, gingival tissue and bone structure, suggesting that pharmacological targeting of H₄R could be an attractive therapeutic approach to the improvement of periodontal disease. Noteworthy, the local administration route is also beneficial for improving periodontal parameters, which highlights the potential clinical value of these compounds.

Acknowledgements

Work supported by grants from the University of Buenos Aires 20020130200148BA, PO02-PDTS, CONICET (PIP 11220110101121), National Cancer Institute of Argentina and Roemmers Foundation. We thank Dr. Nicholas Carruthers and Dr. Robin Thurmond from Janssen, Johnson & Johnson for JNJ777120 and JNJ10191584 compounds. We also thank Miss Natalia Rivera for proof reading the manuscript.

Author contributions

JPP, JFS, VAM, research design; JPP, JFS, DML, ECR, CM, JCP, JCE, VAM research performing; VAM, ESR, JCE participated in acquisition of funding; JPP, JFS, CER, JCP, VAM, data analysis; ESR, JPP, JCE, JFS, VAM, involved in manuscript editing and critical review; JPP, JFS, VAM manuscript writing.

References

- Amer M, Elverdin JC, Fernandez-Solari J, Medina VA, Chiarenza AP, Vacas MI (2011). Reduced methacholine-induced submandibular salivary secretion in rats with experimental periodontitis. *Arch Oral Biol* **56**: 421–427.
- Atkinson JC, Grisius M, Massey W (2005). Salivary hypofunction and xerostomia: diagnosis and treatment. *Dent Clin North Am* **49**: 309–326.
- Burlage FR, Roesink JM, Kampinga HH *et al* (2008). Protection of salivary function by concomitant pilocarpine during radiotherapy: a double-blind, randomized placebo-controlled study. *Int J Radiat Oncol Biol Phys* **70**: 14–22.
- Cowden JM, Yu F, Challapalli M *et al* (2013). Antagonism of the histamine H₄ receptor reduces LPS-induced TNF production in vivo. *Inflamm Res* **62**: 599–607.
- Deiteren A, De Man JG, Pelckmans PA, De Winter BY (2015). Histamine H₄ receptors in the gastrointestinal tract. *Br J Pharmacol* **172**: 1165–1178.
- Dodds MW, Johnson DA, Yeh CK (2005). Health benefits of saliva: a review. *J Dent* **33**: 223–233.
- Ekuni D, Endo Y, Irie K *et al* (2010). Imbalance of oxidative/anti-oxidative status induced by periodontitis is involved in apoptosis of rat submandibular glands. *Arch Oral Biol* **55**: 170–176.
- Forde MD, Koka S, Eckert SE, Carr AB, Wong DT (2006). Systemic assessments utilizing saliva: part I general considerations and current assessments. *Int J Prosthodont* **19**: 43–52.
- Gresz V, Kwon TH, Gong H *et al* (2004). Immunolocalization of AQP-5 in rat parotid and submandibular salivary glands after stimulation or inhibition of secretion in vivo. *Am J Physiol Gastrointest Liver Physiol* **287**: G151–G161.
- Guggenheimer J, Moore PA (2003). Xerostomia: etiology, recognition and treatment. *J Am Dent Assoc* **134**: 61–69.
- Hiroto T, Yoshihara A, Ogawa H, Ito K, Igarashi A, Miyazaki H (2008). Salivary spinability and periodontal disease progression in an elderly population. *Arch Oral Biol* **53**: 1071–1076.
- Ishikawa Y, Yuan Z, Inoue N *et al* (2005). Identification of AQP5 in lipid rafts and its translocation to apical membranes by activation of M3 mAChRs in interlobular ducts of rat parotid gland. *Am J Physiol Cell Physiol* **289**: 1303–1311.
- Kholy KE, Genco RJ, Van Dyke TE (2015). Oral infections and cardiovascular disease. *Trends Endocrinol Metab* **26**: 315–321.
- Kinney JS, Ramseier CA, Giannobile WV (2007). Oral fluid-based biomarkers of alveolar bone loss in periodontitis. *Ann N Y Acad Sci* **1098**: 230–251.

- Leurs R, Chazot PL, Shenton FC, Lim HD, de Esch IJ (2009). Molecular and biochemical pharmacology of the histamine H₄ receptor. *Br J Pharmacol* **157**: 14–23.
- Ma T, Song Y, Gillespie A, Carlson EJ, Epstein CJ, Verkman AS (1999). Defective secretion of saliva in transgenic mice lacking aquaporin-5 water channels. *J Biol Chem* **274**: 20071–20074.
- Martinel Lamas DJ, Carabajal E, Prestifilippo JP et al (2013). Protection of radiation-induced damage to the hematopoietic system, small intestine and salivary glands in rats by JNJ7777120 compound, a histamine H₄ ligand. *PLoS ONE* **26**: e69106.
- Medina VA, Rivera ES (2010). Histamine receptors and cancer pharmacology. *Br J Pharmacol* **61**: 755–767.
- Medina VA, Prestifilippo JP, Croci M et al (2011). Histamine prevents functional and morphological alterations of submandibular glands induced by ionising radiation. *Int J Radiat Biol* **87**: 284–292.
- Prestifilippo JP, Fernandez-Solari J, Elverdin JC (2011). Functional and morphological alterations induced by uranyl nitrate in rat submandibular gland. *Toxicol Environ Chem* **93**: 110–109.
- Prestifilippo JP, Carabajal E, Croci M et al (2012). Histamine modulates salivary secretion and diminishes the progression of periodontal disease in rat experimental periodontitis. *Inflamm Res* **61**: 455–461.
- Rink L, Kirchner H (1996). Recent progress in the tumor necrosis factor alpha field. *Int Arch Allergy Immunol* **111**: 199–209.
- Shaik MM, Ahmad S, Gan SH et al (2014). How do periodontal infections affect the onset and progression of Alzheimer's disease? *CNS Neurol Disord Drug Targets* **13**: 460–466.
- Silver N, Proctor GB, Arno M, Carpenter GH (2010). Activation of mTOR coincides with autophagy during ligation-induced atrophy in the rat submandibular gland. *Cell Death Dis* **1**: e14.
- Stegaev V, Sillat T, Porola P et al (2012). First identification of H₄ histamine receptor in healthy salivary glands and in focal sialadenitis in Sjögren's syndrome. *Arthritis Rheum* **64**: 2663–2668.
- Suwa E, Yamaura K, Oda M, Namiki T, Ueno K (2011). Histamine H₄ receptor antagonist reduces dermal inflammation and pruritus in a hapten-induced experimental model. *Eur J Pharmacol* **667**: 383–388.
- Tatakis DN (1993). Interleukin-1 and bone metabolism: a review. *J Periodontol* **64**: 416–431.
- Taubman MA, Valverde P, Han X, Kawai T (2005). Immune response: the key to bone resorption in periodontal disease. *J Periodontol* **76**: 2033–2041.
- Thurmond RL, Desai PJ, Dunford PJ et al (2004). A potent and selective histamine H₄ receptor antagonist with anti-inflammatory properties. *J Pharmacol Exp Ther* **309**: 404–413.
- Tsubota K, Hirai S, King LS, Agre P, Ishida N (2001). Defective cellular trafficking of lacrimal gland aquaporin-5 in Sjögren's syndrome. *Lancet* **357**: 688–689.
- Vacas MI, Amer M, Chiarenza AP, Luchelli MA, Mandalunis PM, Elverdin JC (2008). Influence of submandibulectomy on alveolar bone loss in rats. *J Periodontol* **79**: 1075–1080.
- Yao C, Purwanti N, Karabasil MR et al (2010). Potential down-regulation of salivary gland AQP5 by LPS via cross-coupling of NF-kappaB and p-c-Jun/c-Fos. *Am J Pathol* **177**: 724–734.