Experimental and Toxicologic Pathology xxx (2014) xxx–xxx

Contents lists available at ScienceDirect

Experimental and Toxicologic Pathology

journal homepage: www.elsevier.de/etp

Air particulate matter exacerbates lung response on Sjögren's Syndrome animals

S. Ferraro[a,b,*], N. Orona[a,b], L. Villalón[c], P.H.N. Saldiva[d], D.R. Tasat[a,e], A. Berra[c]

[a] School of Science and Technology, National University of San Martín, Martin de Irigoyen 3100, 1653 San Martín, Buenos Aires, Argentina
[b] Committee for Scientific Research, Buenos Aires, Argentina
[c] Department of Pathology, School of Medicine, University of Buenos Aires, Uriburu 950, C1114, Argentina
[d] Institute of Integrated Risk Analysis, National Research Council, Brazil
[e] School of Dentistry, University of Buenos Aires, MT de Alvear 2142, C1122AAH, Argentina

ARTICLE INFO

Article history:
Received 26 March 2014
Accepted 24 October 2014

Keywords:
Lung
Particulate matter
Inflammation
Sjögren Syndrome

ABSTRACT

Epidemiological studies have associated air particulate matter (PM) inhalation with a decline in lung function and increased morbo-mortality due to cardiorespiratory diseases, particularly in susceptible populations. Sjögren's Syndrome (SS) is a chronic autoimmune disease characterized by cellular infiltration in exocrine glands and extraglandular tissue, being the respiratory tract an important target. We evaluated the effect of PM on the airways of NOD mice, which develop SS and BALB/c mice.

BALB/c or NOD mice (2–3 months) were randomized in two groups and exposed to intranasal instillation either with saline (control) or ROFA solution (1 mg/kg body weight). After 24 h, mice were euthanized in order to perform lung histology, or measure total cell number (TCN), differential cell count (DCC) and superoxide anion generation in the bronchoalveolar lavage (BAL) fluid.

BALB/c mice showed normal histoarchitecture, while NOD mice showed lymphocytic peribronchial infiltrates. ROFA exposure affected the respiratory tract from both BALB/c and NOD mice, with a significant increase in the TCN ($p < 0.05$) and generation of O_2^- ($p < 0.05$), as well as an imbalance in the DCC ($p < 0.05$). All histological observations correlated with the cellular parameters evaluated. Lesions in NOD mice were more severe than those of BALB/c, showing cellular infiltration in the alveoli and leading to a greater decrease in the alveolar space.

We have proved that in this experimental Sjögren's Syndrome animal model (NOD mice); airborne pollution exacerbates pre-existing pulmonary lesions. These findings show experimental evidence on the harmful effects of airborne pollution on the airways of patients with Sjögren's Syndrome.

© 2014 Elsevier GmbH. All rights reserved.

1. Introduction

Particulate matter (PM) is a major component of urban air pollution derived from fossil-fueled combustion, vehicular transport, industrial emissions, and many other anthropogenic sources. Many epidemiological and clinical studies have associated PM inhalation with a decline in lung function, increased respiratory symptoms and mortality specially due to cardiorespiratory diseases in susceptible populations (Dockery and Brunekreef, 1996; Darrow et al., 2011; Beelen et al., 2008; Forastiere et al., 2005; Pope et al., 2009).

The adverse health effects induced by PM largely depend on its physical and chemical characteristics (Osornio-Vargas et al., 2003). Regarding their chemical composition, transition metals (Rondini et al., 2010) are crucial in organ, tissue and cell injury (Gualtieri et al., 2010). Residual oil fly ash (ROFA) is an important air pollutant emitted as a by-product of the combustion of residual fuel oil, commonly used in environmental studies as a particulate matter able to induce inflammation and oxidative stress due to its metal-rich composition (Ghio et al., 2002; Roberts et al., 2007). In experimental animal models, ROFA induces in the respiratory tract, a variety of pro-inflammatory responses including recruitment of polymorphonuclear cells in the lung parenchyma, augmentation in mucin PAS-positive cells in the respiratory epithelium and the release of pro-inflammatory cytokines such as IL-1, IL-6, IL-8 and

* Corresponding author at: Centro de Estudios en Salud y Medioambiente, Escuela de Ciencia y Tecnología, Universidad Nacional de San Martín, Martín de Irigoyen 3100, Argentina. Tel.: +54 11 4 580 7289x103.
E-mail address: sebaferraro@gmail.com (S. Ferraro).

http://dx.doi.org/10.1016/j.etp.2014.10.007
0940-2993/© 2014 Elsevier GmbH. All rights reserved.

TNFα (Antonini et al., 2004; Gardner et al., 2000; Gavett et al., 1999; Ghio et al., 2002). Additionally, ROFA not only exerts an inflammatory response but also induces, due to the high metal content that in turn increases the generation of reactive oxygen species (ROS), an imbalance on the oxidative metabolism (Martin et al., 2007, 2010). Furthermore, ROFA administrated to mice with allergen-induced pulmonary inflammation resulted in an increase in Th2 cytokine production, eosinophil recruitment, and airway hyperresponsiveness (Goldsmith et al., 1999). However, the effect of ROFA on patients or animals with previous pulmonary autoimmune affections has not been investigated yet.

Sjögren's Syndrome (SS) is one of the three most common systemic autoimmune diseases characterized by cellular infiltration in exocrine glands and extraglandular tissue. As many as 1–2 million people in the United States are affected by SS (Sánchez-Guerrero et al., 2005). The diagnostic criteria include xerosophtalmia and xerostomia, plus the presence of autoimmune criteria (Vitali et al., 2002). Depending on the diagnostic modalities used, the prevalence of respiratory disease in patients with SS varies widely, ranging from 9 to 75% (Cain et al., 1998; Strimlan, 1996; Constantopoulos et al., 1985). Different pulmonary signs have been described in SS, including affection of both superior and inferior airways, interstitial pulmonary disease, pulmonary cysts, and focal or diffuse nodular infiltrate (Cain et al., 1998). Moreover, dry cough can be present in up to a 17% of SS cases (Constantopoulos et al., 1985) and 55% of patients with SS present anomalous cell number count in the bronchoalveolar lavage (BAL) (Manoussakis et al., 1998).

Several studies based on spirometric measures showed the presence of an obstructive component in SS patients' airways (Newball and Brahim, 1977), while those based on metacholine tests showed bronchial hyperreactivity (Potena and La Corte, 1990; Gardiner, 1993). Bronchial affection may be accompanied by dyspnea, commonly associated to an obstructive process. These types of patients possess a peribronchial and periglandular lymphocytic infiltrate, historically known as follicular bronchitis (Strimlan, 1996). Among the pathological findings informed, interstitial lymphocytic pneumonia is the most common one. Therefore SS patients, as many other risk groups which suffer respiratory diseases (asthma, COPD, etc.), can be regarded as a susceptible population.

Non-obese diabetic (NOD) mice are considered a suitable animal experimental model to study this disease, due to the spontaneous development of affections similar to those found on patients who suffer Sjögren Syndrome. Starting on their 8th week of life these mice develop lymphocytic infiltrate, dacryoadenitis, pulmonary alterations, increased expression of cytokines, and sialadenitis with loss of secretory function (Delaleu et al., 2011).

In this context, even though the pulmonary response to ROFA particles on healthy mice (Martin et al., 2010; Cho et al., 2005; Ferraro et al., 2011; Magnani et al., 2011) has been comprehensively researched in several mice strains, the effect of this airborne PM in mice with pre-exisisting pathologies such as SS has not been assessed yet. To the best of our knowledge, this is the first study that provides evidence of the consequences of PM exposure on the lungs of NOD mice, a SS experimental animal model.

Therefore, the aim of this work was to study the effects of ROFA a known air particulate matter, on the respiratory tract of a susceptible population: the NOD mice which spontaneously develop Sjögren Syndrome.

2. Materials and methods

2.1. Animals

Male (2–3 months old) BALB/c and NOD mice were acquired from the animal facilities of the School of Natural and Exact Sciences, University of Buenos Aires and from the Department of Pathology, School of Medicine, University of Buenos Aires, respectively.

Mice employed throughout these experiments were housed in accordance with the NIH Guide for the Care and Use of Laboratory Animals and were fed a regular protein diet and water ad libitum at the breeding facility of the Department of Pathology, School of Medicine, University of Buenos Aires. The business firm of regular protein diet specific for mice is "Asociación Argentina de Cooperativas, Division Nutrición Animal", catalog number 16-014007. All experiments complied with local ethical guidelines.

2.2. ROFA particle sampling

Residual oil fly ash (ROFA) from the Mystic Power Plant, CT, USA, was employed as a recognized, surrogate ambient particulate matter and was generously provided by J. Godleski (Harvard School of Public Health, Boston, MA, USA).

2.3. Animal exposure to ROFA

Either NOD ($n = 14$) or BALB/c ($n = 12$) mice were exposed to ROFA. Particles were suspended in PBS (phosphate buffer solution, pH: 7.2–7.4), sonicated during 10 min and immediately delivered by intranasal instillation (Leong et al., 1998). Intranasal instillation is an effective and noninvasive technique commonly used in toxicity studies (Leong et al., 1998) where the distribution pattern of particles is of crucial importance (Southam et al., 2002). Briefly, mice were anesthetized i.p. with 1 ml kg^{-1} body weight of xylazine (2%) and ketamine (50 mg ml^{-1}) and then were intranasally instilled with 50 μl of a ROFA suspension (1 mg/kg BW). After 24 h, animals were sacrificed by a xylazine–ketamine overdose injection.

2.4. In vivo experimental protocol

NOD or BALB/c mice were divided into two groups: controls instilled with vehicle (PBS) and ROFA instilled animals. As clearly shown in Fig. 1, a total of four subgroups ($n = 6$–7 per subgroup) were generated: BALB/c (instilled with vehicle PBS), BALB/c + ROFA (instilled with 1 mg/kg ROFA), NOD (instilled with vehicle PBS) and NOD + ROFA (NOD mice instilled with 1 mg/kg ROFA). From all four subgroups, broncoalveolar lavage (BAL) fluid was obtained and lungs were processed for histology and histomorphometry. Different biological parameters were evaluated in BAL: total cell number (TCN), differential cell count (DCC), superoxide anion (O_2^-) generation. On lung sections, histology and histomorphometry analysis were performed as described below.

2.5. Lung histology

Lungs from control and particle exposed mice were excised and fixed by immersion in 10% buffered formalin, dehydrated in graded concentrations of alcohol and routine processed for paraffin embedding. Histological sections of 7 μm were cut with a Reichert-Jung micrometer (Nossloch, Germany) for optical microscopy. All samples were stained with hematoxylin–eosin (H&E), Peryodic Acid Schiff (PAS) and Alcyan Blue.

A morphometric analysis was performed using Image Pro Plus software (Media Cybernetics). Microphotographs of paraffin sections stained with hematoxylin–eosin from control and particle-exposed mice were employed. The alveolar space area relative to the total alveolar area of the lung tissue was determined. Results were expressed as the percentage of the lumen area.

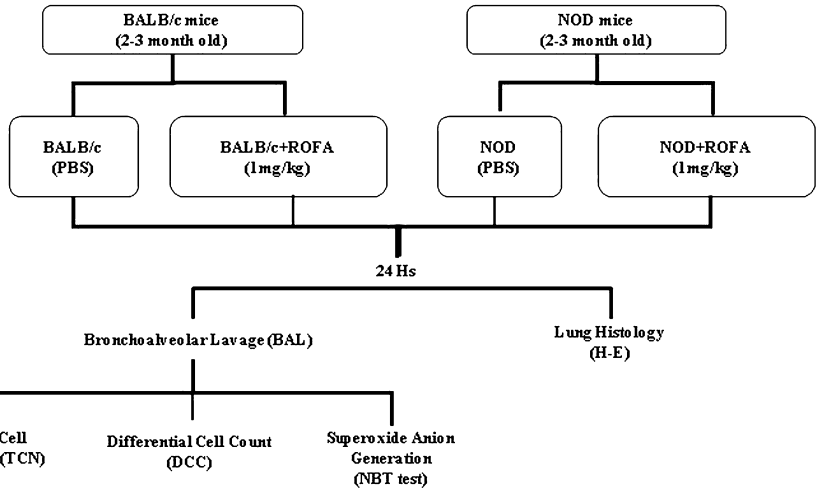

Fig. 1. In vivo experimental protocol diagram. BALB/c or NOD mice (2–3 months of age) were randomized and intranasally instilled either with PBS (control) or ROFA solution (1 mg/kg body weight). All the biological endpoints were performed 24 h post instillation.

2.6. Mice bronchoalveolar lavage (BAL)

BAL was performed as previously described by Tasat and Rey (1987). Briefly, the thoracic cavity was partly dissected and the trachea was cannulated with an 18-gauge needle. The excised lung was then gently massaged and lavaged twelve times with 1 ml of cold sterile PBS (Ca^{++} Mg free, pH 7.2–7.4). The bronchoalveolar lavage fluid (BAL) was immediately centrifuged at 800 × *g* for 10 min at 4 °C and the total cell count determined using a Neubauer chamber. Based on morphological criteria, control animals showed >95% of alveolar macrophages (AM).

2.7. Total cell number (TCN) and differential cell count (DCC)

TCN number was determined under a Neubauer chamber. BAL DCC was performed by fixing the cells in methanol and staining them with H&E. At least 200 cells were counted by light microscopy in each sample.

2.8. Generation of superoxide anion (NBT)

The intracellular release of superoxide anion (O_2^-), a main reactive oxygen species (ROS) generated during the respiratory burst, was evaluated in BAL cells using the NitroBlue Tetrazolium (NBT) reduction test. The NBT reduction test is one of the most commonly used assays to measure superoxide anion generation (O_2^-). NBT is stoichiometrically reduced by O_2^- yielding a violet-blue formazan precipitate. The test was run in triplicates and in the presence or absence of 12-*O*-tetradecanoylphorbol-13-acetate (TPA), a known inductor of O_2^- generation (Segal, 1974). All tubes were incubated with NBT for 45 min at 37 °C. In positive controls TPA was added at a concentration of 0.5 mg ml^{-1} for the last 30 min of reaction. Cells were scored by light microscopy as described elsewhere (Molinari et al., 2000). In all experiments a density of 0.35×10^6 cells/ml was maintained per tube.

2.9. Statistical analysis

One-way ANOVA with Newman–Keuls multiple comparisons post test was performed using GraphPad Prism (version 5.04 for Windows, GraphPad Software, San Diego California USA, www.graphpad.com.). Statistical significance was set at $p < 0.05$. The number of animals and experiments for each group (control and exposed) are shown in the legends of each figure.

3. Results

3.1. ROFA particles induce histological alterations in the lung

Control BALB/c mice displayed normal histoarchitecture (Fig. 2A). By contrast, as shown in Fig. 2B control NOD mice displayed lymphocytic peribronchial infiltrates and presence of intra-alveolar histiocytes; and to a lesser extent peribronchial polymorphonuclear (PMN) infiltrate.

Acute ROFA exposure affected the respiratory tract of both BALB/c and NOD mice (Fig. 2C and D respectively). BALB/c mice exposed to ROFA displayed mononuclear leukocyte and interstitial PMN infiltrate, sub intimal vascular and bronchial wall swelling, increased numbers of goblet cells in the bronchial epithelium, and in some lung areas, collapsed air spaces were found. NOD mice exposed to ROFA elicited mononuclear leukocyte and PMN peribronchial infiltration, as well as presence of PMN in the bronchial and intravascular space, characterized by an exudative lung inflammatory reaction.

3.2. ROFA particles induce changes in BAL cell number and distribution

BAL obtained from control NOD mice displayed more than double the amount of cells obtained from control BALB/c mice. After ROFA intranasal exposure, both BALB/c and NOD mice showed an increase in the BAL TCN and alterations among the distribution of cell subpopulations (DCC) (Fig. 3A and B). Both mice strains showed an increased percentage of PMN cells (mainly neutrophils) (BALB/c: 9.83 ± 1.45% vs BALB/c + ROFA: 52.6 ± 4.8%; NOD: 9.71 ± 1.26% vs NOD + ROFA: 74.91 ± 3.33%, $p < 0.05$). As it is known, these cells are involved in the development of inflammatory reactions in the lung.

3.3. ROFA particles stimulate superoxide anion generation

Superoxide anion generation (O_2^-) was quantified by counting reactive color cells under light microscopy. Fig. 4A shows BAL cells obtained from NOD mice exposed to ROFA particles. In the microphotograph, it can clearly be observed, a few non-reactive cells (colorless) and a larger amount of cells with an intense reaction (dark blue-violet color), consequence of the formazan precipitate.

A significant increase in the generation of O_2^- in BAL cells from ROFA exposed BALB/c or NOD mice is shown in Fig. 4B (BALB/c: 24.76 ± 3.11% vs BALB/c + ROFA: 80.44 ± 3.09%; NOD: 27.99 ± 7.27%

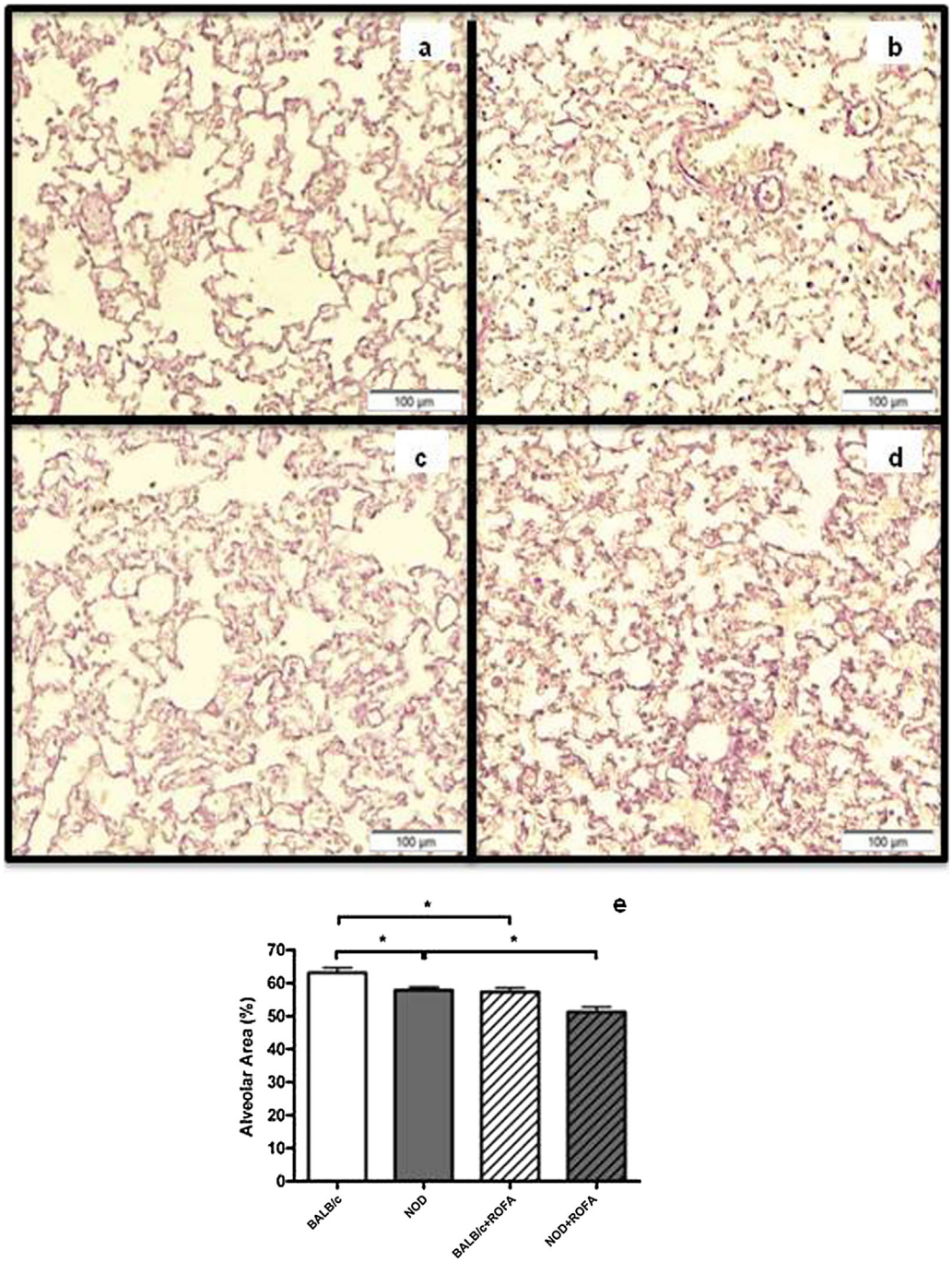

Fig. 2. Lung histology. Microphotographs show representative sections of the lower respiratory tract of control or exposed to ROFA BALB/c or NOD mice. Hematoxylin–eosin stain, original magnification 100×, scale bar is 100 µm. (a) BALB/c (control) non-exposed, (b) NOD non-exposed, (c) BALB/c + ROFA and (d) NOD + ROFA. *Note*: a clear reduction of alveolar spaces is observed due to cell infiltration consistent with acute inflammatory injury in b, c and d. (e) Histogram shows lung histomorphometry. The data are mean ± SD, $n = 6–7$ animals, $^*p < 0.01$, analysis of variance (post test Newman–Keuls).

vs NOD + ROFA: 65.98 ± 4.47%, $p < 0.05$). It is noteworthy that the number of reactive cells elicited by ROFA, is similar to the number of cells found when 12-*O*-tetradecanoylphorbol-13-acetate (TPA), a soluble agent used as positive control, that experimentally induces the generation of superoxide. There was no additive or synergistic outcome when BAL cells were jointly exposed to ROFA and TPA.

4. Discussion

It is known that in normal and susceptible individuals, airborne pollution can induce or exacerbate several pulmonary pathologies. It is also known that most SS patients, while in the development of the disease, could present respiratory affections. Inflammatory response in the lungs is a common complication of several medical conditions and also a rising problem due to acute exposure to environmental pollution, mainly in urban areas (Laumbach and Kipen, 2010; Saini et al., 2010).

In accordance with several authors (Rondini et al., 2010; Goldsmith et al., 1999; Costa et al., 2006), our group has also found that ROFA, a surrogate of ambient pollution with an elevated metal content, mainly vanadium, increased TCN and altered the composition of the cell population presented in the BAL of healthy mice

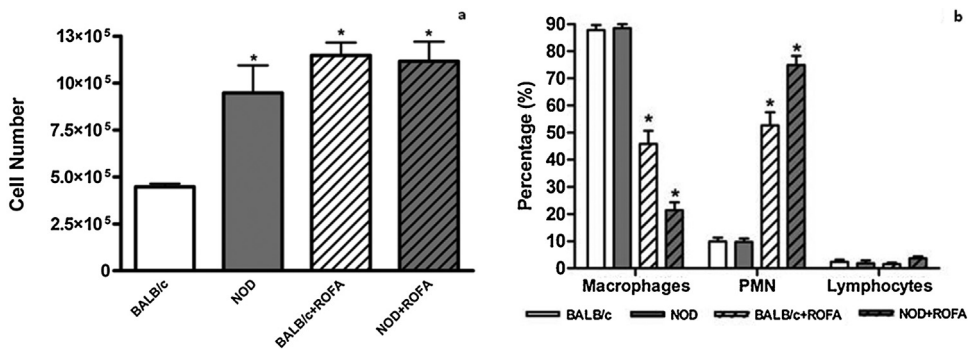

Fig. 3. BAL total cell number and cell distribution. BALB/c and NOD mice were intranasally instilled with ROFA suspension in PBS (1 mg/kg BW). (a) Total cell number (TCN) and (b) cell differential count (DCC). Values are mean ± SD, $n = 6–7$ animals, $^*p < 0.05$ with respect to control non-exposed BALB/c mice, $\#p < 0.05$ with respect to non-exposed NOD mice, analysis of variance (post test Newman–Keuls).

(Martin et al., 2007, 2010; Ferraro et al., 2011). This increase in TCN was followed by a rise in the PMN leucocytes subpopulation, resulting in a reduction of the alveolar space.

There is strong epidemiological evidence of a relationship between particle pollution and alterations in lung function from normal individuals (Saldiva et al., 1994). Recent studies have suggested a role for air pollutants in the exacerbation of respiratory symptoms, mainly from susceptible populations carrying pre-existing respiratory diseases, like asthma or chronic obstructive pulmonary disease (COPD) (Gilmour, 1995; Kelly and Fussell, 2011). Accordingly, we have previously found that the effects elicited by ROFA described above for normal BALB/c animals, held to be true also for animals sensibilized with ovalbumin, a mouse model that mimics pulmonary allergy (Sánchez-Guerrero et al., 2005; Fenoy et al., 2009). Even more, our observations are in agreement with Miyabara et al. (1998) who showed that inhaling of diesel exhaust particles (air PM with no metal content), after ovalbumin sensibilization, produced a severe pulmonary allergic response with eosinophils presence and proinflammatory cytokine production. Thus, it is clear that air PM, irrespective of its size and composition, produces an adverse biological impact on the airways of healthy animals which is largely aggravated in susceptible subpopulations.

Regarding Sjögren's Syndrome, the most common lung histological patterns are nonspecific interstitial pneumonia, with or without lymphocytic and follicular bronchitis (Shi et al., 2009). In accordance with these data, NOD mice displayed a slight peribronchial lymphoplasmacytic infiltrate with intra-alveolar histiocytic and peribronchial polymorphonuclear cells infiltrate. When exposed to ROFA, NOD mice lungs showed an exacerbated response, with an increase on peribronchial histological alterations, with pneumonia foci affecting the interstice and the parenchyma diminishing the alveolar space, driven mostly by PMN recruitment.

Bronchoalveolar lavage allows for an assessment of the lung's health, indicating possible pathologies. BAL cellular analysis in SS patients with respiratory disorders denotes alveolitis with increased numbers of neutrophils, macrophages and lymphocytes (McGrath-Morrow et al., 2006). Furthermore, these patients display the existence of PMN alveolar infiltrate and bronchoalveolar secretions with oxygen radicals, being these two distinctive features associated with a progressive deterioration of the respiratory function and increased oxidative stress status (McGrath-Morrow et al., 2006; Wanchu et al., 2000; Ryo et al., 2006).

In our work we found that non-exposed NOD mice showed altered proportions in the BAL cellular subpopulations and a reduced alveolar area when compared to normal BALB/c. Nevertheless, even though NOD mice present an inflammatory condition, ROFA was still able to induce a greater PMN alveolar infiltrate and a diminished alveolar area when compared to NOD mice. In agreement with the lymphoplasmacytic infiltration observed in lung sections, the degree of glandular (salivary and/or lacrimal) destruction was related to the progressive development of lymphocytic infiltrations which are composed primarily of CD4+ and CD8+ T cells (Skopouli et al., 1991), B cells (Adamson et al., 1983), macrophages, and dendritic cells (Manoussakis et al., 2007).

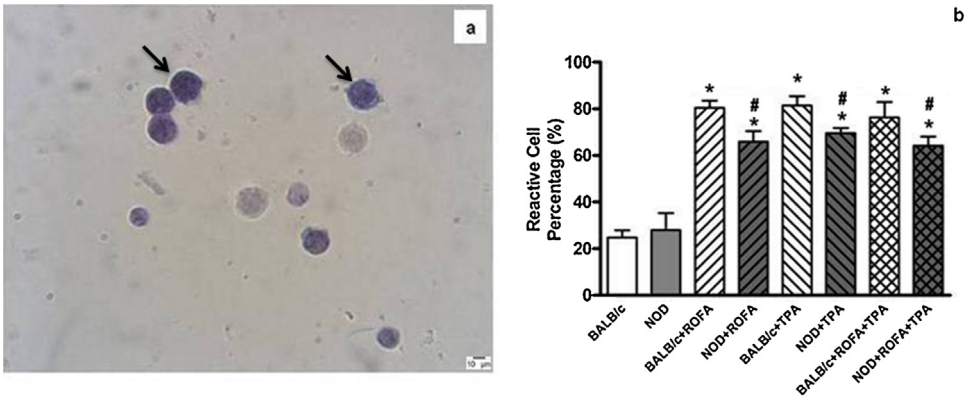

Fig. 4. BAL superoxide anion generation. BAL cells were obtained from animal groups described in Fig. 1. (a) Microphotograph shows a heterogeneous response with varying degree of reaction among BAL cells obtained from NOD non-exposed animals after NBT test was perfomed. Arrows point out clear reactive cells exhibiting a dark blue/violet color, original magnification 400×, scale bar is 10 μm. (b) Percentage of reactive cells as estimated by the NBT reduction test. All treatments increased the generation of superoxide anion with respect to the basal reaction elicited by either non-exposed BALB/c or NOD animals. Values are mean ± SD, $n = 6–7$ animals, $^*p < 0.05$ with respect to control non-exposed BALB/c mice, $\#p < 0.05$ with respect to non-exposed NOD mice, analysis of variance (post test Newman–Keuls).

Please cite this article in press as: Ferraro S, et al. Air particulate matter exacerbates lung response on Sjögren's Syndrome animals. Exp Toxicol Pathol (2014), http://dx.doi.org/10.1016/j.etp.2014.10.007

BALB/c exposed mice showed a significative reduction of the alveolar space, still it is worth to note that no differences were observed between BALB/c + ROFA and NOD mice. This could be due to the inflammatory condition present in the latter. Hence, due to its metal-rich chemical composition, ROFA in our in vivo model was able to induce inflammatory processes in the lungs independently of the mouse strain employed (Cho et al., 2005).

The lung inflammatory response elicited by ROFA in both mice strains studied was mainly sustained by neutrophil cell recruitment as well as a rise in the ROS generation after ROFA exposition. The augmented ROS generation might be triggering cytotoxicity mechanisms, which can lead to the inflammatory response seen in the lung.

In summary, exposure to ROFA increased TCN, altered the composition of the cell population present in the BAL and induced the generation of superoxide anion. The augment in TCN was associated to the PMN subpopulation, which in turn and in agreement with Martin et al. (2010), resulted in a reduction of the alveolar space. We have proved that in this experimental Sjögren's Syndrome animal model (NOD mice) airborne pollution exacerbates pre-existing pulmonary lesions, producing pneumonia foci within 24 h. These findings show experimental evidence of the harmful effects of airborne pollution on the airways of patients with Sjögren's Syndrome.

Acknowledgements

This work was supported by the UNSAM SJ10/54, PICT-2007-2252 and PICT-2010-1661. The authors would like to thank to the technical assistance of Francisco Gallo from the Center of Studies in Health and Environment, University of San Martin and Graciela Zaccagnini, Center of Immunopathologies, Department of Pathology, Buenos Aires University.

References

Adamson TC, Fox RI, Frisman DM, Howell FV. Immunohistologic analysis of lymphoid infiltrates in primary Sjogren's syndrome using monoclonal antibodies. J Immunol 1983;130(1):203–8.
Antonini JM, Taylor MD, Leonard SS, Lawryk NJ, Shi X, Clarke RW, et al. Metal composition and solubility determine lung toxicity induced by residual oil fly ash collected from different sites within a power plant. Mol Cell Biochem 2004;255:257–65.
Beelen R, Hoek G, van den Brandt PA, Goldbohm RA, Fischer P, Schouten LJ, et al. Long-term effects of traffic-related air pollution on mortality in a Dutch cohort (NLCS-AIR study). Environ Health Perspect 2008;116:196–202.
Cain HC, Noble PW, Matthay RA. Pulmonary manifestations of Sjögren's syndrome. Clin Chest Med 1998;19:687–99.
Cho HY, Jedlicka AE, Clarke R, Kleeberger SR. Role of Toll-like receptor-4 in genetic susceptibility to lung injury induced by residual oil fly ash. Physiol Genomics 2005;22:108–17.
Constantopoulos SH, Papadimitrio CS, Moutsopoulos HM. Respiratory manifestations in primary Sjögren's syndrome. Chest 1985;88:226–9.
Costa DL, Lehmann JR, Winsett D, Richards J, Ledbetter AD, Dreher KL. Comparative pulmonary toxicological assessment of oil combustion particles following inhalation or instillation exposure. Toxicol Sci 2006;91:237–46.
Darrow LA, Klein M, Strickland MJ, Mulholland JA, Tolbert PE. Ambient air pollution and birth weight in full-term infants in Atlanta, 1994–2004. Environ Health Perspect 2011;119:731–7.
Delaleu N, Nguyen CQ, Peck AB, Jonsson R. Sjogren's syndrome: studying the disease in mice. Arthritis Res Ther 2011;13(3):217–33.
Dockery DW, Brunekreef B. Longitudinal studies of air pollution effects on lung function. Am J Respir Crit Care Med 1996;154:250–6.
Fenoy I, Giovannoni M, Batalla E, Martin V, Frank FM, Piazzon I, et al. *Toxoplasma gondii* infection blocks the development of allergic airway inflammation in BALB/c mice. Br Soc Immunol Cli Exp Immunol 2009;155:275–84.
Ferraro SA, Yakisich JS, Gallo FT, Tasat DR. Simvastatin pretreatment prevents ambient particle-induced lung injury in mice. Inhal Toxicol 2011;23:889–96.
Forastiere F, Stafoggia M, Picciotto S, Bellander T, D'Ippoliti D, Lanki T, et al. A case-crossover analysis of out-of-hospital coronary deaths and air pollution in Rome, Italy. Am J Respir Crit Care Med 2005;172:1549–55.
Gardiner P. Primary Sjögren's syndrome. Baillieres Clin Rheumatol 1993;7:59–77.
Gardner SY, Lehmann JR, Costa DL. Oil fly ash-induced elevation of plasma fibrinogen levels in rats. Toxicol Sci 2000;56:175–80.
Gavett SH, Madison SL, Stevens MA, Costa DL. Residual oil fly ash amplifies allergic cytokines, airway responsiveness, and inflammation in mice. Am J Respir Crit Care Med 1999;160:1897–904.
Ghio AJ, Silbajoris R, Carson JL, Samet JM. Biologic effects of oil fly ash. Environ Health Perspect 2002;110:89–94.
Gilmour MI. Interaction of air pollutants and pulmonary allergic responses in experimental animals. Toxicology 1995;105:335–42.
Goldsmith CA, Hamada K, Ning Y, Qin G, Catalano P, Krishna Murthy GG, et al. Effects of environmental aerosols on airway hyperresponsiveness in a murine model of asthma. Inhal Toxicol 1999;11:981–98.
Gualtieri M, Ovrevik J, Holme JA, Perrone MG, Bolzacchini E, Schwarze PE, et al. Differences in cytotoxicity versus pro-inflammatory potency of different PM fractions in human epithelial lung cells. Toxicol In Vitro 2010;24:29–39.
Kelly FJ, Fussell JC. Air pollution and airway disease. Clin Exp Allergy 2011;41:1059–107.
Laumbach RJ, Kipen HM. Acute effects of motor vehicle traffic related air pollution exposures on measures of oxidative stress in human airways. Ann N Y Acad Sci 2010;1203:107–12.
Leong BK, Coombs JK, Sabaitis CP, Rop DA, Aaron CS. Quantitative morphometric analysis of pulmonary deposition of aerosol particles inhaled via intratracheal nebulization, intratracheal instillation or nose-only inhalation in rats. J Appl Toxicol 1998;18:149–60.
Magnani ND, Marchini T, Tasat DR, Alvarez S, Evelson PA. Lung oxidative metabolism after exposure to ambient particles. Biochem Biophys Res Commun 2011;412:667–72.
Manoussakis MN, Talal N, Moutsopoulos HM. Sjögren's syndrome. In: En Rose NR, Nackay IR, editors. The autoimmune diseases. 3rd ed. San Diego, California: Academic Press; 1998. p. 381–404.
Manoussakis MN, Boiu S, Korkolopoulou P, et al. Rates of infiltration by macrophages and dendritic cells and expression of interleukin-18 and interleukin-12 in the chronic inflammatory lesions of Sjögren's syndrome: correlation with certain features of immune hyperactivity and factors associated with high risk of lymphoma development. Arthritis Rheum 2007;56(12):3977–88.
Martin S, Dawidowski L, Mandalunis P, Cereceda-Balic F, Tasat DR. Characterization and biological effect of Buenos Aires urban air particles on mice lungs. Environ Res 2007;105:340–9.
Martin S, Fernández-Alanis E, Delfosse V, Evelson P, Yakisich JS, Saldiva PH, et al. Low doses of urban air particles from Buenos Aires promote oxidative stress and apoptosis in mice lung. Inhal Toxicol 2010;22:1064–71.
McGrath-Morrow S, Laube B, Tzou SC, Cho C, Cleary J, Kimura H, et al. IL-12 overexpression in mice as a model for Sjögren lung disease. Am J Physiol Lung Cell Mol Physiol 2006;291:837–46.
Miyabara Y, Yanagisawa R, Shimojo N, Takano H, Lim HB, Ichinose T, et al. Murine strain differences in airway inflammation caused by diesel exhaust particles. Eur Respir J 1998;11:291–8.
Molinari BL, Tasat DR, Fernandez ML, Duran HA, Curiale J, Stoliar A, et al. Automated image analysis for monitoring oxidative burst in macrophages. Anal Quant Cytol Histol 2000;22:423–7.
Newball HH, Brahim SA. Chronic obstructive airway disease in patients with Sjögren's syndrome. Am Rev Respir Dis 1977;115:295–304.
Osornio-Vargas AR, Bonner JC, Alfaro-Moreno E, Martinez L, Garcia-Cuellar C, Ponce-de-Leon Rosales S, et al. Proinflammatory and cytotoxic effects of Mexico City air pollution particulate matter in vitro are dependent on particle size and composition. Environ Health Perspect 2003;111:1289–93.
Pope CA, Ezzati M, Dockery DW. Fine-particulate air pollution and life expectancy in the United States. N Engl J Med 2009;360:376–86.
Potena A, La Corte R. Increased bronchial responsiveness in primary and secondary Sjögren's syndrome. Eur Respir J 1990;3:548–53.
Roberts ES, Malstrom SE, Dreher KL. In situ pulmonary localization of air pollution particle-induced oxidative stress. J Toxicol Environ Health A 2007;70:1929–35.
Rondini EA, Walters DM, Bauer AK. Vanadium pentoxide induces pulmonary inflammation and tumor promotion in a strain-dependent manner. Part Fibre Toxicol 2010;12:7–9.
Ryo K, Yamada H, Nakagawa Y. Possible involvement of oxidative stress in salivary gland of patients with Sjögren's syndrome. Pathobiology 2006;73:252–60.
Saini Y, Greenwood KK, Merrill C, Kim KY, Patial S, Parameswaran N, et al. Acute cobalt-induced lung injury and the role of hypoxia-inducible factor 1α in modulating inflammation. Toxicol Sci 2010;116:673–81.
Saldiva PH, Lichtenfels AJ, Paiva PS, Barone IA, Martins MA, Massad E, et al. Association between air pollution and mortality due to respiratory diseases in children in São Paulo, Brazil: a preliminary report. Environ Res 1994;65:218–25.
Sánchez-Guerrero J, Pérez-Dosal MR, Cárdenas-Velázquez F. Prevalence of Sjögren's syndrome in ambulatory patients according to the American-European Consensus Group criteria. Rheumatology (Oxford) 2005;44(2):235–40.
Segal AW. Nitroblue-tetrazolium Tests, vol. 2; 1974. p. 1248–52.
Shi JH, Liu HR, Xu WB, Feng RE, Zhang ZH, Tian XL, et al. Pulmonary manifestations of Sjögren's syndrome. Respiration 2009;78:377–86.
Skopouli FN, Fox PC, Galanopoulou V, Atkinson JC, Jaffe ES, Moutsopoulos HM. T cell subpopulations in the labial minor salivary gland histopathologic lesion of Sjogren's syndrome. J Rheumatol 1991;18(2):210–4.

Southam DS, Dolovich M, O'Byrne PM, Inman MD. Distribution of intranasal instillations in mice: effects of volume, time, body position, an anesthesia. Am J Physiol Lung Cell Mol Physiol 2002;282:833–9.
Strimlan CV, Rosenow EC III, Divertie MB. Pulmonary manifestations of Sjögren's syndrome. Chest 1996;70:354–61.
Tasat DR, Rey B. Cytotoxic effect of uranium dioxide on rat alveolar macrophages. Environ Res 1987;44:71–81.
Vitali C, Bombardieri S, Jonsson R, Moutsopoulos HM, Alexander EL, Carsons SE, et al. Classification criteria for Sjögren's syndrome: a revised version of the European criteria proposed by the American-European Consensus Group. Ann Rheum Dis 2002;61:554–8.
Wanchu A, Khullar M, Sud A, Bambery P. Elevated nitric oxide production in patients with primary Sjögren's syndrome. Clin Rheumatol 2000;19:360–4.