

Refining the Indications for the Addition of Orbital Osteotomy during Anterior Cranial Base Approaches: Morphometric and Radiologic Study of the Anterior Cranial Base Osteology

Juan Carlos DeBattista¹ Norberto Andaluz¹ Mario Zuccarello¹ Robert G. Kerr¹ Jeffrey T. Keller¹

¹Department of Neurosurgery, University of Cincinnati (UC) College of Medicine; Comprehensive Stroke Center at the UC Neuroscience Institute, Mayfield Clinic, Cincinnati, Ohio, United States

Address for correspondence Norberto Andaluz, MD, Editorial Office, Department of Neurosurgery, University of Cincinnati College of Medicine, ML 0515, Cincinnati, OH 45267-0515, United States (e-mail: mary.kemper@uc.edu).

J Neurol Surg Rep 2014;75:e22–e26.

Abstract

Objectives In anatomic and radiologic morphometric studies, we examine a predictive method, based on preoperative imaging of the anterior cranial base, to define when addition of orbital osteotomy is warranted.

Design Anatomic and radiographic study.

Setting In 100 dry skulls, measurements in the anterior cranial fossa included three lines and two angles based on computerized tomography (CT) scans taken in situ and validated using frameless stereotactic navigation. The medial angle (coronal plane) was the intersection between the highest point of both orbits and the midpoint between the two frontoethmoidal sutures to each orbital roof high point. The oblique angle (sagittal plane) was the intersection at the midpoint of the limbus sphenoidale.

Results No identifiable morphometric patterns were found for our classification of anterior fossae; the two-tailed distribution pattern was similar for all skulls, disproving the hypothetical correlation between visual appearance and morphometry. Orbital heights (range: 6.6–18.7 mm) showed a linear relationship with medial and oblique angles, and they had a linear distribution relative to angular increments. Orbital heights > 11 mm were associated with angles ≥ 20 degrees and more likely to benefit from orbitotomy.

Conclusion Preoperative CT measurement of orbital height appears feasible for predicting when orbitotomy is needed, and it warrants further testing.

Keywords

- ▶ orbitotomy
- ▶ skull base
- ▶ frameless stereotaxy
- ▶ anterior cranial base

Introduction

The addition of an orbital osteotomy for surgical approaches to the anterior cranial base is a useful technical resource. Anatomical and clinical reports have documented the benefits of the complementary addition of an orbital osteotomy in terms of increased exposure and decreased incidence of iatrogenic brain injury because of the decreased need for brain retraction and the obviation of Sylvian fissure dissection.^{1–17} However, in our

critical retrospective review of approaches, which included orbital osteotomy, we observed that, on occasion, addition of an orbital osteotomy did not significantly increase exposure. We speculated that this observation relates to the high variability of the angular exposure afforded by an orbital osteotomy and relative to the anterior cranial base morphology rather than the approach itself. Furthermore, controversy exists not only about the value of adding an orbitotomy but also the criteria

received
December 13, 2012
accepted after revision
August 12, 2013
published online
March 12, 2014

DOI <http://dx.doi.org/10.1055/s-0033-1358794>.
ISSN 2193-6358.

© 2014 Georg Thieme Verlag KG
Stuttgart · New York

License terms



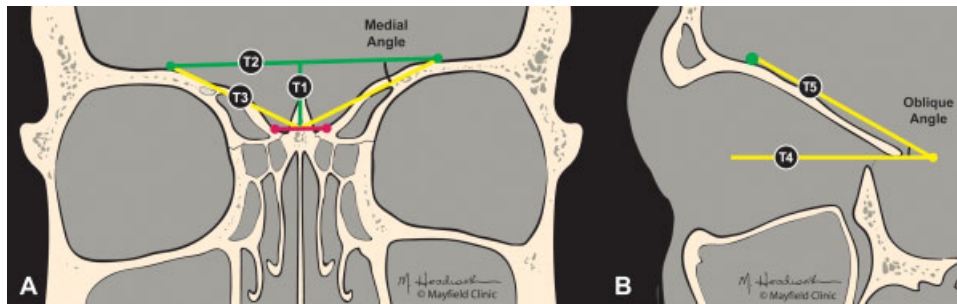


Fig. 1 Is there a correlation between morphometric and visual appearance (i.e., flat, short, or steep medial) of the anterior cranial fossa? Refer to ► **Table 1**. (A) Coronal plane view: A line represents the foramen cecum to limbus sphenoidale (FC–LS) distance (previously described). T1 extends from the midline in the frontoethmoidal suture to a line (T2) drawn from the highest point of each orbit. T3 describes the two lines, one on each side, that extend from the midpoint of each frontoethmoidal suture to each highest most orbital roof point. Medial angle is formed at the intersection of T2 and T3. (B) Sagittal plane view shows that T4 projects to the level of the planum sphenoidale and T5 projects from the highest point of the orbit. Oblique angle represents the intersection of these two lines at the midpoint of the limbus. This figure, with trajectories and colors, correlates with the case presentation in Fig. 4. (Illustration by Martha Headworth, ©2010 Mayfield Clinic, provided under CC BY-NC-ND 4.0)

used for its selection.^{3,18–25} To date, no morphometric criteria exist to aid the surgeon during the preoperative planning phase in the selection of additional orbitotomy.

In this anatomical and radiologic morphometric study, we attempted to define anatomical parameters of the cranio-orbital region that could be both reproducible and reliable as a predictive method based on preoperative imaging. With such parameters, the surgeon can then define the need for the additional orbital osteotomy in surgical approaches to pathologies of the anterior cranial base.

Material and Methods

In this anatomical and morphometric study, 100 dry skulls of unknown race, age, and sex underwent computerized tomography (CT) scans using a standardized stereotaxy protocol (3-mm slices, 0-degree angulation); data were loaded onto a computer workstation (Brainlab VectorVision Navigation System, Feldkirchen, Germany) for automated three-dimensional computerized reconstruction. Six anatomical landmarks in the endocranial anterior skull base were selected for the measurement of distances and angles on the reconstructed images and were those previously measured in situ, including the foramen

cecum (FC), limbus sphenoidale (LS) at the anatomical midline, right frontozygomatic suture, left frontozygomatic suture, uppermost point of the right orbital roof, and uppermost point of the left orbital roof. The measurements done on the computer workstation were also repeated in situ for validation.

Using these points, we constructed two projecting lines and two angles using the Vector Vision software. One projecting line represented the FC-LS measurement, and a second projecting line (trajectory 1) was constructed in the coronal plane, extending from the line that joined the highest points of the orbits to the midline of that joining the frontoethmoidal sutures (► **Fig. 1**). Two angles, the medial and oblique angles, were measured. The medial angle, measured in the coronal plane, was defined as that between two connecting lines: one extending between the highest point of both the orbits (trajectory 2) and another line extending from the midpoint between the two frontoethmoidal sutures to each higher most orbital roof point (trajectory 3). The oblique angle, measured in the sagittal plane, was the result of two projecting lines intersecting at the midpoint of the limbus, one projecting the level of the planum sphenoidale (trajectory 4) and another with an oblique trajectory projecting from the highest point of the orbit (trajectory 5). ► **Table 1** provides a

Table 1 Evaluated measurements of five trajectories (T1–T5) and two angles (medial and oblique) (©2010 Mayfield Clinic, provided under CC BY-NC-ND 4.0)

Trajectory	Measured/view	Description
1	Line/coronal	Midline in coronal plane. T1 line extends from the midpoint of T2 to the frontoethmoidal suture
2	Line/coronal	Line drawn, connecting the highest point of each orbit
3	Line/coronal	Midpoint line, from the highest point of the orbital roof to the midpoint between two frontoethmoidal sutures
4	Line/sagittal	Two projecting lines intersecting at the midpoint of the limbus, one projecting level the planum sphenoidale
5	Line/sagittal	Projecting from the highest point of the orbit
Angle	Measured	Description
Medial	Angle/coronal	Angle formed by intersection of lines T2 and T3
Oblique	Angle/sagittal	Angle formed by intersection of lines T4 and T5

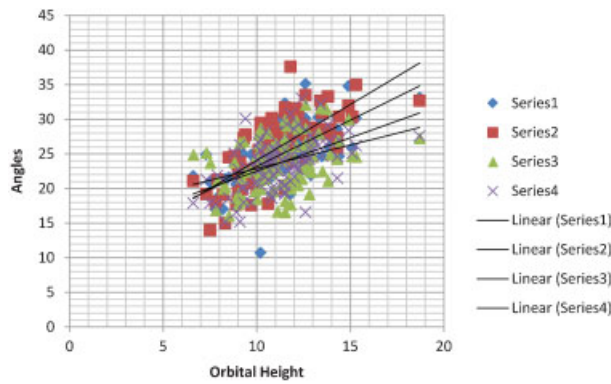


Fig. 2 XY distribution chart depicting the linear relationship between orbital heights and measurements of the oblique and medial angles. Notice the consistency of the relationship of the four lines at the level of 11 mm of orbital heights and angular measurements of 25 degrees.

detailed description. All measurements and calculations were loaded into an Excel table (Microsoft Corp., Redmond, CA) and analyzed.

Results

Measurements and ratios calculated for all the skulls followed a similar two-tailed distribution pattern, disproving the hypothesis of any correlation between visual appearance and morphometry. In situ measurements revealed a normal two-tailed distribution. Measurements on the Brainlab workstation were in agreement with those in situ, exhibiting a < 1.5-mm error in accuracy.

Orbital heights (trajectory 1) ranged from 6.6 to 18.7 mm (11.3 ± 1.48 mm), with 64% of the orbits measuring 10 to 12 mm (–Fig. 2 and –Table 2). Medial angles ranged from 10.7 to 37.6 degrees, with no significant differences between left and right sides, and a linear relationship with orbital heights. Oblique angles ranged from 15.2 to 33 degrees, again

Table 2 Distribution of orbital height measurements

Orbital height (mm)	No. of specimens
6	1
7	4
8	5
9	11
10	26
11	18
12	20
13	8
14	4
≥ 15	3
Total	100

Note: Bold values highlight that most measurements (64%) ranged from 10 to 12 mm.

showing a linear relationship with orbital heights. Orbital heights presented a linear distribution in relation to both medial and oblique angular increments. Orbital heights above 11 mm were associated consistently with angles ≥ 20 degrees, therefore predicting a more likely benefit from orbitotomy.

Discussion

In this anatomical morphometric study of the anterior fossa osteology, evaluation of our predictive model based on simple consistent radiologic measurements could be useful in determining the need of orbitotomy in the preoperative planning stages for pathologies that involve the anterior fossa midline, including the anterior communicating, sellar, and perisellar regions. Using the orbital height, we recognized a linear increase in the oblique angle with increasing orbital heights. When orbital heights exceeded 11 mm, oblique angles were consistently ≥ 20 degrees.

These findings, seemingly intuitive, can be significant in the preoperative planning stages. Previous studies have proven the benefits of an additional orbitotomy for the surgical treatment of pathology of the anterior fossa.^{3,8,21–23,26–29} However, these morphometric data revealed a large variability in the angulation encountered in the sagittal angle and the consequent increments of exposure afforded by orbitotomy.^{1,2,4,10,11,15,25,30} In the operative field, this translates into the impression that, at times, the addition of an orbitotomy and its added risks and surgical times may be unnecessary and on other occasions may be of significant value. Furthermore, because these measurements were taken on a bidimensional image, the measurements of the real angles, which are a product of oblique lines, were potentially affected. For that reason, our concept of the oblique angle describes the base of the anterior fossa as the line that originates from the orbital roof and carries an oblique trajectory, one similar to the vector of approach used during surgery. Oblique angle, working area, angle of attack, projection angle, field of view angle, cone of approach, and surgical vector are concepts that convene under the same philosophy of cranial base surgery, that is, minimal brain retraction, better exposure, illumination, and instrumentation maneuverability.¹⁶

Previous studies have suggested statistically significant benefits in surgical exposure from orbital osteotomy for patients with a sagittal angle (akin to our oblique angle) ≥ 20 degrees. For those patients, orbital osteotomy affords > 10 degrees of increased exposure, which translates in increments that range from 75 to 137% in the sagittal plane.^{1,2,4,10,11,15,25,30} According to our analysis, orbital heights of 11 mm are consistently associated with angles within the 20-degree range. Therefore, we concluded that patients with orbital heights of ≥ 11 mm are most likely to benefit from the addition of an orbital osteotomy when dealing with pathology of the midline anterior fossa. We recently tested this hypothesis with success in our patients with anterior fossa pathology (–Fig. 3). Finally, and most importantly for the clinical applicability of this strategy, the method for orbital height measurement can be calculated

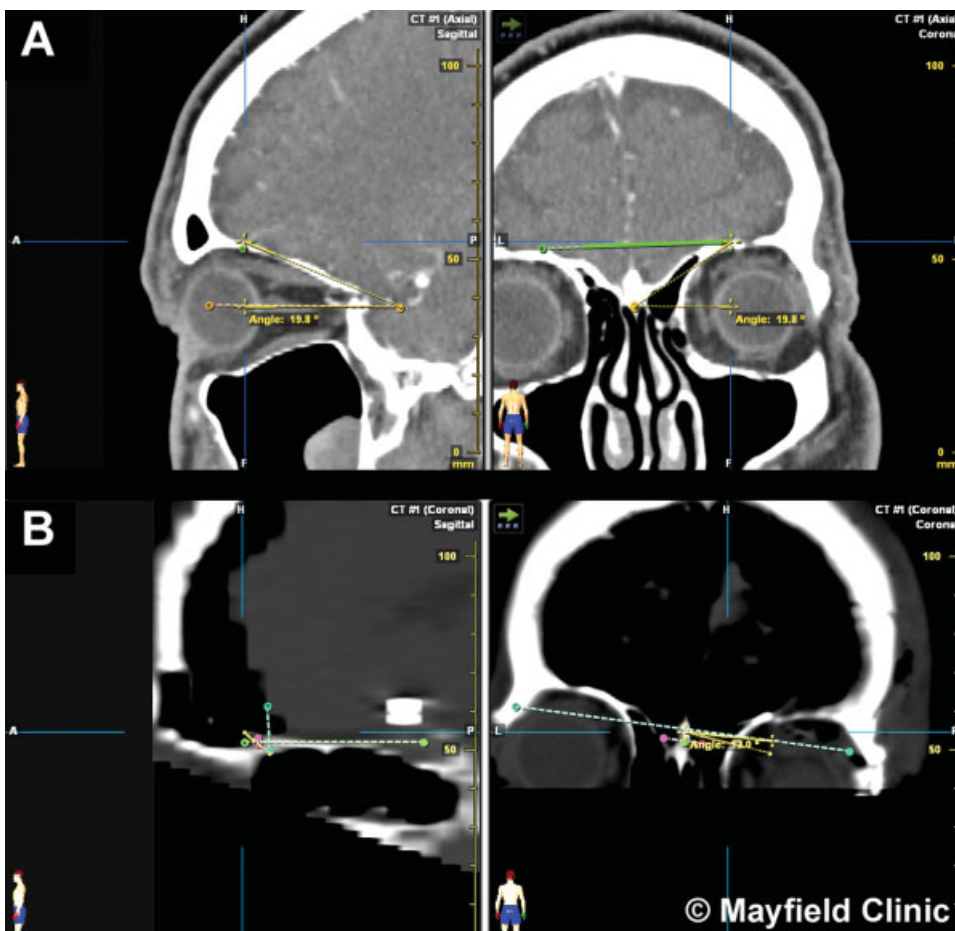


Fig. 3 Pre- and postoperative measurements in a 56-year-old man who underwent clipping of an unruptured anterior communicating artery aneurysm via an orbitopterional approach. (A) Preoperative measurements: orbital height, 12.7 mm; medial angle, 26.4 degrees on the right side (for approach); and oblique angle, 19.8 degrees. (B) Postoperative measurements: orbital height, 3.5 mm; medial angle, 13.7 degrees; and oblique angle, 4.4 degrees. (Illustration by Martha Headworth, ©2010 Mayfield Clinic, provided under CC BY-NC-ND 4.0)

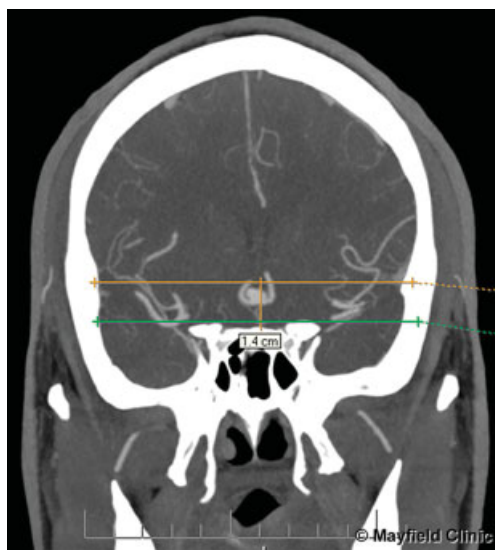


Fig. 4 Unruptured anterior communicating aneurysm in a 36-year-old patient. Preoperative measurement showing 14-mm orbital height predictive of the beneficial effect of adding an orbital osteotomy. Bottom projected line (green) adjoins the frontosphenoidal sutures. Top line (gold) adjoins the highest orbital points. (Illustration by Martha Headworth, ©2010 Mayfield Clinic, provided under CC BY-NC-ND 4.0)

without the aid of a frameless stereotactic workstation using any commercially available digital imaging suite building only three projected lines (→Fig. 4). Further testing in a larger series is required to further elucidate the role of these measurements in the preoperative planning phase.

Conclusion

Addition of an orbitotomy for the exposure of anterior fossa surgical pathology in patients with orbital heights > 11 mm may be beneficial. Preoperative measurement of the orbital height on CT scans appears feasible and promising as a predictive tool for the need for orbitotomy, but further testing in a larger series of patients is necessary.

References

- 1 Acharya R, Shaya M, Kumar R, Caldito GC, Nanda A. Quantification of the advantages of the extended frontal approach to skull base. *Skull Base* 2004;14(3):133–142; discussion 141–142
- 2 Alaywan M, Sindou M. Fronto-temporal approach with orbitozygomatic removal. *Surgical anatomy. Acta Neurochir (Wien)* 1990;104(3–4):79–83

- 3 Andaluz N, Romano A, Reddy LV, Zuccarello M. Eyelid approach to the anterior cranial base. *J Neurosurg* 2008;109(2):341–346
- 4 Andaluz N, Van Loveren HR, Keller JT, Zuccarello M. Anatomic and clinical study of the orbitopterional approach to anterior communicating artery aneurysms. *Neurosurgery* 2003;52(5):1140–1148; discussion 1148–1149
- 5 Aziz KM, Froelich SC, Cohen PL, Sanan A, Keller JT, van Loveren HR. The one-piece orbitozygomatic approach: the MacCarty burr hole and the inferior orbital fissure as keys to technique and application. *Acta Neurochir (Wien)* 2002;144(1):15–24
- 6 Chanda A, Nanda A. Anatomical study of the orbitozygomatic transsellar-transcavernous-transclinoidal approach to the basilar artery bifurcation. *J Neurosurg* 2002;97(1):151–160
- 7 D'Ambrosio AL, Mocco J, Hankinson TC, Bruce JN, van Loveren HR. Quantification of the frontotemporal orbitozygomatic approach using a three-dimensional visualization and modeling application. *Neurosurgery* 2008;62(3, Suppl 1):251–260; discussion 260–261
- 8 Dare AO, Landi MK, Lopes DK, Grand W. Eyebrow incision for combined orbital osteotomy and supraorbital minicraniotomy: application to aneurysms of the anterior circulation. Technical note. *J Neurosurg* 2001;95(4):714–718
- 9 Dzierzanowski J, Słoniewski P, Rut M. Morphometry of the pterional and pterional-orbitozygomatic approaches to the basilar artery bifurcation by the use of neuronavigation systems: a new technical concept. *Folia Morphol (Warsz)* 2008;67(4):267–272
- 10 Figueiredo EG, Deshmukh P, Zabramski JM, et al. Quantitative anatomic study of three surgical approaches to the anterior communicating artery complex. *Neurosurgery* 2005;56(2, Suppl):397–405; discussion 397–405
- 11 Gonzalez LF, Crawford NR, Horgan MA, Deshmukh P, Zabramski JM, Spetzler RF. Working area and angle of attack in three cranial base approaches: pterional, orbitozygomatic, and maxillary extension of the orbitozygomatic approach. *Neurosurgery* 2002;50(3):550–555; discussion 555–557
- 12 Jho HD. Orbital roof craniotomy via an eyebrow incision: a simplified anterior skull base approach. *Minim Invasive Neurosurg* 1997;40(3):91–97
- 13 Jian FZ, Santoro A, Innocenzi G, Wang XW, Liu SS, Cantore G. Frontotemporal orbitozygomatic craniotomy to exposure the cavernous sinus and its surrounding regions. *Microsurgical anatomy. J Neurosurg Sci* 2001;45(1):19–28
- 14 McArthur LL. An aseptic surgical access to the pituitary body and its neighborhood. *JAMA* 1912;58:2009–2011
- 15 Schwartz MS, Anderson GJ, Horgan MA, Kellogg JX, McMenomey SO, Delashaw JB Jr. Quantification of increased exposure resulting from orbital rim and orbitozygomatic osteotomy via the frontotemporal transsylvian approach. *J Neurosurg* 1999;91(6):1020–1026
- 16 Seçkin H, Avci E, Uluç K, Niemann D, Başkaya MK. The work horse of skull base surgery: orbitozygomatic approach. Technique, modifications, and applications. *Neurosurg Focus* 2008;25(6):E4
- 17 Yasargil MG, Fox JL, Ray MW. The operative approach to the aneurysms of the anterior communicating artery. In: Krayenbuhl H, ed. *Advances and Technical Standards in Neurosurgery*. Vol 2. New York, NY: Springer-Verlag; 1975:113–170
- 18 de Divitiis E, Esposito F, Cappabianca P, Cavallo LM, de Divitiis O. Tuberculum sellae meningiomas: high route or low route? A series of 51 consecutive cases. *Neurosurgery* 2008;62(3):556–563; discussion 556–563
- 19 Dehdashti AR, Ganna A, Witterick I, Gentili F. Expanded endoscopic endonasal approach for anterior cranial base and suprasellar lesions: indications and limitations. *Neurosurgery* 2009;64(4):677–687; discussion 687–689
- 20 Fatemi N, Dusick JR, de Paiva Neto MA, Malkasian D, Kelly DF. Endonasal versus supraorbital keyhole removal of craniopharyngiomas and tuberculum sellae meningiomas. *Neurosurgery* 2009;64(5, Suppl 2):269–284; discussion 284–286
- 21 Figueiredo EG, Deshmukh V, Nakaji P, et al. An anatomical evaluation of the mini-supraorbital approach and comparison with standard craniotomies. *Neurosurgery* 2006;59(4, Suppl 2):ONS212–ONS220; discussion ONS220
- 22 Gonzalez LF, Zabramski JM. Anatomic and clinical study of the orbitopterional approach to anterior communicating artery aneurysms. *Neurosurgery* 2004;54(4):1031–1032; author reply 1032
- 23 Grand W, Landi MK, Daré AO. Transorbital keyhole approach to anterior communicating artery aneurysms. *Neurosurgery* 2001;49(2):483–484
- 24 Reisch R, Perneczky A. Ten-year experience with the supraorbital subfrontal approach through an eyebrow skin incision. *Neurosurgery* 2005;57(4, Suppl):242–255; discussion 242–255
- 25 Sindou MP. Working area and angle of attack in three cranial base approaches: pterional, orbitozygomatic, and maxillary extension of the orbitozygomatic approach. *Neurosurgery* 2002;51(6):1526–1527; author reply 1527
- 26 Ramos-Zúñiga R, Velázquez H, Barajas MA, López R, Sánchez E, Trejo S. Trans-supraorbital approach to supratentorial aneurysms. *Neurosurgery* 2002;51(1):125–130; discussion 130–131
- 27 Shanno G, Maus M, Bilyk J, et al. Image-guided transorbital roof craniotomy via a suprabrow approach: a surgical series of 72 patients. *Neurosurgery* 2001;48(3):559–567; discussion 567–568
- 28 Steiger HJ, Schmid-Elsaesser R, Stummer W, Uhl E. Transorbital keyhole approach to anterior communicating artery aneurysms. *Neurosurgery* 2001;48(2):347–351; discussion 351–352
- 29 Warren WL, Grant GA. Transciliary orbitofrontozygomatic approach to lesions of the anterior cranial fossa. *Neurosurgery* 2009;64(5, Suppl 2):324–329; discussion 329–330
- 30 Tanriover N, Ulm AJ, Rhoton AL Jr, Kawashima M, Yoshioka N, Lewis SB. One-piece versus two-piece orbitozygomatic craniotomy: quantitative and qualitative considerations. *Neurosurgery* 2006;58(4, Suppl 2):ONS-229–ONS-237; discussion ONS-237