Journal of Medical Virology

Epstein–Barr Virus (EBV) Association and Latency Profile in Pediatric Burkitt's Lymphoma: Experience of a Single Institution in Argentina

Julia Lara,[1] Melina Cohen,[1] Elena De Matteo,[2] Luis Aversa,[3] Maria Victoria Preciado,[1] and Paola Chabay[1]*

[1]*Molecular Biology Laboratory, Pathology Division, Ricardo Gutiérrez Children's Hospital, Gallo 1330, Buenos Aires, Argentina*
[2]*Pathology Division, Ricardo Gutiérrez Children's Hospital, Gallo 1330, Buenos Aires, Argentina*
[3]*Hematology Division, Ricardo Gutiérrez Children's Hospital, Gallo 1330, Buenos Aires, Argentina*

The aim of this study is to characterize EBV expression and latency pattern in pediatric Burkitt's lymphoma in a single institution in Argentina. EBV-encoded RNA or protein was analyzed in 27 patients. EBERs was expressed in 37% of patients (29% of immunocompetent and 100% of immunosuppressed patients). EBV-positive cases were observed exclusively in patients younger than 5 years old. EBV association with immunocompetent patients exhibits the sporadic pattern in region under study, while its presence in patients infected with HIV was higher than described previously. EBV latency I profile was present in most of the patients, except for two immunosuppressed patients who displayed LMP1 expression. ***J. Med. Virol.***

KEY WORDS: EBV; lymphoma; childhood; latency; LMP1; BHRF1

INTRODUCTION

Burkitt lymphoma is a B-cell lymphoma with an extremely short doubling time which is often present at extranodal sites. Translocation involving MYC is highly characteristic but not specific [Swerdlow et al., 2008]. Three clinical variants of Burkitt lymphoma are recognized, each manifesting differences in clinical presentation, morphology and biology. The high-incidence "endemic" form typically occurs in children from areas of equatorial Africa and Papua New Guinea, where malaria is holoendemic, and is 100% EBV genome–positive. Elsewhere Burkitt lymphoma occurs in "sporadic" form, again mainly in children, at intermediate to low incidence and with different degrees of EBV association depending upon the area. Western countries show the lowest incidence rates and the weakest virus association, with only 15–20% tumors being infected with EBV. In contrast, Burkitt lymphoma appears to be more common in other locations: for example, equatorial areas of Brazil, where EBV-association rates are correspondingly higher. Remarkably, a third, adult form, AIDS-Burkitt's lymphoma, proved to be very common among individuals infected with HIV, often appearing as one of the first symptoms of AIDS; with 30–40% of these tumors carrying EBV [Kelly and Rickinson, 2007].

Epstein–Barr virus (EBV) is an oncogenic virus in the *Lymphocryptovirus* genus which is a member of the *Gammaherpesvirinae* subfamily within the large family *Herpesviridae*. Traditionally, three patterns of latent gene expression displayed by EBV have been described: latency I, II, and III. Latency III is characterized by the expression of all the latent genes (EBNAs driven by either of two upstream promoters, Cp or Wp, LMPs and EBERs), while in latency II only EBERs, EBNA1 driven by the Qp promoter (Qp-EBNA1), LMP1 and 2 are expressed; finally in latency I, which is typically found in Burkitt lymphoma, EBNA1, also driven by the Qp promoter, plus the EBERs are detected [Brady et al., 2007]. The roles that both EBNA1 and the EBERs play in the prevention of apoptosis and survival of Burkitt

Grant sponsor: National Agency for Science and Technology Promotion (PICT 2007 and 2011; partial support); Grant numbers: 1071 and 0478

The authors declare that they have no personal or financial conflict of interest.

*Correspondence to: Paola Chabay, Molecular Biology Laboratory, Pathology Division, Ricardo Gutierrez Children's Hospital, Gallo 1330, C1425EFD, Buenos Aires, Argentina.
E-mail: paola_chabay@yahoo.com.ar

Accepted 22 July 2013

DOI 10.1002/jmv.23737
Published online in Wiley Online Library (wileyonlinelibrary.com).

lymphoma neoplastic cells have been reported [Kennedy et al., 2003]. Interestingly, a study including endemic Burkitt lymphoma cases from Malawi was performed, in which EBNA1, LMP1, LMP2A, BZLF1, EBERs, and the BARTs were identified, suggesting that EBV gene expression may be broader than thought previously [Xue et al., 2002]. Furthermore, a fourth type of infection, driven by Wp promoter, was characterized by expression of EBNA1, EBNA3A, EBNA3B, EBNA3C, EBNA-LP, and BHRF1 in the absence of EBNA2 and the LMPs, and is seen in a subset of endemic Burkitt lymphoma tumors [Rowe et al., 2009].

Given the epidemiological characteristics of EBV infection in an underdeveloped country, the limited number of Burkitt lymphoma pediatric studies dealing with EBV infection in Argentina [Rao et al., 2000] and clinicopathologic features as well as the lack of reports describing EBV latency profile in pediatric Burkitt's lymphoma from an underdeveloped country, this study aimed at establishing EBV association and its latency pattern in pediatric Burkitt lymphoma in a single institution in Argentina.

MATERIALS AND METHODS

Patients and Tissue Preparation

Formalin-fixed paraffin-embedded (FFPE) Burkitt lymphoma lymph node biopsies from consecutive cases of 27 patients were collected retrospectively from 1990 to 2008, from the records filed at the Pathology Division, Ricardo Gutiérrez Children's Hospital in Buenos Aires, Argentina. Institutional guidelines regarding human experimentation were followed, and they were in accordance to the Helsinki Declaration of 1975.

Diagnosis was based on primary tumor biopsies. Histological classification was achieved according to the World Health Organization (WHO) scheme for Non-Hodgkin's lymphomas [Swerdlow et al., 2008].

EBERs In Situ Hybridization

EBERs in situ hybridization (ISH) was performed on FFPE tissue sections using fluorescein isothiocyanate (FITC)-conjugated EBERs oligonucleotides as probes (Dako, Carpinteria, CA). A monoclonal antibody anti-FITC labeled with alkaline phosphatase was used for the detection of hybridized sites (Dako). A well-known mixed cellularity Hodgkin's lymphoma with specific staining in Hodgkin Reed Sternberg cells was used as a positive control.

Immunohistochemistry

Immunohistochemical staining for Burkitt lymphoma diagnosis and EBV analysis was performed on FFPE tissue sections with a panel of antibodies: CD3 (Clone F7.2.38), CD10 (Clone 56C6), CD20 (Clone L26), CD30 (Clone Ber-H2), CD45 (Clone 2B11), Bcl6 (Clone PG-B6p), ALK (Clone ALK1), Ki67 (Clone MIB-1) (Dako) Bcl2 (Clone E17, 1:100, Biogenex, San Ramon, CA), c-Myc (9E10, Santa Cruz Biotechnology, Santa Cruz, CA), LMP1 (CS1-4, Leyca Microsystems, Wetzlar, Germany). Immunohistochemical detection of monoclonal and polyclonal antibodies was conducted using universal streptavidin-biotin complex-peroxidase detection system (Labeled Streptavidin Biotin, LSAB, Scytek, UT) according to the manufacturer's instructions. Diaminobenzidine (DAB) was used as chromogen. Appropriate positive controls were immunostained for each antibody.

RNA Extraction, Reverse Transcription, and PCR Amplification

RNA isolation was performed with QIAamp RNeasy Mini Kit, (Qiagen), according to manufacturer's instructions. Two micrograms of RNA were used for cDNA synthesis using Superscript II RT kit (Invitrogen, Carlsbad, CA) according to manufacturer's instructions. Good quality RNA was verified by phosphoglycerate kinase (PGK) gene amplification, that renders a 200 bp amplicon from RNA, and 600 bp from DNA, ruling out DNA contamination as described previously [Fritsch et al., 2003]. EBERs, EBNA1 promoter usage, LMP2A, BZLF1, and BHRF1 RNA expression was assessed using specific primers as described [Tao et al., 1998]. B95.8 cell line was used as positive control for latent gene expression, and B95.8 treated with TPA (12-O-tetradecanoylphorbol-13-acetate) was used for BZLF1 and BHRF1 expression. Ramos EBV negative cell line was used as negative control.

Statistical Analysis

Statistical analysis was performed using GraphPad Prism 4 software (GraphPad Software, Inc., San Diego, CA). Fisher's exact test or Chi square tests (χ^2) were used for statistical analysis when appropriate. Mann–Whitney test was used to assess the correlation between variables and EBV presence. All tests were two-tailed, and a P-value lower than 0.05 was considered statistically significant.

RESULTS

Patients' age range was between 1 and 16 years (median age 6 years), with a male/female ratio of 1.7:1. Three Burkitt lymphoma patients were infected with HIV. A primary extranodal site was confirmed in 20 cases (74%), whereas the remaining 7 cases (26%) were nodal. The majority of cases with extranodal involvement were abdominal (13 cases, 65%), and the rest occurred in the following sites: ovary, retroorbital sinus, pararectal, mediastinum, bone marrow, ileocecal valve and scalp. All but one nodal case (86%) were localized at the cervical lymph node. All cases expressed CD10, CD20, Ki67, and Bcl6 restricted to tumor cells, along with Bcl2 negative (78% of cases)

or weakly positive (22% of cases) expression. C-Myc immunostaining was performed only in 17 cases, and Myc protein proved to be overexpressed in 16/17 cases.

EBERs expression related to patients' characteristics is listed in Table I. EBV association established by means of EBERs nuclear staining restricted to tumor cells was observed in 10 out of 27 cases (37%; Fig. 1A, B and C). All three patients infected with HIV were EBERs positive by ISH, and EBV association with HIV positive status was statistically significant ($P = 0.0410$, Fisher's exact test). Seven out of 24 immunocompetent patients (29%) were EBERs positive. Since primary EBV infection occurs mainly in early childhood in Argentina, EBV presence in Burkitt lymphoma biopsies was analyzed in two pediatric age groups in those patients with age data: younger than 5 years old ($\leq$5 years), and 11–16 years old (>5 years). The number of EBV positive cases was significantly higher among patients $\leq$5 years old than among patients >5 years old ($P < 0.0001$, Fisher's exact test). The median age of EBV-positive patients was 3 years old versus 8 years old for EBV-negative ones ($P = 0.0027$, Mann–Whitney test) (Fig. 2B). In patients $\leq$ 5 years old, EBV association was 100% in immunocompromised patients (3/3), versus 71% in immunocompetent ones (5/7). On the other hand, EBV expression was distributed homogeneously in male and female patients ($P = 0.4153$, Fisher's exact test).

Concerning EBV antigen profile, LMP1 antigen expression was analyzed by immunohistochemistry, while the remaining antigens were studied by RT-PCR, given the unavailability of commercial EBNA2 and EBNA3s antibodies for FFPE tissues. LMP1 expression localized at cytoplasmic membrane was observed in 2/10 (20%) EBV-positive cases, which in turn were patients infected with HIV (Fig. 1D). Good quality RNA confirmed by PGK expression was obtained in 9/10 EBV-positive cases. All nine cases showed EBERs transcripts positive expression, whereas LMP2A latent gene as well as BZLF1 and BHRF1 lytic genes were not expressed. EBNA1 transcripts driven from Wp/Cp promoters (Wp/Cp-EBNA1) were also absent, while the 6/9 samples tested for EBNA1 Qp promoter usage were positive (Table II; Fig. 2A).

DISCUSSION

EBV is known to be associated with Burkitt lymphoma in different proportions, but the exact role that it plays in the development of Burkitt's lymphoma has remained elusive. It is known that EBV is capable of transforming B cells and this may play a role in the pathogenesis of Burkitt's lymphoma [God and Haque, 2010]. In these series, 27 consecutive Burkitt's lymphoma pediatric patients from a single institution during an 18-year period were analyzed. Remarkably, a sporadic EBV association with Burkitt lymphoma (29%) in immunocompetent patients was observed, much lower than the one observed previously in Argentina [47%; Gutiérrez et al., 1992; Rao et al., 2000]. This difference could be explain by the fact that those studies analyzed both adults and pediatric patients together, and that they dot not discriminate between immunocompetent and immunosuppressed individuals. In contrast, variable regionally EBV association with Burkitt's lymphoma was described, varying from 29% in the South to 76% in the North, but higher in pediatric groups from all regions [Queiroga et al., 2008].

The scenario for Burkitt lymphoma in HIV infected patients was quite different from that described previously by others, since these series showed an interesting 100% EBV association with pediatric Burkitt lymphoma patients infected with HIV, higher than the typical 30–40% reported for this entity [Kelly and Rickinson, 2007]. In the cohort studied, EBV infection was associated statistically with the younger patient group, since all EBV-associated Burkitt lymphoma patients with age data were younger than 5 years old. Given that in Argentina

TABLE I. Demographic and Histological Characteristics of Pediatric Burkitt Lymphoma. Correlation With EBERs Expression

		EBERs			
Patients' characteristics	N	Pos.	Neg.	% pos.	*P*
Age (years)					
$\leq$5 years	10	8	2	80	<0.0001*
>5 years	13	0	13	0	
ND	4	2	2		
Sex					
Male	17	5	12	29	0.4153
Female	10	5	5	50	
Immunological status					
Immunosuppressed	3	3	0	100	0.0410*
Immunocompetent	24	7	17	29	
EBV association	27	10	17	37	

ND, not determined due to lost of follow up.
*Indicates statistical significance by Fisher's exact test.

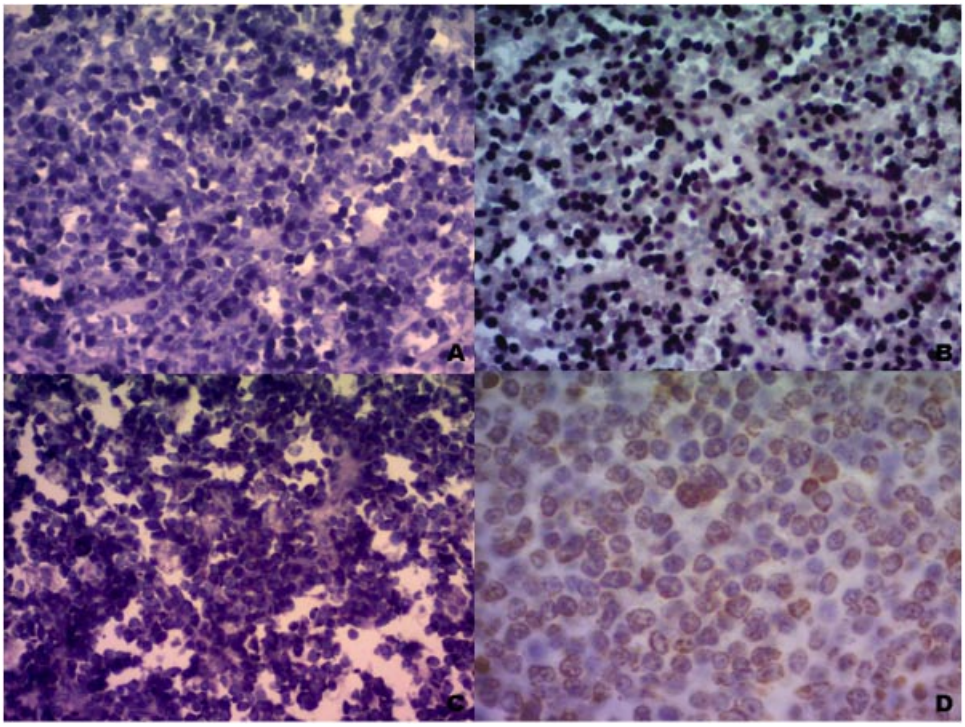

Fig. 1. **A**,**B**: EBERs in situ hybridization for EBV shows positive staining in the nucleus of neoplastic cells in lymph node biopsies from two Burkitt lymphoma patients, original magnification 40×. **C**: GAPDH mRNA positive control in a Burkitt lymphoma biopsy, original magnification 40×. **D**: LMP1 immunohistochemistry shows cytoplasmic membrane staining in a Burkitt lymphoma biopsy, original magnification 40×.

primary EBV infection occurs before the first decade of life [Chabay et al., 1999], and also a higher prevalence of EBV in lymphomas diagnosed in children younger than 10 years old has been described previously in Argentina in pediatric Hodgkin's lymphoma [Chabay et al., 2008], Burkitt lymphoma development could take place as a complication of early primary EBV infection, as suggested previously in Brazil [Hassan et al., 2008]. Furthermore, in Argentina 241 Burkitt's lymphoma cases were reported during the period 2000–2008. Of these, 82 patients (34%) were 1–4 years old, 96 patients (40%) were 5–9 years old, and 63 patients (26%) were 10–14 years old (Registro Oncopediátrico Argentino. Resultados 2000–2008). Clearly, Burkitt lymphoma is distributed homogeneously in all age ranges, so EBV association shown by Burkitt lymphoma within the 1–5 years age range is remarkable.

In order to evaluate both latent and lytic antigen expression patterns, latency I was characterized by Qp-EBNA1 and EBERs expression; latency II by EBERs, Qp-EBNA1 together with LMP1 and 2A expression; latency III by EBERs, Cp/Wp-EBNA1, LMPs and BHRF1 expression; and Wp-restricted latency by EBERs, Cp/Wp-EBNA1, and BHRF1 in the absence of LMPs expression. LMP1 expression was assessed by IHC, whereas EBERs, EBNA1, LMP2A, BHRF1, and BZLF1 gene expression were studied by RT-PCR. A typical latency I infection pattern was described in all the immunocompetent cases and one Burkitt lymphoma patient infected with HIV. Remarkably, the remaining two Burkitt lymphoma cases, both in patients infected with HIV, displayed LMP1 positivity by IHC, and gene expression could only be evaluated in one case with good quality RNA, which did not reveal LMP2A, BHRF1, and BZLF1 gene expression. This pattern did not match either with latency I or Wp-restricted pattern described for Burkitt lymphoma, nor with latency III pattern, associated with EBV-positive lymphomas in immunosuppressed patients. Furthermore, it did not fit with the particular pattern described either, with LMP1 negative expression along with a consistent, weak signal for LMP2A in Burkitt's lymphoma biopsies, described first in 1998 and confirmed latter [Tao et al., 1998; Bell et al., 2006]. Only one group of researchers reported LMP1 expression without LMP2A by RT-PCR in 2/12 patients, restricted to African endemic Burkitt lymphoma patients [Xue et al., 2002].

Early work on HIV-associated lymphadopathy lesions showed clearly expanded germinal center activity [Kelly and Rickinson, 2007]. EBV infected B cells are thought to enter a follicle and undergo the germinal center differentiation process, where some of the EBV latent antigens are expressed in order to guarantee the survival of the latently infected cell in the competitive environment of the germinal center

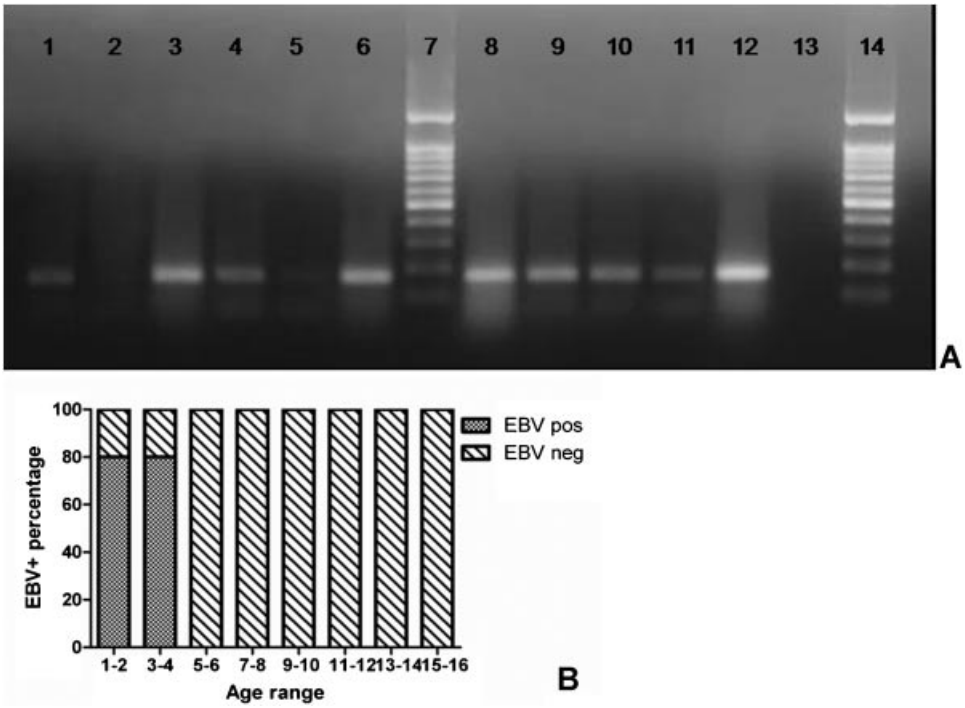

Fig. 2. **A**: EBERs expression by RT-PCR in four Burkitt lymphoma patients from Table II (lines 1–5, patients 1, 3–6 consecutively; lines 8–11, patients 7–10 consecutively), P3HR1 positive control (line 6), B95.8 positive control (line 12) and Ramos negative control (line 13); 100 bp marker (lines 7 and 14). **B**: EBV distribution according to age ranges in Burkitt lymphoma patients.

[Thorley-Lawson and Allday, 2008]. Burkitt lymphoma cells are derived from the germinal center [Seifert et al., 2013]. Hence, LMP1 expression in both Burkitt lymphoma patients infected with HIV could arise from a germinal center cell that failed to turn-off selectively protein expression to achieve the full Burkitt's lymphoma latency I phenotype, promoted by HIV presence. In addition, the presence of HIV-associated immunosuppression, allows the unchecked proliferation of EBV-infected lymphocytes expressing latent antigens different from typical latency I. Hierarchies of immunodominance for CD4+ and CD8+ T cell responses among the latent cycle EBV proteins has been demonstrated. Subdominant responses often map to epitopes either from EBNA3 family, much less often from LMPs, and apparently never from EBNA1 [Hislop et al., 2007]. The most common gene-expression pattern under immunosuppressive status, particularly following transplantation, is latency III [Carbone et al., 2008], caused by total impairment of immune cell responses. Alternatively, HIV associated Burkitt lymphoma tend to arise early following HIV infection, often when EBV-specific immune responses are still probably intact [Hislop et al., 2007]. In the LMP1 positive cases infected with HIV, partial impairment of CD8+ and/or CD4+ T cell response in patients with Burkitt lymphoma could allow selectively LMP1 expression. Further investigation will be crucial to confirm and characterize in depth these findings.

TABLE II. EBV Gene Expression Pattern by RT-PCR

Patient no.	PGK	EBERs 1	EBNA1 Qp	EBNA1 Cp/Wp	LMP2A	BZLF1	BHRF1
1	Pos.	Pos.	Pos.	Neg.	Neg.	Neg.	Neg.
2	Neg.	Neg.	ND	ND	ND	ND	ND
3	Pos.	Pos.	Pos.	Neg.	Neg.	Neg.	Neg.
4	Pos.	Pos.	Pos.	Neg.	Neg.	Neg.	Neg.
5	Pos.	Pos.	ND	Neg.	Neg.	Neg.	Neg.
6	Pos.	Pos.	Pos.	Neg.	Neg.	Neg.	Neg.
7	Pos.	Pos.	Pos.	Neg.	Neg.	Neg.	Neg.
8	Pos.	Pos.	Pos.	Neg.	Neg.	Neg.	Neg.
9	Pos.	Pos.	ND	Neg.	Neg.	Neg.	Neg.
10	Pos.	Pos.	ND	Neg.	Neg.	Neg.	Neg.

ND, not determined. PGK pos, 200 bp amplicon without contaminating DNA (600 bp).

ACKNOWLEDGMENTS

P.C. and M.V.P. are members of the National Research Council (CONICET), Research Career Programme and M.C. is a National Agency for Science and Technology Promotion doctoral fellow.

REFERENCES

Bell AI, Groves K, Kelly GL, Croom-Carter D, Hui E, Chan AT, Rickinson AB. 2006. Analysis of Epstein–Barr virus latent gene expression in endemic Burkitt's lymphoma and nasopharyngeal carcinoma tumour cells by using quantitative real-time PCR assays. J Gen Virol 87:2885–2890.

Brady G, MacArthur GJ, Farrell PJ. 2007. Epstein–Barr virus and Burkitt lymphoma. J Clin Pathol 60:1397–1402.

Carbone A, Gloghini A, Dotti G. 2008. EBV-associated lymphoproliferative disorders: Classification and treatment. Oncologist 13:577–585.

Chabay P, Burna V, Moar A, Grinstein S, Preciado MV. 1999. Prevalencia de la infección por el virus de Epstein–Barr en pacientes pediátricos. Rev Hosp De Niños B Aires 41:88–91.

Chabay PA, Barros MH, Hassan R, De Matteo E, Rey G, Carrico MK, Renault IZ, Preciado MV. 2008. Pediatric Hodgkin lymphoma in 2 South American series: A distinctive epidemiologic pattern and lack of association of Epstein–Barr virus with clinical outcome. J Pediatr Hematol Oncol 30:285–291.

Fritsch MK, Bridge JA, Schuster AE, Perlman EJ, Argani P. 2003. Performance characteristics of a reverse transcriptase-polymerase chain reaction assay for the detection of tumor-specific fusion transcripts from archival tissue. Pediatr Dev Pathol 6:43–53.

God JM, Haque A. 2010. Burkitt lymphoma: Pathogenesis and immune evasion. J Oncol 2010:1–14.

Gutiérrez MI, Bhatia K, Barriga F, Diez B, Muriel FS, de Andreas ML, Epelman S, Risueño C, Magrath IT. 1992. Molecular epidemiology of Burkitt's lymphoma from South America: Differences in breakpoint location and Epstein–Barr virus association from tumors in other world regions. Blood 79:3261–3266.

Hassan R, Klumb CE, Felisbino FE, Guiretti DM, White LR, Stefanoff CG, Barros MH, Seuánez HN, Zalcberg IR. 2008. Clinical and demographic characteristics of Epstein–Barr virus-associated childhood Burkitt's lymphoma in Southeastern Brazil: Epidemiological insights from an intermediate risk region. Haematologica 93:780–783.

Hislop AD, Taylor GS, Sauce D, Rickinson AB. 2007. Cellular responses to viral infection in humans: Lessons from Epstein–Barr virus. Annu Rev Immunol 25:587–617.

Kelly G, Rickinson A. 2007. Burkitt lymphoma: Revisiting the pathogenesis of a virus-associated malignancy. Hematology Am Soc Hematol Educ Program 2007:277–284.

Kennedy G, Komano J, Sugden B. 2003. Epstein–Barr virus provides a survival factor to Burkitt's lymphomas. Proc Natl Acad Sci USA 100:14269–14274.

Queiroga EM, Gualco G, Weiss LM, Dittmer DP, Araujo I, Klumb CE, Harrington WJ, Jr., Bacchi CE. 2008. Burkitt lymphoma in Brazil is characterized by geographically distinct clinicopathologic features. Am J Clin Pathol 130:946–956.

Rao CR, Gutierrez MI, Bhatia K, Fend F, Franklin J, Appaji L, Gallo G, O'Conor G, Lalitha N, Magrath I. 2000. Association of Burkitt's lymphoma with the Epstein–Barr virus in two developing countries. Leuk Lymphoma 39:329–337.

Registro Oncopediátrico Argentino. Resultados 2000–2008. Available at: http://www.roha.org.ar. Accessed May 10, 2012.

Rowe M, Kelly GL, Bell AI, Rickinson AB. 2009. Burkitt's lymphoma: The Rosetta Stone deciphering Epstein–Barr virus biology. Semin Cancer Biol 19:377–388.

Seifert M, Scholtysik R, Küppers R. 2013. Origin and pathogenesis of B cell lymphomas. Methods Mol Biol 971:1–25.

Swerdlow SH, Campo E, Harris NL, Jaffe ES, Pileri SA, Stein H, Thiele J, Vardiman JW. 2008. WHO classification of tumours of haematopoietic and lymphoid tissues. 4th edition. Lyon, France: IARC Press.

Tao Q, Robertson KD, Manns A, Hildesheim A, Ambinder RF. 1998. Epstein–Barr virus (EBV) in endemic Burkitt's lymphoma: Molecular analysis of primary tumor tissue. Blood 91:1373–1381.

Thorley-Lawson DA, Allday MJ. 2008. The curious case of the tumour virus: 50 years of Burkitt's lymphoma. Nat Rev Microbiol 6:913–924.

Xue SA, Labrecque LG, Lu QL, Ong SK, Lampert IA, Kazembe P, Molyneux E, Broadhead RL, Borgstein E, Griffin BE. 2002. Promiscuous expression of Epstein–Barr virus genes in Burkitt's lymphoma from the central African country Malawi. Int J Cancer 99:635–643.