CLINICAL GENETICS An International Journal of Genetics, Molecular and Personalized Medicine

Clin Genet 2014
Printed in Singapore. All rights reserved



CLINICAL GENETICS
doi: 10.1111/cge.12329

## Short Report

# Ocular and craniofacial phenotypes in a large Brazilian family with congenital aniridia

Fernandes-Lima Z.S., Paixão-Côrtes V.R., de Andrade A.K.M., Fernandes A.S., Coronado B.N.L., Monte Filho H.P., Santos M.J., de Omena Filho R.L., Biondi F.C., Ruiz-Linares A., Ramallo V., Hünemeier T., Schuler-Faccini L., Monlleó I.L. Ocular and craniofacial phenotypes in a large Brazilian family with congenital aniridia.
Clin Genet 2014. © John Wiley & Sons A/S. Published by John Wiley & Sons Ltd, 2013

Congenital aniridia is a rare genetic disorder characterized by varying degrees of iris hypoplasia that are associated with additional ocular abnormalities. More than 90% of the causal mutations identified are found in the *PAX6* gene, a transcription factor of critical importance in the process of neurogenesis and ocular development. Here, we investigate clinical, molecular, and craniofacial features of a large Brazilian family with congenital aniridia. Among the 56 eyes evaluated, phenotype variation encompassed bilateral total aniridia to mild iris defects with extensive variation between eyes of the same individual. *PAX6* molecular screening indicated a heterozygous splice mutation (c.141 + 1G>A). Thus, we hypothesize that this splicing event may cause variation in the expression of the wild-type transcript, which may lead to the observed variation in phenotype. Affected individuals were more brachycephalic, even though their face height and cephalic circumference were not significantly different when compared to those of non-affected relatives. From this, we infer that the head shape of affected subjects may also be a result of the *PAX6* splice-site mutation. Our data summarize the clinical variability associated with the ocular phenotype in a large family with aniridia, and help shed light on the role of *PAX6* in neurocranial development.

### Conflict of interest

The authors declare that there are no conflicts of interest.

**Z.S. Fernandes-Lima [a,b,†], V.R. Paixão-Côrtes[a,†], A.K.M. de Andrade[c], A.S. Fernandes[d], B.N.L. Coronado[d], H.P. Monte Filho[d], M.J. Santos[d], R.L. de Omena Filho[e], F.C. Biondi[a], A. Ruiz-Linares[f], V. Ramallo[a], T. Hünemeier[a], L. Schuler-Faccini[a,b] and I.L. Monlleó[c,g]**

[a]Programa de Pós-Graduação em Genética e Biologia Molecular, Departamento de Genética, Universidade Federal do Rio Grande do Sul (UFRGS), Porto Alegre, Brazil, [b]gINAGEMP – Instituto Nacional de Genética Médica Populacional, Universidade Federal do Rio Grande do Sul, Porto Alegre, Brazil, [c]Setor de Genética Médica, Faculdade de Medicina, [d]Serviço de Oftalmologia, Hospital Universitário Professor Alberto Antunes, Universidade Federal de Alagoas (UFAL), Maceió, Brazil, [e]Setor de Genética Médica, Centro de Ciências da Saúde, Universidade Estadual de Ciências da Saúde de Alagoas (UNCISAL), Maceió, Brazil, [f]Department of Genetics, Evolution and Environment, University College London, London, UK, and [g]Serviço de Genética Clínica Hospital, Hospital Universitário Professor Alberto Antunes, Universidade Federal de Alagoas (UFAL), Maceió, Brazil

[†]These authors contributed equally to this work.

Key words: aniridia – autosomal dominant – neurocranium – *PAX6*

Corresponding author: Lavínia Schuler-Faccini, Programa de Pós-Graduação em Genética e Biologia Molecular, Departamento de Genética, Instituto de Biociências, Universidade

Federal do Rio Grande do Sul, Caixa Postal 15053, 91501–970 Porto Alegre, RS, Brazil.
Tel.: +55 51 33089826;
fax: +55 51 33598010;
e-mail: lavinia.faccini@ufrgs.br

Received 6 September 2013, revised and accepted for publication 22 November 2013

Congenital aniridia (OMIM #106210) is a rare condition associated with a wide range of clinical manifestations. Although it is usually diagnosed in early infancy, the disease ultimately leads to vision loss during adulthood. While the name 'aniridia' indicates defects in the iris, ocular abnormalities associated with this disease encompass multiple ocular structures and tissues, with complete or partial hypoplasia of the iris, corneal opacification, cataract, lens ectopia, glaucoma, and macular and optic nerve hypoplasia characterizing the disease. Refractive errors, strabismus, and ptosis may also be present in the affected eye. Clinical expression is highly variable within and between families, but there appears to be little difference between the eyes of a single patient (1–4).

Approximately two thirds of all congenital aniridia cases have been linked to an inherited autosomal dominant trait that demonstrates near complete penetrance and lacks any known ethnic, geographic, or gender bias. In the remaining one third of cases, the disease occurs as a sporadic disorder, and is frequently associated with Wilms tumor as part of the Wilms tumor–Aniridia–Genital anomalies–Retardation (WAGR) 11p microdeletion syndrome (1–4).

Despite the wide phenotype variability, more than 90% of the mutations leading to congenital aniridia are found in the paired box gene 6 (*PAX6*) locus, located on chromosome 11p13 (chr11:31806340–31839509; GRCh37/hg19). *PAX6*, like all PAX family members, is a transcription factor known to play key roles in many aspects of embryonic development and organogenesis, including neurogenesis and ocular development (3, 5). The OMIM catalog use as examples 26 alleles for the *PAX6* gene (OMIM *607108; accessed on October 17, 2013): 13 are solely associated with aniridia, whereas the remaining 13 are also linked to other malformations that occur with or without aniridia. The interactive database Lovd-PAX6 presents 592 documented variations of the human *PAX6* gene. Notably, 56 of the *PAX6* variants have unknown molecular mechanisms (http://www.lovd.nl/3.0/home, accessed on October 17, 2013). Most of causal mutations create codon shift that yields a premature stop codon, leading to truncated, non-functional PAX6 protein. Loss of PAX6 function results in altered downstream gene regulation and subsequent changes in cell signaling, which, in most cases, leads to morphological abnormalities.

The aim of this study was to investigate the clinical features in a large Brazilian family with congenital aniridia and to identify the genetic factors associated with the disease phenotype.

## Materials and methods

### Subject recruitment and clinical examination

We investigated a family of 163 individuals across a five-generation pedigree, residing in a rural area Northeast of Brazil (Água Branca, Alagoas – 09°15′39″S; 37°56′10″W), including 53 subjects presenting phenotypes similar to that of congenital aniridia. Clinical data and biological samples were obtained for 60 family members (31 affected and 29 non-affected). Clinical diagnosis of aniridia was made after a complete ophthalmological examination was performed by four ophthalmologists. Examinations included corneal inspection, measurement of visual acuity, intraocular pressure with applanation tonometry (mmHg), refraction, slit-lamp examination, and dilated fundoscopy. Careful physical examination was also performed by two dysmorphologists. The use of human subjects in this study was approved by the Federal University of Rio Grande do Sul Ethics Committee (Protocol # 195.023). Informed consent was obtained from all participants or their guardians.

### Craniofacial measurement

Four craniofacial absolute/linear measures – head length (g-op), head breadth (eu-eu), facial length (n-gn) and head circumference – were obtained using sliding and spreading calipers. In order to minimize error, the anthropometric measurements were obtained according to international standards and by the same researcher. The cephalic index (CI = eu-eu × 100/g-op) was calculated based on these absolute measurements. Individuals under 12 years of age were excluded from this analysis.

### Molecular tests

DNA was extracted using a standard volume of 2.0 ml Oragene DNA/saliva mixed samples. DNA from seven individuals (5 affected and 2 unaffected) was amplified by polymerase chain reaction (PCR) using primers specific for 18 regions (6, 7), which covered the entire coding and adjacent *PAX6* gene regions (7527 bp). The amplified products were purified following the Exonuclease I and Alkaline Phosphatase

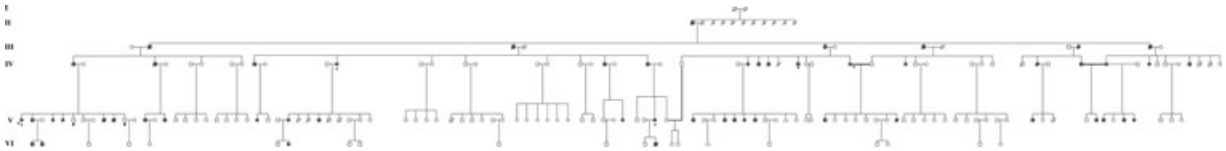

*Fig. 1.* Family pedigree with 53 identified members diagnosed with aniridia in five generations of the family. Five affected individuals with molecular screening and two unaffected individuals with molecular screening.

(Amersham Bisciences – GE Healthcare, Piscataway, NJ) protocols. Both DNA strands were sequenced using an ABI 3730/3730x Sequence Analyzer (Life Technologies, Carlsbad, CA). Any putative mutations identified were re-amplified and re-sequenced for confirmation.

### Sequence data analysis

DNA sequences and chromatograms were aligned and their quality and accuracy were checked using the CodonCode Aligner software (http://www.codoncode.com/). All statistical analysis (ANOVA test, bar and regression graphics representing mean indices values) was carried out using XLSTAT software.

## Results

### Pedigree analysis

The pedigree analysis is concordant with dominant inheritance having complete penetrance (Fig. 1). The ratio of affected to normal subjects in segregating sibships was 0.52/0.48, similar to the expected segregation ratio of 0.5/0.5.

### Clinical characteristics

Of the living family members affected with congenital aniridia, we were able to perform clinical examination of 31, ranging from 2 to 72 years of age, 58% of whom were male. Among the 56 eyes (26 right eyes and 30 left eyes) evaluated, the following phenotypes were observed: bilateral total aniridia (38 subjects), unilateral total aniridia (4 subjects), bilateral partial aniridia (4 subjects), unilateral partial aniridia (4 subjects), bilateral misshapen pupils (4 subjects), and unilateral misshapen pupils (2 subjects) (Table 1). Further, nystagmus, cataract, photophobia, strabismus, and corneal changes (opacity, neovascularization, and microcornea) were the most prevalent associated problems (Fig. 2). Intraocular pressure in the aniridia-affected eyes ranged from 7 to 32 mmHg. Other minor facial defects, including synophrys, low set ears, epicanthus, and clinodactyly, were observed in 21 subjects (70%). Two subjects presented motor delay and learning disabilities.

### Craniofacial analysis

Affected individuals have significantly higher CI (85.93, SD $\pm$4.8) compared to their normal relatives (82.46, SD $\pm$5.12) ($p = 0.014$), often presenting a more brachycephalic head shape. In contrast, there was no significant difference in face height or cephalic circumference between affected and non-affected relatives.

### *PAX6* molecular screening

All five of the affected individuals sequenced for *PAX6* (IV-12, IV-31, IV-34, V-1, and V-58) presented a heterozygous G>A change in the first nucleotide following exon position 141 (c.141 + 1G>A). The two normal individuals tested from this family did not show the mutation (V-6 and V-11).

## Discussion

The clinical findings presented here corroborate what has been presented in literature regarding the broad spectrum of the ocular phenotype and the extent of intrafamilial and individual variability (1, 2, 4, 8). In the family studied for this investigation, different degrees of iris hypoplasia (from total aniridia to misshapen pupil) were observed within family members and between the eyes of an affected individual, with the analyzed affected individuals presenting severe, progressive loss of vision. Additionally, motor delay and learning disability were verified in two subjects, both of whom suffered from perinatal and postnatal injury, according to their clinical history. Other anatomic sites did not show significant malformation, and the minor defects identified did not follow a consistent pattern. Therefore, we postulate that these insignificant abnormalities are not part of the spectrum of aniridia in this family, and will not be discussed further in this study.

Many *PAX6* mutations have been linked to aniridia pathogenesis. In the Brazilian family studied, we found that all five of the affected patients analyzed carried a G>A mutation in the first nucleotide of intron 5 (nucleotide 141 + 1) that was not present in the healthy control samples. This particular mutation (c.141 + 1G>A) was first described by Wang et al. (9) in two related Chinese individuals. They indicate that this mutation likely leads to disruption of one of the splice sites present in exon 5, which contains part of the paired domain, altering the strength of the donor splice site. *PAX6* mutations in splice sites, caused by a point mutation, were present in 9% of the records in the PAX6 Allelic Variant Database (http://lsdb.hgu.mrc.ac.uk/home.php?select db = PAX6, accessed on October 17, 2013), and the phenotype related to these mutations varied from complete absence

Table 1. Clinical characteristics of all affected subjects examined

| Case (age in years) | Gender | Iris (RE/LE) | Cornea changes: Microcornea (RE/LE) | Cornea changes: Opacity (RE/LE) | Cornea changes: Neovascularization (RE/LE) | Lenses: Cataract (RE/LE) | Lenses: Ectopia | Nystagmus | Photophobia | Strabismus | Glaucoma (RE/LE) | Visual acuity (RE/LE) | Other features |
|---|---|---|---|---|---|---|---|---|---|---|---|---|---|
| III-5 (72) | M | IMP/TAN | IMP/No | IMP/Yes | IMP/Yes | IMP/Yes | IMP/Yes | Yes | Yes | IMP | IMP/IMP | NLP/HM | Phthisis bulbi (RE) |
| IV-1 (63) | M | IMP/IMP | IMP/IMP | Yes/Yes | Yes/Yes | IMP/IMP | IMP/IMP | IMP | IMP | IMP | IMP/IMP | IMP/IMP | |
| IV-12 (59) | F | TAN/IMP | Yes/IMP | Yes/Yes | Yes/Yes | IMP/IMP | IMP/IMP | No | IMP | IMP | IMP/IMP | NLP/NLP | Phthisis bulbi (LE) |
| IV-27 (41) | F | IMP/PAN | ? | ? | ? | ? | ? | ? | ? | ? | ? | ? | Phthisis bulbi (RE) |
| IV-28 (35) | M | TAN/TAN | Yes/Yes | Yes/Yes | Yes/Yes | Yes/Yes | No/No | Yes | Yes | Yes | Yes/Yes | FC/FC | Macular reflex less |
| IV-29 (31) | M | PAN/PAN | ? | ? | ? | ? | ? | ? | ? | ? | ? | ? | |
| IV-31 (28) | M | TAN/TAN | No/No | Yes/No | No/No | Yes/Yes | No/Yes | Yes | No | No | No/Yes | HM/NLP | Macular reflex less (RE) |
| IV-46 (39) | F | TAN/TAN | Yes/Yes | Yes/Yes | No/No | Yes/Yes | No/No | Yes | Yes | ? | No/No | FC/FC | Microphthalmia |
| V-1 (28) | F | TAN/TAN | No/No | Yes/Yes | Yes/Yes | Yes/Yes | No/No | Yes | Yes | No | IMP/IMP | FC/FC | |
| V-2 (35) | M | IMP/TAN | Yes/No | Yes/Yes | Yes/Yes | IMP/Yes | IMP/Yes | Yes | Yes | No | IMP/IMP | NLP/NLP | Phthisis bulbi (RE) |
| V-4 (30) | F | TAN/TAN | No/Yes | Yes/Yes | Yes/Yes | Yes/Yes | No/IMP | Yes | Yes | No | No/IMP | 20/400/LP | |
| V-5 (27) | F | TAN/TAN | No/Yes | No/No | No/No | No/No | IMP/IMP | Yes | No | Yes | No/No | 20/400/20/400 | |
| V-12 (43) | M | TAN/TAN | No/No | No/No | No/No | Yes/Yes | No/No | Yes | Yes | ? | No/No | FC/FC | |
| V-13 (28) | M | PAN/MP | No/No | No/No | No/No | Yes/No | No/No | Yes | No | Yes | No/No | FC/FC | |
| V-15 (30) | M | MP/MP | No/No | No/No | No/No | Yes/Yes | No/No | Yes | Yes | Yes | No/No | FC/FC | |
| V-24 (18) | F | TAN/TAN | No/No | No/No | No/No | Yes/Yes | No/No | Yes | Yes | Yes | IMP/IMP | HM/HM | |
| V-27 (32) | F | TAN/TAN | No/Yes | No/No | No/No | Yes/Yes | No/No | Yes | No | Yes | IMP/IMP | HM/FC | Microphthalmia (LE) |
| V-33 (47) | F | TAN/TAN | No/Yes | Yes/Yes | Yes/Yes | IMP/IMP | No/No | Yes | No | Yes | IMP/IMP | NLP/NLP | |
| V-59 (33) | F | TAN/TAN | Yes/Yes | No/No | No/No | No/No | Yes/Yes | Yes | Yes | No | No/No | FC/FC | Macular reflex less |
| V-61 (22) | M | TAN/TAN | No/No | Yes/Yes | No/No | No/No | Yes/Yes | Yes | No | Yes | Yes/Yes | NLP/NLP | |
| V-64 (16) | M | TAN/TAN | No/No | No/No | No/No | Yes/Yes | No/No | Yes | No | No | No/No | FC/FC | |
| V-65 (20) | M | TAN/PAN | No/No | Yes/Yes | No/No | Yes/Yes | Yes/Yes | Yes | No | No | IMP/No | NLP/NLP | |
| V-66 (12) | F | TAN/TAN | No/No | No/No | No/No | Yes/Yes | No/No | Yes | No | Yes | No/No | NLP/NLP | |
| V-67 (8) | M | TAN/TAN | No/No | No/No | No/No | Yes/Yes | No/No | Yes | Yes | No | No/No | NLP/NLP | |
| V-74 (15) | M | MP/PAN | No/Yes | No/No | No/No | Yes/No | No/No | Yes | Yes | Yes | No/No | NLP/NLP | Microphthalmia (LE) |
| V-98 (12) | M | TAN/TAN | No/No | No/No | No/No | Yes/Yes | No/No | Yes | No | No | Yes/Yes | FC/FC | Microphthalmia |
| V-100 (6) | M | TAN/TAN | Yes/Yes | No/No | No/No | Yes/Yes | No/No | Yes | No | Yes | No/No | HM/HM | |
| V-101 (2) | F | PAN/PAN | Yes/Yes | No/No | No/No | No/No | No/No | Yes | Yes | No | No/No | HM/HM | |
| VI-1 (5) | M | TAN/TAN | No/No | Yes/No | No/No | No/Yes | No/No | Yes | Yes | Yes | ? | FC/FC | |
| VI-2 (3) | M | TAN/TAN | No/No | No/No | No/No | No/No | No/No | Yes | Yes | Yes | ? | HM/HM | |
| VI-7 (11) | F | MP/MP | No/No | No/No | No/No | No/No | No/No | Yes | Yes | Yes | No/No | 20/60/20/80 | Microphthalmia (LE) |

?, unavailable; FC, finger count; HM, hand motion; IMP, impracticable; LE, left eye; LP, light perception; MP, misshapen pupil; NLP, no light perception; PAN, partial aniridia; RE, right eye; TAN, total aniridia.

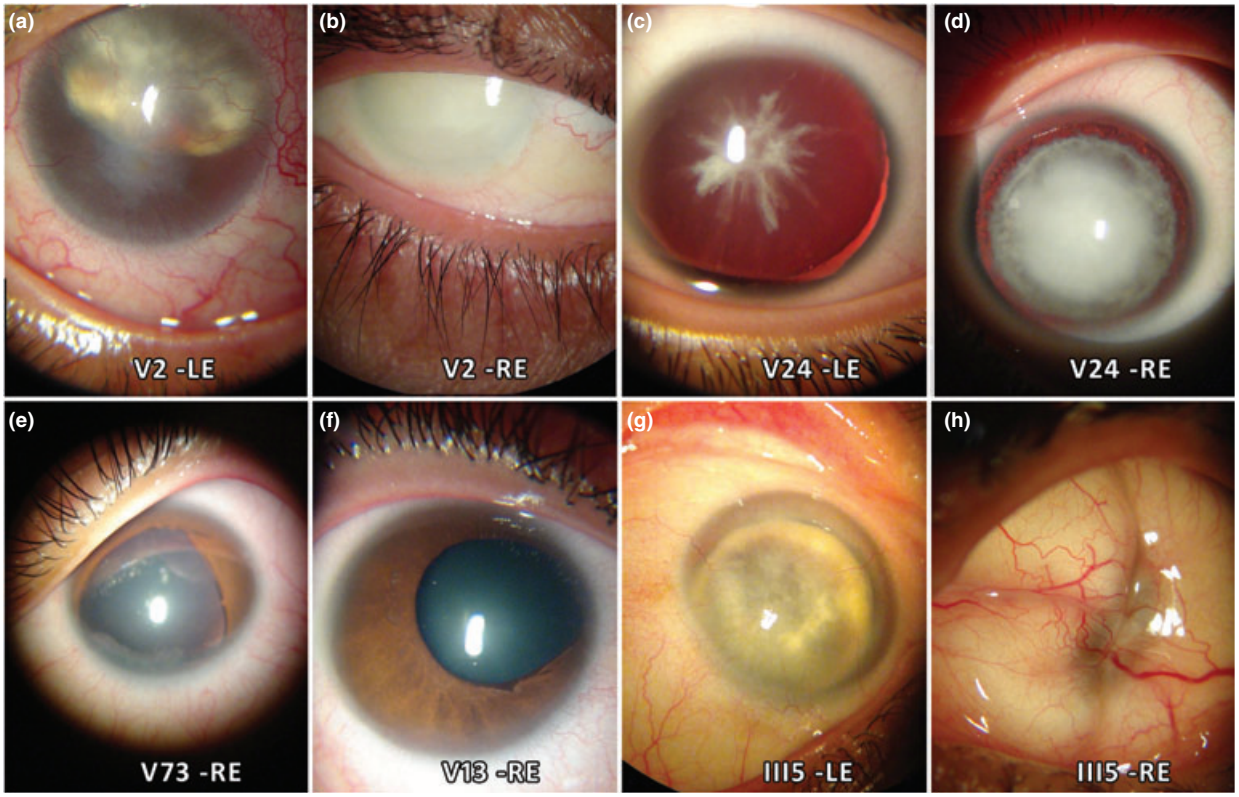


*Fig. 2.* Clinical features of affected subjects. (**a**) Subject V-2 left eye = total aniridia, cataract, and corneal opacity and vascularization; (**b**) Subject V-2 right eye = full corneal opacity; (**c**) Subject V-24 left eye = total aniridia and star-shaped cataract; (**d**) Subject V-24 right eye = total aniridia and full cataract; (**e**) Subject V-74 right eye = partial aniridia; (**f**) Subject V-13 right eye = misshapen pupil; (**g**) Subject III-5 left eye = total aniridia, full cataract, corneal vascularization, and subluxed lenses; (**h**) Subject III-5 right eye = Phthisis bulbi.

of the iris to mild iris defects. Splice site mutations modify or terminate mRNA processing and maturation, and can result in the complete skipping of one or more exons, retention of introns, pseudo-exons, or activation of cryptic splice sites within an exon or an intron. These splice-site mutations may or may not completely abolish expression of the wild-type *PAX6* transcript, which may lead to variation in the morphological phenotype (10–13).

In addition to congenital anomalies, clinical progression of the disorder involves gradual loss of vision combined with a variety of early-onset age-related ocular diseases, which were detected in the majority of the affected subjects in this family. This susceptibility to early-onset eye diseases can be attributed to the anti-apoptotic and multipotent switch functions *PAX6* plays in adult tissues (14), whereby the malfunction of PAX6 prevents proper cellular maintenance and regeneration in many ocular tissues.

*PAX6* is a pleiotropic gene that functions in multiple tissues during development. Homozygous mutations in the human *PAX6* gene result in an absence of nasal bones and defects in parietal bones, in addition to aniridia and other ocular abnormalities (15). Further, previous work in the field identified a subject with a compound heterozygous *PAX6* mutation that presented with severe bilateral microphthalmia and extreme microcephaly (16). Jami et al. (17) found that pax6 was expressed exclusively in the calvaria and long bone tissues during mouse development. These results indicate that *PAX6* might play a central role in stimulating the differentiation of mature osteoblasts to osteocytes in calvaria bones. Furthermore, this function is likely accomplished through the inhibition of canonical WNT signaling as PAX6 stimulates the expression of Sclerostin (SOST), a WNT pathway inhibitor, by binding to its promoter.

Considering this, our findings regarding the shape of the neurocranium, particularly the marked differences in CI and prominent brachycephalic head shape, may be associated with the severity of the ocular phenotype presented by these individuals. The affected individuals showed half of the correlation ($R^2 = 0.0522$) between face height and CI that their non-affected relatives did ($R^2 = 0.1069$). These results seem to be consistent with the role of *PAX6* in the spatial expression of neurocranial osteocytes, but not facial osteocytes, found in other studies (17). Together, this evidence suggests that the more brachycephalic head shape observed in affected individuals may be a result of the *PAX6* splice-site mutation.

In conclusion, this clinical study reports a large Brazilian family with congenital aniridia, summarizing the clinical variability of ocular phenotypes, related to a particular *PAX6* mutation (c.141 + 1G>A). Moreover,

we have shed light on the role of *PAX6* in the development of the neurocranium. Further research on genetic and environmental factors is needed to better understand the intricate developmental pathways involved in the phenotypic spectrum of congenital aniridia.

## Acknowledgements

The authors express their thanks to the patients and family members for their participation in this study. We also wish to thank the Agua Branca Health Department and Municipality for local support, with special thanks to Mrs Cristiany Maria Brandão Dantas for helping us find and assisting with patients' needs. We also thank J. Gómez-Valdés for valuable comments and assistance in the craniofacial analysis. This work was supported by Conselho Nacional de Desenvolvimento Científico e Tecnológico (CNPq), Coordenação de Aperfeiçoamento de Pessoal de Nível Superior (CAPES), and InaGEMP.

## References

1. López-García JS, García-Lozano I, Rivas L et al. Congenital aniridia keratopathy treatment. Arch Soc Esp Oftalmol 2006: 81 (8): 435–444.
2. Brauner SC, Walton DS, Chen TC. Aniridia. Int Ophthalmol Clin 2008: 48 (2): 79–85.
3. Kokotas H, Petersen MB. Clinical and molecular aspects of aniridia. Clin Genet 2010: 77 (5): 409–420.
4. Hingorani M, Hanson I, van Heyningen V. Aniridia. Eur J Hum Genet 2012: 20 (10): 1011–1017.
5. Lang D, Powell SK, Plummer RS et al. PAX genes: roles in development, pathophysiology, and cancer. Biochem Pharmacol 2007: 73 (1): 1–14.
6. Guerra-Junior G, Spinola-Castro AM, Siviero-Miachon A et al. Absence of mutations in PAX6 gene in three cases of morning glory syndrome associated with isolated growth hormone deficiency. Arq Bras Endocrinol Metabol 2008: 52 (8): 1221–1227.
7. França ESS. Mutations and polymorphisms analysis in PAX6 gene of patients with aniridia and morning glory syndrome. Master's thesis, Campinas, 2009, from http://www.bibliotecadigital.unicamp.br/document/?code=000468879. Accessed on August 10, 2012.
8. Park SH, Park YG, Lee MY et al. Clinical features of Korean patients with congenital aniridia. Korean J Ophthalmol 2010: 24 (5): 291–296.
9. Wang P, Guo X, Jia X et al. Novel mutations of the PAX6 gene identified in Chinese patients with aniridia. Mol Vis 2006: 12: 644–648.
10. Hubner CA, Senning A, Orth U et al. Mild Pelizaeus-Merzbacher disease caused by a point mutation affecting correct splicing of PLP1 mRNA. Neuroscience 2005: 132 (3): 697–701.
11. Noordzij JG, de Bruin-Versteeg S, Hartwig NG et al. XLA patients with BTK splice-site mutations produce low levels of wild-type BTK transcripts. J Clin Immunol 2002: 22 (5): 306–318.
12. Varon R, Dutrannoy V, Weikert G et al. Mild Nijmegen breakage syndrome phenotype due to alternative splicing. Hum Mol Genet 2006: 15 (5): 679–689.
13. Skjørringe T, Tümer Z, Møller LB. Splice site mutations in the ATP7A gene. PLoS One 2011: 6 (4): e18599.
14. Thompson JA, Ziman M. Pax genes during neural development and their potential role in neuroregeneration. Prog Neurobiol 2011: 95 (3): 334–351.
15. Hodgson SV, Saunders KE. A probable case of the homozygous condition of the aniridia gene. J Med Genet 1980: 17 (6): 478–480.
16. Solomon BD, Pineda-Alvarez DE, Balog JZ et al. Compound heterozygosity for mutations in PAX6 in a patient with complex brain anomaly, neonatal diabetes mellitus, and microphthalmia. Am J Med Genet A 2009: 149A (11): 2543–2546.
17. Jami A, Gadi J, Lee MJ et al. Pax6 expressed in osteocytes inhibits canonical Wnt signaling. Mol Cells 2013: 35 (4): 305–312.