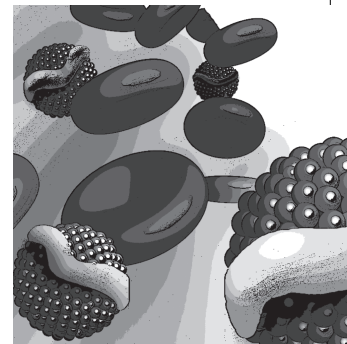

Examining the impact of bone pathology on type I Gaucher disease

Gaucher disease (GD) is an autosomal recessively inherited lysosomal disorder caused by mutations in *GBA* gene leading to deficient activity of the lysosomal enzyme acid β -glucocerebrosidase. Phenotypically, three different forms can be distinguished, type I GD being the most frequent, and characterized by the absence of involvement of the CNS. Affected organs are the spleen, liver, bone marrow and bone and, in severe cases, also the lung and kidney. Bone manifestations include bone pain, bone crises, osteopenia, osteoporosis, avascular necrosis and pathological fractures. Nowadays, skeletal alterations are the major cause of morbidity for patients, and a major concern for physicians who treat them, owing to the variable grade of response and refractoriness of bone pathology to treatment. Pathological mechanisms of bone alterations in GD are still poorly understood. Advances are being achieved in the knowledge of cellular and molecular mechanisms; by application of basic knowledge from osteoimmunology. GD as well as other lysosomal disorders is associated to a chronic stimulation of the immune system, especially the innate arm. Cellular alteration produces a proinflammatory milieu leading to enhancement of the activity of osteoclasts, the main degradative/resorptive cell of bone. This article focuses on the details of bone alterations, effect of therapies on skeletal pathology and our current state of knowledge of the complex pathophysiology of this orphan disease.

KEYWORDS: bone pathology ■ Gaucher disease ■ glucocerebrosidase
■ osteoimmunology ■ pathophysiology

Juan Marcos Mucci¹
& Paula Adriana
Rozenfeld*¹

¹LISIN, Departamento de Ciencias Biológicas, Facultad de Ciencias Exactas, Universidad Nacional de La Plata, 47 y 115 (1900) La Plata, Argentina

*Author for correspondence: paurozen@biol.unlp.edu.ar

Gaucher disease (GD) is an autosomal recessively inherited lysosomal disorder caused by mutations in *GBA* gene leading to deficient activity of the lysosomal enzyme acid β -glucocerebrosidase (EC 3.2.1.45). This enzyme failure results in impaired degradation and storage of the glycolipid glucosylceramide [1] in the lysosomes of macrophages (M ϕ). These so called 'Gaucher cells', a characteristic (but not pathognomonic) finding in various organs from patients, have an eccentric nuclei surrounded by a cytoplasm with a 'wrinkled tissue paper' appearance. It is the most common lysosomal disorder [2] and was the first in its group for which a specific treatment was introduced, the enzyme replacement therapy (ERT) [3].

Classically, three clinical forms of GD, I, II and III, can be distinguished, depending on the presence of neurological involvement and onset of manifestations. However, nowadays a continuum of phenotypes could be observed ranging from early to late onset and absent to severe neuropathic symptoms [4].

Type I GD

Type I GD (GD I) is the most frequent form, and distinguishes itself from the other two types

because of absence of involvement of the CNS. The estimated prevalence is 1:13,000–60,000, with a high frequency in the Ashkenazi Jewish population [5].

Clinical presentation is heterogeneous, ranging from asymptomatic adult patients to severely affected children. Affected organs include the spleen, liver, bone marrow and bone and, in severe cases, also the lung and kidney. The course of disease is chronic and progressive; patients display hepatosplenomegaly, hematological complications including anemia and thrombocytopenia with bleeding and bone alterations [6]. Splenomegaly is found in all but the least affected patients.

Patients with GD I may face only very few or atypical clinical symptoms, thus diagnosis of all affected persons is hard or even impossible, also in view of different diagnostic possibilities of countries around the world [7].

Diagnosis

The majority of Gaucher patients are suspected and diagnosed by hematologists, owing to significant hematological abnormalities commonly present in these patients [8]. For this reason, a

Future
Medicine  part of 

bone marrow biopsy is usually performed. This test reveals the presence of the characteristic lipid-engorged macrophage called 'Gaucher cell', with a 'wrinkled tissue paper' appearance of the cytoplasm and the eccentric, lobulated nucleus. By electron microscopy, typical tubular inclusions are found. Although bone marrow biopsy is a common practice for hematologists, it is not necessary for GD diagnosis, due to the availability of confirmatory enzymatic assay in leukocytes from peripheral blood. The result from bone marrow analysis is not definitive, it is associated with false positives and negatives. Examples of false positives, represented by detection of pseudo Gaucher cells, could be seen in hematologic malignancies such as multiple myeloma or leukemia. On the other hand, situations of samples from Gaucher patients without detection of Gaucher cells in bone marrow aspirate or biopsy were also described [9].

Confirmation of diagnosis is based on the detection of a deficiency of glucocerebrosidase activity in leukocytes from peripheral blood [10]. Genetic testing based on sequencing of *GBA1* gene is a complement for diagnosis. Data regarding mutations may be valuable for some correlation with phenotype especially important for family screening to provide genetic counseling [11].

Biomarkers of GD

A number of biochemical abnormalities have been described in GD [12] and several markers have been developed for laboratory monitoring of severity of disease and therapy outcome. Chitotriosidase is the most reliable biomarker and the most widely used in clinical practice [13]. However, there is an impediment for the use of this substance as a biomarker in some patients that is the existence of a common mutation in the chitotriosidase gene that inactivates the enzyme [14]. For those cases in which the chitotriosidase is not reliable, it is replaced by the measurement of the concentration of CCL18 in plasma [15,16]. Both chitotriosidase and CCL18 are produced by Gaucher cells [17]. They are not pathognomonic of this disease, other inflammatory conditions and lysosomal afflictions may be accompanied by increases in these biomarkers.

Lipid abnormalities in GD

The substrate glucosylceramide, which is accumulated in GD, is significantly increased in Gaucher plasma, by a factor of three, but there

is some overlap between levels from patients and controls [18]. Recently, glucosylsphingosine a derivative of glucosylceramide was found in plasma from Gaucher patients [19]. Concentrations of glucosylsphingosine for Gaucher untreated patients are 200-fold higher than that from controls or heterozygotes in whom no overlap was observed. The values correlate with disease severity and other biomarker changes. The data support the idea that Gaucher cells are the source of glucosylsphingosine and is largely a direct derivative of the primary storage product glucosylceramide. However, the precise biochemical pathway(s) contributing to formation of glucosylsphingosine in Gaucher patients are unknown. Owing to increases in this lipid have not been observed in other conditions, it was proposed as a specific biomarker for GD.

Lipid abnormalities in the sera of Gaucher patients are commonly observed. Levels of cholesterol and triglycerides were analyzed in Gaucher patients. Levels of HDL-cholesterol and ApoA1 were significantly lower and triglycerides levels were significantly higher in patients as compared with control subjects [20]. These values do not normalize in patients on treatment. Although low levels of HDL-cholesterol are found in Gaucher patients, there is no increase risk for cardiovascular disease.

Clinical manifestations

GD I is manifested as hematological, visceral and bone abnormalities. Main hematological problems are anemia and thrombopenia. Leucopenia could also be observed, but is not a major complication. They are caused by bone marrow infiltration together with splenic sequestration [21]. Severe thrombocytopenia subjects to patients to a high risk of bleeding. In addition, concurrent abnormalities of platelet function and coagulation factors may coexist, worsening hemorrhage tendency [22].

Enlargement of the liver and spleen are common in untreated GD I, owing to the infiltration of activated M ϕ in the sinusoids of the spleen and Kupffer cells of the liver. Liver function is usually normal. Furthermore, hepatic involvement may sometimes be associated with fibrosis [23]. Occasionally, severe infiltration of the lungs could be observed.

A rare complication of the condition is the development of hematological malignancies, most characteristically B-cell lymphomas and multiple myeloma, the pathogenesis of which is

incompletely understood. A review of literature has also described an increase risk of cancer in general [24].

Bone pathology in GD I

Bone pathology remains the main problem for GD I patients after the introduction of enzyme replacement therapy. Bone disease is a common and often painful and disabling manifestation of GD [25]. Multiple compartments of bone that are affected are caused by alterations in bone metabolism (turnover, remodeling and mineralization). Almost all GD patients develop skeletal complications, consisting mainly of remodeling failure, osteopenia, osteoporosis, marrow infiltration, avascular necrosis and osteolysis [26]. It may be suggested that patients with early onset GD I are at risk of skeletal disease. One of the early signs is the typical 'Erlenmeyer flask' deformity of the distal femur. These changes predominantly affect long bones and the vertebrae. Patients could be asymptomatic with or without radiological signs or present symptoms including bone pain involving one limb or joint, avascular necrosis or pathological fractures. An international registry of Gaucher patients worldwide revealed that 62% of them had some form of radiologic bone disease and 43% experienced bone pain [27]. The Mφ are prominent in the bone marrow and contribute to acute episodes of osteonecrosis, particularly during growth. Necrosis of the marrow leads to impaired function of joints. Other effects on the skeleton include local swellings (Gaucheromas). Imaging methodologies for the evaluation of skeletal involvement, such as conventional (plain) radiography and scintigraphy, MRI, computed tomography or dual energy x-ray absorptimetry are currently employed and provide accurate evaluation and staging of bone lesions in GD [28].

Bone disease & ERT

Much evidence demonstrates substantial improvement of hematological and visceral parameters upon introduction of specific ERT for Gaucher patients [29]. However, bone tissue does not respond equally, it is, in some degree, refractory to therapy. Patients at risk may benefit from early intervention with ERT, although many lesions and osteonecrosis are irreversible. Enzyme therapy cannot reverse established osseous injury [30].

Several prospective studies have been performed to evaluate the effectiveness of ERT in

treating skeletal pathology. Bone pain is present at baseline in around two-thirds of the patients. Some patients improve in this aspect, but 40% of patients remain with this symptom after 18 months of treatment. In a recent study of patients treated with imiglucerase for 10 years, a positive effect was observed in skeletal symptoms, as well as a reduction of bone pain and crises in patients who suffer from them at baseline. Moreover, most of the patients who did not report bone symptoms at baseline continued to be pain free after 10 years of ERT [31].

Bone mineral density tends to increase during therapy, but the response is slow [30]. Patients with pre-existent skeletal complications tend to suffer incidents during ERT, such as medullary infarctions, avascular necrosis or fractures, but the frequency of these events is reduced [32].

Low bone density manifests early in children with GD, and mineral density deficit is maximal in the adolescent period. Moreover, this group is most responsive to ERT, underscoring the importance of early diagnosis and intervention to achieve optimal peak bone mass [33]. In the largest study with treated pediatric patients bone mineral health was impaired in a large proportion of the group before ERT and improved considerably with treatment [34].

Markers of bone turnover

Biochemical markers of bone turnover are widely used tools for the evaluation of patients with bone diseases. Osteocalcin is a sensitive marker of bone formation and type I collagen telopeptides (carboxy- and amino-terminal telopeptides) are useful indicators of bone resorption because they are released from collagen molecules during osteoclastic activity [35]. However, currently, there is no recommended biomarker that correlates or predicts skeletal alterations of GD [36].

Different studies evaluated bone biomarker levels, but different or discordant results were found in various reports. Analysis in Gaucher patients revealed markedly reduced levels of both serum osteocalcin and type I collagen C-terminal telopeptide indicative of a continuous loss of bone mass, which was clinically expressed by osteopenia and osteoporosis [37,38]. The study from Ciana *et al.*, reported increased bone resorption as identified by a decrease in carboxyterminal propeptide of type I procollagen and an increase in carboxyterminal telopeptide of type I collagen, while osteocalcin was unchanged [39]. By contrast, Sims *et al.* reported normal bone biomarker (osteocalcin,

bone specific alkaline phosphatase, type 1 collagen *N*-terminal telopeptide and deoxypyridinoline) levels at baseline [40]. In conclusion, it seems to be an uncoupling of bone resorption and formation, with varying studies reflecting both reduced bone formation and/or increased resorption in Gaucher patients.

Splenectomy

Splenomegaly is present in all but the least affected Gaucher patients and is the most common presenting manifestation [25]. A common practice before the advent of ERT was the splenectomy, in order to correct cytopenias, hypersplenism and mechanical pressure. After the ERT era, splenectomy is becoming a rare indication, only used in exceptional circumstances after assessment by a physician who is experienced in the management of GD [36]. It has been demonstrated that splenectomy worsens the clinical course of patients. The proposed explanation for this fact is that the spleen would be the major reservoir for lipid laden M ϕ , but in its absence, other organs, such as the bone marrow or liver become more affected. Indeed, bone disease is more severe in splenectomized patients [41].

Pathophysiological mechanisms of bone involvement: osteoimmunology

Chronic immune stimulation in GD was found several years ago; however, until recently there was a lack of immunological insight of the molecular mechanisms explaining this aspect. First studies showing immune compromise have focused on analyzing cytokine levels in sera from patients [42–44]. Although patients show high variations, increased levels of IL-1 α , IL-1 β , IL-1Ra, sIL-2R, IL-6, IL-8, IL-10, IL-18, TNF- α , TGF- β , M-CSF, MIP-1 and CCL18 have been reported in sera [15,45,46].

Machrophages (M ϕ) are crucial cells in innate immunity. Owing to the specific compromise of these cells in GD, it would be reasonable to analyze the functionality of lipid laden M ϕ or Gaucher cells. M ϕ are a heterogeneous group of cells, whose morphology and phenotype differ depending on the tissue/organ and stimuli. They participate in tissue remodeling, host defense and many disease processes. They can secrete both anti- or pro-inflammatory cytokines. Upon activation, two main phenotypes of M ϕ could be produced: classical or alternative, depending on environment present at the time of the stages of activation [47]. Gaucher cells resemble alternative

activated M ϕ [17], characterized by the expression of chitotriosidase and CCL18.

Involvement of monocytes, M ϕ , dendritic cells, T and B cells have been demonstrated in GD [48–50]. Circulating levels of dendritic cells from untreated patients were decreased [51]. Increased levels of CD1d and MHCII on the surface of monocytes have been observed, which could lead to an increased T-cell activation [52]. Abnormalities associated with B-cell compromise were detected, such as IgG and IgM hypergammaglobulinemia and plasmacytosis [53]. ERT treatment lowers IgG and IgM levels [54,55]. An increased incidence of gammopathies and multiple myeloma has been reported, implying interplay between Gaucher cells and the immune system [56].

Recently, a new GD murine model was generated, in which the *GBA* gene was conditionally deleted on hematopoietic cells [57]. This model presents the hallmark characteristics of GD I, including organomegaly and bone involvement. Moreover, an alteration of immune cell compartment was revealed. Altered thymic maturation was evident with higher levels of CD4+ and antigen-presenting cells. Higher numbers of activated B cells on the thymus were also found, which could explain the alteration of normal T-cell maturation [58]. On the same year Pandey *et al.* working with another murine model, showed higher levels of CD4+ cells on lung, spleen and liver as well as an increased expression of costimulatory molecules [59]. In mice sera, higher levels of IFN- γ , IL-12p40, TNF- α , IL-17A/F, IL-6 and TGF- β were found. When T cells were cocultured with dendritic cells in the presence of glucosylceramide, higher levels of Th1/Th17 cytokines were secreted.

This deregulation of immune system cells is tightly related to the increased levels of cytokines and chemokines. These molecules are secreted by the immune cells, which, in turn, are recruited and activated by chemokines and cytokines, respectively. This could create a loop in which immune cells from Gaucher patients are being continuously activated, leading to systemic and focal activation of the immune system.

It is now well acknowledged that immune and skeletal systems interact and affect one another during developmental physiology and pathology. With the aid of modern conditional gene targeting and transgenic technologies, this field of interdisciplinary research, known as osteoimmunology, has been rapidly advancing [60].

Currently, we are over the idea that bone is a metabolically inert tissue. Nowadays it is well known bone is a dynamic tissue that remodels over a life-long period. This remodeling process involves bone removal by resorbing osteoclasts and bone formation by osteoblasts. These processes are strictly regulated in physiological conditions and this regulation implies the participation of osteocytes, which are the final step of osteoblast differentiation and mechanosensory receptors [61].

Bone marrow stem cells are contained within bone. Mesenchymal stem cells, in part, differentiate into osteoblasts and osteocytes. Hematopoietic stem cells give rise to myeloid precursors that differentiate into osteoclasts, and to lymphoid precursors originating lymphocytes [62].

Excessive osteoclast activity leads to pathological bone resorption; a process observed in several conditions such as rheumatoid arthritis, bone metastasis and osteoporosis [63].

In 1998, the molecule expressed on osteoclastogenesis-supporting mesenchymal cells, essential for osteoclast differentiation was cloned [64,65]. Immunologists cloned the same molecule as a stimulator of dendritic cells expressed by T cells and named it RANKL [66,67]. RANKL is a transmembrane protein of the TNF superfamily encoded by the *Tnfrsf11* gene. It is expressed on the surface of osteoblasts (at different stages of differentiation), osteocytes, stromal cells of undefined origin, B and T lymphocytes, synovial fibroblasts, hypertrophic chondrocytes even osteoclasts themselves. The receptor of RANKL is RANK, which is encoded by the *Tnfrsf11a* gene. Upon stimulation of RANK by RANKL under costimulatory signals such as M-CSF, the process of osteoclast differentiation and maturation begins [68]. The third protein member of the osteoclastogenesis axis, is called osteoprotegerin (OPG) and is encoded by the *Tnfrsf11b* gene. OPG functions as a soluble decoy receptor for RANKL, inhibiting RANKL interaction with RANK, thus acting like an antiosteoclastogenic molecule [69]. OPG is expressed by osteoblasts and other mesenchymal cells [70].

Mice lacking *Tnfrsf11* or *Tnfrsf11a* exhibit severe osteopetrosis with absence of tooth eruption due to a complete absence of osteoclasts [71]. On the other hand, mice that lack the *Tnfrsf11b* gene present osteoporosis with spontaneous fractures due to a greater number and activity of osteoclasts [72].

Taken together, these results demonstrate that the RANK/RANKL/OPG axis is essential

in osteoclast differentiation *in vivo*. Mutations in genes encoding RANKL, RANK or OPG lead to disorders with high bone pathology [73].

RANKL presents in two different forms as a membrane anchored molecule or as a soluble protein released by the action of matrix metalloproteinases [74]. Both forms of the protein have osteoclastogenesis activity; however, the membrane-anchored form functions more efficiently [75]. RANKL expression on mesenchymal cells, such as osteoblasts, is upregulated by osteoclastogenic factors such as vitamin D3, prostaglandin E2, parathyroid hormone, IL-1, IL-6, IL-11, IL-17 and TNF- α [76].

Although mice lacking RANK or RANKL presented complete absence of osteoclasts, the induction of osteoclast differentiation could be achieved *in vitro* in the absence of both molecules. In this case, the protein responsible for osteoclast generation was the cytokine TNF- α . These studies provided evidence of a potential alternative route for osteoclast differentiation [77].

Until recently, the role of osteocytes in bone homeostasis was unclear. Experiments using transgenic mice have demonstrated that osteocytes can independently control bone resorption and bone formation via modulation of different pathways [78]. By using different isolation approaches to purify osteoblasts and osteocytes, it was shown that osteocytes express significantly higher levels of RANKL compared with osteoblasts [79] leading to a more efficient support of osteoclastogenesis.

Mice bearing a conditional deficiency of RANKL on osteocytes did not show growth abnormalities or tooth eruption, but presented with a higher bone volume when analyzed at 3 or 6 months of age [80]. The number and activity parameters of osteoclasts were reduced. In other studies, the complete ablation of osteoblasts in adult mice, did not affect osteoclast number or activity, or RANKL expression on the bone [81], which supports the hypothesis that osteocyte effect on osteoclastogenesis plays an important role in bone homeostasis.

The molecular and cellular basis of GD bone physiopathology are not well understood and opposing studies have emerged in the last few years. In 2010, Mistry *et al.* [57] generated a mouse model of GD I by conditionally deleting exons 8–11 from the *GBA* gene on cells of the hematopoietic and mesenchymal stem cell lineages. The mouse presented the main GD clinical hallmarks including hepatosplenomegaly, anemia and thrombocytopenia. One of the most important

features about this model is the presence of bone involvement including medullar infarctions with associated avascular necrosis and osteopenia at all sites. A significant reduction on bone formation rate was present on 14-months-old mice while TRAP-labeled surfaces were unaltered.

The model presented impairment of osteoblast proliferation and differentiation, while neither osteoclastogenesis nor osteoclast resorptive activity seemed to be altered. The reduction of osteoblast proliferation seemed to arise from an inhibition on the intrinsic PKC activity due to the accumulation of glucosylsphingosine and, to a lesser extent, glucosylceramide. These findings suggest that bone complications in GD would result from an osteoblast source without osteoclast involvement [57].

On the other hand, several reports have demonstrated participation of osteoclasts on GD bone pathophysiology. Lecourt *et al.* used mesenchymal stem cells and monocytes from healthy controls exposed to conduritol- β -epoxide (CBE), a specific glucocerebrosidase inhibitor. CBE treatment on mesenchymal stem cells had no effect on their capacity to differentiate into osteoblasts and the generation of mineral matrix. The inhibitor had no direct effect on osteoclast differentiation or resorption activity. However, when mesenchymal stem cells were cultured in the presence of conditioned media from CBE-exposed monocytes, an increased osteoclastogenesis and resorption activity was detected [82].

Using a similar approach, our group showed that conditioned media from peripheral blood mononuclear cells (PBMCs) exposed to CBE had an increased capacity to generate osteoclasts when applied on osteoclast precursors. Moreover these osteoclasts had increased resorptive capacity and secreted greater amounts of matrix metalloproteinases, when compared with untreated controls. We have also demonstrated that this process involved, at least in part, the proinflammatory cytokine TNF- α and T cells, both known to be related to osteoclast differentiation [83].

Using PBMC isolated from patients with GD, Reed *et al.* showed that patients' cells had an increased differentiation potential when exposed to osteoclastogenic mediators [84].

Osteoclasts differentiated from patients had more resorption capacity, were bigger and had a greater number of nuclei when compared with osteoclasts differentiated from healthy controls' PBMCs. The osteoclastogenesis potential had a clinical correlation with patient's bone involvement [84].

The differences observed between the mouse and human models regarding the involvement of osteoclasts and/or osteoblasts in the bone pathophysiology of GD could arise from the fact that the conditional mouse model lacks enzymatic activity only on cells of the hematopoietic lineage. Osteoclasts from mouse models are induced to be glucocerebrosidase deficient in the first days of life, but osteoblasts/osteocytes are normal cells. Therefore it could be that the regulation of osteoclastogenesis in mouse model is not reliably modeling the situation of bone in a Gaucher patient in which all body cells are mutant since fertilization. Regarding experiments using human cells, such as the ones using Gaucher patients' derived or CBE-treated mononuclear cells, all the cells in the *in vitro* culture are enzyme deficient, restricting the study to these isolated cells without the effect of other bone cells.

In conclusion, there is evidence supporting alterations in both bone formation and resorption activities in GD. Indeed, a recently published study from our group provided evidence that bone formation and resorption activities are affected in GD, both contributing to reduced bone mineral density characteristic of this disorder [85].

A plausible model explaining bone pathology in GD is shown in **Figure 1**. An increase in osteoclastogenic and proinflammatory cytokines and molecules, in patients' circulation and/or bone marrow microenvironment, could lead to bone destruction mechanisms through an increment of osteoclast differentiation and resorptive activity. This process could be mediated, at least in part, by the osteoclastogenic Th17 subset as our group showed T-cell dependent osteoclast induction in our *in vitro* chemical model of GD. Another possible mechanism is an increase of the osteoclastogenic molecule RANKL, either as its membrane bound form on osteoblasts, T cells or osteocytes (not shown) or in its soluble form.

On the other hand, there could be bone formation impairment as a result of different causes [57,84]. Osteoblast differentiation and proliferation could be diminished owing to the direct accumulation of glucosylceramide or by external signaling. Another possibility is the induction of apoptosis in osteoblasts through mechanisms involving soluble mediators or intrinsic impairment due to substrate accumulation. Further knowledge of molecular and cellular physiopathological mechanisms that lead to inflammatory activation and bone deregulation would

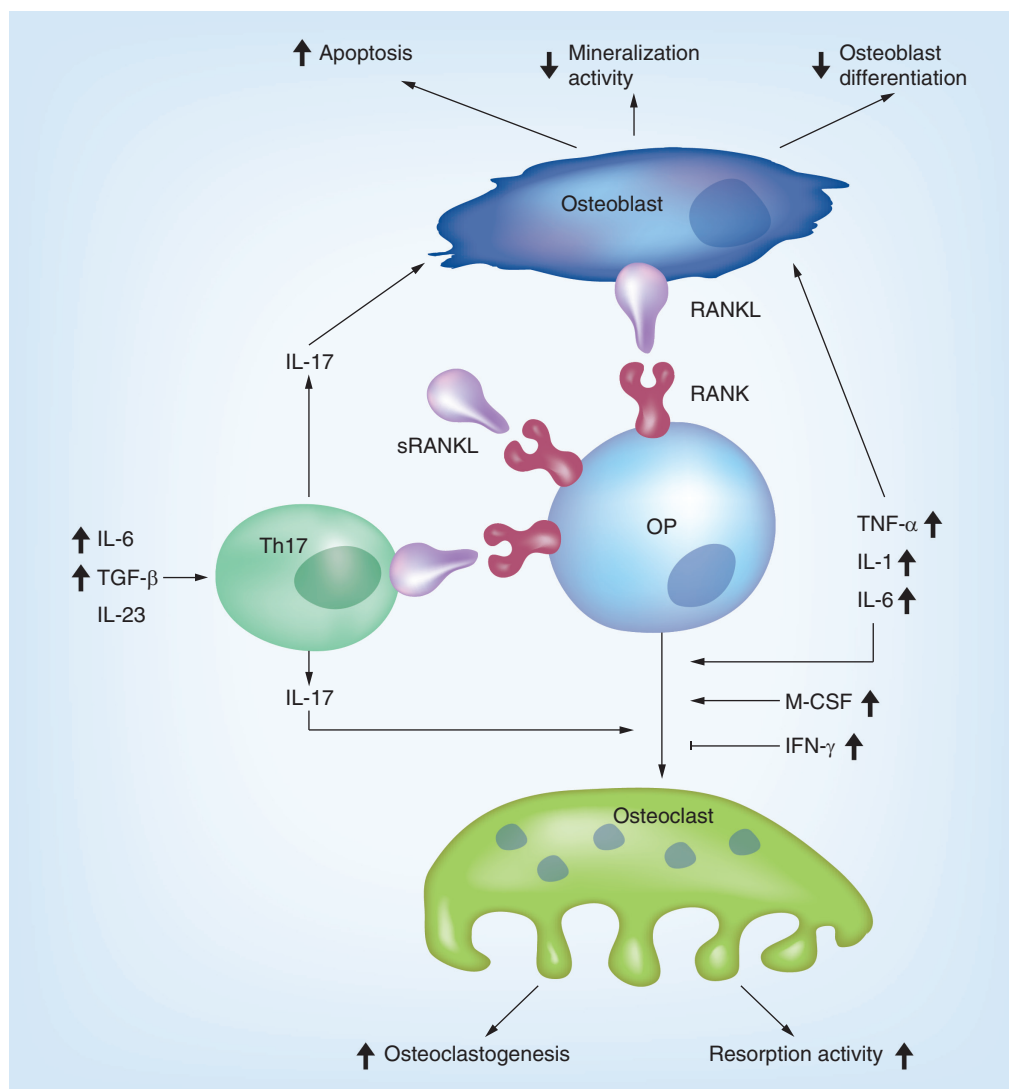


Figure 1. Possible mechanisms underlying bone pathology in type I Gaucher disease. Bold upward facing arrows indicate increase and bold downward facing arrows indicate decrease. See text for explanation.

OP: Osteoclast precursor; sRANKL: Soluble RANKL.

help to develop directed therapies specifically to correct the underlying defect.

Future perspective

GD is the most common lysosomal disorder and the first for which specific treatment has been developed. After more than 20 years of experience with enzyme replacement therapy, there is still much to do. Resolving bone disease of Gaucher patients is the main challenge to ameliorate the quality of life of patients. Currently, we are in the starting point of underscoring the underlying pathophysiological mechanisms that alters bone tissue homeostasis. Studies are designed to explain the cellular pathways that result upon glucosylceramide accumulation in M ϕ and its impact in different lineage of bone cells.

Application of basic knowledge from osteoimmunology is helping to elucidate this aspect. The results of basic research will be of utility in order to identify new targets for adjuvant therapies to treat skeletal pathology in GD.

Financial & competing interests disclosure

PA Rozenfeld has received research grants from Shire HGT and acts as a consultant for Shire HGT. However, this arrangement would not have any influence on this work. The authors have no other relevant affiliations or financial involvement with any organization or entity with a financial interest in or financial conflict with the subject matter or materials discussed in the manuscript apart from those disclosed.

No writing assistance was utilized in the production of this manuscript.

Executive summary

Background

- Gaucher disease (GD) is a lysosomal disorder caused by deficient activity of acid β -glucocerebrosidase, resulting in storage of the glycolipid glucosylceramide in the lysosomes of macrophages.
- The course of disease is chronic and progressive; patients display hepatosplenomegaly, hematological complications including anemia and thrombocytopenia with bleeding and bone alterations.

Lipid abnormalities in GD

- Concentrations of glucosylsphingosine for Gaucher untreated patients are higher than that from controls. It was proposed as a specific biomarker for GD.

Bone pathology in type I GD

- Bone pathology remains the main problem for type I Gaucher patients after the introduction of enzyme replacement therapy. Almost all GD patients develop skeletal complications.

Bone disease & ERT

- Bone tissue response to therapy is suboptimal, it is in some degree, refractory to therapy. Many lesions are irreversible. Enzyme therapy cannot reverse established osseous injury.

Splenectomy

- Splenectomy was a common practice before the advent of ERT. Now it is becoming a rare indication. Splenectomy worsens the clinical course of patients.

Pathophysiological mechanisms of bone involvement: osteoimmunology

- A chronic immune stimulation was found in GD. Macrophages affected in Gaucher patients are in a state of activation. Different immune cells are compromised are secreting chemokines and cytokines, leading to systemic and focal activation of the immune system. Immune and skeletal systems interact and affect one another, altering bone homeostasis. There is evidence supporting alterations both in bone formation and resorption activities in GD.

References

Papers of special note have been highlighted as:

- of interest
- of considerable interest

<p>1 Grabowski GA, Beutler E. Gaucher disease. In: <i>The Online Metabolic and Molecular Basis of Inherited Diseases</i>. Scriver CR, Beaudet AL, Sly WS (Eds). McGraw-Hill, NY, USA (2009).</p> <p>2 Meikle PJ, Hopwood JJ, Clague AE <i>et al</i>. Prevalence of lysosomal storage disorders. <i>JAMA</i> 281, 249–254 (1999).</p> <p>3 Barton NW, Brady RO, Dambrosia JM <i>et al</i>. Replacement therapy for inherited enzyme deficiency-macrophage-targeted glucocerebrosidase for Gaucher's disease. <i>N. Engl. J. Med.</i> 324, 1464–1470 (1991).</p> <p>4 Mistry P, Germain DP. Phenotype variations in Gaucher disease. <i>Rev. Med. Intern.</i> 27(Suppl. 1), S3–S10 (2006).</p> <p>5 Wittmann J, Karg E, Turi S <i>et al</i>. Newborn screening for lysosomal storage disorders in Hungary. <i>JIMD Rep.</i> 6, 117–125 (2012).</p> <p>6 Mehta A. Epidemiology and natural history of Gaucher's disease. <i>Eur. J. Intern. Med.</i> 17(Suppl.), S2–S5 (2006).</p> <p>7 Cox TM, Schofield JP. Gaucher's disease: clinical features and natural history. <i>Baillieres Clin. Haematol.</i> 10, 657–689 (1997).</p> <p>8 Charrow J, Andersson HC, Kaplan P <i>et al</i>. The Gaucher registry: demographics and disease characteristics of 1698 patients with Gaucher disease. <i>Arch. Intern. Med.</i> 160, 2835–2843 (2000).</p>	<p>9 Mistry PK, Cappellini MD, Lukina <i>et al</i>. A reappraisal of Gaucher disease-diagnosis and disease management algorithms. <i>Am. J. Hematol.</i> 86, 110–115 (2011).</p> <p>▪▪ The review is the result of a consensus meeting of experts in the field convened to develop algorithms for diagnosis and disease management for Gaucher disease.</p> <p>10 Raghavan SS, Topol J, Kolodny EH. Leukocyte beta-glucosidase in homozygotes and heterozygotes for Gaucher disease. <i>Am. J. Hum. Genet.</i> 32, 158–173 (1980).</p> <p>11 Charrow J, Esplin JA, Gribble TJ <i>et al</i>. Gaucher disease: recommendations on diagnosis, evaluation, and monitoring. <i>Arch. Intern. Med.</i> 158, 1754–1760 (1998).</p> <p>12 Hollak CE, Evers L, Aerts JM <i>et al</i>. Elevated levels of M-CSF, sCD14 and IL8 in type 1 Gaucher disease. <i>Blood Cells Mol. Dis.</i> 23, 201–212 (1997).</p> <p>13 Hollak CE, van Weely S, van Oers MH <i>et al</i>. Marked elevation of plasma chitotriosidase activity. A novel hallmark of Gaucher disease. <i>J. Clin. Invest.</i> 93, 1288–1292 (1994).</p> <p>14 Boot RG, Renkema GH, Verhoek M <i>et al</i>. The human chitotriosidase gene. Nature of inherited enzyme deficiency. <i>J. Biol. Chem.</i> 273, 25680–25685 (1998).</p> <p>15 Boot RG, Verhoek M, de Fost M <i>et al</i>. Marked elevation of the chemokine CCL18/PARC in Gaucher disease: a novel surrogate marker for assessing therapeutic intervention. <i>Blood</i> 103, 33–39 (2004).</p>	<p>16 Vellodi A, Foo Y, Cole TJ. Evaluation of three biochemical markers in the monitoring of Gaucher disease. <i>J. Inherit. Metab. Dis.</i> 28, 585–592 (2005).</p> <p>17 Boven LA, van Meurs M, Boot RG <i>et al</i>. Gaucher cells demonstrate a distinct macrophage phenotype and resemble alternatively activated macrophages. <i>Am. J. Clin. Pathol.</i> 122, 359–369 (2004).</p> <p>18 Groener JE, Poorthuis BJ, Kuiper S <i>et al</i>. Plasma glucosylceramide and ceramide in type 1 Gaucher disease patients: correlations with disease severity and response to therapeutic intervention. <i>Biochim. Biophys. Acta.</i> 1781, 72–78 (2008).</p> <p>19 Dekker N, van Dussen L, Hollak CE <i>et al</i>. Elevated plasma glucosylsphingosine in Gaucher disease: relation to phenotype, storage cell markers, and therapeutic response. <i>Blood</i> 118, e118–e127 (2011).</p> <p>▪ Describes the discovery of plasma glucosylsphingosine as a biomarker for type 1 Gaucher disease.</p> <p>20 de Fost M, Langeveld M, Franssen R <i>et al</i>. Low HDL cholesterol levels in type I Gaucher disease do not lead to an increased risk of cardiovascular disease. <i>Atherosclerosis</i> 204, 267–272 (2009).</p> <p>21 Zimran A, Altarescu G, Rudensky B <i>et al</i>. Survey of hematological aspects of Gaucher disease. <i>Hematology</i> 10, 151–156 (2005).</p> <p>22 Spectre G, Roth B, Ronen G <i>et al</i>. Platelet adhesion defect in type I Gaucher disease is</p>
--	--	--

- associated with a risk of mucosal bleeding. *Br. J. Haematol.* 153, 372–378 (2011).
- 23 Bohte AE, van Dussen L, Akkerman EM *et al.* Liver fibrosis in type I Gaucher disease: magnetic resonance imaging, transient elastography and parameters of iron storage. *PLoS ONE* 8, e57507 (2013).
- 24 Arends M, van Dussen L, Biegstraaten M *et al.* Malignancies and monoclonal gammopathy in Gaucher disease; a systematic review of the literature. *Br. J. Haematol.* 161, 832–842 (2013).
- 25 Beutler E, Grabowski GA. Gaucher disease. In: *The Metabolic and Molecular Bases of Inherited Disease*. Scriver CR, Beaudet AL, Sly WS *et al.* (Eds). McGraw-Hill, NY, USA, 3635–3668 (2001).
- 26 Itzchaki M, Lebel E, Dweck A *et al.* Orthopedic considerations in Gaucher disease since the advent of enzyme replacement therapy. *Acta Orthop. Scand.* 75, 641–653 (2004).
- **Outlines findings from a large group of patients and from the literature in the decade since the advent of specific enzyme replacement therapy.**
- 27 Weinreb NJ, Charrow J, Andersson HC *et al.* Effectiveness of enzyme replacement therapy in 1028 patients with type 1 Gaucher disease after 2 to 5 years of treatment: a report from the Gaucher Registry. *Am. J. Med.* 113, 112–119 (2002).
- 28 Katz R, Booth T, Hargunani R *et al.* Radiological aspects of Gaucher disease. *Skeletal Radiol.* 40, 1505–1513 (2011).
- 29 Elstein D, Cohn GM, Wang N *et al.* Early achievement and maintenance of the therapeutic goals using velaglucerase alfa in type 1 Gaucher disease. *Blood Cells Mol. Dis.* 46, 119–123 (2011).
- **Reports achievement of therapeutic goals after specific enzyme replacement treatment for Gaucher patients.**
- 30 Sims KB, Pastores GM, Weinreb NJ *et al.* Improvement of bone disease by imiglucerase (Cerezyme) therapy in patients with skeletal manifestations of type 1 Gaucher disease: results of a 48-month longitudinal cohort study. *Clin. Genet.* 73, 430–440 (2008).
- 31 Weinreb NJ, Goldblatt J, Villalobos J *et al.* Long-term clinical outcomes in type 1 Gaucher disease following 10 years of imiglucerase treatment. *J. Inherit. Metab. Dis.* 36, 543–553 (2013).
- 32 Stirnemann J, Belmatoug N, Vincent C *et al.* Bone events and evolution of biologic markers in Gaucher disease before and during treatment. *Arthritis Res. Ther.* 12, R156 (2010).
- 33 Mistry PK, Weinreb NJ, Kaplan P *et al.* Osteopenia in Gaucher disease develops early in life: response to imiglucerase enzyme therapy in children, adolescents and adults. *Blood Cells Mol. Dis.* 46, 66–72 (2011).
- 34 Andersson H, Kaplan P, Kacena K *et al.* Eight-year clinical outcomes of long-term enzyme replacement therapy for 884 children with Gaucher disease type 1. *Pediatrics* 122, 1182–1190 (2008).
- 35 Delmas PD, Hardy P, Garnero P *et al.* Monitoring individual response to hormone replacement therapy with bone markers. *Bone* 26, 553–560 (2000).
- 36 Cox TM, Aerts JM, Belmatoug N *et al.* Management of non-neuronopathic Gaucher disease with special reference to pregnancy, splenectomy, bisphosphonate therapy, use of biomarkers and bone disease monitoring. *J. Inherit. Metab. Dis.* 31, 319–336 (2008).
- 37 Drugan C, Jelebeanu G, Grigorescu-Sido P *et al.* Biochemical markers of bone turnover as tools in the evaluation of skeletal involvement in patients with type 1 Gaucher disease. *Blood Cells Mol. Dis.* 28, 13–20 (2002).
- 38 van Dussen L, Lips P, Everts VE *et al.* Markers of bone turnover in Gaucher disease: modeling the evolution of bone disease. *J. Clin. Endocrinol. Metab.* 96, 2194–2205 (2011).
- 39 Ciana G, Addobbati R, Tamaro G *et al.* Gaucher disease and bone: laboratory and skeletal mineral density variations during a long period of enzyme replacement therapy. *J. Inherit. Metab. Dis.* 28, 723–732 (2005).
- 40 Sims KB, Pastores GM, Weinreb NJ *et al.* Improvement of bone disease by imiglucerase (Cerezyme) therapy in patients with skeletal manifestations of type 1 Gaucher disease: results of a 48-month longitudinal cohort study. *Clin. Genet.* 73, 430–440 (2008).
- 41 Khan A, Hangartner T, Weinreb NJ *et al.* Risk factors for fractures and avascular osteonecrosis in type 1 Gaucher disease: a study from the International Collaborative Gaucher Group (ICGG) Gaucher Registry. *J. Bone Miner. Res.* 27, 1839–1848 (2012).
- 42 Michelakakis H, Spanou C, Kondyli A *et al.* Plasma tumor necrosis factor- α (TNF- α) levels in Gaucher disease. *Biochim. Biophys. Acta* 1317, 219–222 (1996).
- 43 Barak V, Acker M, Nisman B *et al.* Cytokines in Gaucher's disease. *Eur. Cytokine Netw.* 10, 205–210 (1999).
- 44 Hollak CE, Evers L, Aerts JM *et al.* Elevated levels of M-CSF, sCD14 and IL8 in type 1 Gaucher disease. *Blood Cells Mol. Dis.* 23, 201–212 (1997).
- 45 van Breemen MJ, de Fost M, Voerman JS *et al.* Increased plasma macrophage inflammatory protein (MIP)-1 α and MIP-1 β levels in type 1 Gaucher disease. *Biochim. Biophys. Acta* 1772, 788–796 (2007).
- 46 Yoshino M, Watanabe Y, Tokunaga Y *et al.* Roles of specific cytokines in bone remodeling and hematopoiesis in Gaucher disease. *Pediatr. Int.* 49, 959–965 (2007).
- 47 Gordon S, Martinez FO. Alternative activation of macrophages: mechanism and functions. *Immunity* 32, 593–604 (2010).
- 48 Lacerda L, Arosa FA, Lacerda R *et al.* T cell numbers relate to bone involvement in Gaucher disease. *Blood Cells Mol. Dis.* 25, 130–138 (1999).
- 49 Camou F, Viillard JF. Extended remission of B-cell lymphoma with monoclonal gammopathy in a patient with type 1 Gaucher disease treated with enzyme replacement therapy. *Blood Cells Mol. Dis.* 48(1), 51–52 (2012).
- 50 Braudeau C, Graveleau J, Rimbart M *et al.* Altered innate function of plasmacytoid dendritic cells restored by enzyme replacement therapy in Gaucher disease. *Blood Cells Mol. Dis.* 50, 281–288 (2013).
- 51 Micheva I, Marinakis T, Repa C *et al.* Dendritic cells in patients with type I Gaucher disease are decreased in number but functionally normal. *Blood Cells Mol. Dis.* 36, 298–307 (2006).
- 52 Balreira A, Lacerda L, Miranda CS *et al.* Evidence for a link between sphingolipid metabolism and expression of CD1d and MHC-class II: monocytes from Gaucher disease patients as a model. *Br. J. Haematol.* 129, 667–676 (2005).
- 53 Marti GE, Ryan ET, Papadopoulos NM *et al.* Polyclonal B-cell lymphocytosis and hypergammaglobulinemia in patients with Gaucher disease. *Am. J. Hematol* 29, 189–194 (1988).
- 54 Arikan-Ayyıldız Z, Yuca A, Uslu-Kızıllan N *et al.* Immunoglobulin abnormalities and effects of enzyme replacement therapy in children with Gaucher disease. *Pediatr. Blood Cancer* 56, 664–666 (2011).
- 55 Brautbar A, Elstein D, Pines G *et al.* Effect of enzyme replacement therapy on gammopathies in Gaucher disease. *Blood Cells Mol. Dis.* 32, 214–217 (2004).
- 56 Taddei TH, Kacena KA, Yang M *et al.* The underrecognized progressive nature of N370S Gaucher disease and assessment of cancer risk in 403 patients. *Am. J. Hematol.* 84, 208–214 (2009).
- 57 Mistry PK, Liu J, Yang M *et al.* Glucocerebrosidase gene-deficient mouse recapitulates Gaucher disease displaying cellular and molecular dysregulation beyond

- the macrophage. *Proc. Natl Acad. Sci. USA* 107, 19473–19478 (2010).
- Describes the generation of the first Gaucher disease model that displays clinical features of type I disease.
- 58 Liu J, Halene S, Yang M *et al.* Gaucher disease gene *GBA* functions in immune regulation. *Proc. Natl Acad. Sci. USA* 109, 10018–10023 (2012).
- 59 Pandey MK, Rani R, Zhang W. Immunological cell type characterization and Th1-Th17 cytokine production in a mouse model of Gaucher disease. *Mol. Genet. Metab.* 106, 310–322 (2012).
- 60 Mori G, D'Amelio P, Faccio R *et al.* The interplay between the bone and the immune system. *Clin. Dev. Immunol.* 2013, 720504 (2013).
- One of the latest reviews of the field of osteoimmunology, reporting the latest findings about the reciprocal regulation of bone and immune cells.
- 61 Nakashima T, Hayash M, Takayanagi H. Regulation of bone resorption by osteocytes. *Clin. Calcium* 22, 685–696 (2012).
- 62 Takayanagi H. Osteoimmunology: shared mechanisms and crosstalk between the immune and bone systems. *Nat. Rev. Immunol.* 7, 292–304 (2007).
- 63 Lacey DL, Timms E, Tan HL *et al.* Osteoprotegerin ligand is a cytokine that regulates osteoclast differentiation and activation. *Cell* 93, 165–176 (1999).
- 64 Yasuda H, Shima N, Nakagawa N *et al.* Osteoclast differentiation factor is a ligand for osteoprotegerin/osteoclastogenesis-inhibitory factor and is identical to TRANCE/RANKL. *Proc. Natl Acad. Sci. USA* 95, 3597–3602 (1998).
- 65 Anderson DM, Maraskovsky E, Billingsley WL *et al.* A homologue of the TNF receptor and its ligand enhance T-cell growth and dendritic-cell function. *Nature* 390, 175–179 (1997).
- 66 Wong BR, Josien R, Lee SY *et al.* TRANCE (tumor necrosis factor [TNF]-related activation-induced cytokine), a new TNF family member predominantly expressed in T cells, is a dendritic cell-specific survival factor. *J. Exp. Med.* 186, 2075–2080 (1997).
- 67 Gori F, Hofbauer LC, Dunstan CR *et al.* The expression of osteoprotegerin and RANK ligand and the support of osteoclast formation by stromal-osteoblast lineage cells is developmentally regulated. *Endocrinology* 141, 4768–4776 (2000).
- 68 Boyle WJ, Simonet WS, Lacey DL. Osteoclast differentiation and activation. *Nature* 423, 337–342 (2003).
- 69 Simonet WS, Lacey DL, Dunstan CR *et al.* Osteoprotegerin: a novel secreted protein involved in the regulation of bone density. *Cell* 89, 309–319 (1997).
- 70 Siddappa R, Fernandes H, Liu J. The response of human mesenchymal stem cells to osteogenic signals and its impact on bone tissue engineering. *Curr. Stem Cell Res. Ther.* 2, 209–220 (2007).
- 71 Li J, Sarosi I, Yan XQ *et al.* RANK is the intrinsic hematopoietic cell surface receptor that controls osteoclastogenesis and regulation of bone mass and calcium metabolism. *Proc. Natl Acad. Sci. USA* 97, 1566–1571 (2000).
- 72 Mizuno A, Kanno T, Hoshi M *et al.* Transgenic mice overexpressing soluble osteoclast differentiation factor (sODF) exhibit severe osteoporosis. *J. Bone Miner. Metab.* 20, 337–344 (2002).
- 73 Leibbrandt A, Penninger JM. RANK/RANKL: regulators of immune responses and bone physiology. *Ann. NY Acad. Sci.* 143, 1123–1150 (2008).
- 74 Kanamaru F, Iwai H, Ikeda T *et al.* Expression of membrane-bound and soluble receptor activator of NF-kappaB ligand (RANKL) in human T cells. *Immunol. Lett.* 94, 239–246 (2004).
- 75 Nakashima T, Hayashi M, Fukunaga T. Evidence for osteocyte regulation of bone homeostasis through RANKL expression. *Nat. Med.* 17, 1231–1234 (2011).
- 76 Nakashima, T, Kobayashi Y, Yamasaki S *et al.* Protein expression and functional difference of membrane-bound and soluble receptor activator of NFkB ligand: modulation of the expression by osteotropic factors and cytokines. *Biochem. Biophys. Res. Commun.* 275, 768–775 (2000).
- 77 Kim N, Kadono Y, Takami M *et al.* Osteoclast differentiation independent of the TRANCE/RANK–TRAF6 axis. *J. Exp. Med.* 202, 589–595 (2005).
- 78 Tatsumi S, Ishii K, Amizuka N *et al.* Targeted ablation of osteocytes induces osteoporosis with defective mechanotransduction. *Cell Metab.* 5, 464–475 (2007).
- 79 Paic F, Igwe JC, Nori R. Identification of differentially expressed genes between osteoblasts and osteocytes. *Bone* 45, 682–692 (2009).
- 80 Galli C, Fu Q, Wang W *et al.* Commitment to the osteoblast lineage is not required for RANKL gene expression. *J. Biol. Chem.* 284, 12654–12662 (2009).
- 81 Corral DA, Amling M, Priemel M *et al.* Dissociation between bone resorption and bone formation in osteopenic transgenic mice. *Proc. Natl Acad. Sci. USA* 95, 13835–13840 (1998).
- 82 Lecourt S, Vanneaux V, Cras A *et al.* Bone marrow microenvironment in an *in vitro* model of Gaucher disease: consequences of glucocerebrosidase deficiency. *Stem Cells Dev.* 21, 239–248 (2012).
- 83 Mucci JM, Scian R, De Francesco PN *et al.* Induction of osteoclastogenesis in an *in vitro* model of Gaucher disease is mediated by T cells via TNF- α . *Gene* 509, 51–59 (2012).
- 84 Reed M, Baker RJ, Mehta AB *et al.* Enhanced differentiation of osteoclasts from mononuclear precursors in patients with Gaucher disease. *Blood Cells Mol. Dis.* 51, 185–194 (2013).
- Describes the induction of osteoclastogenesis observed in Gaucher disease mononuclear cells. A higher osteoclasts activity observed in Gaucher disease could explain skeletal alterations associated to this pathology.
- 85 Mucci JM, Suqueli García F, de Francesco PN *et al.* Uncoupling of osteoblast-osteoclast regulation in a chemical murine model of Gaucher disease. *Gene* 532, 186–191 (2013).
- Provides evidence that bone formation and resorption activities are affected in Gaucher disease, both contributing to reduced bone mineral density characteristic of this disorder.