



## Brief Communication

## A case of adult osteomyelitis in a Final Late Holocene hunter-gatherer population, eastern Pampa–Patagonian transition, Argentina

Gustavo Flensburg<sup>a,\*</sup>, Jorge A. Suby<sup>b</sup>, Gustavo Martínez<sup>a</sup><sup>a</sup> INCUAPA-CONICET, Facultad de Ciencias Sociales, UNICEN, Avda. del Valle 5737, Olavarría B7400JWI, Argentina<sup>b</sup> CONICET-Laboratorio de Ecología Evolutiva Humana, Departamento de Arqueología, UNICEN, Calle 508 Nro. 881, Quequén, Argentina

## ARTICLE INFO

## Article history:

Received 28 November 2012

Received in revised form 14 May 2013

Accepted 17 May 2013

## Keywords:

Osteomyelitis

Adult

Hunter-gatherer

Final Late Holocene

Eastern Pampa–Patagonian transition  
Argentina

## ABSTRACT

Osteomyelitis was frequent in prehistoric times, although its paleopathological recognition and analysis in skeletal remains is typically incomplete. Contrasting with osteomyelitis in children, in adults it is usually a subacute or chronic infection that develops secondary to an open injury. The aim of this paper is to present a case of osteomyelitis in an adult female skeleton, from a hunter-gatherer population that inhabited the eastern Pampa–Patagonian transition (Argentina) during Final Late Holocene (ca. 250 years BP). Macroscopic studies as well as biplanar radiographs and CT scans were used for diagnosis. Lamellar bone formations on the diaphysis and in the interior of the marrow cavity were recorded. Also, a lytic lesion was identified in CT images. The diagnostic procedures and the probable causes that could generate the lesions in the long bones of the lower limb are discussed. The lesions are consistent with osteomyelitis secondary to a contiguous focus of infection, possibly linked to the abscess in the maxillary bone.

© 2013 Elsevier Inc. All rights reserved.

## 1. Introduction

The study of infectious processes in skeletal remains is one of the most important sources of information about biocultural changes across time and space, in relationship to the environment (Jackson, 2000; Mitchell, 2003; Ortner, 2008; Powell, 1988). Among infectious pathologies in human bones, osteomyelitis was frequent in prehistoric times (Rogers and Waldron, 1989), although paleopathological recognition has been incompletely discussed (see Ortner, 2003, p. 195).

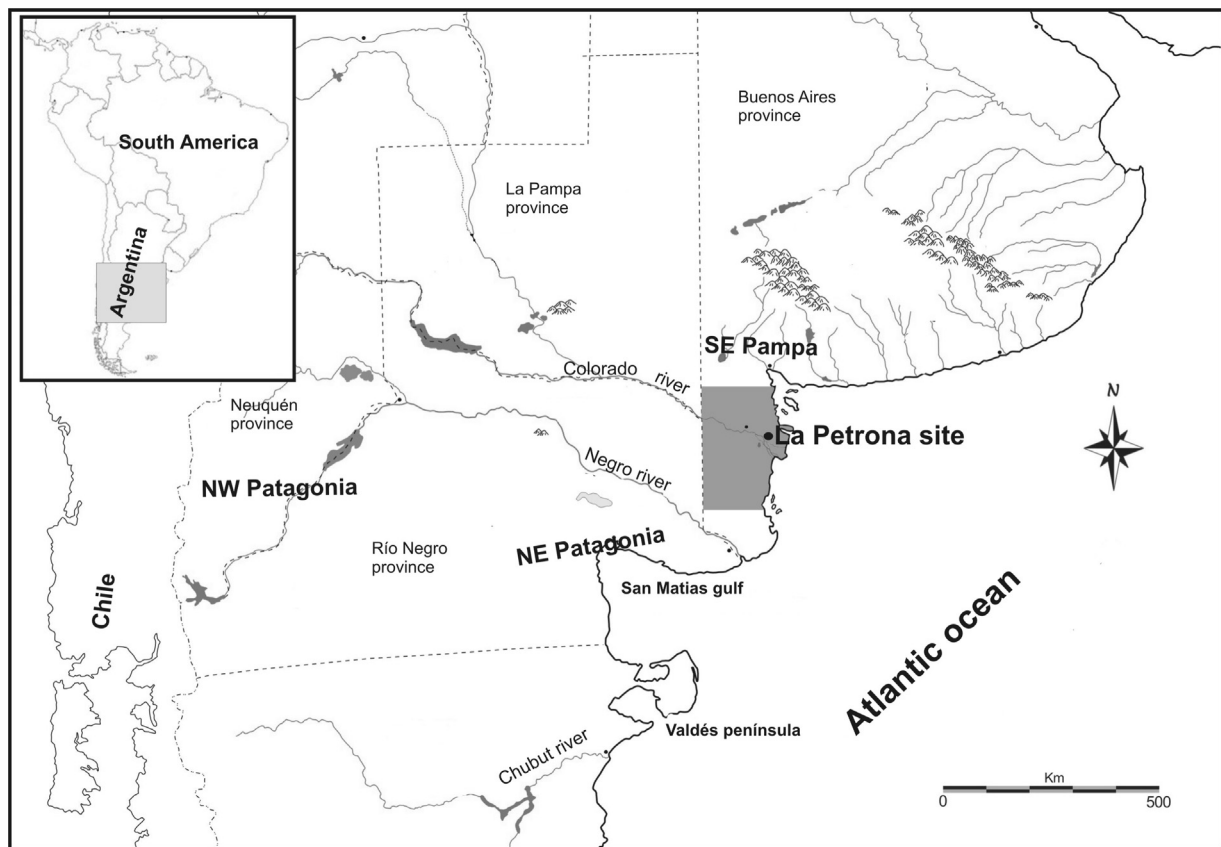
Osteomyelitis is a progressive bone infection accompanied by inflammatory destruction, necrosis and new bone formation caused by an infecting microorganism, involving one or more regions of the bone and the surrounding soft tissue (Ikpeme et al., 2010; Lew and Waldvogel, 2004). The most common infectious agent is *Staphylococcus aureus*, although many others can also be involved (Lew and Waldvogel, 1997; Sia and Berbari, 2006). According to the most frequent classification, proposed by Waldvogel et al. (1970), osseous infections can be classified as either haematogenous or secondary to a contiguous focus of infection. The former is caused by the spread of microorganisms into the bone due to, for example, urogenital infections,

enteritis, endocarditis and diabetes (Hartemann-Heurtier and Senneville, 2008; Sia and Berbari, 2006). In contrast, contiguous focus infection occurs due to bacterial invasion commonly after trauma and also through penetrating wounds (Bohndorf, 2004). Both types may be further classified as acute or chronic. Acute osteomyelitis evolves over several days or weeks, whereas chronic osteomyelitis is arbitrarily defined as a long-standing infection progressing over months or years (Lew and Waldvogel, 2004). While children develop predominantly acute osteomyelitis, often spread haematogenously, osteomyelitis in adults is usually a subacute or chronic infection that develops secondarily to an open injury in the bone and surrounding soft tissue (Mousa, 2003).

In all forms of osteomyelitis, the infective pathogen enters into the bone through a nutrient artery and is quickly spread by way of the blood vessels. While in children the periosteum lifts away from the bone, in adults this does not occur because it is more firmly attached to the cortical bone (Bohndorf, 2004; Jauregui and Senour, 1995). The pressure created by the pus in the medullary cavity and subperiosteal space restricts the blood supply to the bone, beginning the process of necrosis (sequestration) (Jauregui and Senour, 1995; Lew and Waldvogel, 1997). At the same time, osteoblast activation stimulates the periosteum, forming a structure of woven bone (involucrum) enveloping the sequestrum. Necrotic tissue may be resorbed and replaced with new bone. When this process fails, purulent cavities (cloaca) may be formed, releasing necrotic bone and pus (Bohndorf, 2004; Jauregui and Senour, 1995; Lew and Waldvogel, 1997, 2004).

\* Corresponding author. Tel.: +54 2284450331; fax: +54 2284450115.

E-mail addresses: [gflensbo@soc.unicen.edu.ar](mailto:gflensbo@soc.unicen.edu.ar), [gustavoflens@hotmail.com](mailto:gustavoflens@hotmail.com) (G. Flensburg), [jasuby@gmail.com](mailto:jasuby@gmail.com) (J.A. Suby), [gmartine@soc.unicen.edu.ar](mailto:gmartine@soc.unicen.edu.ar) (G. Martínez).



**Fig. 1.** La Petrona site in the eastern Pampa–Patagonian transition. The gray zone indicates the study area.

The diagnosis of osteomyelitis is difficult in modern cases, even with advanced clinical and imaging methods (Calhoun and Shirtliff, 2009; Hass and McAndrew, 1996; Sia and Berbari, 2006). Thus, it is not surprising that paleopathological diagnosis of osteomyelitis in skeletal remains may be even more problematic, assuming that in the absence of antibiotic therapies, prevalence of bone infections was higher than today (Rogers and Waldron, 1989; Santos and Suby, 2012). The accepted criteria for diagnosis in human bone remains include the presence of cloaca, sequestrum and involucrum (Aufderheide and Rodríguez-Martín, 1998; Ortner, 2003). However, as these bone features are not always developed in acute, subacute or even chronic stages of infections, osteomyelitis is probably underdiagnosed in paleopathological studies (Aufderheide and Rodríguez-Martín, 1998; Jackson, 2000; Ortner, 2008; Santos and Suby, 2012). Even in chronic cases, when the infection is frequently cured spontaneously or by antibiotic treatment, it can leave only slight bone reactions (Bohndorf, 2004; Hass and McAndrew, 1996). In this sense, macroscopic identifications of osteomyelitis in the absence of diagnostic bone traits, such as those mentioned above, constitutes a challenge that will be considered in this article.

Osteomyelitis in adult skeletal remains has been described in only a few cases in hunter-gatherer populations from Argentina, mainly in northern Patagonia and southeastern Pampa regions between ca. 3600 and 500 years BP (e.g. Barrientos, 1997; Della Negra and Novellino, 2005; Novellino et al., 2007), and suggested mainly by the presence of cloaca. In contrast, osteomyelitis has not been reported in skeletons from the eastern Pampa–Patagonian transition area (Fig. 1). Consequently, the aim of this paper is to present a case of adult osteomyelitis from this latter area, employing multiple diagnostic procedures.

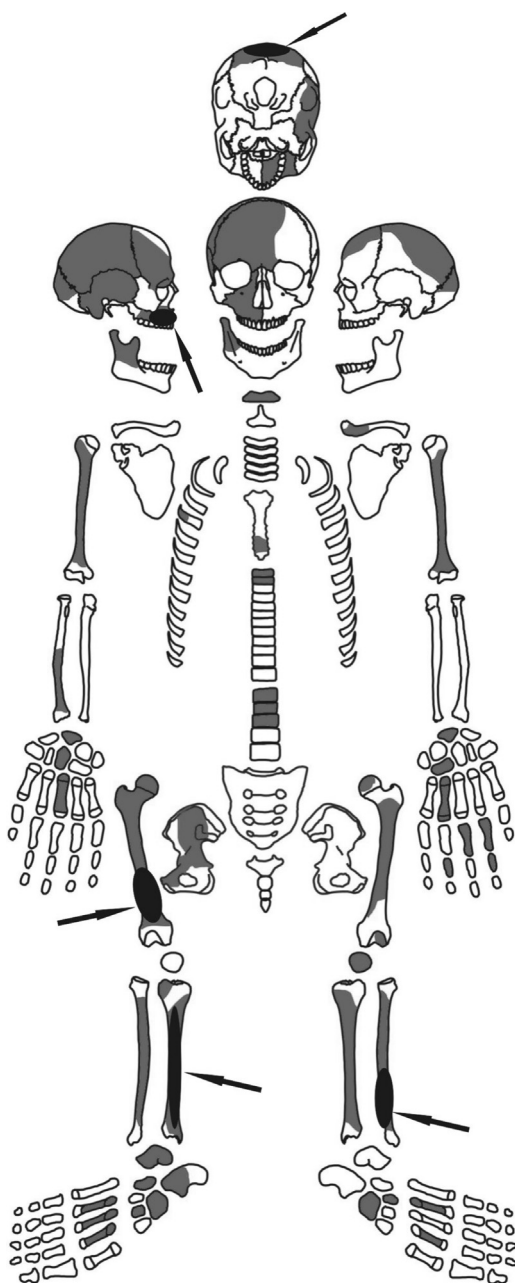
## 2. Sample and methods

The skeleton described in this study was recovered from the La Petrona site, on the lower course of the Colorado River (Fig. 1). Located in the eastern Pampa–Patagonia transitional area, enclosed in the so-called “Diagonal Arida” (Abraham de Vázquez et al., 2000), the site was continuously occupied by hunter-gatherer groups during the Final Late Holocene, ca. 800–250 years BP (Flensburg et al., 2011).

The site includes primary and secondary burials (Martínez and Figuerero Torres, 2000). The latter consist of disarticulated bones corresponding to several skeletons, sorted into funerary bundles (Flensburg et al., 2011). A minimum number of eight individuals was estimated: five adult females, two adults of indeterminate sex (>25 years of age at death), and an infant of indeterminate sex.

The skeleton studied here, denoted LP-4, was a primary burial and dated to  $248 \pm 39$   $^{14}\text{C}$  years uncal. BP (AA-70564; Martínez, 2008–2009). The individual received differential mortuary treatment, since it is the only primary burial that shows cut marks (i.e., defleshing and scraping), which indicates that soft tissue was removed before inhumation (Flensburg et al., 2011; González, 2012). The individual is a female, 35–45 years old (sensu Buikstra and Ubelaker, 1994). The remains consist of 42 bone elements, mostly of the lower limbs and the skull (Fig. 2). Bones of hands and feet were also recovered. In general, the diaphyses of long bones are well preserved, in contrast to the articular regions, which are mostly absent or poorly preserved, apparently through the action of both carnivores and roots (Flensburg et al., 2011; González, 2012).

Morphological examination of the remains was performed macroscopically and with the aid of a 10X magnification hand lens. Furthermore, biplanar radiographs and computed tomography (CT)



**Fig. 2.** Distribution of the lesions in the skeleton LP-4. White areas denote absent skeletal regions, the grey areas correspond to the recovered elements, and black areas and arrows represent the location of the recorded lesions.

scans were carried out by the Instituto Radiológico Mar del Plata (Argentina).

### 3. Results

Periosteal bone reactions were noted in 4 of 42 observable elements (9.5%). All lesions are located on the lower limbs long bones and the skull (Fig. 2). Specifically, lamellar bone formation expanded the anterior mid to distal diaphysis of the right femur (Fig. 3a). A thickening of cortical bone is observed on the lateral aspect of the distal diaphysis, visible radiographically (Fig. 4a).

Similarly, the right tibia shows a remodeled lamellar bone formation affecting the proximal diaphysis. As a result of the new bone apposition the diaphyseal width at the proximal end increased (Fig. 3b). Postmortem fragmentation of the proximal diaphysis

revealed slight new bone formation on the interior of the marrow cavity (Fig. 3b). A radiograph of this bone shows a diffuse area of the cortex in the medial aspect of the proximal portion of the diaphysis (Fig. 4b), with a slightly lytic surface. This bone alteration – accompanied by a thickening of cortical bone – is clearly detectable throughout a coronal CT image (Fig. 4c). A radiograph (Fig. 4d) and coronal CT image (Fig. 4e) of the left tibia show the thickening of cortical bone on the lateral end of the diaphysis, which was not observed macroscopically.

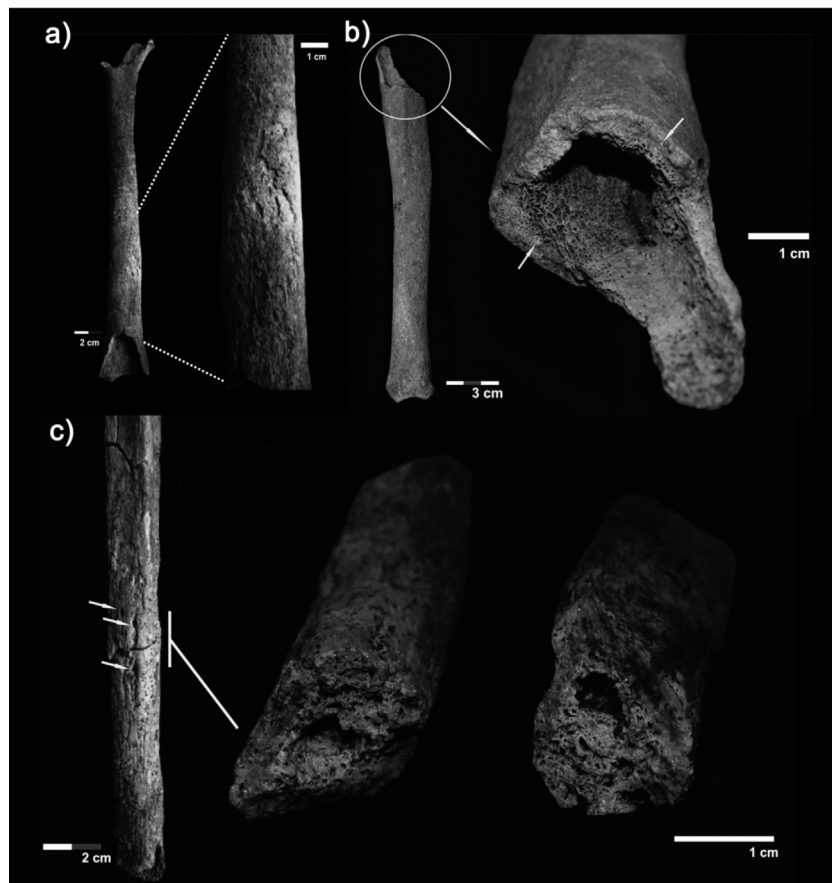
The left fibula shows sclerotic lamellar and woven bone formation in the mid-distal diaphysis. The presence of a small pitted area was recorded, which could have been associated with cloacae (Fig. 3c). Postmortem fragmentation of the diaphysis revealed new bone formation within the marrow cavity, invading the medullary space. Both the radiograph (Fig. 4f) and the CT image (Fig. 4g) show the new bone within the marrow cavity.

Additionally, the skeleton presents periosteal woven bone on the right malar (Fig. 5a). A dislocation of the right superior first molar and a lingual abscess were also observed (Fig. 5b). Finally, the skull shows five remodeled erosive lesions of ca. 2 cm of diameter each (Fig. 6), two on the right parietal and three on the left parietal. The skull showed evidence of artificial cranial vault deformation, characterized by the expansion of the frontal bone and that compression in lambda. However, the lesions do not appear to correspond to the pressure points associated with this cultural modification. These cranial vault lesions appear less compatible with a primary infectious that being the result of blunt force trauma (Flensburg, 2012).

### 4. Discussion and conclusions

The current diagnosis of osteomyelitis both in living children and adults is frequently complex, generally based on the combination of clinical exams, radiographs, tomographic images, and evaluations of bone and soft tissue changes over time (Hass and McAndrew, 1996; Resnick and Niwayama, 1995). The impossibility of obtaining all this clinical information from archaeological skeletal remains presents additional challenges. The limited nature of bone responses to the abundant number and types of bacteria, viruses, parasites and fungi are also complicating factors, along with other problems inherent in differential diagnoses. In addition, high mortality in early stages of growth and development due to many infectious diseases prior to the development of antibiotics (Ciampolini and Harding, 2000) could limit the expression of bone changes and consequently reduce archaeological visibility. Extensive lesions like cloaca are not always present in osteomyelitis, which could therefore be underdiagnosed in archaeological skeletal remains. However, bone destruction, periosteal bone formation and lytic areas surrounded by reactive sclerosis evident in radiographic images, such as the features observed in this case study, are usually interpreted as osteomyelitis (Harik and Smeltzer, 2010; Mellado Santos, 2006; Pineda et al., 2009; Santos and Suby, 2012).

Haematogenous osteomyelitis in adults is rare since the long bone microvasculature does not favor bacterial spread (Bohndorf, 2004). When it does occur, it infrequently involves the appendicular skeleton; instead vertebrae, sternoclavicular and sacroiliac joints are affected (Lew and Waldvogel, 2004). For the adult individual described here, secondary osteomyelitis is more likely (Hass and McAndrew, 1996). Diaphyses of long bones are most commonly affected in secondary osteomyelitis, while the epiphyses and adjacent joints are not usually damaged because the growth plates are closed (Calhoun and Manring, 2005; Bohndorf, 2004). The skeleton presented here shows bone lesions mainly affecting the diaphyses of the lower limb long bones, although it was not possible to evaluate the presence of lesions in the joints, since these bone portions

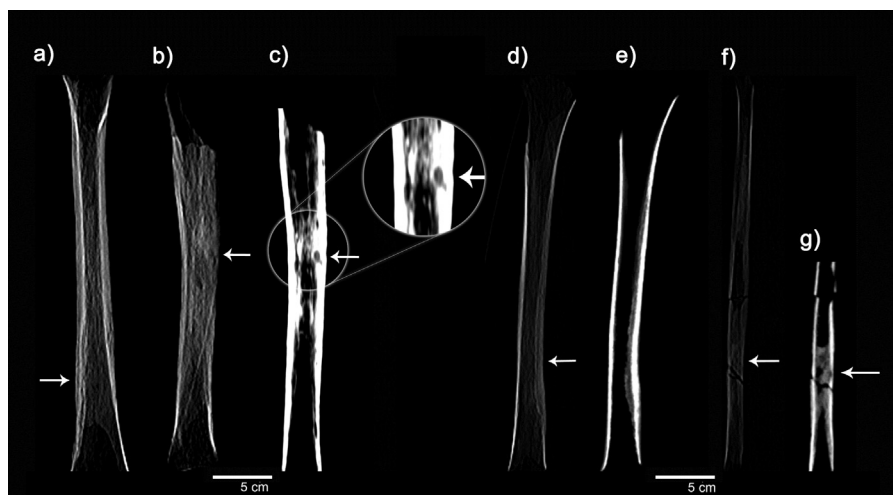


**Fig. 3.** Lesions in lower limbs: (a) lamellar bone formation surrounding the distal shaft on the right femur, (b) remodeled lamellar bone formation on the proximal diaphysis of the right tibia, and (c) sclerotic lamellar and woven bone formation on medial and distal diaphysis of the left fibula. Arrows indicate the possible cloaca in the cortical surface.

were absent. The anatomical distribution of lesions suggests that a contiguous focus of infection is the most probable cause.

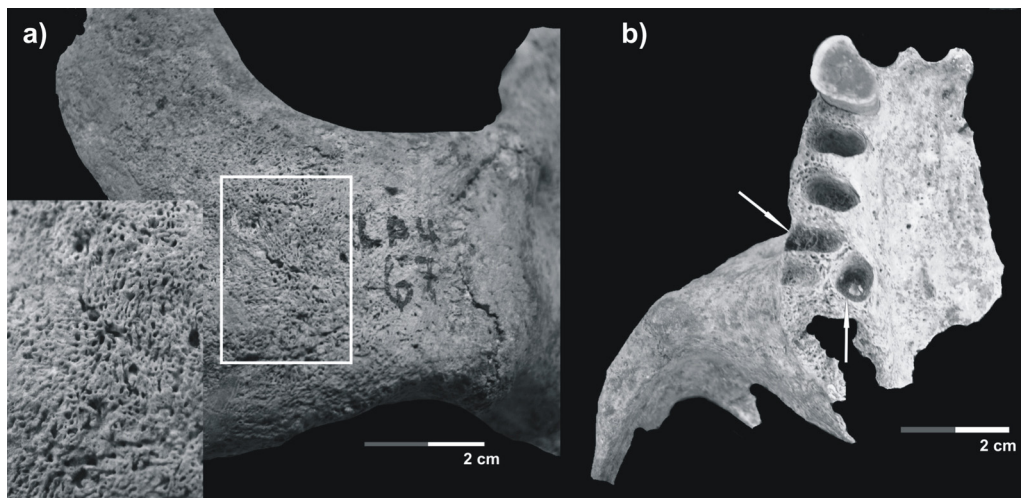
Although it is difficult to propose a specific cause for the lesions, some possibilities can be suggested, even though some anatomical parts are missing due to differential preservation. First, a traumatic event could be responsible for an infective agent affecting bone or soft tissue and ensuing infection. However, neither the macroscopic survey of bone surfaces nor the analyses

provided by radiographs and CT images revealed traumatic lesions in the post-cranial skeleton. Second, the inferred traumatic injuries to the skull do not suggest the entrance of an infective agent into the bone. Third, the observed lesions in this skeleton are not compatible with other diseases commonly invoked as part of differential diagnoses for osteomyelitis, principally rheumatoid arthritis, syphilis, tuberculosis and benign bone neoplasias (Aufderheide and Rodríguez-Martín, 1998). Moreover, diabetes



**Fig. 4.** (a) Radiograph of the right femur; (b and c) radiograph and CT image of the right tibia, respectively; (d and e) radiograph and CT image of the left tibia, respectively; (f and g) radiograph and CT image of the left fibula, respectively. White arrows indicate lytic area, cloaca and thickening of cortical bone.





**Fig. 5.** (a) Woven bone formation on right malar; (b) dislocation of the right superior first molar, and lingual abscess.

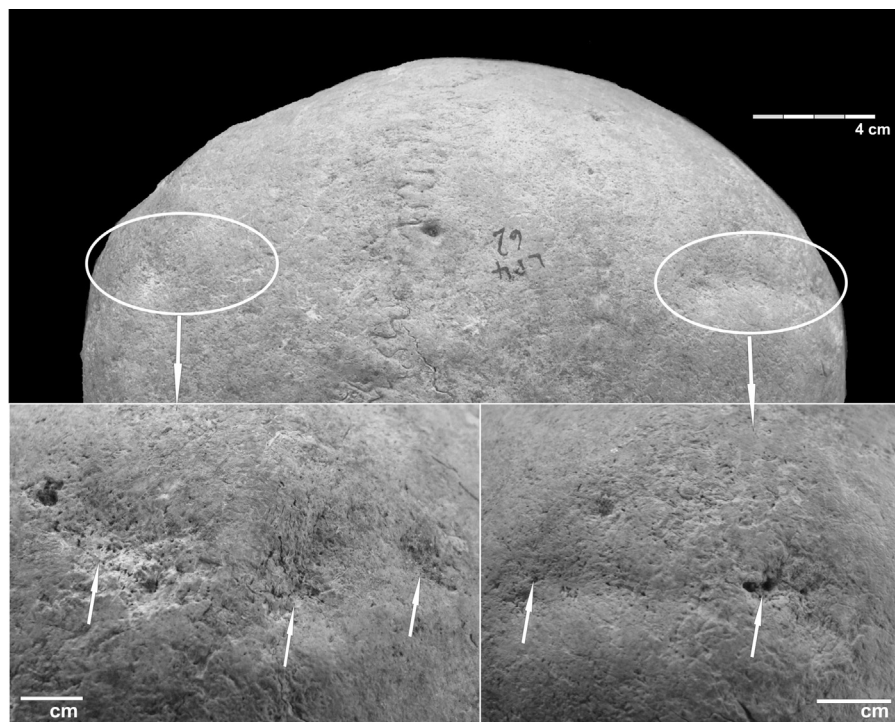
could not be considered since only the bones of the feet are affected (Hartemann-Heurtier and Senneville, 2008; Henke et al., 2005). Finally, the abscess in the maxillary bone is the only recorded lesion that could be associated with the entrance of an infective agent.

It has been suggested that an individual who has had osteomyelitis during childhood can manifest it again in adulthood due to a suppression of the immune response (Calhoun and Manring, 2005; Gaujoux-Viala et al., 2011). Some of the lesions described here seem to have been active at the time of death, since woven bone on the left fibula is present and lytic areas on the right tibia are also observed in CT images. Thus, an alternative hypothesis could be that haematogenous osteomyelitis developed during childhood and was reactivated during adulthood.

As has been frequently mentioned (Buikstra and Ubelaker, 1994; Mays, 2008; Waldron, 2009), radiography is an important tool in diagnosis of ancient bone pathologies. In this case, it facilitates

describing cortical thickening of the femoral and tibial diaphyses. However, only a lytic lesion affecting the right tibia was clearly detected in coronal CT views. Radiographic and CT images are appropriate methodologies since they significantly increase the diagnostic rigor in those cases where cortical bone is affected and cloaca, involucra and sequestra are not present.

From a bioarchaeological point of view, this case study is important for exploring health-related evidence of hunter-gatherer populations of the eastern Pampa–Patagonian transition during the Late Holocene, since this is the only case of osteomyelitis reported from this area, possibly linked to the period of Native-European contact (Flensburg, 2012). No other human bone recovered from the lower stream of the Colorado River valley showed evidences of osteomyelitis. However, it cannot be discounted that other individuals may have suffered from diseases that cannot be diagnosed in the skeletal record due to an immune response by the host to



**Fig. 6.** Remodeled erosive traumatic lesions in the posterior view of both parietal bones.

the infection or to the early death of the individual (Wood et al., 1992). Furthermore, post-depositional processes could have led to differential preservation of fragile, affected anatomical units, thus biasing the study of bone lesions (Waldron, 1994; Stodder, 2008).

In an extra-regional comparative analysis, osteomyelitis was recorded in pre-contact times in the northwest (Della Negra and Novellino, 2005) and northeast Patagonia (Novellino et al., 2007) and southeast Pampa (Barrientos, 1997). As such, the presence of osteomyelitis as reported and discussed here is important for understanding the temporal and spatial distribution of this type of disease in hunter-gatherer populations from the Pampa and Patagonia regions, to date scarcely reported for these groups.

## Acknowledgments

Research was supported by ANCyPT (PICT-264/07) and CONICET (PIP-338/10). Thanks to INCUAPA-CONICET (Facultad de Ciencias Sociales, Universidad Nacional del Centro de la Provincia de Buenos Aires) for providing institutional support for this research. We would also like to thank Dr. Ana Luisa Santos for her comments on the manuscript and to Sandra Baliño, Ana Paula Alcaráz, Florencia Santos Valero and Benjamin Alberti who helped translate the paper. The Instituto Radiográfico de Mar del Plata obtained radiographic and tomographic images for differential diagnosis. We thank three anonymous reviewers for comments that improved the paper substantially.

## References

- Abraham de Vázquez, E., Garleff, K., Liebricht, H., Reigaráz, A., Schäbitz, F., Squeo, F., Stingl, H., Veit, H., Villagrán, C., 2000. Geomorphology and Paleogeology of the Arid Diagonal in Southern South America. *Geodesy, Geomorphology and Soil Science*. Sonderheft ZAG, pp. 55–61.
- Aufderheide, A., Rodríguez-Martín, C., 1998. *The Cambridge Encyclopedia of Human Paleopathology*. Cambridge University Press, Cambridge.
- Barrientos, G., 1997. Nutrición y dieta de las poblaciones aborígenes prehispánicas del sudeste de la Región Pampeana. Facultad de Ciencias Naturales y Museo, Universidad Nacional de La Plata, La Plata (doctoral thesis unpublished).
- Bohndorf, K., 2004. Infection of the appendicular skeleton. *European Radiology* 14, 53–63.
- Buikstra, J., Ubelaker, D., 1994. Standards for data collection from human skeletal remains. In: *Arkansas Archaeological Survey Research Series No. 44*, Arkansas.
- Calhoun, J.H., Manring, M.M., 2005. Adult osteomyelitis. *Infectious Disease Clinics of North America* 19, 765–786.
- Calhoun, J.H., Shirliff, M., 2009. Osteomyelitis of the long bones. *Seminars in Plastic Surgery* 23, 59–72.
- Ciampolini, J., Harding, K.G., 2000. Pathophysiology of chronic bacterial osteomyelitis. Why do antibiotics fail so often? *Postgraduate Medical Journal* 76, 479–483.
- Della Negra, C., Novellino, P., 2005. Aquihuecú: un cementerio Arqueológico, en el norte de la Patagonia, valle del Curi Leuvú, Neuquén, Argentina. *Magallania* 33, 165–172.
- Flensburg, G., 2012. Análisis paleopatológico en el curso inferior del río Colorado (Pcia. De Buenos Aires). Exploración y evaluación del estado de salud de sociedades cazadoras-recolectoras en el Holoceno tardío. Facultad de Ciencias Sociales, Universidad Nacional del Centro de la Provincia de Buenos Aires, Olavarría (doctoral thesis unpublished).
- Flensburg, G., Martínez, G., González, M., Bayala, P., 2011. Revisión de los restos óseos humanos del sitio La Petrona (transición pampeano-patagónica oriental), Argentina. *Magallania* 39 (1), 5–14.
- Gaujoux-Viala, C., Zeller, V., Leclerc, P., Chicheportiche, V., Mamoudy, P., Desplaces, N., Ziza, J.M., 2011. Osteomyelitis in adults: an underrecognized clinical entity in immunocompetent host. A report of six cases. *Joint Bone Spine* 78, 75–79.
- González, M., 2012. Procesos de Formación en el Registro Bioarqueológico de la subregión Pampa-Húmeda y Área Ecotonal Pampa-Patagonia. Facultad de Ciencias Sociales, Universidad Nacional del Centro de la Provincia de Buenos Aires, Olavarría (doctoral thesis unpublished).
- Harik, N.S., Smeltzer, M.S., 2010. Management of acute hematogenous osteomyelitis in children. *Expert Review of Anti-Infective Therapy* 8, 175–181.
- Hartemann-Heurtier, A., Senneville, E., 2008. Diabetic foot osteomyelitis. *Diabetes & Metabolism* 34, 87–95.
- Hass, D.W., McAndrew, M.P., 1996. Bacterial osteomyelitis in adults: evolving considerations in diagnosis and treatment. *American Journal of Medicine* 101, 550–561.
- Henke, P.K., Blackburn, S.A., Wainess, R.W., 2005. Osteomyelitis of the foot and toe in adults is a surgical disease: conservative management worsens lower extremity salvage. *Annals of Surgery* 241 (6), 885–892.
- Ikpeme, I.A., Ngim, N.E., Ikpeme, A.A., 2010. Diagnosis and treatment of pyogenic bone infections. *African Health Sciences* 10, 82–88.
- Jackson, F.L.C., 2000. Human adaptations to infectious disease. In: Stinson, S., Bocci, B., Huss-Ashmore, R., O'Rourke, D. (Eds.), *Human Biology: An Evolutionary and Biocultural Perspective*. Wiley-Liss Inc., New York, pp. 273–293.
- Jauregui, L.E., Senour, C.L., 1995. Diagnosis and management of bone infections. In: Jauregui, L.E. (Ed.), *Infectious Disease and Therapy*. New York, Marcel Dekker, pp. 37–108.
- Lew, D.P., Waldvogel, F.A., 1997. Osteomyelitis. *New England Journal of Medicine* 336, 999–1007.
- Lew, D.P., Waldvogel, F.A., 2004. Osteomyelitis, vol. 364., pp. 369–379, [www.thelancet.com](http://www.thelancet.com)
- Martínez, G., 2008–2009. Arqueología del curso inferior del río Colorado: estado actual del conocimiento e implicaciones para la dinámica poblacional de cazadores-recolectores pampeanos-patagónicos. *Cazadores-Recolectores del Cono Sur. Revista de Arqueología* 2, 73–94.
- Martínez, G., Figuerero Torres, M.J., 2000. Sitio arqueológico La Petrona (partido de Villarino, provincia de Buenos Aires): análisis de las modalidades de entierro en el área sur pampeana. In: *Relaciones de la Sociedad Argentina de Antropología XXV*, pp. 227–247.
- Mays, S., 2008. Radiography and allied techniques in the paleopathology of skeletal remains. In: Mays, S., Pinhasi, R. (Eds.), *Advances on Human Paleopathology*. John Wiley & Sons, Ltd., West Sussex, pp. 77–100.
- Mellado Santos, J.M., 2006. Diagnostic imaging of pediatric hematogenous osteomyelitis: lessons learned from a multi-modality approach. *European Radiology* 16, 2109–2119.
- Mitchell, P., 2003. The archaeological study of epidemic and infectious disease. *World Archaeology* 35 (2), 171–179.
- Mousa, H.A., 2003. Bone infection. *Eastern Mediterranean Health Journal* 9, Available from WHO (serial online).
- Novellino, P., Gómez Otero, J., Dahinten, S., 2007. Bioarqueología de restos humanos del nordeste de la provincia de Chubut: primeros resultados. In: *Resúmenes ampliados del XVI Congreso Nacional de Arqueología Argentina*. Tomo III, Universidad Nacional de Jujuy. Facultad de Humanidades Ciencias Sociales, pp. 417–420.
- Ortner, D.J., 2003. *Identification of Pathological Conditions in Human Skeletal Remains*. Academic Press, Florida.
- Ortner, D.J., 2008. Differential diagnosis of skeletal lesions in infectious disease. In: Mays, S., Pinhasi, R. (Eds.), *Advances on Human Paleopathology*. John Wiley & Sons, Ltd., West Sussex, pp. 191–214.
- Pineda, C., Espinosa, R., Pena, A., 2009. Radiographic imaging in osteomyelitis: the role of plain radiography, computed tomography, ultrasonography, magnetic resonance imaging, and scintigraphy. *Seminars in Plastic Surgery* 23, 80–89.
- Powell, M.L., 1988. *Status and Health in Prehistory*. Smithsonian Institution Press, Washington, DC.
- Resnick, D., Niwayama, G., 1995. Osteomyelitis, septic arthritis and soft tissue infection: mechanisms and situations. In: Resnick, D. (Ed.), *Diagnosis of Bone and Joint Disorders*. 3rd ed. WB Saunders, Philadelphia, pp. 2325–2418.
- Rogers, J., Waldron, T., 1989. Infections in palaeopathology: the basis of classification according to most probable cause. *Journal of Archaeological Science* 16, 611–625.
- Santos, A.L., Suby, J.A., 2012. Skeletal and surgical evidence for acute osteomyelitis in non-adult individuals. *International Journal of Osteoarchaeology*, <http://dx.doi.org/10.1002/oa.2276>.
- Sia, I.G., Berbari, E.F., 2006. Osteomyelitis. *Best Practice & Research Clinical Rheumatology* 20 (6), 1065–1081.
- Stodder, A.L.W., 2008. Taphonomy and the nature of archaeological assemblages. In: Katzberg, M.A., Saunders, S.R. (Eds.), *Biological Anthropology of the Human Skeleton*. Wiley-Liss Inc., New York, pp. 71–114.
- Waldvogel, F.A., Medoff, G., Swartz, M.N., 1970. Osteomyelitis: a review of clinical features, therapeutic considerations and unusual aspects: 3. Osteomyelitis associated with vascular insufficiency. *New England Journal of Medicine* 282 (4), 316–322.
- Waldron, T., 1994. *Counting the Dead: The Epidemiology of Skeletal Populations*. John Wiley & Sons, Chichester.
- Waldron, T., 2009. *Paleopathology*. Cambridge University Press, New York.
- Wood, J.W., Milner, G.R., Harpending, H.C., Weiss, K.M., 1992. The osteological paradox. *Current Anthropology* 33, 343–370.