

AGE-INDEPENDENT OSTEOPATHOLOGY IN SKELETONS OF A SOUTH AMERICAN CERVID, THE PATAGONIAN HUEMUL (*HIPPOCAMELUS BISULCUS*)

Werner T. Flueck^{1,2,4} and Jo Anne M. Smith-Flueck³

¹ National Research Council (CONICET), C.C. 176, 8400 Bariloche, Argentina

² Swiss Tropical Institute, CH-4002 Basel, Switzerland

³ Instituto de Análisis de Recursos Naturales, Universidad Atlántida, 7600 Mar del Plata, Argentina

⁴ Corresponding author (email:wtf@deerlab.org)

ABSTRACT: The huemul (*Hippocamelus bisulcus*), an endemic Patagonian deer, has been endangered for decades. Although conservation in Argentina has been directed at the 350–600 remaining huemul, the population has not recovered. In initial studies on the potential effects of diseases on huemul population dynamics, skeletal remains collected between 1993 and 2007 in the Andes (41–45°S, 71.5–72°W) were examined macroscopically for osteopathologic changes. Bones from six huemul were free of lesions, findings were inconclusive in 13 huemul with less than three bones, and osteopathologic processes were detected in 13 adults. Considering the limited remains/case, the prevalence of osteopathy (52%) among adults probably is conservative; 63% showed mandibular, 100% maxillary, and 78% appendicular lesions. Although predation represented the actual cause of death, the observed skeletal lesions would affect predator avoidance, possibly explaining the low average adult age (3.1 yr) and lack of population recovery. Compared with other studies in ungulates, huemul were affected at a younger age, and they had more severe pathologic changes. Due to the chronic nature of disease, low huemul population density, physiognomy, and spatiotemporal pattern of lesions, we discard senescence; gender; fulminating infections; congenital anomalies; metabolic, endocrine, genetic, or neurologic disorders; parasitism or marasmus; and fluorosis as primary etiologic factors. We hypothesize that generalized secondary chronic alveolar osteomyelitis and osteoarthritis in huemul is related to the nutritional ecology of these animals. Selenium deficiency, which impairs bone metabolism and causes periodontitis in ruminants, occurs in the region and it is more prevalent at high altitudes. Traditional winter grounds at low elevations, sometimes far from high mountains, have been converted to livestock production, which has eliminated migratory behavior and keeps huemul in remote high-elevation refuges. Although this descriptive study contributes to huemul conservation, additional approaches are needed to investigate the etiology of this osteopathy and to close other gaps in knowledge on biology and ecology of huemul.

Key words: Arthritis, chronic alveolar osteomyelitis, *Hippocamelus bisulcus*, huemul, lumpy jaw, osteopathology, periodontitis.

INTRODUCTION

The Patagonian huemul (*Hippocamelus bisulcus*), a cervid endemic to the Southern Cone of Latin America, has been considered endangered for several decades (Diaz and Smith-Flueck, 2000). Habitat conditions for the species include wet temperate rain forests to the west, and, due to the Andean Mountains' rain shadow, drier forests and grasslands to the east. The latter habitat types occur mainly in Argentina, and they are the focus of this report. Huemul numbers and area of occupancy likely began to decline after the increase in numbers of the pre-Columbian tribes, and again after 1536 with arrival of

the Spaniards, who then introduced domestic livestock, horses, and firearms to this part of the continent. Native people then adopted an equestrian lifestyle, which improved hunting efficiency and allowed them to dominate the regional economy for the next 300 years. Subdued in 1881, their territories opened up to frontiersmen, colonists, and explorers. The earliest accounts about huemul from interior Patagonia thus described a landscape that had been modified for several hundred years. Diaz (1993) left no doubt that explorers of the late 19th century were describing the last occurrences of huemul far east of the Andes. Even then, in the Andean foothills more westerly,

they were generally already considered rare. Later accounts of huemul came exclusively from interior Andean mountain areas where seasonal climatic extremes, steep topography, and closed vegetation delayed permanent human colonization. Scientifically oriented interest in the Argentine huemul started in the mid-1980s, beginning with an inventory of remaining subpopulations; these efforts were reviewed in Diaz and Smith-Flueck (2000). Conservation efforts have been directed at the estimated 350–600 animals remaining in Argentina, most of which are found outside of protected areas. These efforts, though, have not resulted in any documented recovery; instead, subpopulations have vanished, even in protected areas.

Securing reliable data is difficult on a species so reduced in numbers and occurring mainly in remote refuges. Thus, as noted by Smith-Flueck and Flueck (2001b) who reported the impact from predation in relation to sex and age classes based on surveyed huemul carcasses, the effect of diseases on population dynamics has never been studied in huemul. The knowledge base on huemul is rudimentary, and a CrossSearch of ISI Web-of-Knowledge (<http://isiknowledge.com>) and 17 external databases (1945–2006) listed 16 entries on *H. bisulcus*, with only nine original studies (Flueck and Smith-Flueck, 2006a). Given the lack of knowledge on the role of disease in reduced huemul populations, the aim of this study was to evaluate the potential of disease to contribute to the species' morbidity. Specifically, skeletal remains of huemul were examined to provide essential baseline data on bone diseases.

MATERIALS AND METHODS

The study area comprises part of the eastern Andean Mountain district (41–45°S, 71.5–72°W), which phytogeographically belongs to the subantarctic province, and it is characterized by mature and dense forests primarily consisting of lenga beech trees (*Nothofagus*

pumilio), with the understory predominated by small shrubs such as *Maytenus disticha*, *Gaultheria mucronata*, *Myoschilos oblongum*, and *Berberis serrata-dentata* (Smith-Flueck and Flueck, 1997, 2001b). The mean annual precipitation is 100–200 cm; however, there are large annual and seasonal variations among localities. The mean temperature during June and August varies between –4 C and –2 C, with mean precipitation between 300 mm and 400 mm, principally as snow. Elevations in the study area range from about 900 m to 2,000 m.

We collected huemul skeletal remains opportunistically between 1993 and 2007. Upon finding signs of a dead ungulate, a circular area of approximately 50 m was searched intensely, and all remains were collected for later identification and inspection for macroscopic lesions. Additional samples collected by others also were inspected. Sex was determined from the physiognomy of pelvis, sacrum, axis, frontals, and from comparative morphometry because the huemul is dimorphic (Smith-Flueck, 2003). Adults were aged by analysis of cementum annuli in incisors or dental wear. Ages of some males also were determined by comparing the dimensions of the pedicels to males whose age had been determined using their teeth (Smith-Flueck and Flueck, 2001b). Age classes used were fawns and adults based on the condition of the epiphyseal plate, size of long bones, and hoof physiognomy (Smith-Flueck, 2003; Flueck and Smith-Flueck, 2005).

RESULTS

Remains of 32 individuals, found at elevations from 930 m to 1,200 m, were inspected. The average age (without fawns, $n=7$) was 3.1 yr (range 1.5–5.5 yr, $SD=1.2$, $n=20$). Fairly complete skeletons of three fawns and three adults were considered to be free of bone lesions, although one adult had no skull parts. Animals represented by less than three bones (nine adults and four fawns), all without lesions, could not be conclusively determined to be free from osteopathy, because positive individuals frequently had skeletal portions unaffected by disease. These nine adults and four fawns thus might have suffered from lesions in other skeletal parts. The remaining 13 cases had clear signs of osteopathologic

TABLE 1. Summary of the major osteopathologic lesions in huemul (sample size in parentheses).

| | Female (4) | Male (8) | Unknown (1) |
|--|------------|----------|-------------|
| Eroded maxillary alveoli | 2 | 6 | |
| Perforated buccal margin of maxillary bone | 1 | 4 | |
| Reduced maxillary bone exhibiting teeth roots | 3 | 4 | |
| Eroded mandibular alveoli | 1 | 3 | |
| Reduced mandibular bone exhibiting teeth roots | 2 | 2 | |
| Perforated mandibular body | 2 | 3 | |
| Exostoses on mandible | | 1 | |
| Thickening of mandibular body | 1 | 2 | |
| Increasingly convex ventral margin of mandible | 2 | 2 | |
| Crystalline deposits on tooth roots | 2 | 4 | |
| Eroded distal articulation of humeral bone | | 2 | |
| Exostoses or remodeling on metacarpal bone | | 2 | |
| Exostoses on tibial bone | 1 | | 1 |
| Exostoses or remodeling on metatarsal bone | | 1 | |
| Deformed hoof or phalanges | | 2 | |
| Exostoses on vertebra | 1 | | |

processes (Table 1). Among diseased animals that had mandibles ($n=8$), 63% had mandibular lesions, whereas maxillary bones of all diseased animals had lesions ($n=9$). The only animal with healthy maxillary bones was also free of other bone lesions. Among diseased animals that had some appendicular material ($n=9$), 78% had lesions.

Description of main lesions

Maxillary lesions included enlarged dental alveoli from osteolytic processes, creating open spaces up to 3.5 mm between the alveolar margin and the marginal root of molars and premolars (Fig. 1c; case 1, 3- to 4-yr-old male with antlers shed; case 6, 2.5-yr-old male; case 7, 4.5-yr-old female; case 8, 3.5-yr-old male; case 9, 2.5-yr-old male; case 10, 3- to 4-yr-old female; case 11, 4.5-yr-old male; case 13, 4- to 5-yr-old male). Another typical lesion was bone resorption on the buccal side exposing roots of teeth partially or completely to the apex (Fig. 1d, case 3, 3.5-yr-old female; cases 6, 7, 8, 9, 10, and 13). The root apices often were club shaped from crystalline deposits, at times 8 mm across (Fig. 1a), or they were eroded away (cases 7, 8, and 11). Moreover, the buccal side of the maxillary bone

showed perforation from lytic processes indicative of periapical abscesses, up to 6×8 mm, at the level of root apices of molars and premolars (Fig. 1a, b; cases 8, 9, 10, 11, and 13).

Mandibular lesions included enlarged dental alveoli from osteolytic processes, creating open spaces up to several millimeters between the alveolar margin and the marginal root of molars and premolars (cases 7, 10, and 13 and case 12, 5.5-yr-old male). Continued osteolytic processes in the periapical cystic cavity resulted in large perforations in the mandibular wall on buccal and lingual sides (Fig. 2a; cases 7, 8, 10, 12, and 13). Case 13 had vertical bone loss of the lingual alveolar margin at M3 taking on a U-shape, because no bone matrix remained at the margin and completely exposed molar roots. Furthermore, the spongy bone from remodeling ventral to the perforation had a pathologic greenstick fracture such that the mandibular height was reduced by approximately 70% (Fig. 2d). The root apices of molars and premolars were frequently club shaped from crystalline deposits (possibly hypercementosis; cases 7, 8, 10, 12, and 13). Tissue reaction in the mandible of case 12 resulted in apparent lysis of the M2 tooth, reducing it to an amorphous structure;

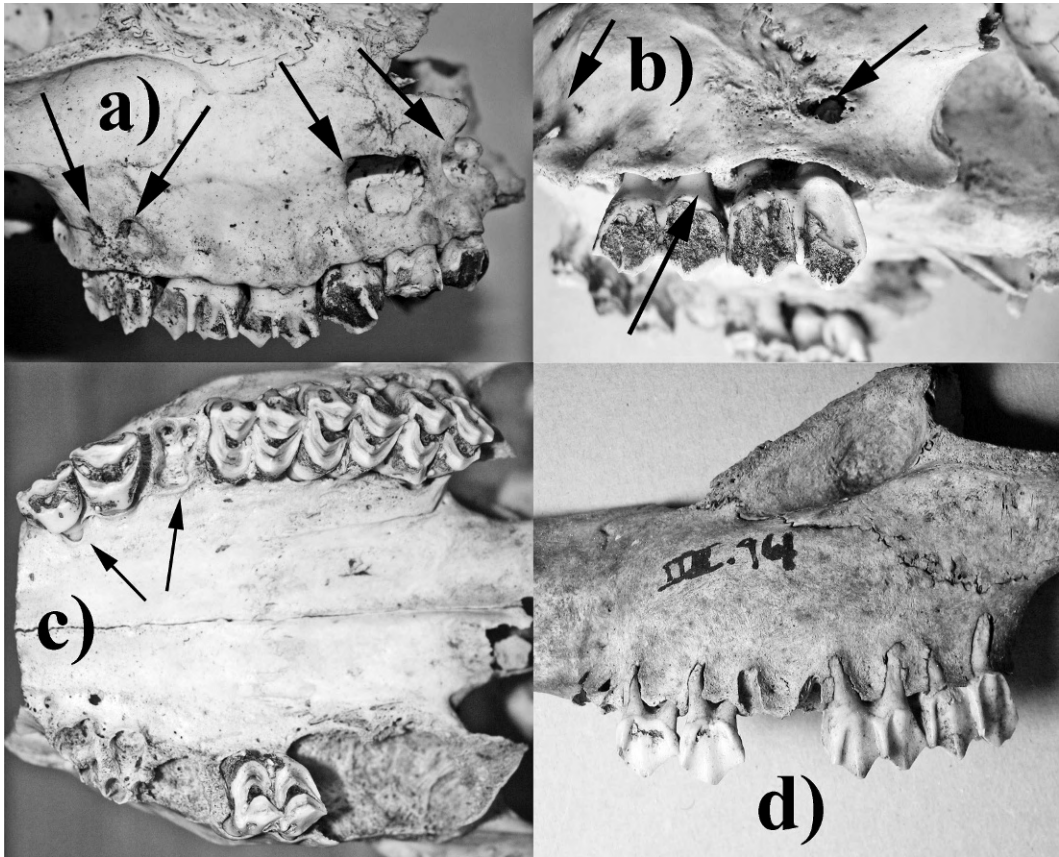


FIGURE 1. (a) Perforations (arrows) on right buccal side of maxillary bone, exposing root apices of premolar and molar teeth (4.5-yr-old male). (b) Perforations (upper arrows) on left maxillary buccal side exposing root apices, and bone resorption at the alveolar margin (lower arrow) exposing the marginal parts of the roots (3.5-yr-old male). (c) Eroded dental alveoli on the right maxillary bone with all teeth except M1 missing, and bone resorption at the left labial alveolar margin (arrows) (4- to 5-yr-old male). (d) Exposed roots of maxillary teeth from generalized erosion and resorption of bone resulting in enlarged dental alveoli (2.5-yr-old male).

and M3 had broken in half longitudinally, possibly from misalignment (Fig. 2b), as also occurred in case 13, with a nearly 90% rotation of P4 (Fig. 2d). Inflammatory reactions and active bone reformation were evidenced by intensified vascularization resulting in an increasingly convex shape of the ventral margin and nearly doubling the mandibular body width (Fig. 2a, b, c; cases 7, 10, 12, and 13). The angular processes of both mandibles in case 8 showed osteopathologic changes involving resorption and exostoses, possibly from enthesitis at the insertion of the occipito-mandibular muscle. Case 13 also

had distinctly different physiognomy of the two mandibular angles and ramus (Fig. 2d).

Appendicular diseases included subchondral cystic lesions in the lateral humeral condyle, up to 2 mm deep, in the distal articulation of the right humeral bone (Fig. 3, case 1). Case 2 (unknown sex, 15–20 mo old) had osteophytes formation at the chondro-osseous margins of the tarsocrural joint in both tibial bones. Case 4 (female, 15–20 mo old) showed roughened exostoses on the surface on the left (but not the right) tibial bone, which was more pronounced toward the proxi-

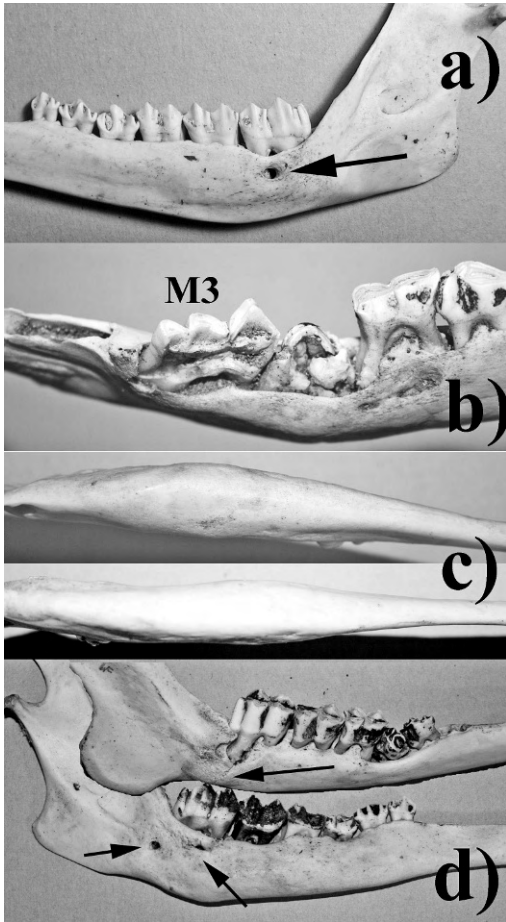


FIGURE 2. (a) Perforation on lingual side exposing roots of mandibular teeth (arrow) and convex shape of the right mandibular body (4.5-yr-old female). (b) Perforations on lingual (shown) and buccal sides, bone resorption at mandibular margin, tooth misalignment, split M3 and apparently lysis of the M2 tooth (5.5-yr-old male). (c) Bilateral thickening of mandibular bodies (4- to 5-yr-old male). (d) Bilateral differing physiognomy of mandibular angles and ramus, pathological fracture at M3 (upper arrow), tooth misalignment and perforations (lower arrows) (4- to 5-yr-old male).

mal end. Whereas a metatarsal, two femoral, and two tibial bones had no lesions in case 5 (adult male), the left humeral bone was greatly deformed. The distal part of the latter was eroded, and bone remodeling resulted in an irregularly shaped, mineralized but spongy, proliferating bone mass also involving the articu-

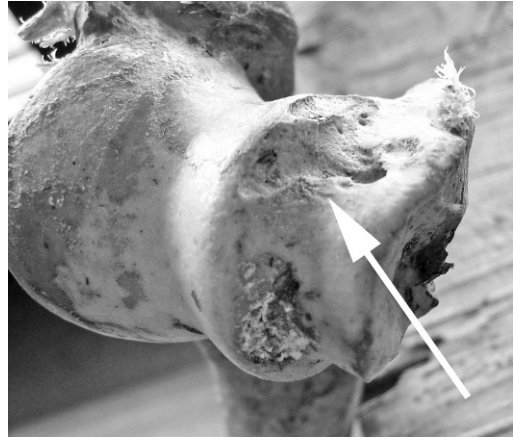

FIGURE 3. Focal subchondral cystic lesion (arrow, caudolateral view) in the lateral condyle of distal right humeral articulation (3- to 4-yr-old male).

lar surface (Fig. 4b). The medial third phalanx of the left front leg in case 9 had lesions affecting the hoof shape. The deformed claw capsule resulted in a hoof width approximately twice that of the normal hoof. Also, extra keratinous growth covering the hoof pad lacked abrasions, which indicated the animal did not use this hoof (Fig. 4c). The metacarpal bone of this case also had exostoses at the distal end. In case 11, the distal end of the left metacarpal bone was grossly deformed such that the shaft reached a width nearly double that of the normal right (Fig. 4a). The medial metacarpal trochlea was deformed, leaving behind only a porous mass of bone matrix. The lateral side of condyle 4, at the level of the tubercle, showed a substantial bony overgrowth, and eroded depression in the articular surface. The proximal half of the first medial phalanx had been eroded away with no articular surface remaining (Fig. 4a). The medial phalanx also had some exostoses on its base. In case 13, of the available appendicle bones, the proximal end of the left metatarsal enclosed to a tarsal bone, probably the os cuneiform lateral.

The only case revealing addition osteopathy was case 4, in which a fragment of

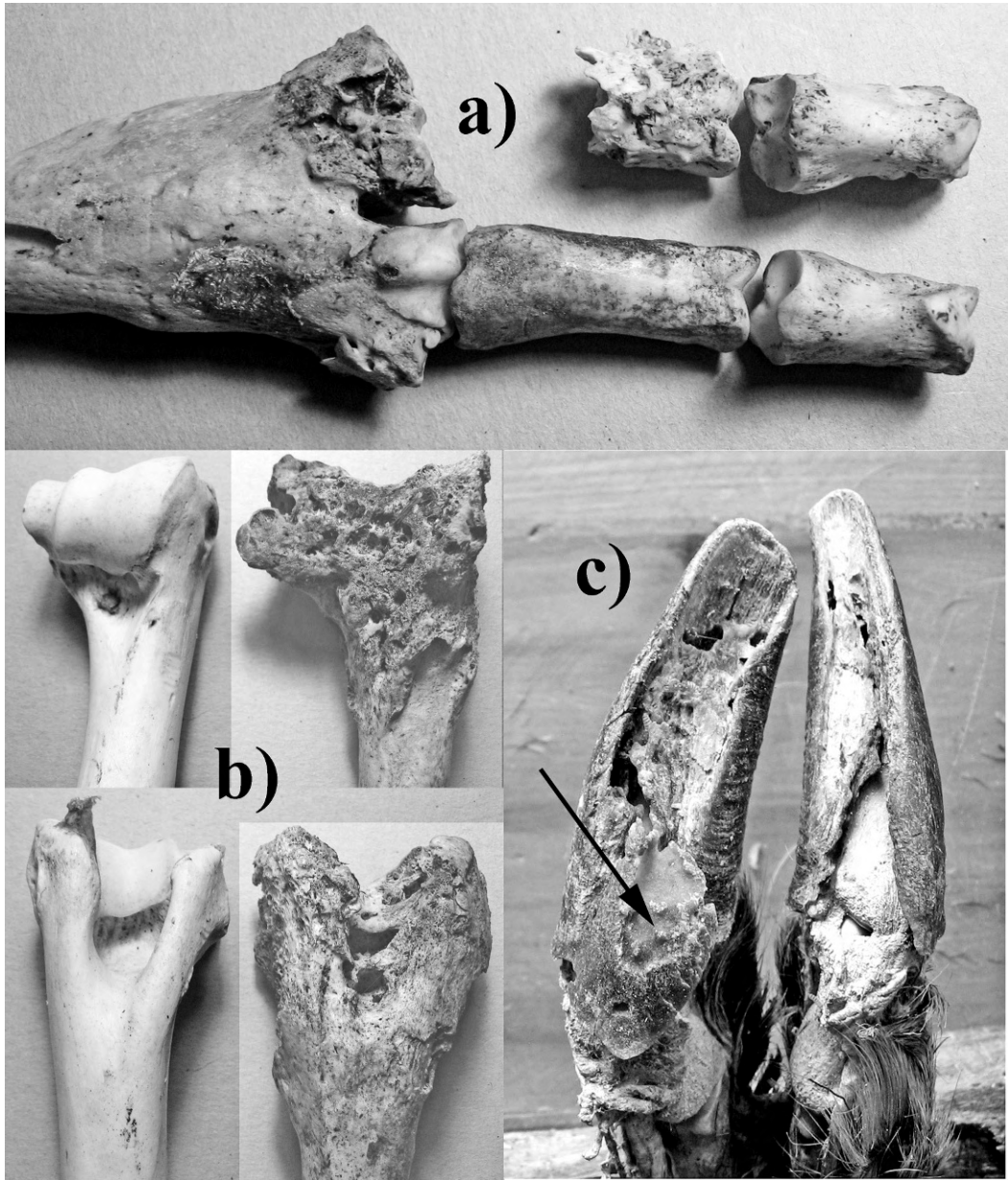


FIGURE 4. (a) Dorsal view of deformed medial metacarpal trochlea, leaving behind only a porous mass of bone matrix, and erosion of the proximal half of the first medial phalange (4.5-yr-old male). (b) Frontal (top) and dorsal (bottom) view of deformed distal end of the left humerus consisting of an irregularly shaped, spongy, proliferating mass of bone matrix (normal ends on left for comparison, adult male). (c) Deformed claw capsule of the left front leg with keratin lacking abrasion, covering the hoof pad (arrow, 2.5-yr-old male).

a thoracic vertebra had clear exostoses on the spinous process and the body, and the only other vertebra, the axis, also had extensive exostoses on the body.

DISCUSSION

Considering the limited amount of skeletal remains per case, the high prev-

alence of osteopathologic changes is striking. The rate of 52% affected among adult huemul is conservative, because another 36% were inconclusive, being represented by too few bones. However, because marginal gingivitis and early stages of arthritis cannot be diagnosed from such material, the prevalence of paradontal disease and arthritis in the population would almost certainly be much higher than indicated by the advanced stages reported here. Similar to what has been observed in other cervids (Leader-Williams, 1980; Peterson, 1988), fawns apparently were not yet affected; arthritis of articular surfaces of vertebral bodies and leg joints, for example, tends to occur after epiphyseal plates are ossified (Greer et al., 1977).

Lesions described here can affect the huemuls' performance to varying degrees, dependent on location and severity. Postcranial lesions might interfere with the energetic balance and general disease resistance, but they likely exert their main effect by reducing mobility and thus capacity to escape predation. In addition, skull lesions also have an energetic cost and reduce foraging efficacy and disease resistance. Thus, in advanced stages, survival strategies such as the capacity to avoid predation and reproductive success would be diminished. Of significance, 67% of diseased deer with both cranial and postcranial material available had lesions in both areas. Due to the limited material in other specimens, this is almost certainly an underestimate. The performance of animals with such widespread lesions would have been most affected. Although we cannot dismiss that puma (*Puma concolor*), the main predator, selected for diseased huemul and thus inflate the prevalence of osteopathy, no remains of a huemul older than 5.5 yr (average 3.1 yr) have been found during the many field campaigns between 1993 and 2007; thus, neither diseased nor healthy huemul survive to a mature age (Smith-Flueck and Flueck, 2001b).

The type of skull lesions, particularly those resulting in an edentulous mouth, would result in debilitations during food processing, thereby affecting body condition (Leader-Williams, 1982; Loe et al., 2006). Ongoing erosive processes are likely paralleled by pain, discomfort, secondary infections, and a drain of energy. Teeth eventually become loose or misaligned, and once lost, foraging efficacy is diminished. In similar habitat in New Zealand, the prevalence of advanced paradontal disease in chamois (*Rupicapra rupicapra*) was found to increase with age, and it was highest among 7+ yr olds (44%). Thus, the development from marginal gingivitis to periodontitis to advanced alveolar osteomyelitis was assumed to take a long time (Pekelharing, 1974). The preponderance of advanced cases in young huemul, however, indicates that the disease developed here in a relatively short time. Furthermore, older chamois frequently survived the disease, with teeth missing but healed jaws (Pekelharing, 1974). We found no cases of healed lesions and no huemul was older than 5.5 yr, but this difference might be explained by the absence of predators in New Zealand. The appendicular arthritic lesions described here indicate a gradient from pain and discomfort during locomotion to complete lameness. The osteoarthritis found in the vertebrae would be debilitating as well. The various lesions described in these huemul cases would thus have affected body condition and locomotive capacity, both of which are important for effective predator avoidance. Although predation by puma has been shown to be an important ultimate cause of death in one population of the study area (Smith-Flueck and Flueck, 2001b), these results indicate that a significant proximal cause might be osteopathologic processes, which would increase the susceptibility to predation, as was found for moose (*Alces alces*; Peterson, 1988). It might explain why the average age of the adult sample is only

about 3.1 yr, although huemul are known to live to at least 15 yr old (Diaz and Smith-Flueck, 2000). Such a truncated age distribution toward a young population indicates high adult mortality rates. Female reindeer (*Rangifer tarandus*) afflicted with the similar jaw problems on South Georgia Island (Falkland Islands) raised fewer calves (Leader-Williams, 1982), which also might be expected in compromised huemul living in a strongly seasonal environment. This together with high adult mortality rates could explain the lack of recovery of any known subpopulation in Argentina, as reflected by absence of recolonization of neighboring watersheds (Flueck and Smith-Flueck, 2006a). The only other incidence of osteopathy in huemul known to us has been reported by Milano et al. during the 1995 Argentine Mammal Society meeting, describing a similar case from similar habitat: of two skulls, one male had eroded maxillary and mandibular dental alveoli and missing teeth; the second male apparently lacked lesions.

Different etiologic factors can result in a similar physiognomy of skull and appendicular lesions, including rare cases of congenital aberrations, osteosarcoma, or toxicosis. The skull lesions described here are often referred to as “lumpy jaws”; however, it is merely a colloquialism used to identify anatomic facial bone abnormalities, because it does not describe an actual disease, nor does it represent a morphologic diagnosis. Initial deforming bony lesions are the clinical manifestation of subsequent chronic alveolar osteomyelitis (Fagan et al., 2005), the etiology of which remains complex. Moreover, clinical evidence of infection is not necessarily present. Lesions in lumpy jaws are generally of mixed microbial type developing within the body of facial bones. Because these tend to originate from the normal oral flora, none of Koch’s postulates apply, and they have to be considered of secondary relevance. Walling off through fibroplasia also can favor anaerobic organ-

isms within the cystic cavity, enlarging the cavity and even resulting in pathologic fractures (Fagan et al., 2005), as was observed in our sample. The reduction of bone substance, particularly in the maxillary bone with frequently exposed dental roots, is indicative of osteoporosis. As Whalen and Krook (1996) observed, periodontal disease is frequently an early manifestation of generalized osteoporosis.

Lumpy jaw has included descriptions of paradental disease involving only maxillary bones (in deer less than 12 yr old; Geiger et al., 1992), only mandibles (Leader-Williams, 1980, 1982; Hoefs and Bunch, 2001), or both (in deer >13 yr old; Geiger et al., 1992; this study). Conditions resulting in lumpy jaws without postcranial bone lesions include infection with the arterial nematode *Elaeophora schneideri*, which can cause partial paralysis of jaw muscles, resulting in food impaction and concomitant jaw disease, including tooth loss and fractured jaws (Davidson and Nettles, 1988). However, we are unaware of any arterial nematodes present in the study area or in other Argentine cervids, although domestic sheep and frequent imports of wild, exotic cervids could be potential sources. Developmentally deformed teeth also can enable intraoral organism and foreign bodies from food material to be impacted into the dental pulp chamber during mastication. Regardless, we discard this as a generalized cause because not all individuals showed misalignments, and the observed misaligned teeth apparently resulted secondarily due to elimination of supporting alveoli. Alternatively, actinomyces invade lesions secondarily and result in lumpy jaw, but they produce diagnostic sulfur granules (Fagan et al., 2005). Dry material from a typically affected maxillary bone in our sample was analyzed histologically without finding filaments or rods. Fluorosis also results in strikingly similar patterns of secondary skull infections and osteolytic processes, and chronic fluoride intoxication causes

hyperostosis in the postcranial skeleton and hoof deformities (Krook and Justus, 2006). The Andes are volcanically very active, and fluorine has been shown to be deposited at hundred of kilometers from volcanic sources (Witham et al., 2005), causing lesions in domestic livestock (Araya et al., 1990). Given that there are no known overt fluorosis cases among people or livestock near the study site, and that typical macroscopic lesions were absent in huemul and feral red deer (*Cervus elaphus*) in northern Patagonia (Flueck and Jones, 2006), fluorosis as a primary cause seems unlikely. Infections from *Fusobacterium necrophorum* also produce oral and postcranial lesions (necrobacillosis). Commonly part of the normal intestinal flora, it can invade lesions secondarily; however, progress is generally fulminating, often through septicemia, including from inhalation. Besides lumpy jaw, vertebral osteomyelitis and arthritis with ankylosis in chronic or healed cases have been described previously (Rosen, 1981). Moreover, necrobacillosis is frequently involved in pododermatitis, affecting hooves, joints, and leg bones in advanced stages (Rosen, 1981). Conversely, the lesions described here in huemul indicate that there was a protracted tissue reaction to a chronic process as evidenced by the extensive bone remodeling. Moreover, the infectious processes was controlled such that at least 62% of the animals died from predation with still active chronic osteomyelitis (remaining specimens had too little material to determine predation) (Smith-Flueck and Flueck, 2001b).

Similar osteopathy has been described in other cervids. Wobeser and Runge (1975) found 16% of white-tailed deer (*Odocoileus virginianus*) affected with degenerative skeletal lesions, based on complete carcasses. The femoral/tibial joint was involved in 95% of the positive cases. However, 90% of affected deer were 5 yr or older, with the most advanced cases at old age, and the absence of

lesions in skulls and leg extremities in all 128 animals indicates that the etiology differed from the present study. Skeletal remains of >2,400 moose from Isle Royal were examined for osteoarthritis, osteoporosis, periodontal disease, and other bone abnormalities (Peterson, 1988; Hindelang and Peterson, 1996). Prevalence was 32% and mainly erosive lesions on top of the skull without osteomyelitis. Furthermore, the prevalence increased sharply after 7 yr of age, and it was rare in earlier age classes, in contrast to our study, which suggests different etiologic origins. Osteoporosis in moose and reindeer were related to undernutrition from overcrowding (Leader-Williams, 1982; Peterson, 1988; Ytrehus et al., 1999), which would be unlikely as a major population of huemul in the study area occurred at a low density of 1.5 deer/km² (Smith-Flueck and Flueck, 2001a) and femoral marrow fat ranged between 88% and 98% (Smith-Flueck and Flueck, 2001b). Miller and Tessier (1971) examined 1,226 skulls of *R. tarandus* and found 43 anomalies mainly as supernumerary teeth and lack of or variation in root developments, but no pathologic changes as described here for huemul. In contrast, Leader-Williams (1980, 1982) found a high and density-dependent prevalence of mandibular osteopathy (but none in maxillary bones or other skeletal parts) of reindeer introduced to South Georgia Island. Because huemul densities were 2 orders of magnitude less than in South Georgia and maxillary bones were frequently involved in our findings, the underlying etiology likely differed. Mandibles of >41,000 Norwegian red deer (*Cervus elaphus*) showed a low frequency of innate problems that increased with age, most commonly as missing teeth, but no other changes were reported (Loe et al., 2006). In contrast, for red deer from central Germany, periodontal disease was common (Geiger et al., 1992). The prevalence of lesions in 267 skulls increased from 11% in 1–2 yr olds to 96% in 13+ yr old

deer. However, among 1–8 yr olds ($n=207$), only maxillary bones were affected, and they included many of the symptoms described for huemul maxillary bone (i.e., exposed roots, perforations). An additional sample of 431 mandibles corroborated that no deer <12 yr of age showed pathologic changes in lower jaws. Only the 13+ yr age class also had mandibles affected (27% prevalence), always accompanied with maxillary disease. Thus, only 2.7% of 698 mandibles were affected (Geiger et al., 1992). The clearly age-dependent periodontitis in mandibles was interpreted to result from the reduced size of worn molars in older animals, leading to a higher chance for food impaction, and therefore infections. The etiologic factors in their study thus not only differed from the Norway sample but also from the present study, where huemul at a young age had distinctly more severe pathologic changes, and with mandibles affected in 63% of diseased huemul with mandibles present. An additional pattern of lumpy jaw was described for wild sheep species (*Ovis* spp.) across North America (Hoefs and Bunch, 2001). Although only osteomyelitis from bacteria or fungus was found mainly in mandibles, there were no cases of actinomyces ($n=4,387$).

In conclusion, we hypothesize that the lesions described here represent secondary chronic alveolar osteomyelitis and osteoarthritis among young adult huemul, which suggests the occurrence of osteochondrosis. Senescence and gender can be excluded as predisposing factors. The data indicate a systemic phenomenon as 67% of the more complete specimens exhibit cranial and postcranial lesions, suggesting that this is the common pathophysiologic expression.

Although at the individual level there are numerous possible etiologic factors that could explain the observed changes, such as metabolic or endocrine disorders, posttraumatic congenital or developmental problems, genetic or neurologic disor-

ders, parasitism or marasmus, none of these would be expected to occur among such different age/sex classes and across such a large area and so many years. Moreover, we are not aware of any study showing the existence of such a widespread disease pattern that has one of these factors mentioned above as the underlying cause in a wild cervid population. Rather, the disease pattern reported here suggests that there are one or more fundamental common external factors. Preliminary investigations allow us to suggest that a likely underlying scenario is one in the realm of nutritional ecology. Southern Chile, which coincides with the huemul distribution, is known to be deficient in selenium (Se; Wittwer et al., 2002; Leyan et al., 2004), and this deficiency is associated with overt pathology in livestock (Contreras et al., 2005). Although there is no data for Argentina, the geologic features resulting in Se deficiency in Chile, namely, the type of bedrock and widespread volcanism (Flueck and Smith-Flueck, 2006b), also apply to the Argentine side of the Andean distribution of huemul. Se deficiency not only reduces host defense mechanisms but also impairs bone metabolism, causing osteopenia and osteoarthritis (Moreno-Reyes et al., 2001; Köhrle et al., 2005). In similar environments of New Zealand, Se deficiency in ruminants was shown to be the underlying factor for periodontitis, mandibular thickening, premature tooth shedding, and reduced bone density (Andrews et al., 1968; Porter et al., 1970). Se is not distributed homogeneously in the landscape, being often more concentrated in lower elevations and drier sites (Carter et al., 1970; Ren et al., 1987). Domestic ruminants have been shown to be Se deficient at high, but not at low elevation in the Columbian Andes, with Se enzyme activity differing by 41% (Jaramillo et al., 2005). Huemul in the studied population (and likely most others occurring along the eastern slopes of the Andes), used to migrate to western

lowlands and valley bottoms. Early explorers reported wintering huemul at 200 km from the Andes in treeless grasslands, and in groups of >100 huemul (Prichard, 1902; Hatcher, 1903). Once those areas had all been converted to livestock ranching, overhunting then eliminated the huemul's migratory behavior, and they survived only in the least-accessible refuges toward the continental divide. It has recently been shown that bighorn sheep (*Ovis canadensis*) made bimonthly short trips during the summer, to visit mineral licks at up to 2,000-m elevation lower in traditional winter ranges, which replenished an otherwise Se-deficient summer diet (Mincher et al., 2008). Similarly, we have hypothesized that the lack of access to traditional winter ranges might have created a nutritional bottleneck, compromising the immune and reproductive system of huemul in Argentina (Diaz and Smith-Flueck, 2000; Flueck and Smith-Flueck, 2006b).

Although surveillance and descriptive studies are valuable for species or diseases that have received little attention, limiting the research effort to mere reporting is of limited value if management recommendations are not given at the same time. Thus, additional experimental approaches are needed to produce substantial information that will enable authorities to make targeted management recommendations (Gortázar et al., 2007). Given the difficulties to effectively study wild huemul populations, a conservation center for semicaptive huemul was proposed, to be supported by long-term financial commitments by international nongovernmental organization (Smith-Flueck and Flueck, 2001c). If authorized, such a center could provide the mechanism to investigate the etiology of the bone changes observed in this study, to close other gaps in the knowledge on biology and ecology of this species, and to use an experimental approach through monitored reintroductions (Smith-Flueck et al., 2004).

ACKNOWLEDGMENTS

We thank the Departments of Fauna of the Chubut and Rio Negro provinces for permitting the study. We are grateful for active participation with information or fieldwork to the following: Esther Colinetti, Cathrine Davis, Garry Elliott, Susi Leiva, and Beat Fuchs. We also appreciate the excellent reviews and constructive criticism by several anonymous reviewers. Financial and logistic support were mainly provided by DeerLab, and additionally from Gernot Langes-Swarovski, World Nature Association, Scott Neotropical Fund, Zoologische Gesellschaft für Arten- und Populationsschutz, Wildlife Conservation International, Carlos and Francis Mallman, Juan Brondo, Eduardo Mayer, Swazi NZ, Cyon GmbH, and El Retorno-Bariloche.

LITERATURE CITED

- ANDREWS, E. D., W. J. HARTLEY, AND A. B. GRANT. 1968. Selenium-responsive diseases of animals in New Zealand. *New Zealand Veterinary Journal* 16: 3–17.
- ARAYA, O., F. WITTWER, A. VILLA, AND C. DUCON. 1990. Bovine fluorosis following volcanic activity in the Southern Andes. *Veterinary Record* 126: 641–642.
- CARTER, D. L., C. W. ROBBINS, AND M. J. BROWN. 1970. Selenium concentrations in forage on some high northwestern ranges. *Journal of Range Management* 23: 234–238.
- CONTRERAS, P. A., E. PAREDES, F. WITTWER, AND S. CARRILLO. 2005. Clinical case: Outbreak of white muscle disease or nutritional muscular dystrophy in calves. *Revista Científica, FCV-LUZ* 15: 401–405.
- DAVIDSON, W. R., AND V. F. NETTLES. 1988. Field manual of wildlife diseases in the Southeastern United States. Southeastern Cooperative Wildlife Disease Study. University of Georgia, Athens, Georgia, 309 pp.
- DÍAZ, N. I. 1993. Changes in the range distribution of *Hippocamelus bisulcus* in Patagonia. *Zeitschrift für Säugetierkunde* 58: 344–351.
- , AND J. SMITH-FLUECK. 2000. The Patagonian huemul. A mysterious deer on the brink of extinction. *Literature of Latin America*. Buenos Aires, Argentina, 149 pp.
- FAGAN, D. A., J. E. OOSTERHUIS, AND K. BENIRSCHKE. 2005. “Lumpy jaw” in exotic hoof stock: A histopathologic interpretation with a treatment proposal. *Journal of Zoo and Wildlife Medicine* 36: 36–43.
- FLUECK, W. T., AND A. JONES. 2006. Potential existence of a sylvatic cycle of *Taenia ovis krabbei* in Patagonia, Argentina. *Veterinary Parasitology* 135: 381–383.

- , AND J. M. SMITH-FLUECK. 2005. Hoof growth in neonatal Patagonian huemul (*Hippocamelus bisulcus*): A tentative tool for aging. *Journal of Neotropical Mammalogy* 12: 245–248.
- , AND ———. 2006a. Predicaments of endangered huemul deer, *Hippocamelus bisulcus*, in Argentina: A review. *European Journal of Wildlife Research* 52: 69–80.
- , AND ———. 2006b. Why the Patagonian huemul deer in Argentina fails to recover: An ecological hypothesis. In *Advances in deer biology*, L. Bartos, A. Dusek, R. Kotrba and J. Bartosova (eds.). Research Institute of Animal Production, Praha, Czech Republic, pp. 181–185.
- GEIGER, G., H. THOME, AND A. KUEHL. 1992. Parodontal bedingte Veränderungen am *Procesus alveolaris* beim Rotwild. *Zeitschrift für Jagdwissenschaft* 38: 107–115.
- GORTÁZAR, C., E. FERROGLIO, U. HÖFLE, K. FRÖLICH, AND J. VICENTE. 2007. Diseases shared between wildlife and livestock: A European perspective. *European Journal of Wildlife Research* 53: 241–256.
- GREER, M., J. K. GREER, AND J. GILLINGHAM. 1977. Osteoarthritis in selected wild mammals. *Proceedings of the Oklahoma Academy of Science* 57: 39–43.
- HATCHER, J. B. 1903. Reports of the Princeton University expeditions to Patagonia, 1896–1899, Vol. I: Narrative of the expeditions. In *Geography of Southern Patagonia*, W. B. Scott (ed.). Princeton University Press, Princeton, New Jersey, 314 pp.
- HINDELANG, M., AND R. O. PETERSON. 1996. Osteoporotic skull lesions in moose at Isle Royale national park. *Journal of Wildlife Diseases* 32: 105–108.
- HOEFS, M., AND T. D. BUNCH. 2001. Lumpy jaw in wild sheep and its evolutionary implications. *Journal of Wildlife Diseases* 37: 39–48.
- JARAMILLO, S., N. A. VILLA, A. F. PINEDA, A. B. GALLEGO, P. TABARES, AND A. CEBALLOS. 2005. Actividad sanguínea de superóxido dismutasa y glutatión peroxidasa en novillas a pastoreo. *Pesquisa Agropecuária Brasileira* 40: 1115–1121.
- KÖHRLE, J., B. CONTEMPRE, J. E. DUMONT, AND F. JAKOB. 2005. Selenium, the thyroid, and the endocrine system. *Endocrine Reviews* 26: 944–984.
- KROOK, L. P., AND C. JUSTUS. 2006. Fluoride poisoning of horses from artificially fluoridated drinking water. *Fluoride* 39: 3–10.
- LEADER-WILLIAMS, N. 1980. Dental abnormalities and mandibular swellings in South Georgia reindeer. *Journal of Comparative Pathology* 90: 315–330.
- . 1982. Relationship between a disease, host density and mortality in a free-living deer population. *Journal of Animal Ecology* 51: 235–240.
- LEYAN, V., F. WITTWER, P. A. CONTRERAS, M. PHIL, AND J. KRUEZ. 2004. Serum and colostrum immunoglobulin concentrations from selenium deficient cows and in the blood of their calves. *Archivos de Medicina Veterinaria* 36: 155–162.
- LOE, L. E., C. BONENFANT, R. LANGVATN, A. MYSTERUD, V. VEIBERG, AND N. C. STENSETH. 2006. Increased effect of harsh climate in red deer with a poor set of teeth. *Oecologia* 147: 24–30.
- MILLER, F. L., AND G. D. TESSIER. 1971. Dental anomalies in caribou, *Rangifer tarandus*. *Journal of Mammalogy* 52: 164–174.
- MINCHER, B. J., J. MIONCZYNSKI, P. A. HNILICKA, R. D. BALL, AND T. X. HOUGHTON. 2008. Some aspects of geophagia in Wyoming bighorn sheep (*Ovis canadensis*). *European Journal of Wildlife Research* 54: 193–198.
- MORENO-REYES, R., D. EGRISE, J. NEVE, J.-L. PASTEELS, AND A. SCHOUTENS. 2001. Selenium deficiency—Induced growth retardation is associated with an impaired bone metabolism and osteopenia. *Journal of Bone and Mineral Research* 16: 1556–1563.
- PEKELHARING, C. J. 1974. Parodontal disease as a new cause of tooth loss in a population of chamois (*Rupicapra rupicapra* L.) in New Zealand. *Zeitschrift für Säugetierkunde* 39: 250–255.
- PETERSON, R. O. 1988. Increased osteoarthritis in moose from Isle Royale. *Journal of Wildlife Diseases* 24: 461–466.
- PORTER, W. L., R. S. SCOTT, AND B. W. MANKTELOW. 1970. The occurrence of parodontal disease in sheep in relation to superphosphate topdressing, stocking rate and other related factors. *New Zealand Veterinary Journal* 18: 21–27.
- PRICHARD, H. H. 1902. *Through the heart of Patagonia*. D. Appleton and Co., New York, 346 pp.
- REN, J.-Z., Z.-Y. ZHOU, B. PAN, AND W. CHEN. 1987. Selenium distribution in four grassland classes of China. In *Selenium in biology and medicine*, G. F. Comb, J. E. Spallholz, O. A. Levander and J. E. Oldfield (eds.). AVI Book, New York, pp. 769–774.
- ROSEN, M. N. 1981. Necrobacillosis. In *Infectious diseases of wild mammals*, J. W. Davis, L. H. Karstad and D. O. Trainer (eds.). Iowa State University Press, Ames, Iowa, pp. 332–338.
- SMITH-FLUECK, J. M. 2003. The ecology of the endangered huemul deer (*Hippocamelus bisulcus*) in the Andean Patagonia of Argentina and conservation considerations. PhD Dissertation, Universidad Nacional del Comahue, Bariloche, Argentina, 361 pp.
- , AND W. T. FLUECK. 1997. Survey of a huemul population in the province of Rio Negro,

- Argentina. *Journal of Neotropical Mammalogy* 4: 25–33.
- , AND ———. 2001a. Conservation problems for an unusual concentration of huemul (*Hippocamelus bisulcus*) by Lago La Plata, province of Chubut. *Journal of Neotropical Mammalogy* 8: 72–83.
- , AND ———. 2001b. Natural mortality patterns in a population of southern Argentina huemul (*Hippocamelus bisulcus*), an endangered Andean cervid. *European Journal of Wildlife Research* 47: 178–188.
- , AND ———. 2001c. Una visión conceptual sobre la conservación del huemul en Argentina. In *Actas del Taller: Hacia un Plan Nacional de Conservación y Recuperación del Huemul en Argentina*, M. Cosse, D. Paz Barreto and S. Gonzalez (eds.). IUCN Deer Specialist Group, Montevideo, Uruguay.
- , N. I. DIAZ, AND W. T. FLUECK. 2004. Cría de huemules en cautiverio: las perspectivas actuales considerando las experiencias históricas. In *Cría en cautividad de fauna Chilena*, A. Iriarte, C. Tala, B. Gonzalez, B. Zapata, G. Gonzalez and M. Maino (eds.). Servicio Agrícola y Ganadero-Parque Metropolitano, Zoológico Nacional-Universidad de Chile, Santiago, Chile, pp. 457–470.
- WHALEN, J. P., AND L. KROOK. 1996. Periodontal disease as the early manifestation of osteoporosis. *Nutrition* 12: 53–54.
- WITHAM, C. S., C. OPPENHEIMER, AND C. J. HORWELL. 2005. Volcanic ash-leachates: A review and recommendations for sampling methods. *Journal of Volcanology and Geothermal Research* 141: 299–326.
- WITTWER, F., P. ARANEDA, A. CEBALLOS, P. A. CONTRERAS, M. ANDAUR, AND H. BOHMWALD. 2002. Glutathione peroxidase activity (GSH-Px) in grazing dairy cattle in the south of Chile (IXth Region) and their relation with selenium contents in the forage. *Archivos de Medicina Veterinaria* 34: 49–57.
- WOBESER, G., AND W. RUNGE. 1975. Arthropathy in white-tailed deer and a moose. *Journal of Wildlife Diseases* 11: 116–121.
- YTREHUS, B., H. SKAGEMO, G. STUVE, T. SIVERTSEN, K. HANDELAND, AND T. VIKOREN. 1999. Osteoporosis, bone mineralization, and status of selected trace elements in two populations of moose calves in Norway. *Journal of Wildlife Diseases* 35: 204–211.

Received for publication 19 November 2007.

APPENDIX

After the acceptance of the final MS, partial remains of three more huemul became available from another subpopulation, all positive and thus raising the prevalence of affected adult huemul to 57%. A 2.5-yr-old male had affected maxillae (bone resorption and perforation exposing roots of teeth: Fig. 1a, d) and mandibles (periodontitis, enlarged alveoli, reduced margin, and thickening from osteomye-

litis: Fig. 2a, c). A mature male had affected maxillae (bone resorption, perforations exposing roots of teeth, and enlarged dental alveoli: Fig. 1a, b, c, d). A mature female had affected maxillae (bone resorption and perforation exposing roots of teeth: Fig. 1a, b, c, d) and mandibles (periodontitis, enlarged alveoli, reduced margin, thickening from osteomyelitis, broken teeth, greenstick fracture, and reduced jaw height: Fig. 2a, b, c, d).