



## Effects of *Solanum glaucophyllum* toxicity on cell proliferation and apoptosis in the small and large intestine of rabbits

C.N. Zanuzzi<sup>a,b,\*</sup>, F. Nishida<sup>a</sup>, E.L. Portiansky<sup>a</sup>, P.A. Fontana<sup>a</sup>, E.J. Gimeno<sup>a</sup>, C.G. Barbeito<sup>a,b</sup>

<sup>a</sup> Instituto de Patología, Facultad de Ciencias Veterinarias, Universidad Nacional de La Plata, La Plata, Buenos Aires, Argentina

<sup>b</sup> Cátedra de Histología y Embriología, Facultad de Ciencias Veterinarias, Universidad Nacional de La Plata, La Plata, Buenos Aires, Argentina

### ARTICLE INFO

#### Article history:

Received 7 January 2011

Accepted 21 July 2011

#### Keywords:

1,25-Dihydroxyvitamin D<sub>3</sub>

Intestine

Rabbit

Proliferation

Apoptosis

### ABSTRACT

Vitamin D regulates mineral homeostases and enterocyte proliferation and differentiation. Hypervitaminosis D generates changes in cell proliferation, differentiation and apoptosis in several organs. We analysed morphometric parameters and proliferative and apoptotic indices in the intestinal epithelium of rabbits with hypervitaminosis D induced by the chronic treatment with the calcinogenic plant *Solanum glaucophyllum*. Rabbits were treated for 15 or 30 days. A group was treated for 15 days and led to possible recovery for 30 days. Another group was nutritionally restricted for 30 days. Morphological, morphometric, proliferative and apoptotic changes were found in the treated animals. Mild atrophy and reduced proliferation was found in the jejunum and ileum. Apoptosis increased in the crypts of the ileum and in the superficial epithelium and crypts of the rectum. Most of the alterations were partially recovered. The possible involvement in these changes of the hypervitaminosis D-like state induced by *S. glaucophyllum* is discussed.

© 2011 Elsevier Ltd. All rights reserved.

### 1. Introduction

Vitamin D has been associated with increased absorption of dietary calcium and phosphate (Wesley et al., 2006; Bikle, 2007) and enterocyte proliferation and differentiation (Suda et al., 1990; Newmark and Lipkin, 1992; Menard et al., 1995; Holt et al., 2002) in the gastroenteric tract. It induces the expression of genes involved in environmental intestinal toxin detoxification (Kutuzova and DeLuca, 2007), and in the preservation of the mucosal barrier integrity (Kong et al., 2008).

Cell proliferation, differentiation and apoptosis continuously occur in the intestine, and they are tightly regulated to ensure epithelial renewal (Potten, 1991; Potten et al., 1997). These processes can be altered under starvation (Holt et al., 1986; Chappell et al., 2003), fasting (Park et al., 2008) and chronic psychological stress in rats (Boudry et al., 2007), as well as under *Escherichia coli* infection in rabbits (Wada et al., 1997; Heczko et al., 2001).

*Solanum glaucophyllum* (*S. glaucophyllum*) (synonym of *Solanum malacoxylon*) is a calcinogenic plant responsible for enzootic calcinosis in ruminants of South America, a cause of considerable

\* Corresponding author at: Instituto de Patología, Facultad de Ciencias Veterinarias, Universidad Nacional de La Plata, Calle 60 y 118, 1900 La Plata, Buenos Aires, Argentina. Tel.: +54 221 423 6663x426; fax: +54 221 423 7980.

E-mail addresses: [carozanuzzi@fcv.unlp.edu.ar](mailto:carozanuzzi@fcv.unlp.edu.ar), [carozanuzzi@gmail.com](mailto:carozanuzzi@gmail.com) (C.N. Zanuzzi).

economic losses in Argentina, Brazil and Uruguay (Worker and Carrillo, 1967). The toxic principles, mainly contained in the leaves, consist of vitamin D analogues, mostly 1,25(OH)<sub>2</sub>D<sub>3</sub>, associated with glycoside derivatives. The chronic ingestion of this plant induces a hypervitaminosis D-like state (Wasserman, 1974; Dallorso et al., 2001; Mello, 2003). Spontaneous intoxication occurs in ruminants when the active principle is released into the rumen. The intoxication of non-ruminant species, such as pigs (Campero and Odriozola, 1990) and horses (Ruager and Gimeno, 1977), shows that the toxic principle does not need to suffer structural modifications such as the hydrolysis of the glycosides accounted in the rumen, as it has been previously suggested (Boland et al., 1986; Mello and Habermehl, 1992). Intoxicated animals show mineralization in heart, arteries, lungs and kidneys, joint erosions, stiffness, painful gait, kyphosis, anorexia and loss of body condition. In severe cases, emaciation is also observed (Worker and Carrillo, 1967), although the cause remains unknown. Rabbits are useful as experimental model. They are highly susceptible to experimental treatment with *S. glaucophyllum* in a way similar to the natural intoxication that occurs in ruminants (Dallorso et al., 2001; Gimeno et al., 2004; Fontana and Zanuzzi, 2007; Zanuzzi et al., 2008; 2010).

Experimental studies performed in animal models treated with *S. glaucophyllum* have shown changes in cell proliferation, differentiation and apoptosis in aorta, lungs (Barros and Gimeno, 2000; Portiansky et al., 2002), skin (Gimeno et al., 2000; 2004), thymus, lymph nodes and spleen (Fontana and Zanuzzi, 2007; Fontana,

2009; Fontana et al., 2009). In the intestine the effects of this treatment include specific changes in Paneth cells (Zanuzzi et al., 2008) and in the carbohydrate expression pattern of enterocytes and goblet cells (Zanuzzi et al., 2010). The experimental model of hypervitaminosis D in transgenic mice used by Razzaque and Lanske (2006) and Medici et al. (2008) showed changes in cell proliferation and apoptosis in the intestine, skin and kidneys.

In the present work we studied the morphometry and the changes in cell proliferation and apoptosis in the intestine of rabbits treated with *S. glaucophyllum*. We aimed to contribute to the understanding of the pathogenesis of the hypervitaminosis D-like state induced by *S. glaucophyllum* intoxication.

## 2. Materials and methods

### 2.1. Animals

Twenty-five three-month-old New Zealand male rabbits were used. All animals were clinically healthy at the beginning of the experiment. They were housed at the experimental unit for one week prior to the experiment in order to reduce stress effects due to environmental changes. Each animal was housed in an individual cage. All the procedures were carried out in accordance to the “Guide for the Care and Use of Laboratory Animals” of the National Research Council (National Academy Press, 1996, Washington, USA).

### 2.2. Treatment with *S. glaucophyllum* and experimental groups

*S. glaucophyllum* leaves were collected in the locality of Chascomús (Buenos Aires, Argentina), an area of high incidence of enzootic calcinosis, during springtime. The active principle is stable for up to four years (Puche et al., 1981). The leaves were air-dried, powdered with a blender and administered as pellets, which consisted of a mix of standard diet, tap water and 125 mg/kg of powdered leaves, a dose chosen based on previous works (Dallorso et al., 2001; Gomar, 2006; Fontana and Zanuzzi, 2007; Zanuzzi et al., 2008; Fontana, 2010; Fontana et al., 2009). Animals were orally treated three times a week with these pellets and water *ad libitum*, whereas control group received water and standard diet *ad libitum* during the study.

Animals were intramuscularly anesthetized with ketamine (35 mg/kg) and xylazine (5 mg/kg) and then cardiac puncture was performed. Five rabbits were killed after 15 days of treatment (group A); other five were treated for 30 days and killed thereafter (group B); five animals that were treated for 15 days were led to possible recovery for 30 days (group C - recovery group). Six animals were used as controls and killed in pairs at day 15, 30 and 45. During *S. glaucophyllum*-intoxication the treated animals reduced the ingestion of food and suffered a reduction in their body weight. A group of four rabbits (group D) was then selected to determine whether changes in the body weight were a consequence of a reduction in the ingestion of food, the treatment or a combination of both. For this purpose group D animals were fed with the same standard diet as that given to control group, but in an amount equal to that consumed by the treated animals. Group D animals were killed after 30 days.

Clinical signs were observed and recorded every day during the entire study. Rabbits were weighed once a week. In order to compare weight variations between groups the relative weight index was calculated for each animal using the following formula:

Relative weight index

= body weight on the day of measurement/body weight on day 0

### 2.3. Histological studies

All rabbits were necropsied and samples of small and large intestine were collected. Samples were obtained from jejunum (middle region, 1 m from the pyloric sphincter), ileum (10 cm from the ileocecal junction) and rectum, and then rinsed in 0.2 M PBS, fixed in 10% neutral buffered formalin for 24 h and embedded in paraffin wax. Paraffin blocks were sectioned on a semiautomatic microtome (LEICA RM2245, GmbH, Nussloch, Germany) and six 3- $\mu$ m-thick non-contiguous (100  $\mu$ m apart) sections of each intestinal region of every tested animal were routinely stained with haematoxylin and eosin (HE) according to Bancroft and Stevens (1990). All morphological measurements were conducted by two blinded researchers.

### 2.4. Morphometric studies

Sections stained with HE were examined under a light microscope. A minimum of 10 well-oriented crypt-villous units or crypts of each section from jejunum, ileum and rectum were analysed for each animal. The length and width of villi and crypts were measured. Images of each sample section were captured from a microscope (Olympus BX50, Tokyo, Japan), with objectives of 10 $\times$  or 40 $\times$  magnification, using an attached digital video camera (Olympus DP71, Tokyo, Japan) connected to a computer containing an image analysis program (ImagePro Plus, v6.3, Media Cybernetics, USA), and stored in RGB TIFF 24 bits format.

### 2.5. Proliferation study

Sections (3  $\mu$ m thick) were mounted on slides coated with g-methacryloxypropyltrimethoxy-silane (M6514, Sigma, St. Louis, MO, USA), passed through a decreasing graded alcohol scale and incubated with 0.03% H<sub>2</sub>O<sub>2</sub> in methanol (purum P99.0%) for 30 min at room temperature. Sections were then rinsed twice in PBS and exposed to microwave antigen retrieval using a buffer citrate solution (pH 6.0) (Taylor et al., 1996). Sections were then incubated with 1% BSA in PBS for 30 min, followed by overnight incubation with anti-Ki67 antibody (monoclonal mouse anti-human Ki-67 antigen Clone MIB-1, ready-to-use, DakoCytomation, Carpinteria, CA, USA). The EnVision<sup>®</sup> detection system + HRP system labelled anti-mouse polymer (DakoCytomation) was applied for 30 min. Sections were then rinsed three times in PBS for 5 min each time. Liquid 3,3-diaminobenzidine tetrahydrochloride (DAB) (DakoCytomation) was used as chromogen and Hill's haematoxylin for counterstaining. Control negative sections were prepared by omitting primary antibody. A section of feline squamous cell carcinoma was used as a positive control. At least 700 cells per section were counted using a 40 $\times$  objective and the number of labelled and non-labelled epithelial cells was recorded. Proliferation index was expressed as the percentage of labelled cells over the total epithelial cells using the following formula:

$$\text{Proliferation index} = \frac{\text{number of epithelial labelled cells}}{\text{total number of epithelial cells}} \times 100$$

### 2.6. Apoptosis study

In the HE-stained sections apoptotic cells were identified using the following morphological criteria: cell shrinkage, acidophilic cytoplasm and condensation and fragmentation of nuclear chromatin. Apoptosis was confirmed by the use of the modified terminal deoxynucleotidyl transferase (TdT)-mediated deoxyuridine triphosphate (dUTP) nick-end labelling technique (TUNEL kit ApopTag Chemicon International, Temecula, CA, USA). We followed

the manufacturer's suggested protocol. All TUNEL labelled samples were counterstained with methylene green. TUNEL protocol included negative controls excluding the TdT step of the original method. As positive control we used the positive sample provided by the commercial kit.

To calculate the apoptotic index in the villi we measured the perimeter of the villi and counted the number of apoptotic cells along that perimeter. The apoptotic index was expressed as:

$$\text{Apoptotic index} = \frac{\text{number of apoptotic epithelial cells in the villi}}{\text{total number of epithelial cells}} \times 100$$

To calculate the apoptotic index in the crypts in the three anatomic segments and in the superficial epithelium of the rectum we

counted at least 700 cells per slide using a 40× objective. The apoptotic index was expressed as:

$$\text{Apoptotic index} = \frac{\text{number of apoptotic epithelial cells in the crypt}}{\text{total number of epithelial cells}} \times 100$$

### 2.7. Statistical analysis

An analysis of variance (ANOVA) with one factor was used. Significance was assumed at values of  $p < 0.05$ . The Fisher least significant difference (LSD) test was used for the post hoc comparisons. For these comparisons, the  $p < 0.01$  level was used to define significance between groups.

## 3. Results

### 3.1. Clinical signs and macroscopic lesions

All the treated animals from groups A and B reduced the ingestion of food after 24–48 h. Compared to control animals, all the groups showed a significant reduction in their body weight index from day 7 up to the end of the experiment (Fig. 1). Treated animals also showed other clinical signs, such as diarrhoea, rhinitis, conjunctivitis or external otitis. Animals from group C showed clinical signs only during the treatment time, and partially recovered body weight during the remaining 30 days. Animals from group D also showed a gradual body weight reduction. In contrast to treated animals, they were more aggressive and hyperkinetic.

At necropsy, animals from groups A and B showed reduction of adipose tissue compared to control animals, muscular atrophy and

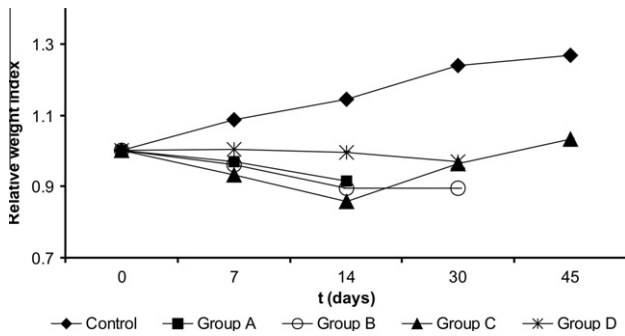


Fig. 1. Body weight variations in *S. glaucophyllum*-treated animals. Note the progressive reduction of body weight index with time in treated animals. All the groups showed a significant reduction in their body weight index in comparison to control group ( $p < 0.05$ ).

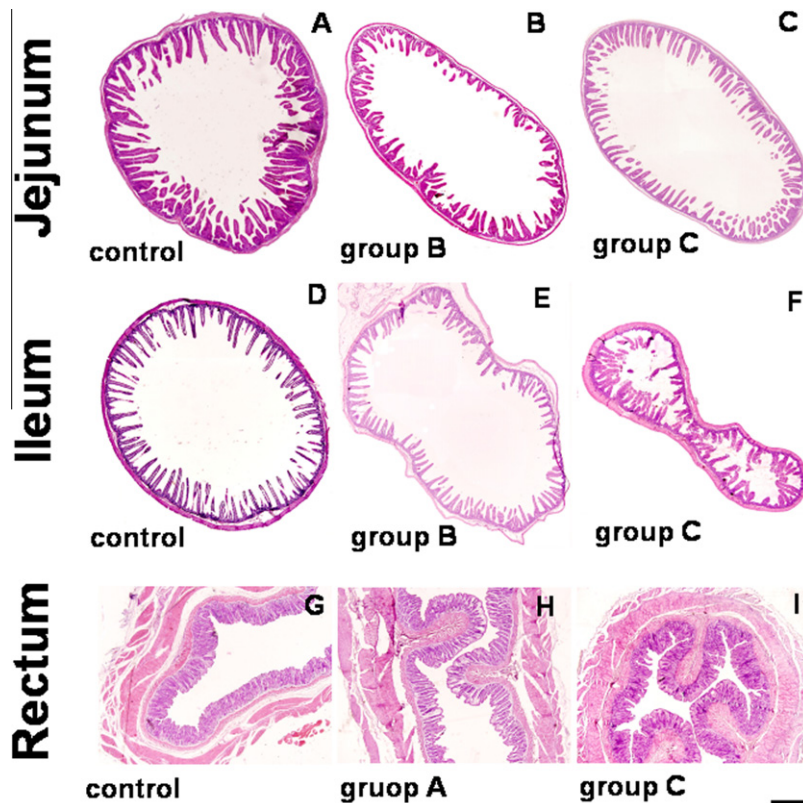
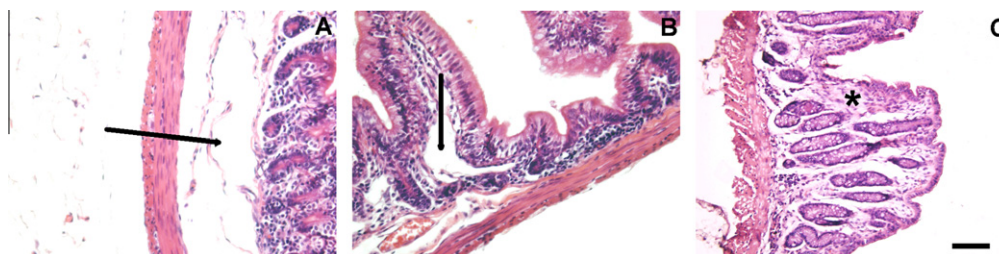
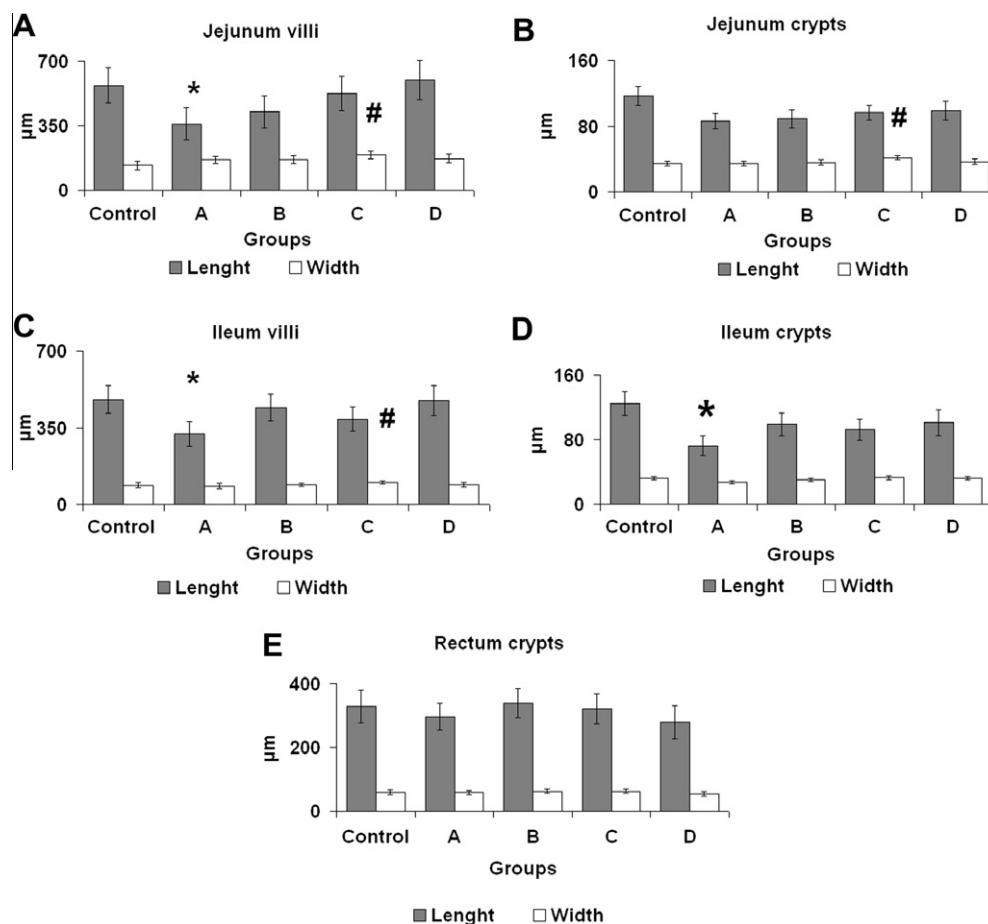


Fig. 2. Morphological changes of the intestine. A–C: jejunum; D–F: ileum; G–I: rectum. A, D and G: control group. B, E: group B. H: group A. C, F and I: group C. Samples of jejunum and ileum of treated animals show atrophy of the villi. A mild recovery is observed in the same intestinal tracts in group C. Multifocal slight atrophy was observed in the rectum. All sections were stained with H–E. Bar = 1 mm.



**Fig. 3.** Pathological features of the intestine. All images belong to group B. Lymphangiectasia is observed in both jejunum (A) and ileum (B) (arrows). (C) oedema in the lamina propria (\*) of the rectum. All sections were stained with H-E. Bar = 50  $\mu$ m.



**Fig. 4.** Morphometric study of crypts and villi. Significant differences (\*) in villi length of jejunum were observed (group A vs. control and group D) or villi width (#) (group C vs. control). Significant differences in crypt width (#) were observed (group C vs. all groups except group D). Significant differences (\*) in villi length of ileum were observed (group A vs. control and group D) or villi width (#) (group C vs. group A). Significant differences in crypt length of rectum (\*) were observed (group A vs. controls). The figure shows the means of the experimental groups and the 99% confidence interval on the treatment means. \*, # =  $p < 0.01$ .

calcification of the cardiovascular system (tricuspid and mitral valves, inner surface of aorta and pulmonary arteries), lungs and renal cortices. Animals from group C only showed calcification of the cardiovascular system.

### 3.2. Histological studies

The mucosa of the jejunum, ileum and rectum from the treated groups during 15 (group A) and 30 days (group B) showed atrophy (Fig. 2). In jejunum and ileum the degree of atrophy of the villi was about 30%. In some animals lymphangiectasia extended up to the tunica muscular (Fig. 3). The mucosal layer of the animals from group D appeared slightly atrophic with oedema and lymphangiectasia in the lamina propria.

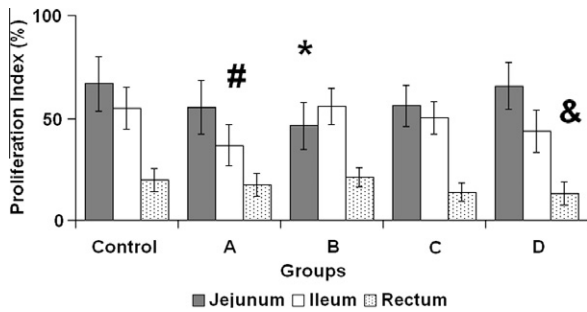
### 3.3. Morphometric studies

#### 3.3.1. Jejunum

Villous length was significantly reduced in groups A as compared to control and D groups, whereas villous width was significantly higher in group C in comparison to control group. Crypt width increased in group C as compared to all groups except group D (Fig. 4).

#### 3.3.2. Ileum

Villous length (Fig. 4) was significantly reduced in group A as compared to control and D groups. Villous width increased in group C compared to group A. Crypt length was significantly reduced in group A compared to control animals.



**Fig. 5.** Ki-67 proliferation index in the intestine. The proliferation index was reduced in some *S. glaucophylum*-treated animals. In the jejunum, significant differences (\*) were observed between group B vs. control and D groups. In the ileum, significant differences (#) were observed between group A and the rest of the groups. In the rectum significant differences (&) were observed between group D vs. group B. The figure shows the means of the experimental groups and the 99% confidence interval on the treatment means. \*, #, & =  $p < 0.01$ .

### 3.3.3. Rectum

No significant differences were found in crypt length or width neither between treated animals nor with controls (Fig. 4).

## 3.4. Proliferation and apoptosis studies

### 3.4.1. Jejunum

Proliferation index was significantly decreased in animals from group B compared to controls and group D (Fig. 5). No significant

difference in the apoptotic index was observed between groups (Fig. 6).

### 3.4.2. Ileum

Proliferation index was significantly reduced in group A compared to the rest of the groups (Fig. 5). There was a significant increase in the apoptotic index of the crypts in group A compared to the rest of the groups (Fig. 6).

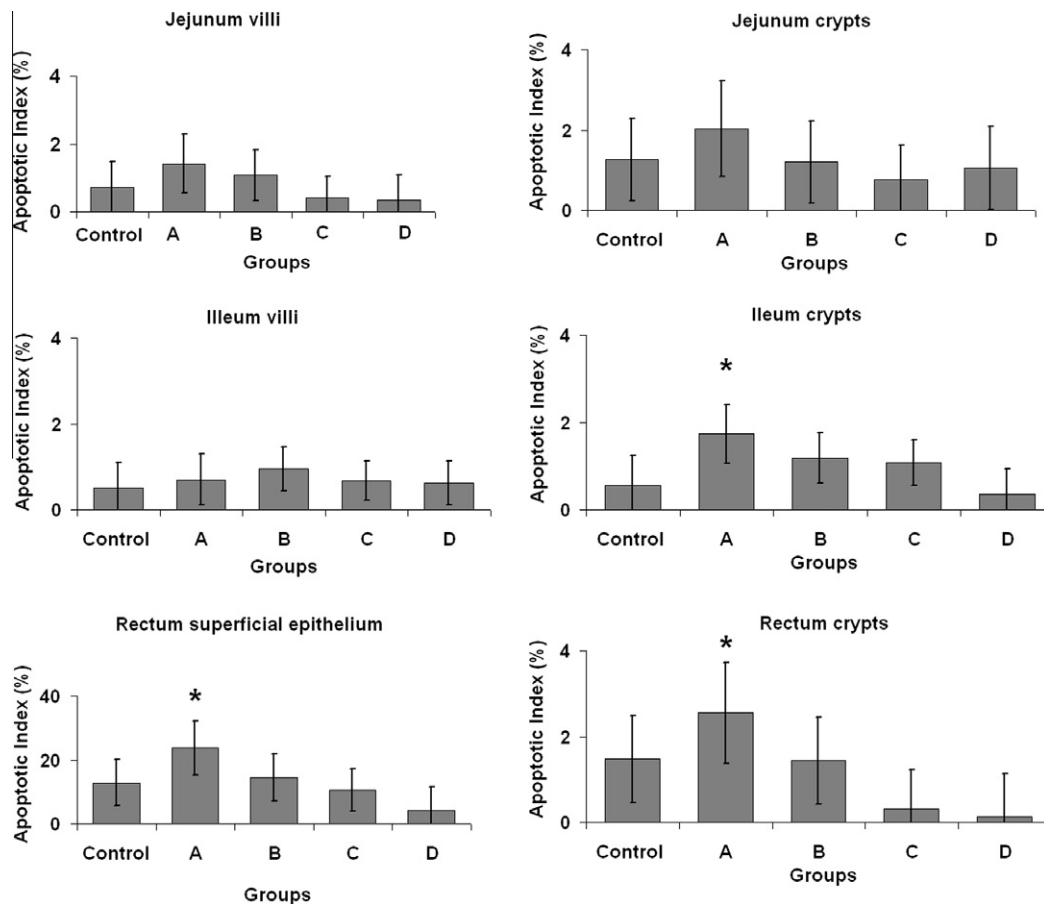
### 3.4.3. Rectum

The proliferation index was significantly reduced in group D compared to group B (Fig. 5). The apoptotic index of the superficial epithelium and crypts was significantly increased in group A in comparison to group C and D (Fig. 6).

## 4. Discussion and conclusions

Vitamin D regulates cell proliferation, differentiation and apoptosis in the intestine (Menard et al., 1995; Díaz et al., 2000; Biol-N' Garagba et al., 2002; Holt et al., 2002; 2006). Several studies have shown that 1,25 (OH)<sub>2</sub> vitamin D<sub>3</sub> inhibits cell proliferation in normal rectal mucosa (Thomas et al., 1992), adenomatous polyps (Holt et al., 2006) and colonic and rectal cancer cell lines (Díaz et al., 2000). These findings have supported its use in the prevention and treatment of hyperproliferative disorders (Bikle, 2007; 2008).

Changes in cell proliferation, differentiation and apoptosis have been reported in several organs under a hypervitaminosis D state (Barros and Gimeno, 2000; Gimeno et al., 2000; Portiansky et al.,



**Fig. 6.** Apoptosis of epithelial cells. In ileum crypts (\*) significant differences vs. the remaining groups were observed. In the superficial epithelial cells and crypts of the rectum (\*) significant differences vs. groups C and D were found. The figure shows the means of the experimental groups and the 99% confidence interval on the treatment means. \* =  $p < 0.01$ .

2002; Gimeno et al., 2004; Razzaque and Lanske, 2006; Fontana and Zanuzzi, 2007; Medici et al., 2008; Zanuzzi et al., 2008; Fontana et al., 2009; Fontana, 2010; Zanuzzi et al., 2010). Morphological modifications have been reported in the crypts of the small intestine of rats treated with metrotrexate (Verburg et al., 2000), and in the mucosa and lamina propria of young rats fed with low protein content diet (Rodrigues et al., 1985). According to Drozdowski and Thomson (2006) dynamic morphological parameters, such as enterocyte proliferation and migration, are associated with intestinal adaptation to internal and external environmental stimuli. Modifications in the proliferation and apoptosis may explain the changes in the size of villi and crypts found in several pathological conditions.

In the present study, we observed morphological and morphometrical alterations in the intestines of rabbits fed with the calcinogenic plant *S. glaucophyllum*. Besides, cell proliferation and death were affected. Cell proliferation in the jejunum and in the ileum was reduced after 30 and 15 days of treatment, respectively. In contrast, in the rectum the changes in apoptosis seemed to play a primary role. In other experimental studies, variations in proliferation rate within intestinal regions have also been reported, e.g. in rats subjected to thermal stress (Greant et al., 1988) and in the colon of mice fed with a vitamin D-deficient diet (Sadava et al., 1996). Specific adaptive responses of each anatomical region and differences in the expression of vitamin D receptors within the gastrointestinal tract have been reported in goats, sheep (Liesegang et al., 2007; Riner et al., 2008) and rabbits (Duncan et al., 1984). Variations in the number and distribution of vitamin D receptors in the intestine might also explain the results obtained in the present study. In addition, the hormonal and metabolic profile of animals from group C during and after the treatment period, and the differences in the mechanism of adaptation or recovery of each intestinal section could account for their partial recovery.

The response of the intestinal mucosa to different injuries or stressors reveals the great plasticity of this organ to adapt to most of them, a property known as enteroplasticity (Drozdowski and Thomson, 2006). In some circumstances the response to similar injuries might differ. Holt et al. (1986) observed a hyperplastic response in the ileum of nutritionally restricted animals, and a reduced cell proliferation in the duodenum. Other authors (Chappell et al., 2003) found a decreased cell proliferation in the proximal intestine of rats subjected to progressive nutritional restriction, with changes in cell death only during complete fasting. In contrast, the apoptosis was increased in the crypts of animals under intermittent water avoidance stress (Boudry et al., 2007).

The results from group D differed from those of control or treated groups according to the intestinal section analysed and the measured parameters. Thus, the alterations found in the treated animals might result from the reduction in food ingestion, from a specific response to *S. glaucophyllum* treatment or a combination of both. Taking into account the present results and the well-known vitamin D antiproliferative effects in the intestine (Thomas et al., 1992; Holt et al., 2006; Bikle, 2007; 2008), it is possible that the changes observed in affected animals were primarily induced by *S. glaucophyllum* treatment.

Atrophy and changes in cell proliferation and death have been also reported in knockout mice for *FGF-23* and *Klotho* genes that exhibit a hypervitaminosis-D like status (Razzaque and Lanske, 2006; Lanske and Razzaque, 2007). They show hyperphosphatemia, hypercalcemia, atherosclerosis, emphysema, kyphosis, alopecia, loss of body weight, osteopenia/osteoporosis, hypogonadism, soft tissue calcifications and atrophy of several organs, such as thymus and spleen (Razzaque and Lanske, 2006; Medici et al., 2008). Most of the aforementioned clinical signs are frequently found in naturally and experimentally *S. glaucophyllum*-intoxicated animals.

Particularly, in the intestine of *FGF-23* and *Klotho*-knockout mice, intestinal mucosa and villi are atrophic (Razzaque and Lanske, 2006; Lanske and Razzaque, 2007). The reduced proliferation and the increased apoptosis explain those morphological alterations (Razzaque and Lanske, 2006; Lanske and Razzaque, 2007; Medici et al., 2008). The changes described in these knockout mice have been attributed to the hypervitaminosis D status, and considered premature ageing-like features (Razzaque and Lanske, 2006; Lanske and Razzaque, 2007; Medici et al., 2008). We also found significant differences in the proliferation index of the small intestine and in the apoptotic index of the ileum and rectum in the treated animals. In line with these observations, the similarity between the results of our model and those from transgenic mice further support the involvement of vitamin D in the changes found in the treated rabbits.

The reduced body weight in the treated animals supports that reported in naturally intoxicated cows by Worker and Carrillo (1967), and in experimentally intoxicated rabbits by Dallorso et al. (2001). It has been shown that high calcium levels reduce weight gain (Davies et al., 2000; Heaney et al., 2002). Thus, the intestinal atrophy, the reported modifications on the glycosylation process (Zanuzzi et al., 2010), and the hypercalcemic state found in the treated rabbits (Fontana, 2010) could lead to alterations in the digestive and absorption processes, and explain the gradual and progressive loss of weight.

Vitamin D has immunomodulatory effects (Bikle, 2008). Although we did not evaluate the specific impact of hypervitaminosis D state on the adaptive and innate immunity the clinical signs and lesions found in the treated animals strongly suggest local or systemic immunological impairment. In addition, atrophy of lymphoid organs, changes in proliferation and apoptosis, and hyperplasia and hypertrophy of Paneth cells, were other changes reported in cattle and rabbits treated with *S. glaucophyllum* (Fontana and Zanuzzi, 2007; Zanuzzi et al., 2008; Fontana et al., 2009; Fontana, 2010). The otitis, rhinitis, conjunctivitis or diarrhoea described in this study have been previously reported in rabbits treated with *S. glaucophyllum* by several authors (Dallorso et al., 2001; Gomar, 2006; Fontana, 2010) who did not observe anatomopathological characteristic lesions suggestive of diseases induced by infectious agents, such as rotavirus, coronavirus or *Escherichia coli*.

In conclusion, the findings described in this work show that *S. glaucophyllum* treatment induced a hypervitaminosis D-like state that alters cellular proliferation and apoptosis in the intestinal epithelium. These results will help to better understand the clinical signs observed in naturally intoxicated animals.

## 5. Conflict of interest statement

All the authors declare that there is no actual or potential conflict of interest including any financial, personal or other relationships with other people or organizations within three years of beginning the submitted work that could inappropriately influence, or be perceived to influence, their work.

## Acknowledgements

We thank Mr. Rubén Mario, Mrs. Rosa Villegas and Miss María Guadalupe Guidi for their technical assistance. Financial support was provided in part by grants from Agencia Nacional de Promoción Científica (ANPCyT) (PICT 08-08573), Consejo Nacional de Investigaciones Científicas (CONICET) and Academia Nacional de Agronomía y Veterinaria (ANAV), Argentina. CNZ, FN, ELP, EJC and CGB are members of CONICET (National Scientific Research Council).

## References

- Bancroft, J.D., Stevens, A., 1990. Theory and Practice of Histological Techniques, Third ed. Churchill, Livingstone, New York, pp. 639–640.
- Barros, S.S., Gimeno, E.J., 2000. Cell differentiation and bone protein synthesis in the lungs of sheep with spontaneous calcinosis. *Journal of Comparative Pathology* 123, 270–277.
- Bikle, D.D., 2007. What is new in vitamin D: 2006–2007. *Current Opinion in Rheumatology* 19, 383–388.
- Bikle, D.D., 2008. Nonclassical actions of vitamin D. *Journal of Clinical Endocrinology and Metabolism* 94, 26–34.
- Biol-N' Garagba, M.C., Greco, S., George, P., Huguency, I., Louisot, P., 2002. Polyamine participation in the maturation of glycoprotein fucosylation, but not sialylation, in rat small intestine. *Pediatric Research* 51, 625–634.
- Boland, R.L., Skliar, M.I., Norman, A.W., 1986. Isolation of the Vitamin D<sub>3</sub> metabolites from *Solanum malacoxylon* leaf extracts incubated with ruminal fluid. *Planta Medica* 1, 161–164.
- Boudry, G., Jury, J., Chang Yang, P., Perdue, M.H., 2007. Chronic psychological stress alters epithelial cell turn over in rat ileum. *American Journal of Physiology. Gastrointestinal and Liver Physiology* 292, 228–232.
- Campero, C.M., Odriozola, E., 1990. A case of *Solanum malacoxylon* toxicity in pigs. *Veterinary and Human Toxicology* 32, 238–239.
- Chappell, V.L., Thompson, M.D., Jeschke, M.G., Chung, D.H., Thomson, J.C., Wolf, S.E., 2003. Effects of incremental starvation on gut mucosa. *Digestive Diseases and Sciences* 48, 765–769.
- Dallorso, M.E., Gil, S., Pawlak, E., Lema, F., Marquez, A., 2001. 1,25 (OH)<sub>2</sub> vitamin D concentration in the plasma of *Solanum glaucophyllum*-treated rabbits. *Australian Veterinary Journal* 79, 419–423.
- Davies, K.W., Heaney, R.P., Recker, R.R., Lappe, J.M., Barger-Lux, M.J., Rafferty, K., Hinders, S., 2000. Calcium intake and body weight. *Journal of Clinical Endocrinology and Metabolism* 85, 4635–4638.
- Díaz, G.D., Paraskeva, C., Thomas, M.G., Binderup, L., Hague, A., 2000. Apoptosis is induced by the active metabolite of vitamin D<sub>3</sub> and its analogue EB1089 in colorectal adenoma and carcinoma cells: possible implications for prevention and therapy. *Cancer Research* 60, 2304–2312.
- Drozdowski, L., Thomson, A.B., 2006. Intestinal mucosal adaptation. *World Journal of Gastroenterology* 12, 4614–4627.
- Duncan, W.E., Walsh, P.G., Kowalski, M.A., Haddad, J.G., 1984. Ontogenesis of the rabbit intestinal receptor for 1, 25-dihydroxyvitamin D<sub>3</sub>—evidence for increased receptor content during late suckling and lactating periods. *Comparative Biochemistry and Physiology. A, Comparative Physiology* 78, 333–336.
- Fontana, P.A., Zanuzzi, C.N., 2007. Cambios estructurales y funcionales de órganos y células del sistema inmune de bovinos experimentalmente intoxicados con *Solanum glaucophyllum*. *Revista de Medicina Veterinaria* 88, 47–56.
- Fontana, P.A., 2010. Evaluación morfológica y funcional del sistema inmune y de células asociadas al mismo, en animales intoxicados con *Solanum glaucophyllum*. PhD degree thesis. School of Veterinary Medicine, National University of La Plata.
- Fontana, P.A., Zanuzzi, C.N., Barbeito, C.G., Gimeno, E.J., Portiansky, E.L., 2009. Evaluation of immunotoxic effects of plant-induced hypervitaminosis D on cattle thymus. *Pesquisa Veterinária Brasileira* 27, 267–275.
- Gimeno, E.J., Costa, E.F., Gomar, M.S., Massone, A.R., Portiansky, E.L., 2000. Effects of plant-induced hypervitaminosis D on cutaneous structure, cell differentiation and cell proliferation in cattle. *Journal of Veterinary Medicine A* 47, 201–211.
- Gimeno, E.J., Portiansky, E.L., Gomar, V., Costa, E.F., Massone, A.R., Alonso, C.R., Dallorso, M.E., Barros, S.S., 2004. Calcinosis in ruminants due to plant poisoning. Contributions on the pathogenesis. In: Acamovic, T., Stewart, C.S., Pennycott, T.W. (Eds.), *Poisonous plants and related toxins (CAB-International): Commonwealth Agricultural Bureau*. Cambridge, MA, USA, pp. 84–89.
- Gomar, M.S., 2006. Efectos de la hipervitaminosis D vegetal en la diferenciación y proliferación celulares cutáneas, aéreas y pulmonares del conejo. Doctoral Thesis, School of Veterinary Sciences, National University of La Plata, 2006.
- Greant, P., Delvaux, G., Willems, G., 1988. Influence of stress on epithelial cell proliferation in the gut mucosa of rats. *Digestion* 40, 212–218.
- Heaney, R.P., Davies, K.M., Barger-Lux, M.J., 2002. Calcium and Weight: Clinical studies. *Journal of American College of Nutrition* 21, 152–155.
- Heczko, U., Carthy, C.M., O'Brien, B.A., Finlay, B.B., 2001. Decreased apoptosis in the ileum and ileal Peyer's patches: a feature after infection with rabbit enteropathogenic *Escherichia coli* O103. *Infection and Immunity* 69, 4580–4589.
- Holt, P.R., Wu, S., Yeh, K.Y., 1986. Ileal hyperplastic response to starvation in the rat. *American Journal of Physiology* 251, 124–131.
- Holt, P.R., Arber, N., Halmos, B., Forde, K., Kissileff, H., McGlynn, K.A., Moss, S.F., Fan, K., Yang, K., Lipkin, M., 2002. Colonic epithelial cell proliferation decreases with increasing levels of serum 25-hydroxy vitamin D. *Cancer Epidemiology, Biomarkers and Prevention* 11, 113–119.
- Holt, P.R., Bresalier, R.S., Ma, C.K., Liu, K.F., Lipkin, M., Byrd, J.C., Yang, K., 2006. Calcium plus vitamin D alters preneoplastic features of colorectal adenomas and rectal mucosa. *Cancer* 106, 287–296.
- Kong, J., Zhang, Z., Musch, M.W., Ning, G., Sun, J., Hart, J., Bissonnette, M., Li, Y.C., 2008. Novel role of the vitamin D receptor in maintaining the integrity of the intestinal mucosal barrier. *American Journal of Physiology. Gastrointestinal and Liver Physiology* 294, 208–216.
- Kutuzova, G.D., DeLuca, H.F., 2007. 1,25-Dihydroxyvitamin D<sub>3</sub> regulates genes responsible for detoxification in intestine. *Toxicology and Applied Pharmacology* 218, 37–44.
- Lanske, B., Razaque, M.S., 2007. Premature aging in klothe mutant mice: Cause or consequence? *Ageing Research Reviews* 6, 73–79.
- Liesegang, A., Riner, K., Boos, A., 2007. Effects of gestation and lactation on vitamin D receptor amounts in goat and sheep. *Domestic Animal Endocrinology* 33, 190–202.
- Medici, D., Razaque, M.S., DeLuca, S., Rector, T.L., Hou, B., Kang, K., Goetz, R., Mohammadi, M., Kuro-O, M., Olsen, B.R., Lanske, B., 2008. FGF-23-Klotho signaling stimulates proliferation and prevents vitamin D-induced apoptosis. *The Journal of Cell Biology* 182, 459–465.
- Mello, J.R.B., Habermehl, G., 1992. Kalzinogene Pflanzen und der Inkubations Effekt durch Pansensatz. *Dtsch Tierärztl Wochenschr* 99, 353–392.
- Mello, J.R.B., 2003. Calcinosis-calcinogenic plants. *Toxicon* 41, 1–12.
- Menard, D., Levy, E., Delvin, E.E., 1995. Effects of calcitriol on proliferation and differentiation of human fetal jejunum. *Biology of the Neonate* 68, 157–162.
- Newmark, H.L., Lipkin, M., 1992. Calcium, vitamin D and colon cancer. *Cancer Research* 52, 2067–2070.
- Park, J.M., Kakimoto, T., Kuroki, T., Shiraiishi, R., Fujise, T., Iwakiri, R., Fujimoto, K., 2008. Suppression of intestinal mucosal apoptosis by ghrelin in fasting rats. *Experimental Biology and Medicine* 233, 48–56.
- Portiansky, E.L., Alonso, C.R., Costa, E.F., Gimeno, E.J., 2002. Collagenous and elastic system fibres in the aorta of cattle poisoned by *Solanum glaucophyllum*. *Veterinary Record* 150, 42–45.
- Potten, C.S., 1991. Regeneration in epithelial proliferative units as exemplified by small intestinal crypts. *Ciba Foundation Symposium* 160, 54–71.
- Potten, C.S., Wilson, J.W., Booth, C., 1997. Regulation and significance of apoptosis in the stem cells of the gastrointestinal epithelium. *Stem Cells* 15, 82–93.
- Puche, R.C., Masoni, A.M., Alloatti, D.A., Roveri, E., 1981. The antirachitic activity of *Solanum glaucophyllum* leaves. *Planta Medica* 40, 378–381.
- Razaque, M.S., Lanske, B., 2006. Hypervitaminosis D and premature aging: lessons learned from Fgf23 and Klotho mutant mice. *Trends in Molecular Medicine* 12, 298–305.
- Riner, K., Boos, A., Hässig, M., Liesegang, A., 2008. Vitamin D receptor distribution in intestines of domesticated sheep *Ovis ammon faries*. *Journal of Morphology* 269, 144–152.
- Rodrigues, M.A., de Camargo, J.L., Coelho, K.I., Montenegro, M.R., Angeleli, A.Y., Burini, R.C., 1985. Morphometric study of the small intestinal mucosa in young, adult, and old rats submitted to protein deficiency and rehabilitation. *Gut* 26, 816–821.
- Ruager, J., Gimeno, E.J., 1977. Enteque Seco en equinos, caprinos y ovinos. *Gaceta Veterinaria* 39, 597–599.
- Sadava, D., Remer, T., Petersen, K., 1996. Hyperplasia, hyperproliferation and decreased migration rate of colonic epithelial cells in mice fed a diet deficient in vitamin D. *Biocell* 87, 113–115.
- Suda, T., Shinki, T., Takahashi, N., 1990. The role of vitamin D in bone and intestinal cell differentiation. *Annual Review of Nutrition* 10, 195–211.
- Taylor, C.R., Shi, S.R., Chen, C., Young, L., Yang, C., Cote, R.J., 1996. Comparative study of antigen retrieval heating methods: microwave, microwave and pressure cooker, autoclave, and steamer. *Biotechnical and Histochemistry* 71, 263–270.
- Thomas, M.G., Tebbutt, S., Williams, R.C.N., 1992. Vitamin D and its metabolites inhibit cell proliferation in human rectal mucosa and a colon cancer cell line. *Gut* 33, 1660–1663.
- Verburg, M., Renes, I.B., Meijer, H.P., Taminiau, J.A.J.M., Büller, H.Á., Einerhand, A.W.C., Dekker, J., 2000. Selective sparing of goblet cells and Paneth cells in the intestine of metrotrexate-treated rats. *American Journal of Physiology. Gastrointestinal and Liver Physiology* 279, 1037–1047.
- Wada, Y., Mori, K., Iwanaga, T., 1997. Apoptosis of enterocytes induced by inoculation of a strain of attaching and effacing *Escherichia coli* and verotoxin. *Journal of Veterinary Medical Science* 59, 815–818.
- Wasserman, R.H., 1974. Calcium absorption and calcium binding protein synthesis: *Solanum malacoxylon* reverses strontium inhibition. *Science* 183, 1092–1094.
- Wesley, J.P., Watanuki, M., Shevde, N.K., 2006. Vitamin D<sub>3</sub>: synthesis, actions, and mechanisms in the intestine and colon. In: Johnson, L. (Ed.), *Physiology of the gastrointestinal tract*. Editorial Elsevier Academic Press, Amsterdam, pp. 1753–1771, 4th Ed.
- Worker, N.A., Carrillo, B.J., 1967. "Enteque seco", calcification and wasting in grazing animals in the Argentine. *Nature* 215, 72–74.
- Zanuzzi, C.N., Fontana, P.A., Barbeito, C.G., Portiansky, E.L., Gimeno, E.J., 2008. Paneth cells: histochemical and morphometric study in control and *Solanum glaucophyllum*-treated rabbits. *European Journal of Histochemistry* 52, 93–100.
- Zanuzzi, C.N., Barbeito, C.G., Ortiz, M.L., Lozza, F.A., Fontana, P.A., Portiansky, E.L., Gimeno, E.J., 2010. Glycoconjugate histochemistry in the small and large intestine of normal and *Solanum glaucophyllum*-treated rabbits. *Research in Veterinary Science* 89, 214–222.