

Senna occidentalis poisoning in cattle: report of 8 outbreaks in northwestern Argentina

August 2024

Ovelar, F.¹; Medina, D.M.^{2,3}; Colque-Caro, L.A.^{2,4}; Avellaneda-Cáceres, A.^{2,4}; Aguirre, L.S.^{2,3,4}; Sandoval, G.V.^{2,3,4}; Ruiz, A.F.^{1,2}; Micheloud, J.F.^{2,3,4}

ABSTRACT

Senna occidentalis is one of the many *Senna* species present in Argentina known for its toxicity to cardiac muscles and large muscle masses. However, there are only a few reports about *S. occidentalis* poisoning in cattle to date in Argentina. This work aims to describe a retrospective study, which includes 8 outbreaks of *S. occidentalis* poisoning in cattle from northwestern Argentina. The clinical, pathological, and epidemiological aspects of each outbreak were also detailed. The affected animals showed weakness, incoordination, and myoclonus of large muscle masses. Some animals also showed non-specific clinical signs like depression, anorexia, weight loss, and recumbency before death. The main macroscopic finding was muscle necrosis in large muscle masses and the histological findings included multifocal segmental degeneration and necrosis of muscle fibers. Serum samples collected from the necropsied animals showed a high CPK activity in the most acute cases.

Keywords: myotoxicity, bovine, toxic plant, creatine phosphokinase.

RESUMEN

Senna occidentalis es una de las muchas especies de *Senna* presentes en Argentina, conocida por su toxicidad para los músculos cardíacos y las grandes masas musculares. Sin embargo, existen pocos informes sobre la intoxicación por *S. occidentalis* en bovinos en Argentina. Este trabajo tiene como objetivo describir un estudio retrospectivo que incluye brotes de intoxicación por *S. occidentalis* en bovinos del noroeste argentino. También se detallaron los aspectos clínicos, patológicos y epidemiológicos de cada brote. Los animales afectados mostraron debilidad, incoordinación y mioclonías de las grandes masas musculares. Algunos también mostraron signos clínicos inespecíficos como depresión, anorexia, pérdida de peso y decúbito antes de morir. El principal hallazgo macroscópico fue una necrosis muscular en las grandes masas musculares, y los hallazgos histológicos incluyeron degeneración segmentaria multifocal y necrosis de las fibras musculares. Las muestras de suero recolectadas de los animales a los que se les realizó necropsia mostraron niveles altos de CPK en los casos más agudos.

Palabras clave: miotoxicidad, bovinos, planta tóxica, creatinfosfoquinasa.

¹Universidad Nacional del Nordeste (UNNE), Facultad de Ciencias Veterinarias, Sargento Cabral 2139 (3400), Corrientes, Argentina.

²Instituto Nacional de Tecnología Agropecuaria (INTA), Instituto de Investigación Animal del Chaco Semiárido, Área de Investigación en Salud Animal, (CIAP), Estación Experimental Agropecuaria (EEA) Salta, Ruta Nacional 68 km 172 (4403) Cerrillos, Salta, Argentina. Correo electrónico: micheloud.juan@inta.gob.ar

³Universidad Católica de Salta, Facultad de Ciencias Agrarias y Veterinarias, Campo Castañares (A4400EDD) Salta, Argentina.

⁴Consejo Nacional de Investigaciones Científicas y técnicas (CONICET).

INTRODUCTION

The ingestion of *S. occidentalis* produces poisoning characterized by myopathy and, less frequently, by degenerative cardiomyopathy (Martins *et al.*, 1986; Barros *et al.*, 1990, 1999; Carmo *et al.*, 2011). This plant is common to several environments in northern Argentina (Chileski *et al.*, 2021) and is normally found in pastures, in fertile soils, along roads, corrals, or contaminating soybean, corn, and sorghum crops (Barros *et al.*, 1990).

In Argentina, poisoning by this species has been described, in some cases, as isolated toxicity problems (Marín, 2010; Gual *et al.*, 2012; Mussart *et al.*, 2013). However, the information on this subject is limited in our country. In Brazil, *S. occidentalis* poisoning in cattle has been reported in Rio Grande do Sul and was associated with the direct consumption of the plant or after the use of feed contaminated with the seeds of the plant (Barros *et al.*, 1990, 1999; Carmo *et al.*, 2011; Takeuti *et al.*, 2011; Riet-Correa *et al.*, 2023).

As with other plant species, several factors can affect the probability of occurrence of outbreaks due to the consumption of *S. occidentalis* in cattle (Carmo, 2011; Chileski *et al.*, 2021), such as variations in the toxicity of the plant due to its phenological stage, or the occurrence of special management conditions that may facilitate the plant being ingested by animals (Riet-Correa *et al.*, 2023). These management factors may include feed restrictions, lack of forage, prolonged drought, prolonged transport or confinement of animals, and unfamiliarity with the

plant. All these factors may predispose to the occurrence of this or other intoxications (Tokarnia *et al.*, 2012).

This work aims to describe a sequence of 8 cases of poisoning by *S. occidentalis* in northwestern Argentina. Clinical, pathological, and epidemiological aspects of these cases are highlighted.

MATERIALS AND METHODS

A retrospective study of the cases of poisoning by *S. occidentalis* was carried out at the Animal Health Research Area "Dr. Bernardo Carrillo" of IIACS Salta of the Agricultural Research Center of INTA. For the diagnosis, the presence of compatible muscular lesions was considered and later associated with the finding of the plant and evidence of its consumption. The data from the corresponding reports was analyzed by compiling information on the clinical, pathological, and epidemiological aspects of the outbreaks.

RESULTS

Throughout 2015-2023, 8 outbreaks of *S. occidentalis* poisoning were confirmed out of the 430 cases seen in cattle in that period. This represents 1.8% of the bovine cases received by the laboratory. The diagnosis of *S. occidentalis* poisoning (fig.




Figure 1. **A.** Adult *Senna occidentalis* plant in the fruiting stage. The insert shows the flowers and pods in erect position, which are distinctive for field identification. **B.** Affected animal in sternal recumbency with normal sensory status and inability to sit up. However, they keep the ability to eat and drink until their death. **C.** Striated skeletal muscle (triceps brachii) with degeneration and diffuse necrosis with an appearance resembling cooked meat. **D.** Dark-colored urine resulting from myoglobinuria.

1 A) was based on clinical findings, along with the presence of monophasic muscle necrosis in large muscle masses, which was associated with the identification of the plant in grazing areas with evidence of its consumption.

The clinical findings included paraparesis of muscular origin, characterized by weakness, incoordination of the extremities, myoclonus of large muscle masses, and difficulty in moving. The animals then remained in sternal or lateral decubitus position until death ensued. Some animals showed depression, anorexia, and weight loss, finally progressing to sternal recumbency, unable to sit up, but alert, and able to eat and drink water until they died (fig. 1 B). In all the clinical cases recorded, the average evolution of the disease occurred in 4.5 ± 3.9 days, with a maximum of 12 days.

Serum samples were collected from 12 animals and serum creatine phosphokinase (CPK) activity was determined. The variations in its values according to the time of evolution of each clinical case are shown in fig. 2.

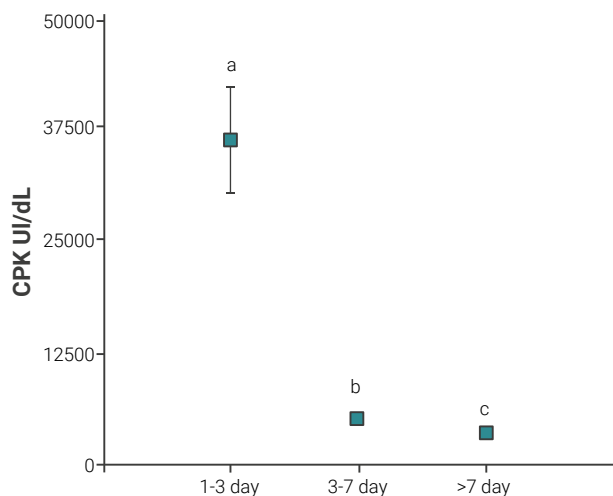


Figure 2. Creatine phosphokinase (CPK) levels in cattle according to different evolution times. The different letters indicate significant differences between groups.

Additionally, a total of 14 necropsies were performed. In all of them, degeneration and necrosis of the large muscle masses in the buttocks and forelimbs were identified. The lesions were characterized by an accentuated pallor of extensive muscular areas in the more rapidly evolving cases. These lesions were very noticeable in the quadriceps femoris, semitendinosus, semimembranosus, and triceps. They either had a homogeneous “cooked meat” appearance (fig. 1 C) or a striated appearance, involving several muscle fascicles. In cases of longer evolution (more than one week), the damaged areas had a focal distribution, mainly affecting the semimembranosus and semitendinosus muscles. In a single case, a cardiac lesion, characterized by a small area of affected right ventricular myocardium, was observed. In the animals that died more rapidly, hepatomegaly with an accentuated lobular pattern of the parenchyma was also observed. In these cases, the urine had a dark coloration due to myoglobinuria (fig. 1 D). In several cases with shorter evolutions, seeds or fragments of the sheaths of the plant were observed in the ruminal or abomasal contents.

Microscopically, the muscle lesions were characterized by multifocal segmental degeneration and necrosis of muscle fibers (fig. 3. A B). The lesions were monophasic or polyphasic depending on the case. In the most acute cases (1-2 days of evolution), the lesions were of the diffuse monophasic type, while in the cases in which the evolution took longer, the distribution was of the multifocal polyphasic type. The liver presented centrilobular congestion and diffuse vacuolization of hepatocytes. In one case, small areas of focal necrosis were identified.

The epidemiological data of the recorded outbreaks are described in table 1—the date on which they occurred, the category affected, the place where they occurred, the incidence of the outbreak, and the conditions under which the outbreaks occurred.

DISCUSSION AND CONCLUSIONS

Senna occidentalis poisoning is a relatively common disease in Brazil and Argentina (Riet Correa *et al.*, 2023). However, due to the wide distribution of the plant, outbreaks are expected to occur in other South American countries as well. Other species of this genus have been associated with poisoning in cattle,

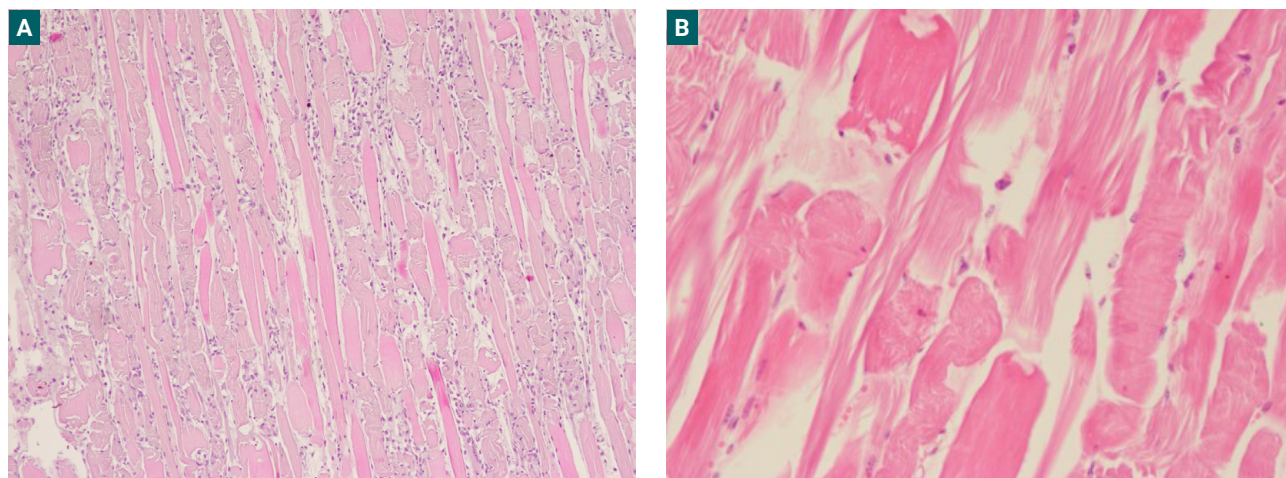


Figure 3. A. Histology of skeletal muscle showing segmental degenerative myopathy. A diffuse lesion with swelling, hyalinization, and fragmentation of myofibrils with macrophage infiltration and myoblast proliferation is observed (H&E, 4X). **B.** Severe fragmentation and hyalinization of muscle fibers with the formation of contraction bands and fibrin floccules (H&E, 20X).

Case	Outbreak location	Date of outbreak	Affected categories	Cumulative incidence	Cumulative mortality	Context
1	Rosario de la Frontera, Salta	set/21	Cows and Bulls	3,7	0,23	The animals were in a corn stubble field with good feed availability. In one area of the paddock, abundant <i>S. occidentalis</i> plants were found.
2	San Pedro de Colalao, Tucumán	mai/22	Calves	1,33	1,33	The animals were put in pens with corn silage, grain, and mineral supplementation. In those pens, abundant fruiting <i>S. occidentalis</i> were present. The first affected animals were observed 3 days later.
3	Joaquín V. Gonzalez, Salta	mai/21	Cows and calves	2,5	2,5	The animals were enclosed in a paddock with a large amount of fruiting <i>S. occidentalis</i> . The next day, some affected animals appeared and despite having been moved, more affected animals continued to appear during the following week.
4	Taco Pozo, Chaco	out/19	Steers and heifers	10	10	The animals were placed in a confinement pen. During that time, they were fed corn and protein concentrate. The first affected animals were observed 6 to 7 days after confinement. <i>S. occidentalis</i> seeds were identified mixed with the corn gains.
5	Weisburd, Santiago del Estero	mai/22	Calves	4,5	4,5	After weaning, the animals were introduced to a pen with a large number of fruiting <i>S. occidentalis</i> plants. After 4 to 5 days, affected animals began to be observed.
6	Bobadal, Santiago del Estero	mai/18	Steers	28,6	28,6	The animals were taken to a paddock with low feed availability, but with abundant presence of fruiting <i>S. occidentalis</i> . The first affected animals were observed one week later.
7	El Carril, Salta	mai/14	Cows	4,16	3,3	The cows entered a paddock with little forage supply. Areas with fruiting <i>S. occidentalis</i> were found in that paddock. Several animals died sporadically over a period of 45 days.
8	Metán, Salta	Aug 2014	Heifers	7,7	7,7	The animals were put in a confinement pen and fed with a balanced ration. Several <i>S. occidentalis</i> plant shoots were found under the feeders with evidence of having been consumed.

Table 1. Epidemiological characteristics of the outbreaks, highlighting the place and date of occurrence, the affected category, the incidence and mortality rate, and the management measures under which the outbreaks occurred.

such as *S. obtusifolia* in cattle from Brazil (Carvalho *et al.*, 2014; Furlan *et al.*, 2014) and *Senna cobanensis* in calves from Costa Rica (Vargas-Muñoz *et al.*, 2023).

According to the data recorded in Brazil, poisoning by some of the *Senna* species mentioned above usually occurs in cattle older than one year, in the form of outbreaks, affecting from 2% to 62% of the herd (Carmo *et al.*, 2011; Carvalho *et al.*, 2014; Furlan *et al.*, 2014). The same authors report mortality levels between 5% to 58%. In our work, incidence rates ranged from 1.3 to 28%, with an average value of $7.3 \pm 9.2\%$ and lethality of almost 100% in all cases. As mentioned in the literature, the most affected categories included animals older than 1 year (bulls, cows, and heifers) and the presence of affected calves was recorded in only two of the described outbreaks.

All the clinical findings mentioned in this report coincide with those mentioned by other authors (Barros *et al.*, 1990, 1999; Carmo *et al.*, 2011; Furlan *et al.*, 2012; Purisco and Lemos, 2002). The clinical signs were quite unspecific initially. In some cases, and depending on the dose of the plant consumed, the animals died quickly. Pathologically, the most important findings were muscle degeneration and necrosis, present mostly in the forelimb and hind limb regions. These findings are similar to those described in the poisoning by other species of the genus *Senna* (Furlan *et al.*, 2014; Vargas-Muñoz *et al.*, 2023). As mentioned by several authors, CPK elevation is a relevant and indicative finding for diagnosis (Furlan *et al.*, 2014; Mus-sart *et al.*, 2013; Purisco and Lemos, 2002) and this result coincides with the findings observed in our study, where mean

CPK values were 18948 ± 19230 IU/dL. However, it should be considered that there are variations according to the evolution of each clinical case. For example, it was observed that, during the first 3 days post intoxication, CPK levels were quite high ($CPK=36399 \pm 14326$ IU/dL), and then they fell progressively in the first week ($CPK=4979 \pm 1287$ IU/dL) and continued to do so for the rest of the disease. Although this enzyme remained elevated after 7 days of plant consumption ($CPK=3250 \pm 1808$ IU/dL), the levels were not high enough to reach a diagnosis, especially in animals that had been lying on the ground for a while. Microscopically, the muscle lesions were characterized by the presence of mono or polyphasic multifocal degeneration according to the evolution of the clinical case (Barros *et al.*, 1990, 1999; Carmo *et al.*, 2011). Ultra-structurally, these lesions consisted mainly of mitochondrial alterations. The mitochondria were usually swollen, with signs of rupture and destruction of the inner membrane ridges and the formation of electron-dense inclusions associated with the formation of pseudo-myelinated structures (Barros *et al.*, 1990).

There are still several unanswered questions about the toxic principles of *S. occidentalis*. Several potentially toxic compounds have been isolated, including an alkaloid, a toxalbumin, and several anthraquinone derivatives. The latter compounds have been associated with muscle injury (Chileski *et al.*, 2021; Carmo *et al.*, 2011; Haraguchi *et al.*, 1996); however, we cannot be conclusive in this regard. Toxic doses of the plant vary widely among animal species, and it is known that it can have a cumulative effect, as some animals become ill several days after ingesting the plant (Barros *et al.*, 1990; Irigoien *et al.*, 1991).

According to the data recorded in Rio Grande do Sul, intoxication in grazing cattle is observed in late autumn and early winter, between April and July (Barros *et al.*, 1990; Carmo *et al.*, 2011). In this case, there seem to be two differentiable moments in which poisoning occurs: one at the end of autumn/beginning of winter (May) and the other at the end of winter/beginning of spring, when the plant is resprouting (August, September, and October). Cases occurring in late winter/early spring are less frequent and occur due to seed consumption or plant regrowth in the paddocks. The most important outbreaks occur with the consumption of mature seeded plants, probably because, although all parts of the plant are toxic, the seeds of *S. occidentalis* are the most toxic part of this species (Carmo, 2011; Chileski *et al.*, 2021; Furlan *et al.*, 2014).

Finally, it is important to note that plant poisonings are an ongoing problem for livestock throughout South America (Riet-Correa *et al.*, 2023). However, despite their impact, the literature on this subject is very restricted and is usually limited to the description of isolated cases. The epidemiological aspects described in this work contribute to the knowledge of *S. occidentalis* poisoning in northwestern Argentina and may be useful to mitigate the losses caused by this plant. Further studies on this problem in Argentina are needed.

REFERENCES

BARROS, C.S.L.; PILATI, C.; ANDUJAR, M.B.; GRAÇA, D.L.; IRIGOYEN, L.F.; LOPES, S.T.; SANTOS, C.P. 1990. Intoxicación por *Cassia occidentalis* (Leg. Caes.) em bovinos. *Pesq. Vet. Bras.* 10: 47-58.

BARROS, C.S.; ILHA, M.R.S.; BEZERRA JUNIOR, P.S.; LANGOHR, I.M.; KOMMERS, G.D. 1999. Intoxicación por *Senna occidentalis* (Leg. Caesalpinioideae) em bovinos em pastoreio. *Pesquisa Veterinária Brasileira*, 19, 68-70.

CARMO, P.; IRIGOYEN, L.F.; LUCENA, R.B.; FIGHERA, R.A.; KOMMERS, G.D.; BARROS, C.S. 2011. Spontaneous coffee senna poisoning in cattle: report on 16 outbreaks. *Pesquisa Veterinária Brasileira*, 31, 139-146.

CARVALHO, A.Q.D.; CARVALHO, N.M.; VIEIRA, G.P.; DOS SANTOS, A.C.; FRANCO, G.L.; POTT, A.; BARROS, C.S.L.; LEMOS, R.A. 2014. Intoxicación espontânea por *Senna obtusifolia* em bovinos no Pantanal Sul-Mato-Grossense. *Pesquisa Veterinária Brasileira*, 34, 147-152.

CHILESKI, G.S.; RIOS, E.E.; LÉRTORA, W.J.; TEIBLER, P.G.; PARADA, J.; CHOLICH, L.A. 2018a. Miopatía tóxica en cerdos intoxicados experimentalmente a partir del consumo de frutos de *Senna occidentalis*. *Rev. investig. vet. Perú.* 5(3), 782-789. 312 <http://dx.doi.org/10.15381/rivep.v29i3.14760>

FERREIRA NETO, P.G.; LEMOS, R.; MORI, A.; GUIMARÃES, E. 2004. Intoxicación por *Senna occidentalis* (Leg. Caesalpinioideae) em bovinos em pastoreio rotacionado. *Pesq. Vet. Bras.* 24(Supl): 22-23.

FURLAN, F.H.; COLODEL, E.M.; LEMOS, R.A.; CASTRO, M.B.; MENDONÇA, F.S.; RIET-CORREA, F. 2012. Poisonous plants affecting cattle in central-western Brazil. *International Journal of Poisonous Plant Research*, 2(1), 1-13.

FURLAN, F.H.; ZANATA, C.; DOS SANTOS DAMASCENO, E.; DE OLIVEIRA, L.P.; DA SILVA, L.A.; COLODEL, E.M.; RIET-CORREA, F. 2014. Toxic myopathy and acute hepatic necrosis in cattle caused by ingestion of *Senna obtusifolia* (sicklepod; coffee senna) in Brazil. *Toxicol.* 92, 24-30.

GUAL, I.; GATTI, J.E.; MICHELOUD, J.F.; ODRIOZOLA, E.; WEBER, N.; CAMPERO, C.M.; MORRELL, E.M. 2012. Presunta intoxicación con *Senna occidentalis* en terneros. Presentación a congreso. RAPAVE 2012, Córdoba, Argentina.

HARAGUCHI, M.; GORNIÁK, S.L.; DAGLI, M.L.Z. 1996. Determinação dos constituintes químicos das frações tóxicas de fedegoso (*Senna occidentalis* L.) Anais. Encontro Anual da Sociedade Brasileira de Química, 19, 96.

IRIGOYEN, L.F.; GRAÇA, D.L.; BARROS, C.S.L. 1991. Intoxicación experimental por *Cassia occidentalis* (Leg. Caes.) em equinos. *Pesq. Vet. Bras.* 11: 35-44.

MARIN, R.E. 2010. Miopatía tóxica en bovinos asociada al consumo de *Cassia occidentalis* en el norte de Salta. *Vet. argent.* 27 (267), 210-218.

MARTINS, E.; MARTINS, V.M.V.; RIET-CORREA, F.; SONCINI, R.A.; PARABONI, S.V. 1986. Intoxicación by *Cassia occidentalis* (Leguminosae) in swine. *Pesquisa Veterinária Brasileira (Brazil)*, 6(2).

MUSSART, N.B.; KOZA, G.A.; LÉRTORA, J.; ÁLVAREZ CHAMALE, G.M.; COPPO, J.A. 2013. Intoxicación por "cafetillo" (*Cassia occidentalis*) en bovinos del nordeste argentino. *Revista veterinaria*, 24(2), 138-143.

PURISCO, E.; LEMOS, R.A.A. 2002. Intoxicación por *Senna occidentalis*. In: LEMOS, R.A.A.; BARROS, N.; BRUM, K.B. (ed.). *Enfermidades de interesse econômico em bovinos de corte. Perguntas e respostas.* Editora UFMS, Campo Grande, 171-176 pp.

RIET-CORREA, F.; MACHADO, M.; MICHELOUD, J.F. 2023. Plants causing poisoning outbreaks of livestock in South America: a review. *Toxicol X.* <https://doi.org/10.1016/j.toxcx.2023.100150>

TAKEUTI, K.L.; RAYMUNDO, D.L.; BANDARRA, P.M.; DE OLIVEIRA, L.G.S.; BOABAI, F.M.; BARRETO, L.; DRIEMEIER, D. 2011. Surto de intoxicación por *Senna occidentalis* em bovinos em pastoreio. *Acta Scientiae Veterinariae*, 39(1), 1-4.

VARGAS-MUÑOZ, C.; VARGAS-MUÑOZ, M.; SÁNCHEZ-CHAVES, L.; ALFARO-ALARCÓN, A.; ALPÍZAR-SOLÍS, C.; LUNA-TORTÓS, C. 2023. Intoxicación por *Senna cocabensis* en terneros cebuinos: Primer reporte de caso. *Ciencias Veterinarias*, 41(1), 1-14.