

Clinical microbiology

Protective effect of a mixture of kefir-isolated lactic acid bacteria and yeasts in a hamster model of *Clostridium difficile* infection

Patricia A. Bolla^{a,b,*}, Paula Carasi^a, María de los Angeles Bolla^c, Graciela L. De Antoni^{a,b},
María de los Angeles Serradell^a

^a Cátedra de Microbiología, Departamento de Ciencias Biológicas, Facultad de Ciencias Exactas, Universidad Nacional de La Plata, Argentina

^b Centro de Investigación y Desarrollo en Criotecología de Alimentos (CIDCA), CCT La Plata, CONICET, Argentina

^c Servicio de Anatomía Patológica, Hospital Interzonal General de Agudos (H.I.G.A) "Profesor Dr. Rodolfo Rossi", La Plata, Buenos Aires, Argentina

ARTICLE INFO

Article history:

Received 3 December 2012

Received in revised form

18 March 2013

Accepted 22 March 2013

Available online 29 March 2013

Keywords:

C. difficile

Kefir

Hamsters

ABSTRACT

The objective of this work was to test the protective effect of a mixture (MM) constituted by kefir-isolated microorganisms (*Lactobacillus plantarum*, *Lactobacillus kefir*, *Lc. lactis*, *Kluyveromyces marxianus* and *Saccharomyces cerevisiae*) in a hamster model of infection with *Clostridium difficile*, an anaerobic Gram-positive bacterium that causes diarrhoea. Placebo or MM was administered *ad libitum* in drinking water from day 0 to the end of treatment. Hamsters received orally 200 µg of clindamycin at day 7 and then were infected with 1×10^8 CFU of *C. difficile* by gavage. Development of diarrhoea and death was registered until the end of the protocol. Surviving animals were sacrificed at day 16, and a test for biological activity of clostridial toxins and histological stainings were performed in caecum samples. Six of seven infected animals developed diarrhoea and 5/7 died at the end of the experimental protocol. The histological sections showed oedema and inflammatory infiltrates with neutrophils and crypt abscesses. In the group of animals infected and treated with MM_{1/1000}, only 1 of 7 hamsters showed diarrhoea and none of them died. The histological sections showed only a slight thickening of the mucosa with presence of lymphocytic infiltrate. These results demonstrate that an oral treatment with a mixture of kefir-isolated bacteria and yeasts was able to prevent diarrhoea and enterocolitis triggered by *C. difficile*.

© 2013 Elsevier Ltd. All rights reserved.

1. Introduction

Kefir is a food product obtained by fermentation of milk with a community of lactic acid bacteria, yeasts and acid acetic bacteria confined in a complex matrix of polysaccharides and proteins (kefir grains). Many different health-promoting properties have been associated to kefir consumption [1]. Has been demonstrated that of probiotic microorganisms are capable of inhibiting the detrimental effect of pathogens, enhance the intestinal barrier, and modulating the immune response [2,3].

Clostridium difficile is an anaerobic and spore-forming Gram-positive bacterium that causes a wide range of gastrointestinal diseases from mild diarrhoea to pseudomembranous colitis, mainly associated with antibiotic treatments. With the recent emergence of hypervirulent antibiotic-resistant strains, the incidence of *C. difficile*

associated diarrhoea is an increasing public health problem, particularly in both North America and Europe [4]. The alteration in the enteric microbiota due to antibiotic treatment allows the colonisation and growth of *C. difficile* in the gut. The main virulence factors of *C. difficile* are toxins A and B, but other factors such as adhesins and hydrolytic enzymes were also been described [5].

In the past few years, there has been a renewed interest in *C. difficile* infection due to the recognition that this disease is more common, more severe, and more resistant to standard treatment than previously reported [5]. Although prevention primarily revolves around control of antibiotic use, other potential factors have been explored, including the use of probiotic bacteria and yeast [6]. Regarding this issue, there are evidences of protective effects against *C. difficile* by different probiotic microorganisms using eukaryotic cell cultures [7–10] and distinct animal models [11–13]. Nevertheless, the efficacy of probiotics on the control of *C. difficile* infection in clinical trials is still inconclusive [14,15].

The studies using *in vivo* experimental models are the best way to understand the dynamic of host–pathogen interaction. Different animal models using guinea pig [16], rabbit [17], rat [11,18], mouse

* Corresponding author. Laboratorio de Microbiología, Departamento de Ciencias Biológicas, Facultad de Ciencias Exactas, Universidad Nacional de La Plata (UNLP), 47 y 115, La Plata 1900, Argentina. Tel.: +54 221 4250497; fax: +54 221 4890741.
E-mail address: pbolla@quimica.unlp.edu.ar (P.A. Bolla).

[11,19] and hamster [20–23] have been described. Among them, hamsters (*Mesocricetus auratus*) are considered one of the most important models because of their high sensibility to the infection and the similarity with human signs and symptoms (such as colitis, histological damage and relapse) [20,23].

Our group has been dedicated to the study of the probiotic and technological properties of kefir, and until now, we have isolated more than one hundred bacterial and yeast strains from different kefir grains [24–26]. Previous studies carried out in our laboratory demonstrated the ability of a mixture of kefir-isolated microorganisms (*Lactobacillus plantarum* CIDCA 83114, *Lactobacillus kefir* CIDCA 8348, *Lc. Lactis* CIDCA 8221, *Kluyveromyces marxianus* CIDCA 8154 and *Saccharomyces cerevisiae* CIDCA 8112) to inhibit the growth of *Shigella sonnei* *in vitro* [27] and also the cytotoxicity of *C. difficile* toxins on eukaryotic cells [28].

The objective of this work was to test the protective effect of a mixture of microorganisms isolated from kefir (two lactobacilli, one *Lactococcus* and two yeasts) on an animal model of infection with vegetative forms of *C. difficile*.

2. Methods

2.1. Microorganisms and growth conditions

In this study, the pure cultures used comprised *Lactococcus lactis sub lactis* CIDCA 8221, *L. plantarum* CIDCA 83114, *L. kefir* CIDCA 8348, *Kluyveromyces marxianus* CIDCA 8154 and *S. cerevisiae* CIDCA 8112. These strains were previously isolated from kefir grains and have been identified and characterised by Garrote et al. [24] and Delfederico et al. [25]. The original reference cultures were maintained in milk at -80°C . Both lactobacilli and yeasts were propagated in MRS-broth (DIFCO, Detroit, USA) for 48 h at 30°C . *Lc. lactis* was grown in 1.1.1 growth media (1% w/v of tryptone – Difco, Detroit, USA – 1% w/v of yeast extract – Biokard Diagnostic, Beauvais, France – and 1% w/v of lactose – Mann Research Laboratories, NY) Abraham et al. [29] for 24 h at 30°C . To obtain the microbial mixture (MM), same volume of each microbial suspension was centrifuged at 10,000 g for 15 min and all microorganisms were resuspended together in 50 mL of sterile PBS added with sterile 3 M sucrose. The resulting suspension was stored at -80°C until use. The final concentration of bacteria and yeasts in MM was 10^{11} CFU/mL and 10^8 CFU/mL respectively (*L. plantarum*: 1.2×10^{11} CFU/mL, *L. kefir*: 1.1×10^{11} CFU/mL *Lc. lactis* 1.2×10^{11} CFU/mL *K. marxianus*: 1.2×10^8 CFU/mL, *S. cerevisiae*: 1.3×10^8 CFU/mL).

The clinical isolate of *C. difficile* strain 117, obtained from the Hospital Dr. Muñiz (Buenos Aires, Argentina) and previously characterised as positive for TcdA and TcdB production, was grown for 24 h at 37°C in Brain Heart Infusion (BHI: Biokard Diagnostic, Beauvais, France) supplemented with 0.05% (w/v) cysteine chlorhydrate (BHI/cys) in anaerobic conditions (AnaeroPak, Mitshubishi Gas Chemical Co, Inc). The culture was centrifuged for 10 min at 12,000 g. The supernatant was discarded and the bacterial pellet was resuspended in sterile PBS at a concentration of 10^9 cells/mL.

2.2. Animals

Six- to eight-week female outbred Syrian hamsters (Golden, CPZ: SYR, *M. auratus*) were obtained from Laboratorio Azul Diagnóstico (Azul, Argentina). Hamsters were accustomed to their new environment for at least 10 days before the start of the experiments. Animals were maintained in a 12 h light/dark cycle and received conventional food and water *ad libitum*. All procedures were performed according to international guidelines for animal care.

2.3. Induction of *C. difficile* enterocolitis

Animals were infected with *C. difficile* strain 117, according to the protocol described by Trejo et al. [22] with some modifications. Briefly, animals received a single intra-gastric dose of 200 μg of clindamycin hydrochloride (ParaFarm, Argentina) prepared in PBS per animal (day 0). On day 4, animals were infected by gavage with 0.1 mL of *C. difficile* (1×10^8 bacteria/animal). Through the experimental period, we registered weight evolution, diarrhoea and death. Animals with signs of severe illness were sacrificed according to humanitarian endpoint. In those cases, cecal contents were taken during necropsy and conserved until use for determination of clostridial toxins level. Samples from animals that died spontaneously were not included in other assays. Finally, surviving animals were sacrificed on day 9 of the protocol in order to analyse clostridial toxins level and to perform histological analysis of cecal segments.

2.4. Microbial mixture (MM) treatment

The MM was prepared as described above. The administration of MM (dilution 1/100 and 1/1000) or placebo in drinking water started 11 days before infection. For this experimental protocol hamsters were divided in five groups containing 7 animals each: animals receiving MM and clindamycin (MMA); animals receiving MM, clindamycin and *C. difficile* by gavage (MMI); animals receiving placebo (0.3 M sucrose), clindamycin and *C. difficile* by gavage (CI); animals receiving placebo, clindamycin and PBS by gavage (CA); and animals receiving placebo and PBS by gavage (C).

2.5. Determination of clostridial toxins

To determine the presence of toxins from *C. difficile* strain 117, biological activity of cecal content was tested by cell detachment assay Trejo et al. [7] Briefly, monolayers of Vero cells were grown in Dulbecco's Modified Eagle's Medium (DMEM; Gibco BRL Life Technologies, Rockville, MD, USA) supplemented with 10% (v/v) of bovine foetal serum (BIOSER, Argentina, PAA Laboratories GmbH), 2 g/L NaHCO_3 , 10 mg/L streptomycin and 10 IU/mL penicillin G. Cells were inoculated (6.25×10^4 cells per well) into 48-well tissue culture plates (Corning, NY) and incubated at 37°C for 48 h in a 5% (v/v) CO_2 –95% (v/v) air atmosphere. Two hundred μl of twofold serial dilutions of 0.45 μm -filtered cecal contents (0.01% w/v) in DMEM without serum were added per well and incubated for 16 h at 37°C in a 5% (v/v) CO_2 –95% (v/v) air atmosphere. The clinical isolate of *C. difficile* was grown for 24 h at 37°C in Brain Heart Infusion (BHI: Biokard Diagnostic, Beauvais, France) supplemented with 0.5 g/L cysteine chlorhydrate (BHI/cys) in anaerobic conditions (AnaeroPak, Mitshubishi Gas Chemical Co, Inc). Culture was centrifuged at 15,000 g for 15 min and the *C. difficile* spent culture supernatant (SCS) containing toxins was retained and used in this experiment as a positive control of cytotoxic effect.

For cellular detachment assay, after incubation cells were washed twice with PBS and fixed with 2% (v/v) formaldehyde for 1 min [30]. The remaining cells were stained with 0.13 g/L Crystal Violet in 5% (v/v) ethanol and 2% (v/v) formaldehyde. Next, an extraction with 50% (v/v) ethanol was performed and OD_{540} was determined.

2.6. Histological analysis of cecal segments

Cecal tissue samples from hamsters were resected and fixed in 10% neutral buffered formalin, routinely processed and embedded in Histoplast (Biopack, Argentina). Histological sections of 3–5 μm

were deparaffinized, hydrated and stained with haematoxylin-eosin for microscopic observation.

2.7. Statistical analysis

Statistical comparisons were made by analysis of variance (ANOVA). Significant differences were established by Fisher's test.

3. Results

3.1. Induction of *C. difficile* enterocolitis

The infection with *C. difficile* strain 117 in clindamycin-treated hamsters (CI group) induced diarrhoea in 6 of 7 animals and five days after infection, only 2 animals survived (Table 1). This group began to show signs of lethargy, dehydration and diarrhoea after the third day post-infection. In agreement with these observations, an average weight loss of 20.1 ± 2.8 g per animal was registered for CI group in that period (data not shown). No signs of illness were observed in the uninfected controls that did not receive clindamycin (C group).

Regarding the effect of antibiotic administration, we observed that 5 of 7 hamsters developed diarrhoea in the uninfected control group that received antibiotic (CA group), 2 of which died before the end of the experimental protocol (Table 1).

3.2. Effect of treatment with MM on *C. difficile* enterocolitis outcome

To determine the dose of microbial mixture (MM) that was more effective to protect against *C. difficile* infection, we tested three different dilutions of MM administered in drinking water (1/100 and 1/1000). The treatment with MM_{1/100} did reduce neither the fraction of animals with diarrhoea nor the percentage of mortality produced by *C. difficile* infection (data not shown). However, the administration of MM_{1/1000} (containing 1×10^8 bacteria/mL and 1×10^5 yeast/mL) significantly reduced the amount of animals with diarrhoea after infection with *C. difficile*. All animals treated with MM_{1/1000} (MMI group) survived at the end of the protocol (Table 1).

Additionally, treatment with MM_{1/1000} reduced the damage induced by clindamycin administration (MMA group), since no signs of illness (diarrhoea or death) were observed in that group along the protocol (Table 1).

Taken together, these results strongly suggest that the mixture of kefir-isolated microorganisms, administered in the adequate dose protect against infection with *C. difficile* and also reduce the damage induced by antibiotic treatment.

3.3. Determination of biological activity of clostridial toxins

To determine whether the decrease in the development of *C. difficile* enterocolitis by treatment with MM_{1/1000} correlated with

Table 1
Effect of MM treatment in *C. difficile* enterocolitis outcome.^a

| Group | Diarrhoea | Dead animals |
|---|-----------|--------------|
| CI (placebo + ATB ^b + <i>C. difficile</i>) | 6/7 | 5/7 |
| MM _{1/100} (MM + ATB + <i>C. difficile</i>) | 6/7 | 6/7 |
| MMI _{1/1000} (MM + ATB + <i>C. difficile</i>) | 1/7 | 0/7 |
| MMA _{1/1000} (MM + ATB) | 0/7 | 0/7 |
| CA (placebo + ATB) | 5/7 | 2/7 |
| C (placebo) | 0/7 | 0/7 |

^a These results are representative of three independent experiments.

^b ATB: clindamycin (200 µg per animal).

a reduction of clostridial toxins in the caecum, we performed an *in vitro* assay to test the biological activity of TcdA and TcdB in faecal filtrates obtained from cecal contents. Fig. 1 shows the percentages of detached cells when the concentration of faecal filtrates was 5% v/v. Samples from animals belonging to the infected group (CI) showed activity associated to clostridial toxins (88.3 ± 9 , 8% of detached cells), meanwhile in the samples from infected animals treated with MM_{1/1000} (MMI group) the percentage of detached cells did not show significant differences to samples belonging to control animals (C, CA and MMA group) ($P < 0,05$).

3.4. Histological analysis

Fig. 2 shows the haematoxylin-eosin stained sections of cecal tissue from representative animals belonging to different groups under study. Histological analysis of acute colitis includes studying the following features: presence of: oedema, superficial mucosal ulcers, cryptitis and crypt abscesses, and lamina propria inflammation (with recruitment of neutrophils, lymphocytes, plasma cells and eosinophils, depending on the stage of the disease). In hamsters infected with *C. difficile* (CI group), we observed thickening of the mucosa, oedema (arrow "e") and an inflammatory infiltrate with a predominance of neutrophils (arrow "ii") and cryptic abscesses (arrow "ca") (panels A, A'). Animals that only received clindamycin (CA group), show a chronic inflammation with an infiltration of lymphocytes (panels B and B'). The group of hamsters treated with MM_{1/1000} and then infected with *C. difficile* (MMI group) did not develop acute colitis, although a slight thickening of the mucosa could be observed due to mild inflammatory infiltrates of lymphocytes (panels C, C'). Untreated control animals (C group) and animals from MMA group showed normal histological features and preserve the thickness of the mucosa (panels D and D'). According to these results we can conclude that the oral administration of MM protects hamsters from acute injury due to antibiotic and *C. difficile* infection.

4. Discussion

Probiotics are being used with increasing frequency as a treatment for several medical conditions such allergic diseases, bacterial vaginosis, urinary and gastrointestinal tract infections [31]. Several studies have used probiotics such as *Saccharomyces boulardii* and *L. rhamnosus* GG for the prevention of antibiotic-associated diarrhoea (AAD) or *C. difficile*-associated diarrhoea (CDAD) [6,32,33]. Hickson et al. [34] reported the effectiveness of a preparation containing

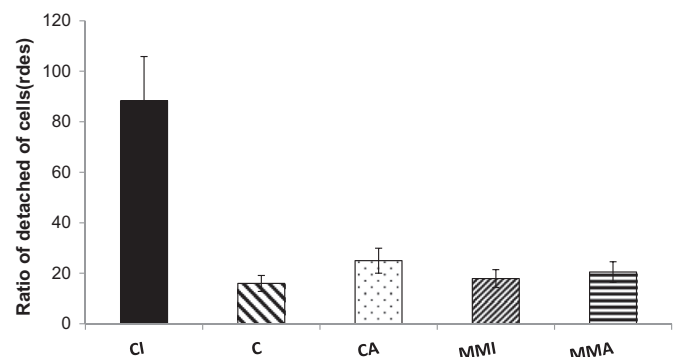


Fig. 1. Biological activity of toxins by *C. difficile* using Vero cells. Hamsters receiving placebo and infected with *C. difficile* 117 (CI group) ■; animals that only received placebo (C group) □; animals that received placebo and clindamycin (CA group) ▨; hamsters treated with MM, that received clindamycin and were infected with *C. difficile* 117 (MMI group) ▩; hamster treated with the MM, that received clindamycin (MMA) ▤. The results shown here are representative of two independent experiments. * $P < 0.05$.

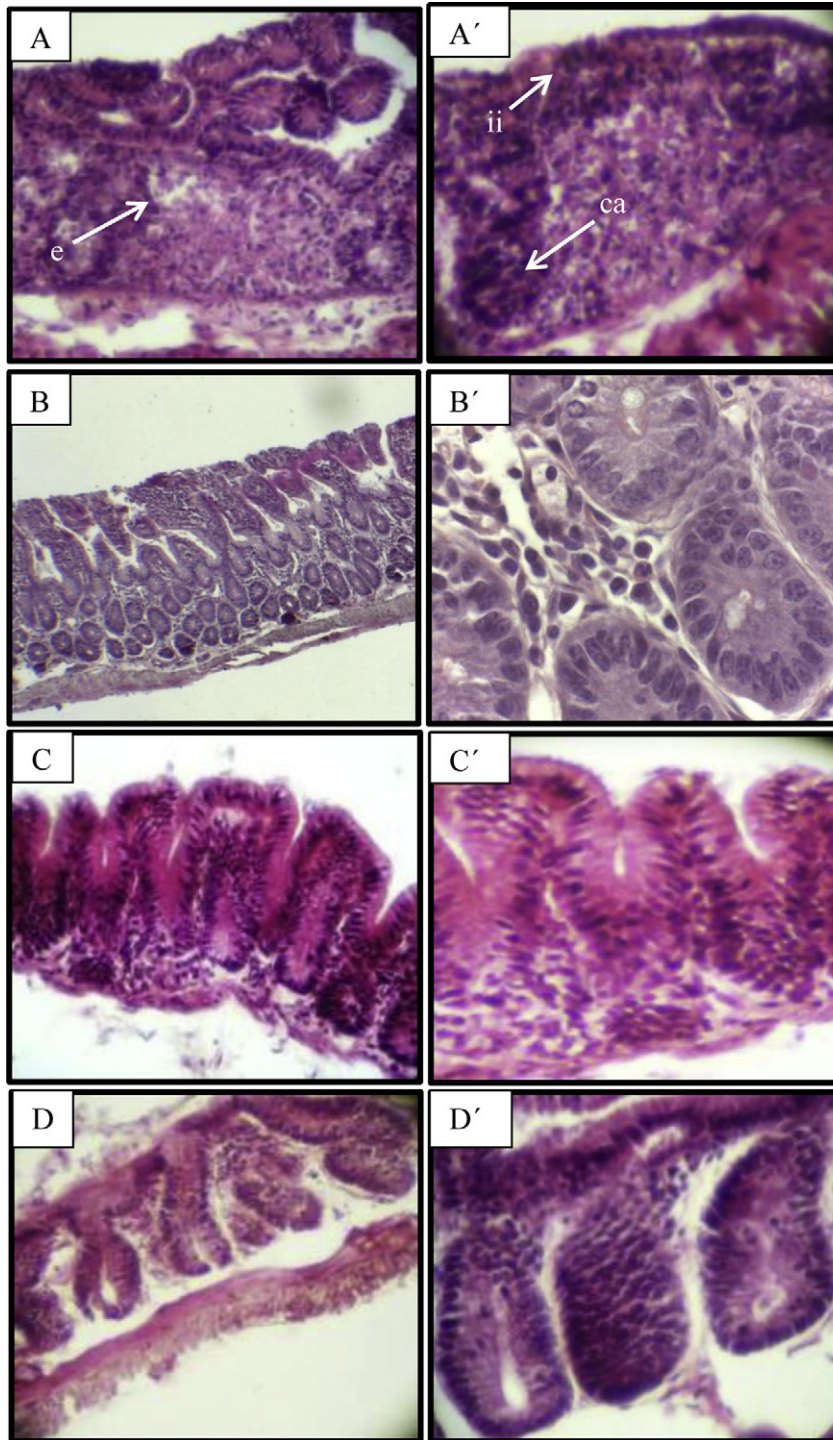


Fig. 2. Haematoxylin-eosin staining of the cecal tissues. Hamsters receiving placebo and infected with *C. difficile* 117 (CI group) – panels A, A'; animals that received placebo and clindamycin (CA group) – panels B, B'; hamsters treated with MM, that received clindamycin and were infected with *C. difficile* 117 (MMI group) – panels C, C'; animals that only received placebo (C group) – panels D, D'. A, B, C: 100X; A', B', C': 400X. e: oedema; ii: inflammatory infiltrate; c: cryptic abscess.

L. casei, *S. thermophilus* and *L. bulgaricus* against CDAD in clinical trials. In this work, we demonstrated the protective effect of a mixture constituted by bacterial and yeast strains isolated from kefir-fermented milk against *C. difficile* infection in a hamster model.

The hamster is regarded as an important model of *C. difficile* disease since many of the clinical symptoms observed in humans can also be observed in the model [21]. After administration of clindamycin and challenge with toxigenic strains of *C. difficile*,

hamsters develop a haemorrhagic caecitis, manifested as “wet tail” (a sign of diarrhoea) which is mainly followed by death [23]. Although, animals could die without signs of diarrhoea when infected with highly virulent strains of *C. difficile* [35,36]. Regarding these features, our model of infection worked as expected, since 6 of 7 hamsters infected with the *C. difficile* strain 117 developed diarrhoea, and 5 of them finally died before the end of the experiment. On the other hand, only 1 of 7 animals belonging to the

group treated with MM_{1/1000} showed signs of diarrhoea after infection and none of them died. Indeed, biological activity of clostridial toxins was significantly reduced in the samples of cecal contents from infected hamsters treated with MM_{1/1000} compared with non-treated infected controls. This outcome could be due to a decrease in the ability of *C. difficile* to produce or release toxins in the gut. In this sense, it has been described that *Lactobacillus delbrueckii* subsp. *bulgaricus* B-30892 secreted one or more bioactive components which neutralise cytotoxicity of *C. difficile* probably by inactivating its toxins [9]. More recently, Trejo et al. 2010 [8] showed that co-incubation of *C. difficile* strain 117 with *L. plantarum* or *Bifidobacterium* strains induce a decrease in the production of toxins *in vitro*. However, we do not have sufficient evidence to confirm these hypotheses in our model.

The failure of MM_{1/100} administration to protect against the *C. difficile* enterocolitis in this model could be probably due to the high doses of microorganisms in the gut. This could induce an exacerbated inflammatory response in the mucosa thus leading to a damage of the tissues which even might facilitate the infection.

Differences between healthy and ill animals were also evident by macroscopic observation of abdominal cavity and cecal content during necropsy. As a consequence of *C. difficile* infection, haemorrhagic infiltrates in cecal tissues and a large amount of gas in a yellow content were observed in animals that presented diarrhoea. These features were compatible with those described for *C. difficile*-induced enterocolitis [37] and correlate with the characteristics visualised by microscopic observation of cecal tissues. A thick mucosa, with oedema, cryptic abscesses and an inflammatory infiltrate with a predominance of neutrophils was only observed in samples from hamsters infected with *C. difficile*. However, control group that received antibiotic treatment (clindamycin) presented different histological features, showing a chronic inflammation with an infiltration of lymphocytes. On the other hand, cecal samples from infected animals treated with MM showed only a slight thickening of the mucosa due to mild inflammatory infiltrates of lymphocytes.

All these findings strongly suggest that treatment with MM_{1/1000} not only significantly reduced the proportion of hamsters which developed enterocolitis induced by infection with *C. difficile* strain 117, but also was effective against antibiotic-associated diarrhoea in this animals.

4.1. Conclusion

The ability of a mixture constituted by kefir-isolated bacteria and yeasts to protect against *C. difficile*-induced enterocolitis in hamsters was described by first time in this work, contributing significantly to the knowledge about the probiotic properties of this functional food.

Acknowledgements

This work was supported by Agencia Nacional de Promoción Científica y Tecnológica (PICT 00479/06), CONICET and Universidad Nacional de La Plata (Project 11X/443). P Bolla and P Carasi are fellows of CONICET; M Bolla is fellow of Servicio de Anatomía Patológica del hospital Interzonal General de Agudos (H.I.G.A) "Profesor Dr Rodolfo Rossi". GL De Antoni is a member of the Carrera de Investigador Científico y Tecnológico of CICPBA; M Serradell is a member of the Carrera de Investigador Científico y Tecnológico of CONICET.

References

[1] Farnworth E. Kefir – a complex probiotic. Food Science and Technology Bulletin: Functional Foods 2005;2:1–17.

- [2] Servin AL. Antagonistic activities of lactobacilli and bifidobacteria against microbial pathogens. FEMS Microbiology Reviews 2004 Oct;28(4):405–40. Review.
- [3] Corthésy B, Gaskins HR, Mercenier A. Cross-talk between probiotic bacteria and the host immune system. Journal of Nutrition 2007 Mar;137(3 Suppl. 2): 781S–90S. Review.
- [4] Sun X, Wang H, Zhang Y, Chen K, Davis B, Feng H. Mouse relapse model of *Clostridium difficile* infection. Infection and Immunity 2011;79:2856–64.
- [5] Tam Dang TH, Fagan RP, Fairweather NF, Tate EW. Novel inhibitors of surface layer processing in *Clostridium difficile*. Bioorganic & Medicinal Chemistry 2011;20:614–21.
- [6] Hickson M. Probiotics in the prevention of antibiotic-associated diarrhoea and *Clostridium difficile* infection. Therapeutic Advances in Gastroenterology 2011;4:185–97.
- [7] Trejo FM, Minnaard J, Pérez PF, De Antoni GL. Inhibition of *Clostridium difficile* growth and adhesion to enterocytes by *Bifidobacterium* supernatants. Anaerobe 2006;12:186–93.
- [8] Trejo FM, Pérez PF, De Antoni GL. Co-culture with potentially probiotic microorganisms antagonises virulence factors of *Clostridium difficile* *in vitro*. Antonie Van Leeuwenhoek 2010;98:19–29.
- [9] Banerjee P, Merkel GJ, Bhunia AK. *Lactobacillus delbrueckii* ssp. *bulgaricus* B-30892 can inhibit cytotoxic effects and adhesion of pathogenic *Clostridium difficile* to Caco-2 cells. Gut Pathogens 2009;1:8.
- [10] Carasi P, Trejo FM, Pérez PF, De Antoni GL, Serradell MD. Surface proteins from *Lactobacillus kefir* antagonize *in vitro* cytotoxic effect of *Clostridium difficile* toxins. Anaerobe 2012;18:135–42.
- [11] Castagliuolo I, LaMont JT, Nikulasson ST, Pothoulakis C. *Saccharomyces boulardii* protease inhibits *Clostridium difficile* toxin A effects in the rat ileum. Infection and Immunity 1996;64:5225–32.
- [12] Castagliuolo I, Riegler MF, Valenick L, LaMont JT, Pothoulakis C. *Saccharomyces boulardii* protease inhibits the effects of *Clostridium difficile* toxins A and B in human colonic mucosa. Infection and Immunity 1999;67:302–7.
- [13] Pothoulakis C, Kelly CP, Joshi MA, Gao N, O'Keane CJ, Castagliuolo I, et al. *Saccharomyces boulardii* inhibits *Clostridium difficile* toxin A binding and enterotoxicity in rat ileum. Gastroenterology 1993;104:1108–15.
- [14] Tung JM, Dolovich LR, Lee CH. Prevention of *Clostridium difficile* infection with *Saccharomyces boulardii*: a systematic review. Canadian Journal of Gastroenterology 2009;23:817–21.
- [15] Venuto C, Butler M, Ashley E, Brown J. Alternative therapies for *Clostridium difficile* infections. Pharmacotherapy 2010;30:1266–78.
- [16] Lowe BR, Fox JG, Bartlett JG. *Clostridium difficile*-associated cecitis in guinea pigs exposed to penicillin. American Journal of Veterinary Research 1980;41: 1277–9.
- [17] Carman RJ, Borriello SP. Infectious nature of *Clostridium spiriforme*-mediated rabbit enterotoxaemia. Veterinary Microbiology 1984;9:497–502.
- [18] Czuprynski CJ, Johnson WJ, Balish E, Wilkins T. Pseudomembranous colitis in *Clostridium difficile*-monoassociated rats. Infection and Immunity 1983;39: 1368–76.
- [19] Chen X, Katchar K, Goldsmith JD, Nanthakumar N, Cheknis A, Gerding DN, et al. A mouse model of *Clostridium difficile*-associated disease. Gastroenterology 2008;135:1984–92.
- [20] Larson HE, Price AB, Honour P, Borriello SP. *Clostridium difficile* and the aetiology of pseudomembranous colitis. Lancet 1978;20:1063–6.
- [21] Borriello SP, Barclay FE. Protection of hamsters against *Clostridium difficile* ileocaecitis by prior colonisation with non-pathogenic strains. Journal of Medical Microbiology 1985;19:339–50.
- [22] Trejo FM. Interacción entre *Clostridium difficile*, lactobacilos y bifidobacterias. Ph.D Thesis. Facultad de Ciencias Exactas, Universidad Nacional de La Plata; 2009.
- [23] Buckley AM, Spencer J, Candlish D, Irvine JJ, Douce GR. Infection of hamsters with the UK *Clostridium difficile* ribotype 027 outbreak strain R20291. Journal of Medical Microbiology 2011;60:1174–80.
- [24] Garrote G, Abraham A, De Antoni G. Chemical and microbiological characterisation of kefir grains. Journal of Dairy Research 2001;68:639–52.
- [25] Delfederico L, Hollmann A, Martínez M, Iglesias NG, De Antoni G, Semorile L. Molecular identification and typing of lactobacilli isolated from kefir grains. Journal of Dairy Research 2006;73:20–7.
- [26] Hamet F. Polisacáridos de bacterias lácticas de fermentos artesanales para el desarrollo de alimentos funcionales. Ph.D Thesis. Facultad de Ciencias Exactas, Universidad Nacional de La Plata; 2012.
- [27] Bolla PA, Serradell M de L, de Urraza PJ, De Antoni GL. Effect of freeze-drying on viability and *in vitro* probiotic properties of a mixture of lactic acid bacteria and yeasts isolated from kefir. Journal of Dairy Research 2011;78:15–22.
- [28] Bolla PA, Carasi P, Serradell M de LA, De Antoni GL. Kefir-isolated *Lactococcus lactis* subsp. *lactis* inhibits the cytotoxic effect of *Clostridium difficile* *in vitro*. Journal of Dairy Research 2013;80:96–102.
- [29] Abraham A, De Antoni G, Añón M. Effect of calcium on the cryopreservation of *L. bulgaricus* in different freezing media. Cryobiology 1990;27: 186–93.
- [30] Minnaard J, Humen M, Pérez PF. Effect of *Bacillus cereus* exocellular factors on human intestinal epithelial cells. Journal of Food Protection 2001;64: 1535–41.
- [31] Verna EC, Lucak S. Use of probiotics in gastrointestinal disorders: what to recommend? Therapeutic Advances in Gastroenterology 2010;3:307–19.

- [32] McFarland LV. Meta-analysis of probiotics for prevention of antibiotic associated diarrhea and treatment of *Clostridium difficile* disease. *American Journal of Gastroenterology* 2006;101:812–22.
- [33] McFarland LV. Evidence-based review of probiotics for antibiotic-associated diarrhoea and *Clostridium difficile* infections. *Anaerobe* 2009;15:274–80.
- [34] Hickson M, D'Souza AL, Nuthu N, Rogers TR, Want S, Rajkumar C, et al. Use of probiotic *Lactobacillus* preparation to prevent diarrhea associated with antibiotics: randomized double blind placebo controlled trial. *British Medical Journal* 2007;335:80.
- [35] Razaq N, Sambol S, Nagaro K, Zukowski W, Cheknis A, Johnson S, et al. Infection of hamsters with historical and epidemic BI types of *Clostridium difficile*. *Journal of Infectious Diseases* 2007;196:1813–9.
- [36] Ochsner UA, Bell SJ, O'Leary AL, Hoang T, Stone KC. Inhibitory effect of REP3123 on toxin and spore formation in *Clostridium difficile*, and *in vivo* efficacy in a hamster gastrointestinal infection model. *Journal of Antimicrobial Chemotherapy* 2009;63:964–71.
- [37] Keel MC, Songer JG. The comparative pathology of *Clostridium difficile*-associated disease. *Veterinary Pathology* 2006;43:225–40.