

Follow-up of first permanent molar restorative treatment with and without Molar Hypomineralization

Ana M Biondi, Silvina G Cortese, Lucía Babino, Andrea M Ortolani

Universidad de Buenos Aires, Facultad de Odontología, Cátedra Odontología Integral Niños. Buenos Aires, Argentina

ABSTRACT

The selection and long-term stability of restorative materials for teeth affected by Molar Hypomineralization (MH) are controversial. The aim of this study was to compare need for treatment and status of restorations performed on first permanent molars in patients with and without MH. Retrospective design based on the clinical records of 153 patients who had received comprehensive care in 2014 at the Clinic of the Children's Comprehensive Dentistry Department (FOUBA) by 3 pediatric dentists (Kappa MH 0.94), and who attended periodical follow-up visits for at least 24 months. Need for treatment in first molars, and type and longevity of treatment were recorded (modified Ryge criteria /USPHS, Kappa 0.78). Results were compared between patients with MH and without MH. The Kruskal Wallis test was used to compare follow-up time, the asymptotic test was performed to compare proportions, and relative risk (RR) was calculated to compare need for treatment.

Mean follow-up times for the 595 teeth analyzed were 61.7±20.1 months for Group without MH, and 57.5±23.9 months for Group with MH ($p=0.0504$). The percentages of teeth requiring at least one treatment were 7.2% in Group without MH and 27.5% in Group with MH ($RR = 3.80, p < 0.001$). Of the teeth treated in Group with MH 23.1% required retreatment, while none of the teeth in Group without MH did. The need for treatment was approximately 4 times higher in molars affected with MH, with greater probability of retreatment.

Keywords: dental enamel - molar incisor hypomineralization - therapeutics.

Seguimiento del tratamiento restaurador de primeros molares permanentes con y sin Hipomineralización Molar

RESUMEN

La selección y estabilidad a largo plazo de los materiales de restauración en piezas afectadas por Hipomineralización Molar (HM) es en la actualidad un tema de controversia. El objetivo de este estudio fue comparar las necesidades de tratamiento y el estado de las restauraciones realizadas en primeros molares permanentes en pacientes con y sin HM. Diseño retrospectivo sobre las historias clínicas de 153 pacientes que habían recibido atención integral en 2014, en la Clínica de la Cátedra de Odontología Integral Niños (Facultad de Odontología de la Universidad de Buenos Aires) por 3 odontopediatras (Kappa HM 0,94) y que asistieron a las recitaciones periódicas durante un mínimo de 24 meses. Se registraron las necesidades de tratamiento, tipo y longevidad de los mismos en primeros molares (criterios Ryge modificados /USPHS, Kappa 0,78). Se compararon los resultados entre los pacientes con y sin HM. Se utilizó test de Kruskal Wallis para comparar tiempos de seguimiento, test asintótico de comparación de proporciones y se calculó riesgo relativo (RR) para comparar la necesidad de tratamiento. Los tiempos medios de seguimiento de las 595 piezas analizadas resultaron de 61.7±20.1 y 57.5±23.9 meses en los grupos sin HM y con HM respectivamente ($p=0.0504$). Los porcentajes de piezas que requirieron al menos un tratamiento fueron 7.2% en el grupo sin HM y 27.5% en el grupo con HM. ($RR = 3.80, p < 0.001$) De las piezas con HM tratadas, el 23.1% requirieron retratamiento, mientras que en el grupo sin HM ninguna pieza lo necesitó. La necesidad de tratamiento fue aproximadamente 4 veces mayor en los molares afectados con HM con más probabilidad de retratamiento.

Palabras clave: esmalte dental - hipomineralización molar incisiva - terapéutica.

To cite:

Biondi AM, Cortese SG, Babino L, Ortolani AM. Follow-up of first permanent molar restorative treatment with and without Molar Hypomineralization, Argentina. Acta Odontol Latinoam. 2022 Sep 30;35(2):75-79. <https://doi.org/10.54589/aol.35/2/75>

Corresponding Author:

Ana M Biondi
anamaria.biondi@odontologia.uba.ar

Received: April 2022.

Accepted: August 2022.



This work is licensed under a Creative Commons Attribution-NonCommercial 4.0 International License

INTRODUCTION

Hereditary, environmental and local factors can cause structural defects in the enamel of primary and/or permanent teeth. According to the amelogenesis period affected, these alterations may be quantitative if they act during the protein matrix secretion phase, or qualitative if they occur during the maturation or mineralization processes.

Until two decades ago, the three most frequent enamel developmental defects reported in the literature were amelogenesis imperfecta, endemic fluorosis and hypoplasia.

In recent years, research – particularly research in pediatric dentistry – has been focusing on Molar Hypomineralization (MH), which affects almost 1 out of every 5 children. MH presents as an anomaly in the translucence of the adamantine structure, with clinically observed white/yellow/brown demarcated areas without alteration of enamel thickness, which can sometimes disintegrate, giving rise to rapid progression of caries lesions. Worldwide prevalence, based on 141 studies in 47 countries, is currently 19%, with first permanent molars being the most frequently affected teeth. This rate makes MH the most frequent enamel anomaly, with 17 million new cases per year. MH can impact nutrition and hygiene due to molar hypersensitivity, even when the enamel is intact, as well as causing esthetic problems if anterior teeth are involved, affecting patients' quality of life. The etiology of MH remains uncertain¹.

Results of previously published studies by teachers from the Children's Comprehensive Dentistry Department, School of Dentistry, University of Buenos Aires, reported prevalence of 15.9 % for the Autonomous City of Buenos Aires in 2010².

Leppaniemi et al., Muratbegovic et al. and Da Costa-Silva et al. reported an association between presence of opacities and caries lesions³⁻⁵.

Using spectrometry, Jälevik et al. found greater presence of carbon, especially from proteins, Mangum et al. and Farah et al. using biochemical approaches for isolating and characterizing proteins, found they may be up to 21 times higher, with a 20% reduction in mineral content⁶⁻⁸.

Bozal et al. analyzed the ultrastructure and mineral composition of the enamel surface of a molar with clinical diagnosis of MH, with and without acid etching treatment, using SEM and ionic analysis (EDS). They concluded that the enamel, including clinically intact adamantine surface, presents severe ultrastructural alterations and changes in ionic composition, affecting the acid etching pattern, which could interfere with bonding mechanisms⁹.

Because these characteristics make the behavior of opacities unpredictable, with probable collapse of the enamel and loss of restorations, the selection and long-term stability of the restorative materials in affected teeth is currently subject to controversy.

The aim of this study was to compare the need for treatment and the status of restorations performed on first permanent molars in patients with and without MH.

METHODS

This was a retrospective study based on the clinical records of 153 patients born from 2003 to 2006, who had received comprehensive care during 2014 at the clinic of the Children's Comprehensive Dentistry Department of the School of Dentistry of Buenos Aires University. Care was provided by 3 pediatric dentists (Kappa MH 0.94), and the children attended periodical follow-up visits for at least 24 months. The project was approved by the Ethics Committee of the School of Dentistry of Buenos Aires University (006/2019 CETICA-FOUBA).

Need for treatment, and type and longevity of treatments in first permanent molars were recorded (modified Ryge criteria /USPHS, Kappa 0.78). Results were compared between patients with MH and without MH groups.

An asymptotic test for comparing proportions was applied, and the relative risk (RR) calculated with 95% confidence interval (CI 95%) to compare need for treatment. Since teeth had different follow-up times, they were compared previously with a Kruskal Wallis test to determine the validity of the comparison of need for treatment between groups.

RESULTS

The sample consisted of 595 molars (236 with MH and 359 without MH). Mean follow-up times were 61.7±20.1 months for group without MH, and 57.5±23.9 months for group with MH ($p = 0.0504$), (Fig. 1).

The percentages of teeth requiring at least one treatment were 7.2% in Group without MH and 27.5% in Group with MH (RR = 3.80, CI 95%: 2.50-5.81. $p < 0.001$), (Fig. 2).

In Group with MH, 23.1% of the treated molars required retreatment. No retreatment was recorded in Group without MH.

In Group with MH, the treatments selected were glass ionomers (GI) and steel crowns (Cw), while in group without MH, they were mainly composite resins (CR).

Fig. 3 shows the distribution of treatments.

The highest proportion of failures in Group with MH occurred in restorations with glass ionomers, although differences were not significant ($p = 0.53$).

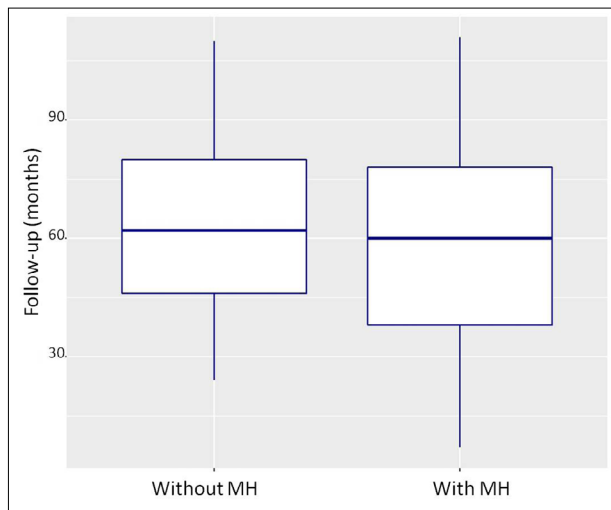


Fig. 1. Comparison of follow-up times for without MH and with MH groups.

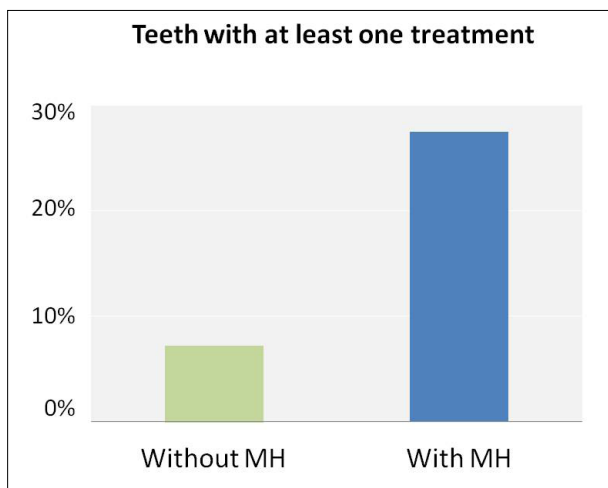


Fig. 2. Comparison of need for treatment

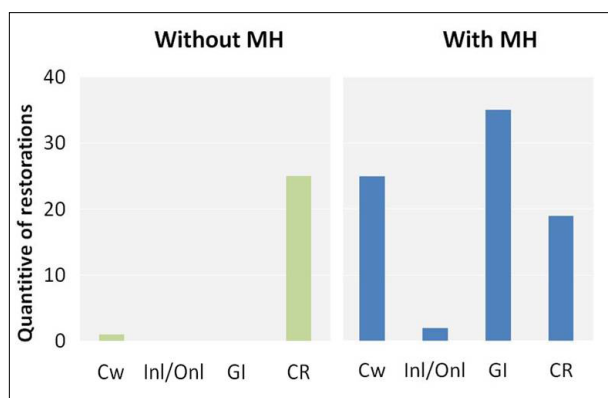


Fig. 3. Quantity of restorations and treatment type in each group

DISCUSSION

The ultrastructural alterations of the hypomineralized enamel interfere with and alter the bonding

mechanisms of restorative materials⁹. Because of the small amount of available information regarding the longevity of restorative practices, the selection and stability of materials is currently a subject of research. Lygidakis et al.¹⁰ agree that choosing a treatment is complex, and depends upon factors such as severity of the defect, dental eruption stage, patient age and cooperation, social context, and the expectations of the child and parents. Options include preventive practices for mild MH, restoration (GI, CR or steel crown) or tooth extraction for moderate/severe MH.

The literature reports a higher frequency of treatment in teeth with MH than in unaffected teeth¹¹. In the current sample, over a follow-up period of several years, need for treatment was 4 times higher in the group with MH. This rate is lower than the one found by Jälevik and Klinberg¹², who conducted a cross-sectional study in 2002 on 9-year-old patients, concluding that children with MH received dental treatment 10 times more often than children without MH, and that affected teeth were treated twice, on average. A subsequent study by the same authors on 18-year-olds found a similar rate to the current study¹³.

Because teeth in the current study had different follow-up times, these times had to be compared previously in order to determine the validity of the comparison of need for treatment between groups. Although the significance of the difference was borderline, in practice, it is not significant.

Choice of treatment differed between Groups with and without MH based on previous knowledge regarding the bonding difficulties and the sensitivity typical of MH. For Group with MH, the most frequent choices were modified GI and steel crowns, while for Group without MH, the most frequent choice was composite resins.

Ionomers are used for intermediate restoration because studies on conventional GIs report low longevity rates. Linner et al.¹¹ found that only 7% of GI restorations survived at 36 months, while Durmus et al.¹⁴ found 87% longevity at 2 years for modified ionomers. In the current study, photoactivated resinous GIs were used, with a 74% success rate.

There is a point of controversy regarding the removal of tissue prior to restoration. Although decisions are variable, most dentists prefer conservative, minimally invasive preparations, as used in the current sample¹⁵. Linner et al.¹¹ conclude that restorations with non-invasive composite resins, used mainly in younger or less cooperative children, were associated to lower restoration survival rates. These authors found a 30% survival rate at 36 months for conservative resins, which was lower than the rate found in the current sample. Rolim et al.¹⁶, for a similar sample and using

preparations with minimal intervention with composite resins, found a success rate of 81% using total etching with 37% phosphoric acid, and 62% with a self-conditioner. In the current study, all composite resins were used with total etching and achieved a similar success rate, with 89.5%.

Regarding the use of steel crowns, which was high in the current sample for the group with MH, Fariás et al. report a 94% success rate at 24 months, which is much higher than the composite resin success rate, in agreement with the results of the current study reflecting a low failure rate for crowns¹⁷.

Ceromer inlays/onlays (Inl/Onl) were used for teeth in which previous treatments failed, due to which they subsequently received endodontic treatment. Gaardmand et al. found a 98% success rate at 36 months in teeth with MH¹⁸.

DECLARATION OF CONFLICTING INTERESTS:

The authors declare no potential conflicts of interest regarding the research, authorship, and/or publication of this article.

With regard to need for retreatment, the results of the current study are similar to those of Kotsanos et al., who found three times more retreatments in the group with MH than in the control group¹⁹.

Na Ha et al. conclude that the size of the defect is the factor with greatest impact on the prognosis for the restoration²⁰.

It is currently hoped that biological materials and resin infiltration may provide a solution for this problem which has high impact on both the patient and the professional.

CONCLUSIONS

In group of patients under study, the need for treatment was approximately 4 times higher in molars affected by MH, with more probability of retreatment.

FUNDING

None

REFERENCES

- Hubbard MJ, Mangum JE, Perez VA, Williams R. A Breakthrough in Understanding the Pathogenesis of Molar Hypomineralisation: The Mineralisation-Poisoning Model. *Front Physiol.* 2021 Dec 21;12:802833. <https://doi.org/10.3389/fphys.2021.802833>
- Biondi AM, Cortese SG, Martínez K, Ortolani AM, et al. Prevalence of molar incisor hypomineralization in the city of Buenos Aires. *Acta Odontol Latinoam.* 2011; 24(1):81-5.
- Leppaniemi A, Lukinmaa PL, Alaluusua S. Nonfluoride hypomineralizations in the first permanent molars and their impact on the treatment need. *Caries Res.* 2001;35(1):36-40. <https://doi.org/10.1159/000047428>
- Muratbegovic A, Markovic N, Ganibegovic Selimovic M. Molar incisor hypomineralisation in Bosnia and Herzegovina: aetiology and clinical consequences in medium caries activity population. *Eur Arch Paediatr Dent.* 2007; 8(4):189-94. <https://doi.org/10.1007/BF03262595>
- da Costa-Silva CM, Jeremias, de Souza JF, Cordeiro R de C, et al. Molar incisor hypomineralization: prevalence, severity and clinical consequences in Brazilian children. *Int J Paediatr Dent.* 2010; 20(6):426-34. <https://doi.org/10.1111/j.1365-263X.2010.01097.x>
- Jälevik B, Odellius H, Dietz W, Noren J. Secondary ion mass spectrometry and X-ray microanalysis of hypomineralized enamel in human first permanent molars. *Arch Oral Biol.* 2001; 46: 239-247. [https://doi.org/10.1016/S0003-9969\(00\)00113-8](https://doi.org/10.1016/S0003-9969(00)00113-8)
- Mangum JE, Crombie FA, Kilpatrick N, Manton DJ, Hubbard MJ. Surface integrity governs the proteome of hypomineralized enamel. *J Dent Res.* 2010;(10):1160-5. <https://doi.org/10.1177/0022034510375824>
- Farah RA, Monk BC, Swain MV, Drummond BK. Protein content of molar-incisor hypomineralisation enamel. *J Dent.* 2010; 38(7):591-6. <https://doi.org/10.1016/j.jdent.2010.04.012>
- Bozal CB, Kaplan A, Ortolani A, Cortese GS, Biondi AM. Ultrastructure of the Surface of Dental Enamel with Molar Incisor Hypomineralization with and without acid etching. *Acta Odontol Latinoam.* 2015; 28(2):192-8.
- Lygidakis NA, Wong F, Jälevik B, Vierrou A, Alaluusua S. Best Clinical Practice Guidance for clinicians dealing with children presenting with Molar-Incisor-Hypomineralisation (MIH): An EAPD Policy Document. 2010; 11:75-81. <https://doi.org/10.1007/BF03262716>
- Linner T, Khazaei Y, Bücher K, Pfisterer J, et al. Comparison of four different treatment strategies in teeth with molar-incisor hypomineralization-related enamel breakdown-A retrospective cohort study. *Int J Paediatr Dent.* 2020; 30(5):597-606. <https://doi.org/10.1111/ipd.12636>
- Jälevik B, Klingberg GA. Dental treatment, dental fear and behaviour management problems in children with severe enamel hypomineralization of their first permanent molars. *Int J Paediatr Dent.* 2002; 12(1):24-32. <https://doi.org/10.1046/j.0960-7439.2001.00318.x>
- Jälevik B, Klingberg G. Treatment outcomes and dental anxiety in 18-year-olds with MIH, comparisons with healthy controls - a longitudinal study. *Int J Paediatr Dent.* 2012; 22(2): 85- 91. <https://doi.org/10.1111/j.1365-263X.2011.01161.x>
- Durmus B, Sezer B, Tugcu N, Caliskan C, et al. Two-Year Survival of High-Viscosity Glass Ionomer in Children with Molar Incisor Hypomineralization. *Med Princ Pract.* 2021; 30(1):73-79. <https://doi.org/10.1159/000508676>

15. Kopperud SE, Pedersen CG, Espelid I. Treatment decisions on Molar-Incisor Hypomineralization (MIH) by Norwegian dentists - a questionnaire study. *BMC Oral Health*. 2016;17(1):3. <https://doi.org/10.1186/s12903-016-0237-5>
16. Rolim TZC, da Costa TRF, Wambier LM, Chibinski AC, et al. Adhesive restoration of molars affected by molar incisor hypomineralization: a randomized clinical trial. *Clin Oral Investig*. 2021;25(3):1513-1524. <https://doi.org/10.1007/s00784-020-03459-2>
17. de Farias AL, Rojas-Gualdrón DF, Mejía JD, Bussaneli DG, et al. Survival of stainless-steel crowns and composite resin restorations in molars affected by molar-incisor hypomineralization (MIH). *Int J Paediatr Dent*. 2022;32(2):240-250. <https://doi.org/10.1111/ipd.12849>
18. Gaardmand E, Poulsen S, Haubek D. Pilot study of minimally invasive cast adhesive copings for early restoration of hypomineralised first permanent molars with post-eruptive breakdown. *Eur Arch Paediatr Dent*. 2013; 14:35-9. <https://doi.org/10.1007/s40368-012-0002-7>
19. Kotsanos N, Kaklamanos E. Treatment management of first permanent molars in children with Molar-Incisor Hypomineralisation. *Eur J Paediatr Dent*. 2005; 6(4):179-84.
20. Ha N, Kim H, Kim H, Nam S. A Prognostic Assessment of First Permanent Molars Showing Molar-Incisor Hypomineralization Based on Restorative Materials and Defect Class. *J Korean Acad Pediatr Dent*. 2017; 44(3): 263-271. <https://doi.org/10.5933/JKAPD.2017.44.3.263>