



Case report

Diptera (Insecta: Pterygota) larvae as predators of *Strongyloides stercoralis* causing false negative stool cultures



Pedro E. Fleitas^{a,b,c}, Ximena G. Acosta^{c,d}, Paola A. Vargas^a, Nicolas Caro^a,
Alejandro J. Krolewiecki^{a,c}, Julio R. Nasser^b, Rubén O. Cimino^{a,b,c,1,*}

^a Universidad Nacional de Salta, Sede Regional Orán, Instituto de Investigaciones de Enfermedades Tropicales (IIET), Salta, Argentina

^b Universidad Nacional de Salta, Facultad de Ciencias Naturales, Cátedra de Química Biológica, Salta, Argentina

^c Consejo Nacional de Investigaciones Científicas y Técnicas (CONICET), CCT-Salta, Salta, Argentina

^d Universidad Nacional de Salta, Facultad de Ciencias Naturales Salta, Instituto para el Estudio de la Biodiversidad de Invertebrados (IEBI), Salta, Argentina

ARTICLE INFO

Article history:

Received 22 December 2021

Accepted 5 January 2022

Available online xxxx

Keywords:

S. stercoralis

Diptera

Harada Mori

ABSTRACT

A stool sample of a five-year-old boy with suspected STH infection arrived at the Laboratory of the Instituto de Investigaciones de Enfermedades Tropicales (IIET), National University of Salta in Oran, province of Salta, Argentina in 2017. Three Harada Mori were prepared, of which only one showed the presence of *S. stercoralis*. In the other two, the presence of an unknown larva was observed, which was later identified as an insect larva of the Diptera order. PCR analysis of the liquid medium of Harada Mori and Diptera larvae revealed presence of *S. stercoralis* DNA. These results, added to the predatory characteristics of the dipteran larvae, indicate that the *S. stercoralis* larvae were prey for these organisms, resulting in a negative diagnosis for *S. stercoralis* in the Harada Mori.

© 2022 Published by Elsevier Ltd.
CC_BY_NC_ND_4.0

Introduction

Strongyloides stercoralis is a soil transmitted helminth (STH) infection belonging to the group of neglected tropical diseases. *S. stercoralis* affects approximately 386 million people worldwide, [1] however, the global prevalence of *S. stercoralis* is underestimated due to the relatively low sensitivity of diagnostic methods. The successful diagnosis of *S. stercoralis* in stool depends on fresh samples and concentration methods [2]. This is because the diagnosis requires the identification of larvae in feces, which are excreted intermittently and in most cases in small quantities. Due to the absence of a gold standard, the most common approach for the detection of *S. stercoralis* is the combination of several techniques, [3] being the recommended techniques Baermann, Harada Mori and Koga agar plate culture [4]. Additionally, PCR from stool samples and serology have improved the diagnosis of *S. stercoralis* infections [5,6].

The Harada Mori technique has lower diagnostic sensitivity than the Koga agar plate and Baermann techniques [7,8]. However, a

smaller amount of stool is required, several tubes with individual samples can be prepared and the use of charcoal or culture medium is not required [9]. This makes Harada Mori a simple technique to perform in any laboratory; although an incubator is needed.

Case

A stool sample of a five-year-old boy with suspected STH infection arrived at the Laboratory of the Instituto de Investigaciones de Enfermedades Tropicales (IIET), National University of Salta in Oran, province of Salta, Argentina in 2017. The stool sample was examined by Telemann concentration and McMaster's methods. The sample was insufficient to include an aliquot for the Baermann technique, instead three Harada Mori culture tubes were prepared. For each Harada Mori test, one gram of fecal matter was weighed, it was smeared onto the lower third of a strip of filter paper folded in an accordion shape, the paper was placed in a test tube with five milliliters of water and covered the tube with pre-drilled paraffin paper. The tube was then incubated in an upright position at 28 °C for three days. The sample was positive for *Strongyloides stercoralis* by Telemann concentration technique. Two Harada Mori tubes were negative for *S. stercoralis*, but in both tubes the presence of larvae of an unknown species were observed. The third Harada Mori tube was positive for *S. stercoralis*, with presence of many rhabditiform larvae,

* Corresponding author at: Universidad Nacional de Salta, Sede Regional Orán, Instituto de Investigaciones de Enfermedades Tropicales (IIET), Salta, Argentina.

E-mail address: rubencimino@gmail.com (R.O. Cimino).

¹ Present address: Alvarado 751 Orán, zip code:4530, Salta, Argentina.

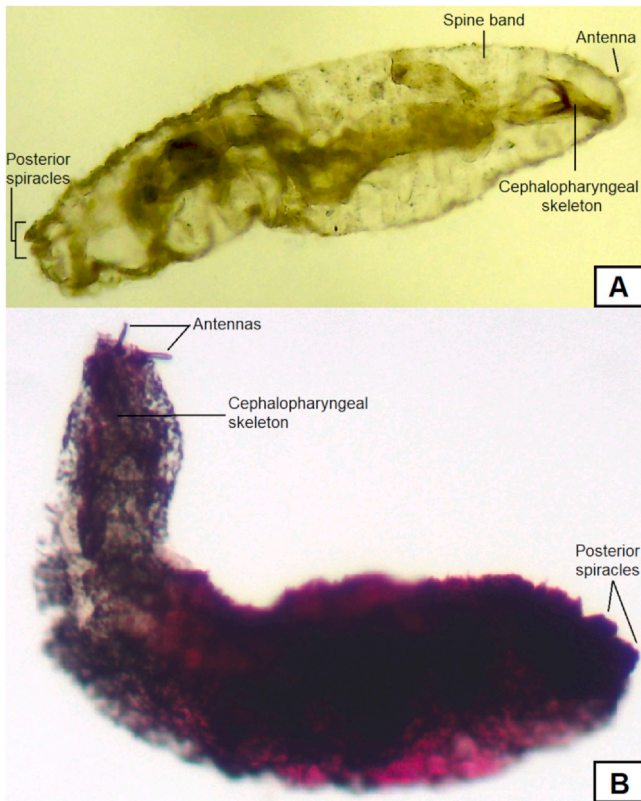


Fig. 1. Full view of dipteran larva under the light microscope at 20X: A. Alive larva. B. Mounted larva.

and absence of the unknown larvae observed in the other tubes. Although this case report describes the event that occurred with the stool sample of a five-year-old child, it should be mentioned that two more cases were found in 2020 in children under ten years of age, where the same type of larvae were observed but no infection with helminths were found.

A video recording was made of the larvae of *S. stercoralis* and the unknown larvae found in the harada tubes [10].

Nine specimens of the unknown larvae were retrieved for identification under Zeiss optical microscope using taxonomic keys, [11–14] and following the system proposed by Wiegmann et al. [15]. A Summary through the Past 3.23 software, [16] was carried out to obtain the mean and standard deviation (SD) of larval body length. The unknown larvae found in the stool samples all belong to the same morphospecies and correspond to insect larvae of the Diptera order. Specifically, they are Diptera from the *Calypttrariae* subsection and, according to their characteristics, they are closer to the *Oestroidea* superfamily. The Diptera larvae had a mean body length of 0.54 mm (SD=0.12). Regarding morphology (Fig. 1A), the dipteran larvae present two antennae in the anterior part (Fig. 1B), the cephalopharyngeal skeleton is compact with the dorsal cornua shorter than the ventral cornua, both ending with sharp edges (Fig. 2A). The mouthhooks are bifid and curved (Fig. 2A–B). The cuticular spines are rose-thorn-shaped, laterally flattened and unicuspid with sharply pointed tips (Fig. 2C), varying in length along the body, being longer at the anterior and posterior ends. The posterior spiracles are elevated over short caudal processes (Fig. 1A–B), which are distinctly separated, each bearing one of the two spiracles.

PCR for *S. stercoralis* was performed on the Diptera larvae to verify if it had the ability to feed on *S. stercoralis* larvae and give a false negative result in the Harada Mori technique. For this, a Diptera larva was recovered from the first Harada Mori tube, that had been negative for *S. stercoralis*, washed ten times with sterile PBS 1X

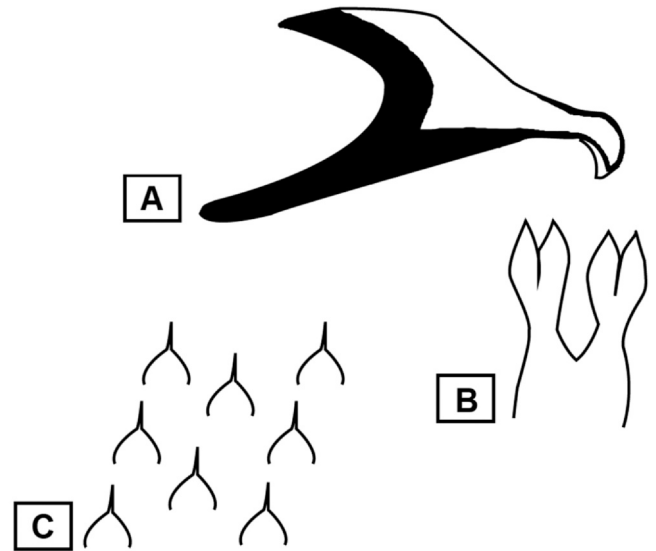


Fig. 2. Morphology of the most distinctive features under the light microscope at 40X: A. cephalopharyngeal skeleton. B. Mouthhooks. C. Cuticular spines.

solution and finally placed in a tube with 100 µl of sterile 1X PBS. This tube was divided into two samples of 50 µl each, one including the unknown larva that was called sample 1 (S1) and another sample with 50 µl of 1X PBS without the unknown larva, wash control, that was named sample 2 (S2). Prior to the collection of the Diptera larvae, a 50 µl sample was taken from one of the negative Harada Mori tubes and it was called sample 3 (S3). S3 had no larvae of any kind. DNA was extracted from the three sample (S1, S2, and S3) using the FastPrep® Spin Kit for Soil (MP Biomedicals, Santa Ana, CA) according to manufacturer's instructions [18]. All PCRs were performed in 25 µl volume containing 10 µl DNA sample, 0.125 µl Go Taq polymerase (Promega), 5 µl 5x GoTaq reaction buffer (Promega), 0.5 µl diethyl-nitrophenyl thiophosphate (dNTP) (Promega) mixture (10 mM), 5 µl of 0.45 µM of specific primers for *S. stercoralis*, [5] and 4.375 µl MiliQ water. The thermocycler program consisted of 95°C for 3 min, followed by 35 cycles of 95 °C for 45 s, 57 °C for 30 s, 72 °C for 45 s, and a final extension step at 72 °C for 5 min. For each PCR, negative control (H₂O) was run together. PCR products were analyzed by electrophoresis on 1.5% agarose gels, stained with GelRed 1X (Biotium), and visualized on a UV transilluminator.

The PCR for *S. stercoralis* was positive for samples S1 and S3 (Fig. 3). The positive result of sample S3 demonstrates that the Harada Mori tube had, at some time prior to the microscopic observation, *S. stercoralis* larvae. In addition, the fact that sample S1 tested positive proved that the dipteran larvae had the ability to feed

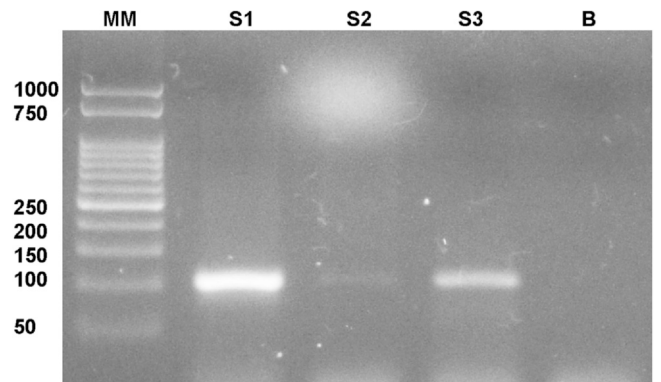


Fig. 3. PCR for the detection of *S. stercoralis* DNA in Diptera larvae and in the liquid of Harada Mori negative for *S. stercoralis*. MM: molecular marked, B: reagent blank.

on the *S. stercoralis* larvae. Sample S2 showed a slight signal, indicating that although the dipteran washout was not optimal, it can be assumed that the signal observed in S1 is due to *S. stercoralis* DNA ingested by the dipteran.

Discussion

As shown in this case report, contamination of the stool sample with Diptera larvae led to a false negative result that could result in an overall negative diagnosis if other diagnostic techniques had not been performed. The presence of the Diptera larva in the stool sample can be explained by two hypotheses. The first, is the deposition of eggs/larvae in fresh stool prior to collection in the sterile container. This means that the stool was exposed for a period of time to the outside environment, which facilitated contact with different insects. This can be common in homes with latrines, and when the fecal sample is not immediately collected into a closed container. The second hypothesis consists of the occurrence of a gastrointestinal myiasis. This type of myiasis occurs accidentally through facultative myiasis, caused by saprophage or necrophage diptera (or even another type of insect) that are found in contaminated food, either in the egg or larval stages. [17] Following this hypothesis, the larva/egg should have the capacity to remain viable until it was expelled through the feces; or a high resistance to the digestive juices of the gastrointestinal tract and to the low amount of oxygen present in it. However, the latter possibility is unlikely since the larva did not have the specialized structures of an obligatory parasite.

The Diptera larvae identified in this case seems not yet described or its appearance in studies is very scarce, so it was not possible to identify it at the family level following the available keys consulted for both North America, [12] and South America [11,13,14]. Another source of uncertainty for the identification of the Diptera is the presence of mixed distinctive characters that belong to several families so tracking of the key is truncated, especially when these focuses exclusively on the spiracles, either anterior or posterior. Even so, it could be observed that this dipteran larva has a predatory character, which is hinted at by its well-developed mandibular hooks. Added to this, is the larger size of the dipteran larvae, which makes rhabditiform *S. stercoralis* larvae a plausible prey, which was confirmed by PCR analyzes. This implies that greater considerations in the collection of stool samples for STH analysis should be taken. However, it is possible that although Diptera larvae may produce false negatives in microscopy techniques, this is not the case for PCR techniques. Since as it could be observed, the PCR detected the presence of *S. stercoralis* DNA in the liquid of the Harada Mori that was negative by microscopy (sample S3).

Ethical approval

This case does not require an ethics committee because it is limited to describing what was found in a stool sample that was voluntarily given to the ILET for the diagnosis of helminths.

Consent

Ethical approval was obtained from the Bioethics Committee of the Faculty of Health Sciences (#417/15) from the Universidad Nacional de Salta. Participation was voluntary and an informed consent was obtained from all patients involved in the study.

Funding sources

This work was supported by a research grant from Consejo de Investigación de la Universidad Nacional de Salta (CIUNSA), Salta, Argentina. Grant number 2478/0.

CRedit authorship contribution statement

Pedro E. Fleitas: Conceptualization, Investigation, Methodology, Writing – original draft, Writing – review & editing. **Ximena Acosta:** Investigation, Methodology, Writing – original draft, Writing – review & editing. **Paola A. Vargas:** Investigation, Methodology, Writing – review & editing. **Nicolas Caro:** Investigation, Writing – review & editing. **Alejandro J. Krolewiecki:** Conceptualization, Writing – original draft. Writing – review & editing. **Julio R. Nasser:** Methodology, Writing – review & editing. **Rubén O. Cimino:** Supervision, Project administration, Funding acquisition, Writing – review & editing.

Conflict of interest

The authors have no conflicts of interest to declare.

References

- [1] Fleitas PE, Travacio M, Martí-Soler H, Socías ME, Lopez WR, Krolewiecki AJ. The *Strongyloides stercoralis*-hookworms association as a patho to the estimation of the global burden of strongyloidiasis: A systematic review. Cappello M, editor. *PLoS Negl Trop Dis*. 2020;14:e0008184.
- [2] Watts MR, Robertson G, Bradbury R. The laboratory diagnosis of *Strongyloides stercoralis*. *Microbiol Aust* 2016;37:4. (Available from). (<http://microbiology.publish.csiro.au/?paper=MA16003>).
- [3] Krolewiecki AJ, Lammie P, Jacobson J, Gabrielli AF, Leveck B, Socías E, et al. A public health response against *Strongyloides stercoralis*: time to look at soil-transmitted helminthiasis in full. *PLoS Negl Trop Dis* 2013;7:e2165.
- [4] Machicado JD, Marcos LA, Tello R, Canales M, Terashima A, Gotuzzo E. Diagnosis of soil-transmitted helminthiasis in an Amazonian community of Peru using multiple diagnostic techniques. *Trans R Soc Trop Med Hyg* 106. 2012. p. 333–9. <https://doi.org/10.1016/j.trstmh.2012.03.004>
- [5] Verweij JJ, Canales M, Polman K, Ziem J, Brienen EA, Polderman AM, van Lieshout L. Molecular diagnosis of *Strongyloides stercoralis* in faecal samples using real-time PCR. *Trans R Soc Trop Med Hyg* 2009;103:342–6.
- [6] Buonfrate D, Requena-Mendez A, Anghoben A, Cinquini M, Cruciani M, Fittipaldo A, et al. Accuracy of molecular biology techniques for the diagnosis of *Strongyloides stercoralis* infection—A systematic review and meta-analysis. *PLoS Negl Trop Dis* 2018;12:e0006229.
- [7] Hanan R, Rasha S, Nahla G. Detection of *Strongyloides stercoralis* in fecal samples using conventional parasitological techniques and real-time PCR: a comparative study. *Parasitol U J* 2012;2:2–6.
- [8] Krolewiecki AJ, Ramanathan R, Fink V, McAuliffe I, Cajal SP, Won K, et al. Improved diagnosis of *Strongyloides stercoralis* using recombinant antigen-based serologies in a community-wide study in northern Argentina. *Clin Vaccine Immunol* 2010;17:1624–30. <https://doi.org/10.1128/CVI.00259-10>
- [9] Reiss D, Harrison LM, Bungiro R, Cappello M. Short report: an agar plate method for culturing hookworm larvae: analysis of growth kinetics and infectivity compared with standard coproculture techniques. *Am J Trop Med Hyg* 2007;77:1087–90.
- [10] Fleitas P. Unknown larva found in harada mori from human feces - YouTube [Internet]. 2021 [cited 2021 Jun 25]. Available from: (<https://www.youtube.com/watch?v=HPaeS1j48jc>).
- [11] Costa C, Ide S, Simonka C. Insetos imaturos: metamorfose e identificação. Brazil: Holos Editora; 2006.
- [12] Teskey HJ. Morphology and terminology- Larvae. In: McAlpine J, editor. *Man Nearctic Diptera*. volumen 1. Ottawa, Canadá: Research Branch Agriculture Canada; 1981. p. 65–88.
- [13] Florez E, Wolff M. Descripción y clave de los estadios inmaduros de las principales especies de Calliphoridae (Diptera) de importancia forense en Colombia. *Neotrop Entomol* 2009;38:418–29.
- [14] Oliva A. Diptera (Insecta) de interés forense o causantes de Miasis. Claves artificiales para estadios preimaginales. In: Salomón OD, editor. *Actual en arropodología Sanit Argentina*. Buenos Aires, Argentina: Fundación Mundo Sano; 2002. p. 51–60.
- [15] Wiegmann BM, Trautwein MD, Winkler IS, Barr NB, Kim JW, Lambkin C, et al. Episodic radiations in the fly tree of life. *Proc Natl Acad Sci USA* 2011;108:5690–5.
- [16] Hammer Ø, Harper DAT, Ryan PD. PAST: paleontological statistics software package for education and data analysis. *Palaeontol Electron* 2001;4:1–9.
- [17] Forero-Becerra E. Miasis en salud pública y salud pública veterinaria. *UNA Salud Rev Sapuvet Salud Pública* 2011;2:95–132.
- [18] Cimino RO, Jeun R, Juarez M, et al. Identification of human intestinal parasites affecting an asymptomatic peri-urban Argentinian population using multi-parallel quantitative real-time polymerase chain reaction. *Parasites Vectors* 2015;8(380). <https://doi.org/10.1186/s13071-015-0994-z>