

# Amelanotic Melanoma of the Root of the Tongue in A Canine Patient Treated by Electrochemotherapy

F.H. Maglietti<sup>1,\*</sup>, S.D. Michinski<sup>1</sup>, I. Ricotti<sup>2</sup>, P. Maure<sup>3</sup>, L.M. Mir<sup>4,5</sup>, N. Olaiz<sup>1</sup> and G. Marshall<sup>1</sup>

<sup>1</sup>Laboratorio de Sistemas Complejos, Departamento de Computación, Facultad de Ciencias Exactas y Naturales, Universidad de Buenos Aires. Intendente Güiraldes 2160, Ciudad Universitaria, C1428EGA, Ciudad de Buenos Aires, Argentina

<sup>2</sup>Belfos Veterinary Clinic. Av. Directorio 3026, C1406HAT, Ciudad de Buenos Aires, Argentina

<sup>3</sup>Centro de Inmunología Veterinaria, CIV Flores, Av. Directorio 3026, C1406HAT, Ciudad de Buenos Aires, Argentina

<sup>4</sup>CNRS, UMR8203, Laboratory of Vectorology and Anticancer Therapies, Institut de Cancérologie Gustave Roussy, 94805, Villejuif, France

<sup>5</sup>Université Paris-Sud, UMR8203, 91405, Orsay, France

**Abstract:** *Background:* Electrochemotherapy is a novel tumor treatment routinely used for cutaneous and subcutaneous tumors in human patients in the European Union since 2006. Here we used it to treat an amelanotic melanoma of the root of the tongue in a canine patient.

*Case Presentation:* The patient was a 9 year-old, female, Golden Retriever, dehydrated, cachectic and in a bad general condition due to the difficulty in eating and drinking provoked by the tumor. The procedure was performed with general anesthesia, with intravenous administration of bleomycin, and went uneventful. The only adverse effect was an important swelling of the tongue which lasted 2 days and was controlled with non-steroidal anti-inflammatory drugs.

*Results and Conclusion:* A good local control of the disease was achieved with a 83% reduction of the tumor mass, at day 21 after a single treatment. On the 33<sup>rd</sup> day the patient died after a digestive hemorrhage not related to the treatment. Electrochemotherapy was found a good approach to locally control the disease. The swelling of the tongue was an important side effect which has to be taken into account when treating this organ, and should be controlled with medication.

**Keywords:** Amelanotic melanoma, electroporation, cancer, ECT, dog.

## BACKGROUND

Malignant melanoma is a common neoplasm in dogs. It is more frequent in male, older dogs, and it is frequently found in the gingiva [1,2]. However cancer confined to the tongue is rare, and the most common type in this location is squamous cell carcinoma.

Malignant melanomas have a very poor prognosis since they early metastasize and their diagnosis is usually made late [1,3]. The treatment options include radical surgical excision of the tumor [3,4]. As in the case here reported, 54% of tongue tumors in dogs are located in the midline, which limits the ability to achieve a complete surgical resection. Complications from aggressive resections include hypersalivation and alterations in thermoregulation in hot and humid environments [5]. Malignant melanomas are known to be radiation responsive [6] and radiotherapy can also be

considered as a primary treatment option [5]. Complications, which depend on the tissue irradiated, in this case include oral mucositis, dysphagia, and other late less frequent complications [5]. Chemotherapy can modestly improve the survival time if it is used in combination with the previous treatment modalities [5,7]. DNA vaccination is a new therapeutic option that might improve the outcome, but it requires previous local control of the disease [8, 9].

Electrochemotherapy (ECT) is a novel treatment modality consisting in the use of an electric field to increase tissue permeability to certain drugs. The drug generally used is bleomycin, which works as an endonuclease, cutting the DNA strands and thus interfering with cell division. This provides a sort of selectivity towards dividing cells, sparing the quiescent ones, and thus allowing the tissue to heal with minimum scarring. This treatment is used in the European Union since 2006, for the treatment of cutaneous and subcutaneous tumors in human clinics [10,11], particularly for the treatment of melanoma nodules. Electrochemotherapy was introduced in

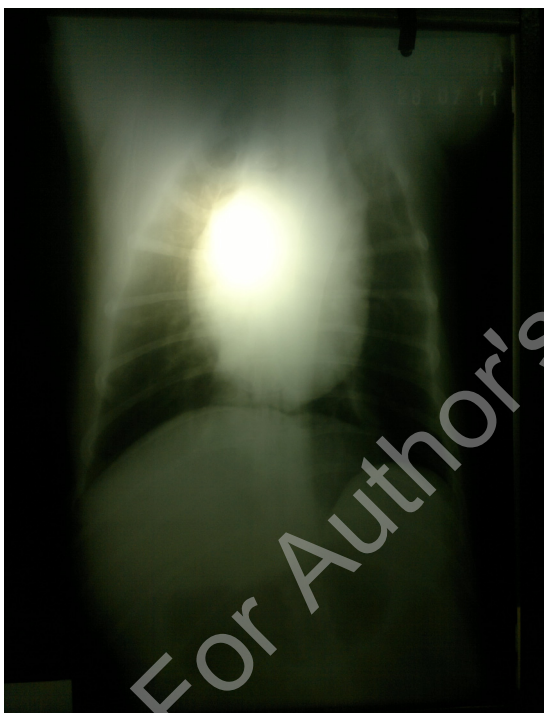\*Address correspondence to this author at the Intendente Güiraldes 2160, Ciudad Universitaria, C1428EGA, Buenos Aires, Argentina; Tel/Fax: (+54 11) 4576 3300 (int 709); E-mail: felipemaglietti@gmail.com

veterinary oncology in 1997 [12]. Cemazar *et al.* reviewed the use of electrochemotherapy for treating tumors in veterinary oncology [13]. Here we report the results obtained when ECT is applied in the tongue of a canine patient with an amelanotic melanoma.

## CASE PRESENTATION

### Clinical Examination

A 9 year-old, female, Golden Retriever was presented with cachexia, dehydration, sialorrhoea, and a bad general condition. The owner reported that the dog had difficulties in eating and drinking water in the previous month. Additionally, he reported that his kids didn't want to play with the dog because of the sialorrhoea and the bad smell coming out from his mouth.



**Figure 1:** Chest X-ray of the patient. The x-ray image shows a dilated heart, with no signs of lung metastasis.

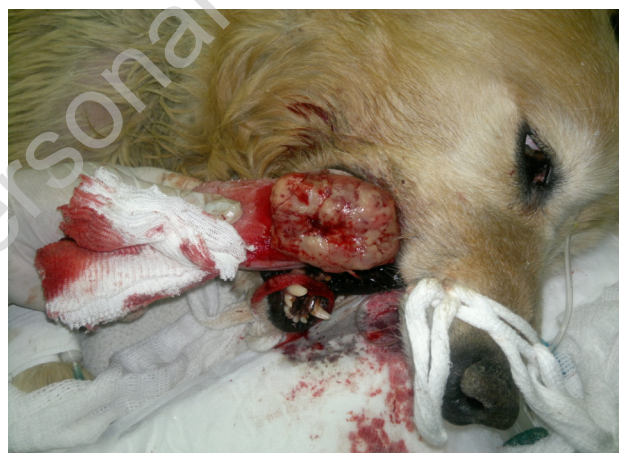The patient was clinically fully examined, including laboratory analysis and chest X-ray. Figure 1 shows a chest X-ray revealing a dilated heart without any other pathologic sign or lung metastasis.

A pale, 5.6 x 5.4 x 2 cm<sup>3</sup> tumor was found in the root of the tongue. A tissue sample was cut for histopathology revealing an amelanotic melanoma. According to the World Health Organization staging *scheme* for dogs with oral melanoma, it corresponded to a stage III [8].

Laboratory findings revealed a mild anemia (RBC 4.8 M/mm<sup>3</sup> – Reference Value (RV) 5-8; Hb 9.9 g/dL – RV 12-18; Hematocrit 29% -RV 35-55; MCV 60.41 fl – RV 64-75), hyperleucocytosis (WBC 36 000/mm<sup>3</sup> – RV 5 000-15 000), excessive uremia (87 mg/dl - RV 15-45) and alkaline phosphatase activity (343 U/l - RV less than 250). Other results were within normal range.

### Treatment

Figure 2 shows the patient on the day of the treatment. Due to the bad general condition, ECT was the therapeutic modality chosen. To determine the dose of bleomycin the body surface of the dog was estimated using the formula:  $body\ surface\ in\ m^2 = \frac{10.1 \times (weight\ in\ grams)^{2/3}}{10000}$  [14]. The weight was 25 kg, so the calculated body surface was 0.86 m<sup>2</sup>.



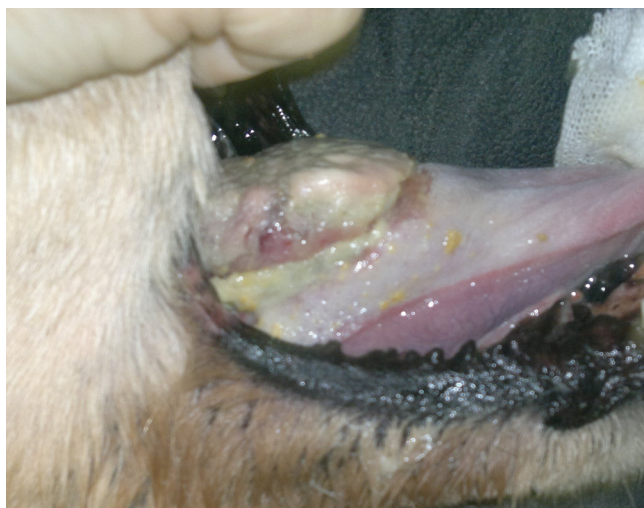**Figure 2:** The patient at the time of the treatment. The tumor, located on the root of the tongue, is clearly seen.

General anesthesia was used. A single dose of bleomycin (15 000 IU/m<sup>2</sup>) was administered in bolus, and the electric pulses were delivered 8 minutes later. A 6 needles electrode (2 cm long and 1.2 mm in diameter) was used to apply 8 pulses of 1000V/cm with a length interval of 100 μsec at a repetition frequency of 10 Hz, using a BTX ECM 830, Harvard Apparatus, Holliston, MA, USA. After the procedure, NSAID was administered for pain containment and tongue swelling control.

## RESULTS

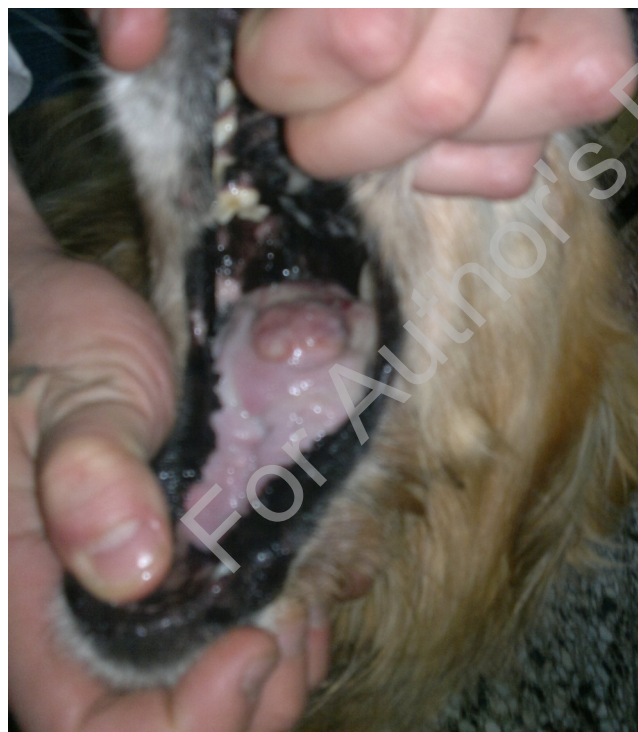
### Follow Up

Two days after the ECT, the patient showed significant edema of the tongue, with aggravated difficulty to eat.



**Figure 3:** The patient seven days after the ECT. The tumor already started to shrink.

Figure 3 shows the patient seven days after the ECT. No sign of edema was present and patient displayed a clear improvement of its general condition. The tumor started to shrink to a size of  $4.2 \times 3.4 \times 0.9 \text{ cm}^3$ .



**Figure 4:** The patient twenty-one days after the ECT. The size of the tumor notably reduced and patient general condition greatly improved.

Figure 4 displays the patient twenty-one days after the ECT with a marked improvement in its general condition, absence of pain, and the capability to eat and drink with no problems. The sialorrhoea and the bad smell were no longer present. The size of the tumor

was  $2.5 \times 2.2 \times 0.5 \text{ cm}^3$ . The tumor size was calculated using the formula  $A = ab$ , in accordance with the WHO response criteria, showed an 83% reduction of the tumor size, which corresponds to a partial response [15]. Since the diagnostic, a second ECT treatment was programmed because of the thickness of the lesion. It should have been performed 15 days after the second visit. Unfortunately 12 days later after the second visit (on the 33<sup>rd</sup> day after the ECT), patient died due to a digestive hemorrhage (unrelated to the treatment).

## CONCLUSION AND DISCUSSION

A very good antitumor response was achieved. The patient recovered its general condition in a few days, with a rapid improvement in less than a week. The low doses of bleomycin (11 to 30 times lower dose than the one reported as toxic [16]) had no undesired effects. However, the treatment provoked a marked swelling of the tongue which made patient nourishment difficult after the ECT. The situation ceased in less than three days, controlled with medication (NSAIDs). It must be noticed that, prior to the ECT treatment, the tumor itself made the food and beverage ingestion very difficult. However, once the swelling of the tongue returned to normal and the tumor started to shrink (due to the ECT treatment), the normal capacity to eat and drink was restored. Thus, this side effect was quite limited in time and it was actually compensated by the efficacy of the ECT.

There is a single treatment of an amelanotic melanoma of the tongue in dogs by means of ECT reported in the literature [17]. No good local control of the tumor was achieved even though 4 ECT sessions were applied. However, the ECT procedure was not the same since the authors of that study injected the bleomycin in the tumor, and not intravenously, as usually recommended in human's treatment [18, 19, 20, 21] and as performed in our case. This difference can easily explain the poor result previously reported because tumors are heterogeneous tissues, thus, the intratumoral injection of bleomycin probably did not provide a uniform distribution inside the melanoma mass. By administering the drug intravenously this difficulty was eliminated. We conclude that, also in the amelanotic melanoma, ECT is a safe and efficient treatment for local control of the disease. This result confirms that one of the most remarkable aspects of ECT is its effectiveness against any histological type of cancer [10, 11, 19, 22]. Our data also confirm that ECT

is very useful when patient clinical condition impedes a more aggressive treatment.

In some cases, like the one reported here, a limitation of the ECT is tumor accessibility by the electrodes, as well as the electrodes dimensions. Indeed, due to the thickness of the tumor at the time of the ECT, the complete treatment of the tumor in a single session was not possible. A second ECT application was scheduled to be performed after the reduction of the tumor volume. This would provide adequate coverage of the tumor base and a margin of normal tissue [18, 20]. In this context, new electrodes and pulse generators, presently under development, shall overcome this ECT limitation, making possible the access to larger lesions and to organs in other locations.

## ACKNOWLEDGEMENTS

F. Maglietti and N. Olaiz have fellowships from Consejo Nacional de Investigaciones Científicas y Técnicas (CONICET), S. Michinski has a fellowship from Instituto Nacional del Cancer (INC), L.M. Mir and G. Marshall are members of CNRS and CONICET, respectively. This work is supported by grants from CONICET (PIP 1087/05) and Universidad de Buenos Aires (UBACyT X132/08).

## AUTHOR CONTRIBUTIONS

PM and IR selected the patient. FM, SM, NO worked in the design and fabrication of the electrodes. FM, SM and IR performed the treatment and follow up of the patient. FM, GM and LMM participated in design and coordination and in drafting the manuscript.

## REFERENCES

- [1] Ramos-Vara JA, Beissenherz ME, Miller MA, Johnson GC, Pace LW, Fard A *et al.* Retrospective Study of 338 Canine Oral Melanomas with Clinical, Histologic, and Immunohistochemical Review of 129 Cases. *Vet Pathol* 2000; 37: 597-608.  
<http://dx.doi.org/10.1354/vp.37-6-597>
- [2] Teixeira TF, da Silva TC, Cogliati B, Nagamine MK, Dagli MLZ. Retrospective study of melanocytic neoplasms in dogs and cats. *Braz J Vet Pathol* 2010; 3: 100-104.
- [3] Ballinari U, Schiller I, Schroff-Ballinari A, Mazzi M. Case report: oral malignant melanoma in an 11-month-old Doberman. *Schweiz Arch Tierheilkd* 1998; 140:110-3.
- [4] Veena P, Kokila S, SureshKumar RV, Sankar P, Dhanalakshmi N. Malignant Melanoma in a Dog - A Case report. *Vet World* 2012; 5: 431-432.  
<http://dx.doi.org/10.5455/vetworld.2012.431-432>
- [5] Withrow SJ, Vail DM. Specific Malignancies in the small animal patient. *Withrow and MacEwen's Small Animal Clinical Oncology*. 4th ed. St. Louis: Saunders Elsevier; 2007.
- [6] Bateman KE, Catton PA, Pennock PW, Kruth SA. Radiation Therapy for the Treatment of Canine Oral Melanoma. *J Vet Intern Med* 1994; 8: 267-272.  
<http://dx.doi.org/10.1111/j.1939-1676.1994.tb03231.x>
- [7] Modiano JF, Ritt MG, Wojcieszyn J. The Molecular Basis of Canine Melanoma: Pathogenesis and Trends in Diagnosis and Therapy. *J Vet Intern Med* 1999; 13:163-174.  
<http://dx.doi.org/10.1111/j.1939-1676.1999.tb02173.x>
- [8] Bergma PJ. Canine Oral Melanoma. *Clin Tech Small Anim Pract* 2007; 22: 55-60.  
<http://dx.doi.org/10.1053/j.ctsap.2007.03.004>
- [9] Finocchiaro LME, Glikin GC. Cytokine-enhanced vaccine and suicide gene therapy as surgery adjuvant treatments for spontaneous canine melanoma. *Cancer Gene Ther* 2008; 15:267-276.  
<http://dx.doi.org/10.1038/sj.cgt.7701096>
- [10] Mir LM. Bases and rationale of the electrochemotherapy. *Eur J Cancer Suppl* 2006; 4:38-44.  
<http://dx.doi.org/10.1016/j.ejcsup.2006.08.005>
- [11] Marty M, Sersa G, Garbay J, Gehl J, Collins C, Snoj M *et al.* Electrochemotherapy - An easy, highly effective and safe treatment of cutaneous and subcutaneous metastases: Results of ESOPE (European Standard Operating Procedures of Electrochemotherapy) study. *Eur J Cancer Suppl* 2006; 4:3-13.  
<http://dx.doi.org/10.1016/j.ejcsup.2006.08.002>
- [12] Mir LM, Devauchelle P, Quintin-Colonna F, Delisle F, Doliger S, Fradelizi D *et al.* First clinical trial of cat soft-tissue sarcomas treatment by electrochemotherapy. *Brit J Cancer* 1997; 76:1617-1622.  
<http://dx.doi.org/10.1038/bjc.1997.606>
- [13] Cemazar M, Tamzali Y, Sersa G, Tozon N, Mir LM, Miklavcic D *et al.* Electrochemotherapy in Veterinary Oncology. *J Vet Intern Med* 2008; 22: 826-831.  
<http://dx.doi.org/10.1111/j.1939-1676.2008.0117.x>
- [14] Merck Manuals. The Merck Veterinary Manual. Weight to body surface area conversion. Whitehouse Station, NJ, USA, Inc.; c2009-2014 Merck Sharp & Dohme Corp., a subsidiary of Merck & Co., Inc., All rights reserved. [updated 2012 march; cited 2014 oct 19] Available from URL: <http://www.merckvetmanual.com/mvm/htm/bc/tref9.htm>.
- [15] WHO Handbook for Reporting Results of Cancer Treatment. WHO Offset Publications 1979; 48:22-27.
- [16] Fleischman RW, Baker JR, Thompson GR, Schaeppi UH, Illievski VR, Cooney DA *et al.* Bleomycin-induced interstitial pneumonia in dogs. *Thorax* 1971; 26: 675-682.  
<http://dx.doi.org/10.1136/thx.26.6.675>
- [17] Spugnini EP, Dragonetti E, Vincenzi B, Onori N, Citro G, Bladi A. Pulse-mediated chemotherapy enhances local control and survival in a spontaneous canine model of primary mucosal melanoma. *Melanoma Res* 2006; 16: 23-27.  
<http://dx.doi.org/10.1097/01.cmr.0000195702.73192.a0>
- [18] Quagliano P, Mortera C, Osella-Abate S, Barberis M, Illengo M, Rissone M *et al.* Electrochemotherapy with intravenous bleomycin in the local treatment of skin melanoma metastases. *Ann Surg Oncol* 2008; 15: 2215-22.  
<http://dx.doi.org/10.1245/s10434-008-9976-0>
- [19] Breton M, Mir LM. Microsecond and nanosecond electric pulses in cancer treatments. *Bioelectromagnetics* 2011.  
<http://dx.doi.org/10.1002/bem.20692>
- [20] Campana LG, Mocellin S, Basso M, Puccetti O, De Salvo GL, Chiarion-Sileni V *et al.* Bleomycin-based electrochemotherapy: clinical outcome from a single institution's experience with 52 patients. *Ann Surg Oncol* 2009; 16: 191-9.  
<http://dx.doi.org/10.1245/s10434-008-0204-8>

[21] Testori A, Rossi CR, Tosti G. Utility of electrochemotherapy in melanoma treatment. *Curr Opin Oncol* 2012; 24:155-61.  
<http://dx.doi.org/10.1097/CCO.0b013e32834fcaa8>

[22] Silve A, Mir LM. Cell electroporation and small molecules cellular uptake: the electrochemotherapy concept. In: Kee S, Lee E, Gehl J editors. *Electroporation in Science and Medicine*. 1st ed. New York: Springer 2010; p. 69-82.

Received on 02-10-2014

Accepted on 20-10-2014

Published on 29-10-2014

<http://dx.doi.org/10.6000/1927-7229.2014.03.04.6>

For Author's Personal Use