

Clinical Study

Extrahippocampal Desynchronization in Nonlesional Temporal Lobe Epilepsy

Jesús Pastor,^{1,2} Eduardo G. Navarrete,³ Rafael G. Sola,^{2,3} and Guillermo J. Ortega³

¹ *Clinical Neurophysiology, Hospital Universitario and Instituto de Investigación La Princesa, 28006 Madrid, Spain*

² *School of Medicine, San Pablo-CEU University, 28008 Madrid, Spain*

³ *Departamento de Neurocirugía (planta 7), Hospital Universitario and Instituto de Investigación La Princesa, Diego de León 62, 28006 Madrid, Spain*

Correspondence should be addressed to Guillermo J. Ortega, gjortega.hlpr@salud.madrid.org

Received 12 May 2011; Revised 14 September 2011; Accepted 25 September 2011

Academic Editor: Warren T. Blume

Copyright © 2012 Jesús Pastor et al. This is an open access article distributed under the Creative Commons Attribution License, which permits unrestricted use, distribution, and reproduction in any medium, provided the original work is properly cited.

Although temporal lobe epilepsy (TLE) is traditionally associated with both hypersynchronous activity in the form of interictal epileptic discharges and hippocampal sclerosis, recent findings suggest that desynchronization also plays a central role in the dynamics of this pathology. The objective of this work is to show the imbalance existing between mesial activities in patients suffering from mesial TLE, with normal mesial structures. Foramen ovale recordings from six patients with mesial TLE and one with lateral TLE were analyzed through a cluster analysis and synchronization matrices. None of the patients present findings in the MRI presurgical evaluation. Numerical analysis was carried out in three different situations: awake and sleep interictal and also during the preictal stage. High levels of desynchronization ipsilateral to the epileptic side were present in mesial TLE patients. Low levels of desynchronization were present in the lateral TLE patient during the interictal stage and almost zero in the preictal stage. Implications of these findings in relation with seizure spreading are discussed.

1. Introduction

Temporal lobe epilepsy (TLE) is the most common form of focal epilepsy, where the epileptogenic area is located at some part of the temporal lobe. Mesial TLE (MTLE) refers to those cases where the suspected source of epileptogenic activity is located in the mesial area of the temporal lobe [1], and lateral TLE (LTLE), instead, where the focus is located in the lateral side. MTLE is often associated with structural lesions and/or functional deficiency in one or several (dual pathology) mesial structures of the temporal lobe, with hippocampal sclerosis (HS) as the most common underlying abnormality [2]. However, pathological findings of damage in the amygdala and parahippocampal region, which in turn is subdivided into the entorhinal cortex (EC), perirhinal cortex (PC), and parahippocampal cortex (PPC), are also reported [3, 4]. A significant minority of MTLE patients have no pathological findings on magnetic resonance imaging (MRI), even though lateralization may be correctly performed by neurophysiological methods [5, 6].

Normal underlying mesial structures play a key role in our understanding of the pathogenesis of MTLE, as they oblige us to ask whether mesial sclerosis (MS) is either the cause or the effect in MTLE [7].

Pathophysiology in MTLE can be explained according to two models: (1) the “focal” model suggests that a single pathological region in the mesial temporal lobe is responsible for seizure origin, establishing a link between the presence of MS and the region of seizure onset [8]. (2) The “network” model states that seizures in MTLE result from an alteration of limbic network, which implies atrophy in other structures different from hippocampus [9]; this model suggests that the abnormal interaction between EC, hippocampal formation, and subiculum may be responsible for the seizures [10].

In a high percentage of MTLE patients (60%–80%), clinical seizures cannot be eliminated by drug treatment. In such cases, surgery is the only curative/palliative alternative. Even with the advent of imaging techniques that are now routinely applied in the preevaluation of drug-resistant TLE patients, neurophysiological assessment remains the main

diagnostic method at the time of locating epileptogenic areas. Besides traditional electroencephalography (EEG), invasive and semi-invasive neurophysiological methods are justified in most cases when imaging techniques fail in the localization/lateralization of the epileptic focus. Traditional neurophysiological analysis, whether noninvasive, semi-invasive, or fully invasive, depends mainly on the analysis of interictal epileptogenic discharges (IED), which are the hallmark of epileptic activity [11]. However, IED appears in the so-called irritative area, which often does not coincide with the true epileptogenic area. Thus, ictal neurophysiological patterns, such as spikes and sharp waves, must be studied in order to obtain a correct diagnosis. Moreover, as we have recently highlighted [12], analysis of IED in a neurophysiological signal, although very valuable, can only account for a very low percentage of the full information carried by a pathological signal. In order to obtain such recordings, v-EEG (EEG combined with an invasive technique and video recording) is used in most centers. This approach requires hospital admission for several days in order to record and analyze a suitable quantity of seizures to locate the focus.

In this work we analyze foramen ovale electrodes (FOEs) recordings in seven TLE patients with normal presurgical MRI, without taking into account IED activity. Very recently we have shown [12] the existence of interictal mesial synchronization imbalance in TLE patients, mostly with pathologic findings in MRI studies. In the present work, by using part of the already developed methodology, we extend the preceding work in several directions.

- (a) We analyze, for the first time, both interictal and ictal mesial synchronization in TLE patients.
- (b) We use here a homogenous sample of seven nonlesional TLE patients, in order to discard the causality relation of lesion-desynchronization.
- (c) Six out of seven patients presented MTLE, as assessed by previously evaluating FOEs ictal IED analysis; the remaining patient presented LTLE, thus, the issue of mesial synchronization imbalance against mesial or lateral TLE is also addressed.

By analyzing records of ictal and interictal activity in a homogenous sample of nonlesional TLE patients we were able to provide new information regarding the synchronization imbalance in this pathology, as we will show below.

2. Methods

2.1. Patients. The study sample comprised seven patients (six women). Mean age was 39.2 ± 9 years, and time of these intractable epilepsies was 21.4 ± 13.7 years. The Ethics Committee of Hospital de la Princesa approved the study, and all the patients gave their informed consent. Patients were evaluated before surgery according to the local protocol, as published elsewhere [13, 14], namely, interictal single-photon emission computer tomography (SPECT), MRI 1.5 T, scalp EEG, and v-EEG using 19 scalp electrodes according to the international 10–20 system. None of the patients

presented pathologic findings in the presurgical MRI studies, and, in some cases, this was corroborated by histopathology.

Table 1 shows the clinical information and results of the presurgical studies (SPECT, MRI, and v-EEG) routinely performed in the sample. During the v-EEG recording, antiepileptic drugs were progressively discontinued from the second day to the fourth day (approximately one-third of the dose per day). Six-contact platinum FOEs [15–17] (AD-Tech, Racine, USA) with 1 cm center-to-center spacing, were inserted bilaterally under general anesthesia. Correct implantation was assured using fluoroscopic imaging in the operating room. The most rostral electrode in the foramen ovale was termed FOE no. 1 and the most occipital electrode FOE no. 6.

2.2. Signal Analysis. Digital EEG and FOE data were acquired at 500 Hz, filtered at 0.5–60 Hz for both scalp and FOE recording, and exported at 200 Hz to ASCII format (XLTEK, Canada). Artifact-free epochs lasting around 60 minutes were selected for interictal analysis. Multivariate nonoverlapping temporal windows of 2048 data points were used. In the cases of preseizure and seizure analysis, multivariate records of 512 data points were used in order to achieve better temporal resolution; 512 points at 200 Hz yield temporal windows of approximately 2.5 seconds each. All derivations in scalp and FOE electrodes were referenced to $(Fz + Cz + Pz)/3$, thus 28 electrodes were used:

$$Fp1, F3, F7, T3, C3, P3, T5, O1. \quad \text{Left scalp} \quad (1a)$$

$$Fp2, F4, F8, T4, C4, P4, T6, O2. \quad \text{Right scalp} \quad (1b)$$

$$Lf1, Lf2, Lf3, Lf4, Lf5, Lf6. \quad \text{Left FOE} \quad (1c)$$

$$Rf1, Rf2, Rf3, Rf4, Rf5, Rf6. \quad \text{Right FOE} \quad (1d)$$

Postprocessing calculations were performed using *Fortran* and R. Interactions between areas covered by electrodes were quantified using the Pearson correlation coefficient [18]. Other nonlinear measures, such as phase synchronization [19], provide similar results [12]. We converted correlation values, $-1 \leq \rho_{ij} \leq 1$, between each pair of electrodes i and j , into distances, $0 \leq d(i, j) \leq 1.4$. Distances serve in the construction of dendograms and provide a more intuitive notion of desynchronization, a central issue in this work. The greater the distance between two recorded areas, the more desynchronized the corresponding neurophysiological activity is. We use the distance matrix to construct dendograms by applying the classic agglomerative single-linkage algorithm.

In order to quantify the degree of synchronization between FOEs on each side, we summed up the distances between pairs of FOE, $d(i, j)$, for the left and right sides, and divided the result by two (due to the symmetric character of the distance matrix):

$$AS_L = \frac{1}{2} \sum_{i=1}^6 \sum_{j=1}^6 d(i, j), \quad AS_R = \frac{1}{2} \sum_{i=1}^6 \sum_{j=1}^6 d(i, j). \quad (2)$$

We termed the measure defined above average synchronization (AS), which turns out to be a simple yet robust measure

TABLE 1: Clinical data. Gray-shaded row, patient no. 6 is the only case of lateral TLE.

No.	Patients characteristics				Presurgical studies			
	Freq	Age	Duration of epilepsy	Gender	SPECT	NMR	v-EEG (inter/ictal)	Diagnosis
1	d	37	6	Male	LM	Normal	RM/RM	R M TLE
2	w	42	28	Female	aLM	M asym	Bi M/LM	L M TLE
3	w	51	40	Female	aMBi (L>R)	*	Bi M/RM	R M TLE
4	m	34	20	Female	aLM	Normal	LM/LM	L M TLE
5	d	24	1	Female	aRM	Normal	Mult/LM	L M TLE
6	w	48	25	Female	aRM	Normal	Mult/Llat	L lat TLE
7	w	39	30	Female	LT	Normal	Bi M/LM	L M TLE

* Retrocerebellar arachnoid cyst

Freq: seizure frequency; w: weekly; d: daily; m: monthly; irreg: irregular; L: left; R: right; M: mesial; T: temporal; a: anteromedial; Bi: Bilateral; Mult: multifocal; asym: asymmetry; lat: lateral.

of synchronization between all the electrodes on each mesial side. The measure actually is a spatial average over the mesial sites recorded by each FOE.

As we have shown elsewhere [12], interictal synchronization imbalance exists between both mesial sides in TLE patients. This imbalance will be quantified with

$$LI_{AS} = AS_L - AS_R, \quad (3)$$

as a lateralization index. AS actually quantifies the degree of desynchronization instead of the degree of synchronization. Higher levels of AS_L imply greater distances between the left FOEs and, thus, higher desynchronization. LI_{AS} quantifies the imbalance in desynchronized activity between the left and right mesial areas. A positive LI_{AS} implies higher desynchronization on the left side, and, conversely, a negative LI_{AS} implies greater desynchronization on the right side.

3. Results

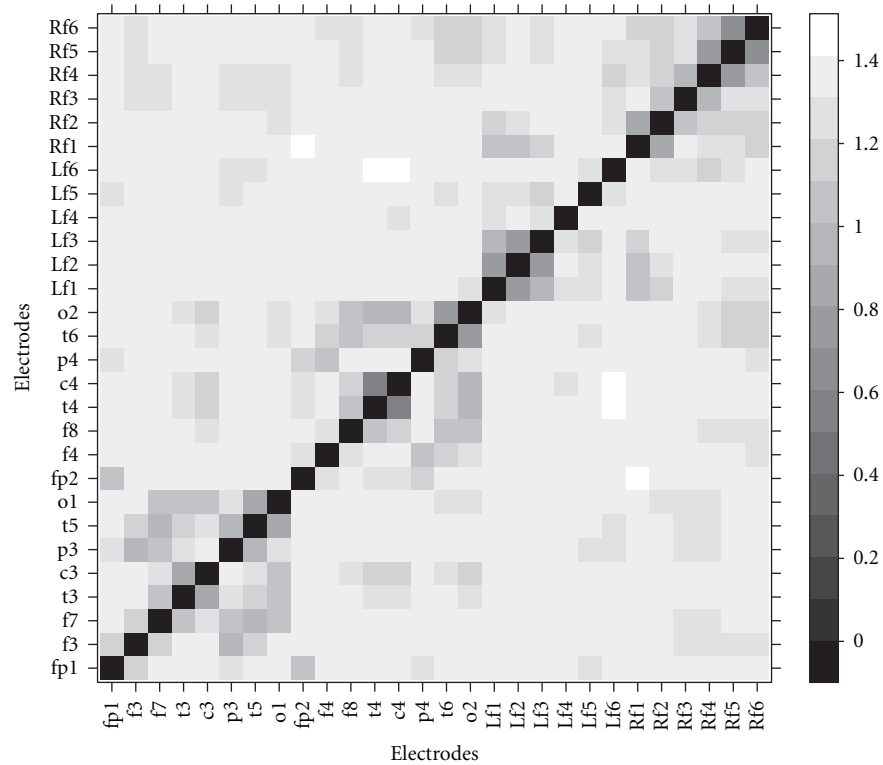
Figure 1 shows a typical distance matrix between each pair of electrodes (patient no. 5). In Figure 1(a), we plot the distance matrix of a single 2.5 sec temporal window during the preictal stage, that is, five minutes before the start of the seizure. Darker areas correspond to higher synchronization or tighter interactions between electrodes: the difference between right FOEs (Rf1–Rf6) and left FOEs (Lf1–Lf6) is apparent. The right FOEs seem to be better synchronized than the left FOEs. On the left temporal side, tighter synchronization was observed only between three electrodes, Lf1, Lf2, and Lf3, which seem to be more synchronized with the right electrodes. On the other side, Figure 1(b) which corresponds to a 2.5 sec temporal window during a seizure, the tight interactions between the entire FOE group are striking.

In order to view the above results in a different but equivalent way, we constructed dendrograms from the corresponding distance matrix of Figure 1. This is displayed in Figure 2. Figure 2(a) shows the dendrogram of Figure 1(a). There are three FOEs on the left mesial side, namely, Lf4, Lf5, and Lf6, and these are “high” in the distance axis, which in turn implies that they are poorly connected with other electrodes. The figure shows that all the mesial electrodes except those

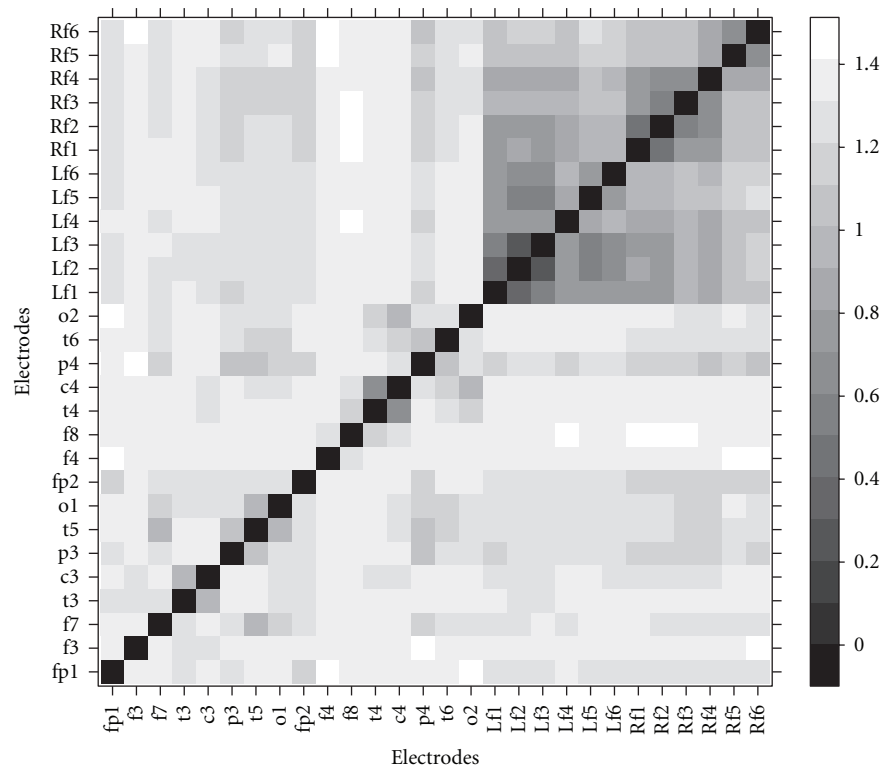
mentioned above are tightly grouped in one or two clusters. Therefore, one can conclude that, in this situation, the left mesial area is more desynchronized than the right one, due to the poor connection of the areas covered by electrodes Lf4–Lf6. Figure 2(b) shows the equivalent situation, but during the seizure. The greater synchronization between all of the mesial electrodes is striking and is seen as the deep position of the entire FOE group in the dendrogram, which in turn is also subdivided into two different clusters, one for the right FOE and another for the left.

In order to follow desynchronization activity during the whole recording for each patient, we used (2) and (3). Figure 3 shows desynchronization activity in patient no. 5 during the period before the onset of the seizure (solid vertical line) and also during the seizure. The upper panel displays the number of channels whose recorded activity was 2.5 standard deviations above baseline activity, as recorded in the first 5 minutes of the interictal record [20]. At onset, activity in the entire FOE group begins to increase, and, after a few seconds, the 12 FOE channels are highly excited. The second panel from the top shows AS_L with a smooth reduction in desynchronization activity or, equivalently, an increase in synchronization until the end of the seizure. One can observe from this figure that even when the seizure has stopped, the AS_L does not recover its preseizure value. The third panel from the top shows the AS_R , that is, desynchronization activity on the right side, whose behavior is similar to that on the left side. The main difference between both sides seems to be the deepest drop in the right desynchronized activity toward the end of the seizure. The last panel shows the difference between both desynchronization measures, that is, (3). Desynchronization activity is greater on the left side than on the right one during the preseizure period. Once the seizure starts, LI_{AS} behaves erratically, increasing the imbalance toward the positive value in the first part of the seizure, but decreasing and inverting to a negative value (around minute 32) in the second and final part of the seizure.

Figure 4 shows LI_{AS} for every patient with MTLE, as assessed by ictal video-EEG, that is, patients no. 1, no. 2, no. 3, no. 4, no. 5, and no. 7. During the preseizure period, the imbalance is always ipsilateral to the epileptic side in all



(a)



(b)

FIGURE 1: Typical distance matrix for a particular temporal window. Rf1–Rf6 stands for right FOEs no. 1 to no. 6. Rf1 is the most rostral electrode. Lf1–Lf6 stands for left FOEs no. 1 to no. 6. Lf1 is the most rostral electrode. The other labels are consistent with the standard 10–20 nomenclature. Lower distances (darker) imply tighter interactions. (a) Preseizure stage in patient no. 5. (b) Seizure stage in patient no. 5.

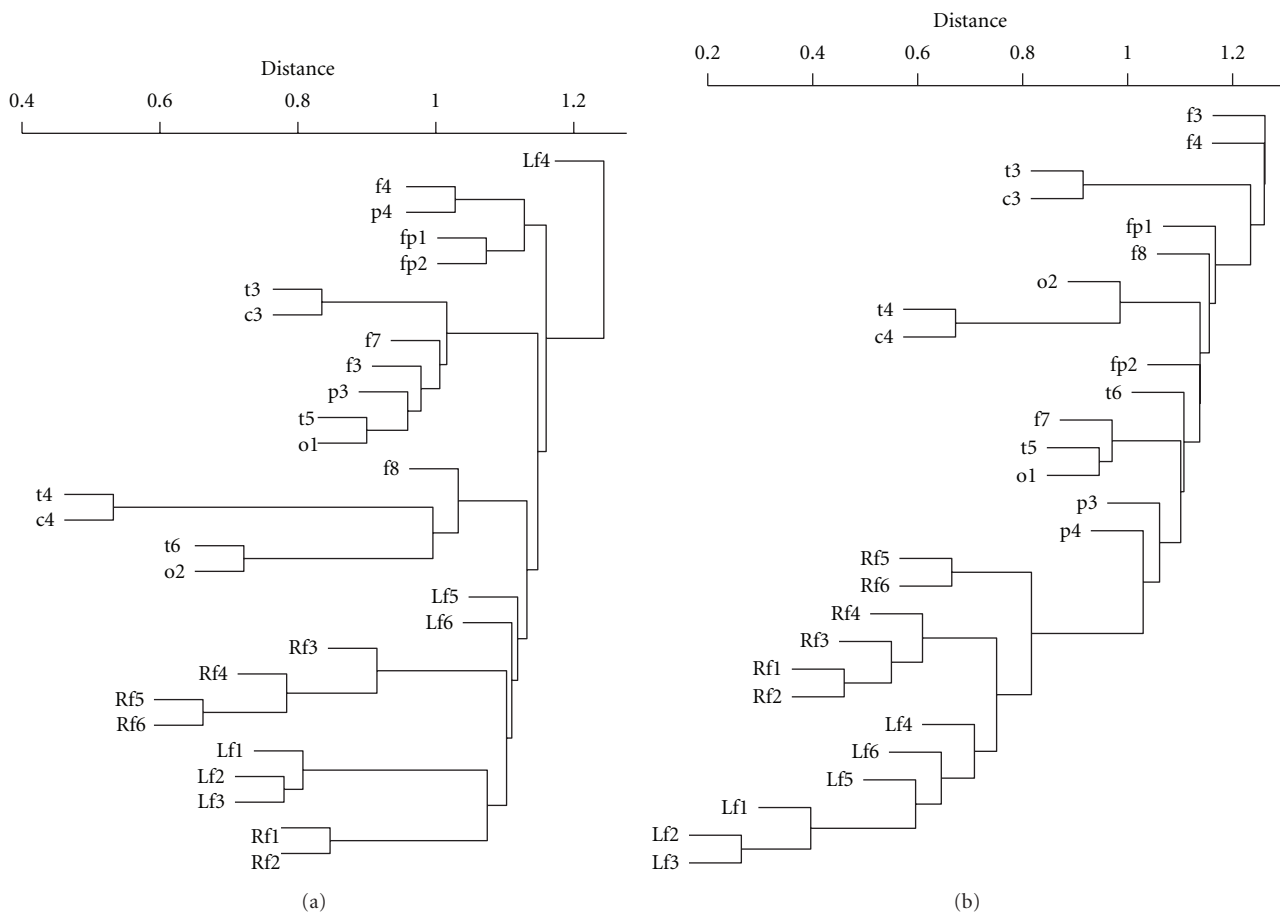


FIGURE 2: Dendrograms (see text) constructed using the distances matrix from Figure 1. (a) Preseizure stage in patient no. 5. (b) Seizure stage in patient no. 5. Lf4, Lf5, and Lf6 correspond to desynchronized activity.

cases. Patients no. 1 and no. 3 are right MTLE, and patients no. 2, no. 4, no. 5, and no. 7 are left MTLE. Although it is difficult to extract a typical pattern of evolution of LI_{AS} during the seizure from these six cases, some suggestions may be made. For instance, it seems that there is a difference between right and left temporal seizures. In left-sided cases, desynchronization increases ipsilaterally at seizure onset. The most prominent case is patient no. 4, with an abrupt increase in the imbalance around minute 14. Patient no. 7, however, displays a rapid drop before the beginning of the increase. Nevertheless, in all four cases, the imbalance during the seizure seems to begin with an increase in the imbalance followed by a decrease, which seems to end with a reversal of the imbalance, that is, minute 32 for patient no. 2, minute 16 for patient no. 4, minute 35 for patient no. 7, and minute 32 for patient no. 5.

On the other hand, patients with left MTLE (no. 1 and no. 3) do not show any significant change during the seizure, except for the high variability observed.

Figure 5 shows the LI_{AS} for patient no. 6, which, accordingly with the video-EEG evaluation, is a lateral left TLE. The difference between this LTLE case and those of MTLE is apparent. Little imbalance exists prior to onset, with LI_{AS} crossing zero imbalance randomly. During the seizure,

desynchronization was initially greater on the right side, although it suddenly became negative around minute 21.

We calculated mean values of LI_{AS} for each complete FOE recording and for each patient in three different situations. During the interictal stage, we used recordings of approximately one hour, during both the awake and sleep states. We also used a preictal recording of ten minutes prior to the seizure onset. Figure 6 shows the main results. Two cases are missing, namely, patient no. 3 (sleep) and patient no. 7 (awake). The recordings in these cases were inappropriate for the numerical analysis we performed. Except for case no. 6—LTLE—the imbalance LI_{AS} always coincided with the v-EEG evaluation, which is the gold standard for lateralization in TLE. It is noteworthy that LI_{AS} correctly lateralizes in each different situation, although with a different power. For the case of patient no. 6, however, LI_{AS} yielded a right imbalance, although with a much lower value, which in the case of the preictal stage is almost zero.

4. Discussion

We showed the existence of desynchronized activity in mesial structures ipsilateral to the epileptic side in MTLE patients. The only patient with LTLE showed little or no imbalance

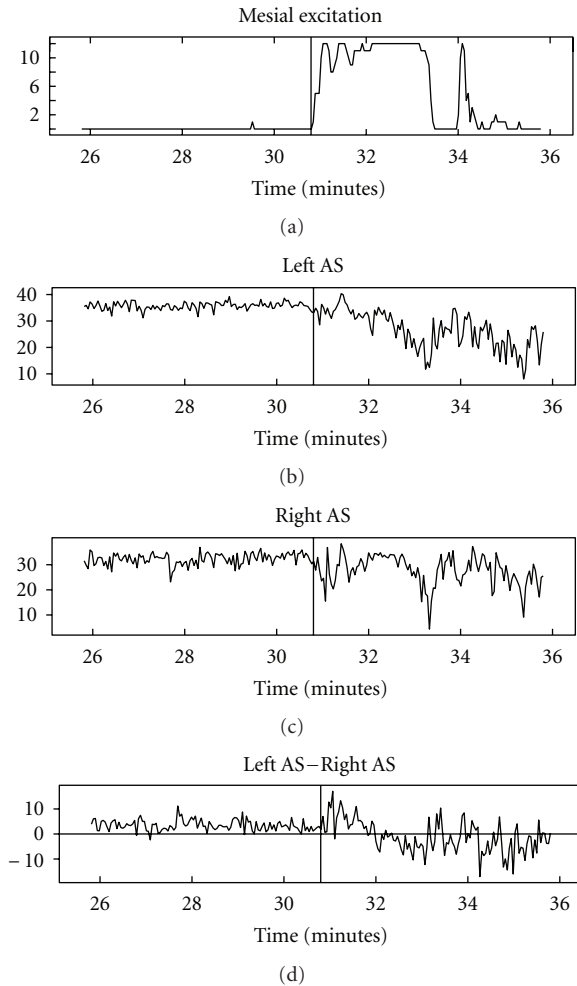


FIGURE 3: Preictal and ictal desynchronization activity in patient no. 5. Upper panel: Number of channels with activity greater than 2.5 standard deviations of baseline activity. Second upper panel: Left AS, as defined in (2), that is, desynchronized activity in the left FOE during the preictal and ictal stages. Third upper panel: Right AS, as defined in (2), that is, desynchronized activity in the right FOE during the preictal and ictal stages. Lower panel: $LI_{AS} = \text{Left AS} - \text{Right AS}$, desynchronization imbalance, as defined in (3). In every panel, solid vertical line marks seizure onset.

in desynchronized activity. Our findings came from a cluster analysis of FOEs records in a sample of normal MRI patients.

Our study, however, was subject to a series of limitations. First, none of the patients presented relevant findings in the MRI studies. MRI in our hospital is routinely performed using a 1.5 T device, and the images are visually inspected by expert neuroradiologists. New advances in MRI technologies, such as increased strength of magnetic fields to 3T, improve diagnostic information compared with standard 1.5T studies [21, 22]. In addition, volumetric and quantitative postprocessing image analysis yields better information [2, 23] in some cases. However, it is also true that visual inspection of standard MRI images by a dedicated epileptologist expert, as was the case in our center, can

account for 80–90% of hippocampal atrophy [2, 24]. Second, little attention was paid to the detection of abnormalities in mesial structures other than the hippocampus, mostly due to the tradition of regarding hippocampal sclerosis as the main cause of mesial epilepsy. Nonetheless, several authors report that abnormalities in the EC have been found in TLE patients with [4] and without [25] hippocampal abnormalities. We may resume the above comments stating that no abnormalities in the hippocampus and extrahippocampal areas in our patients were found, at least at the level of routine presurgical evaluations carried out in an average epilepsy center.

The results presented here are based on recordings of FOEs activity. These semi-invasive electrodes, which are introduced into the cisterna ambiens, record activity from extrahippocampal areas. It is reasonable to assume that the most anterior three to four electrodes record activity from EC, because this area forms the lateral wall of the cisterna ambiens [26]. Probably, the rest of the electrodes pick activity up from parahippocampal or perirhinal cortex, though the most frequent epileptiform activity arises from the most facial area [27].

Although it is difficult to define “normal” synchronized activity, we were able to demonstrate the existence of higher levels of desynchronization activity ipsilateral to the epileptogenic side than the contralateral one. As anticipated in the past [28, 29], a decrease in synchronization facilitates seizure onset; therefore, desynchronization facilitates seizure onset in one of these nonhippocampal structures. The state of desynchronization activity could be regarded as a state of increased susceptibility for pathological synchronization, thereby representing a possibly lowered threshold for seizure activity [28, 29]. This point is important in regard to the seizure’s dynamic. In studying the seizure evolution, low levels of synchronization, assessed by measuring zero-lag correlated activity at the seizure onset, were reported [20], although without a definite explanation. Two hypotheses were advanced [20]: whether desynchronized neuronal activity during seizure spreading is due to delays in reaching different cortical areas or the initial ictal desynchronization is caused by the already desynchronized preictal activity. Our results clearly favor the second hypothesis, implying that interictal desynchronization would be essential for initial ictal desynchronization, at least in the mesial cases. In the unique case with LTLE, mesial desynchronized activity achieves similar levels at both sides and therefore plays no role in the seizure onset. This would be expected because the seizure onset zone, as located by v-EEG in this LTLE patient, is at the lateral side of the temporal lobe.

Traditionally, the functional connectivity underlying seizure generation in MTL highlights the importance of a circuit composed of the EC, parahippocampus, and hippocampus, with special emphasis on the last one. Once epileptogenic activity arises at some part of this circuit, it spreads to other structures, such as the amygdala or neocortex. However, recent anatomical findings and our own electrophysiological results place the hippocampus in a comparable position as the EC and amygdala, thus establishing a functional network of interactions. A deficit in communication between these areas, for instance, lowering levels of

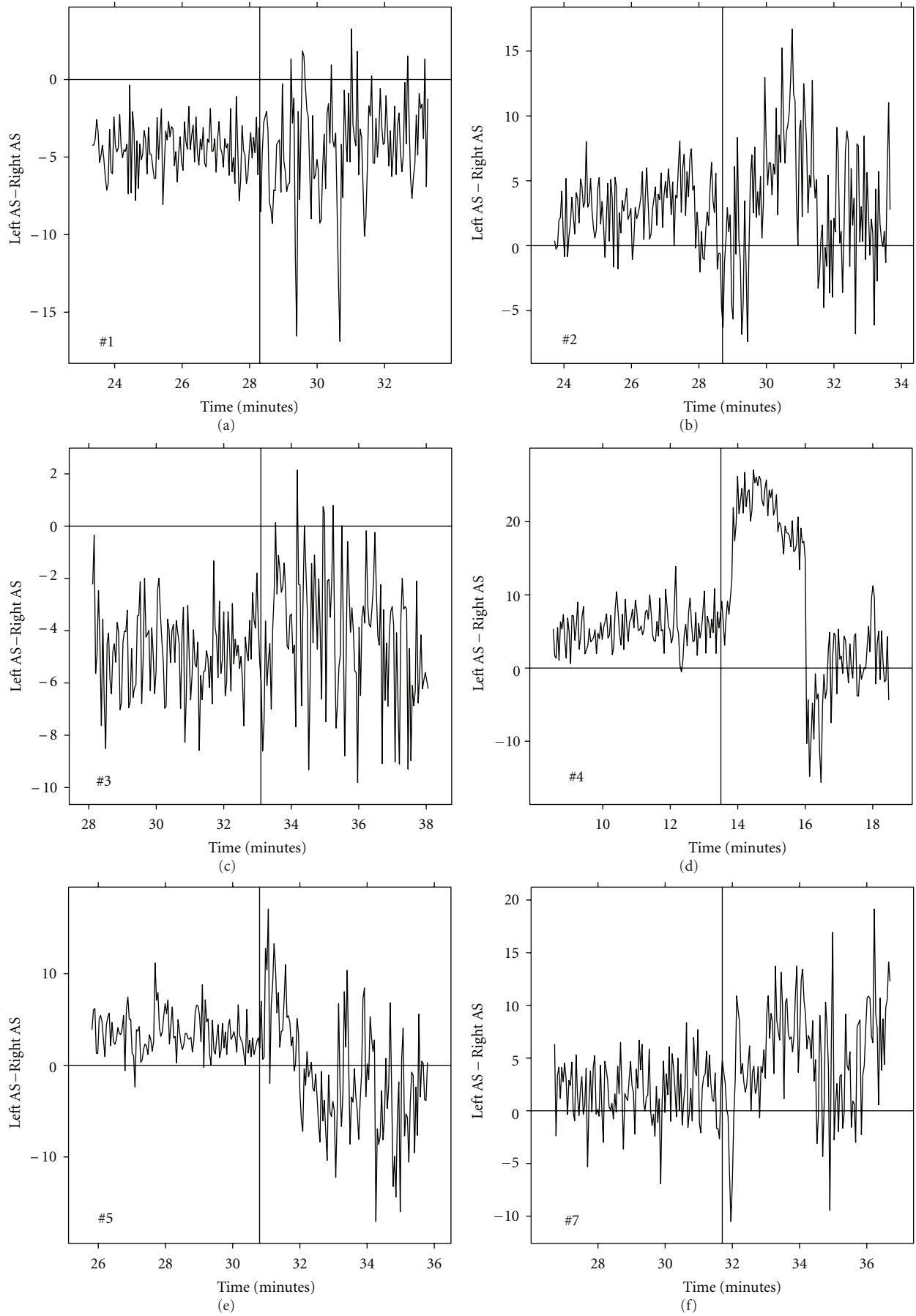


FIGURE 4: Desynchronization imbalances, as quantified by (3) for every mTLE patient.

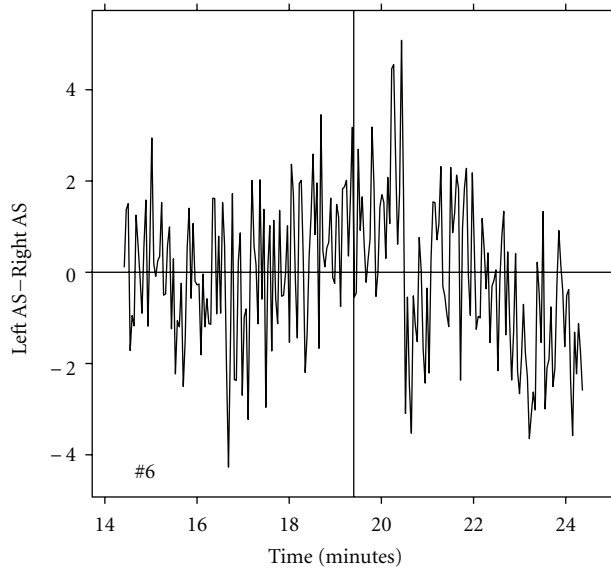


FIGURE 5: Desynchronization imbalances, as quantified by (3) in the only case of lateral TLE (patient no. 6).

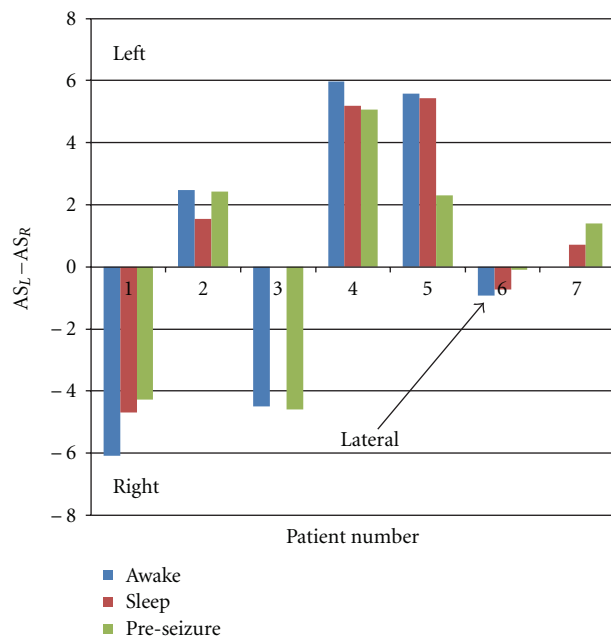


FIGURE 6: Average values of $LI_{AS} = \text{Left AS} - \text{Right AS}$, for every patient in three different situations. Blue bar corresponds to awake interictal stage, red bar to sleep interictal stage, and green bar to the pre-seizure stage.

synchronization between them, would promote epileptogenic activity. Once anomalous information is generated in this network, it would then spread to other mesial and lateral structures, reaching the neocortex (and thalamus) and becoming generalized. Failure in the network would be due to underlying structural pathology, such as hippocampal sclerosis or EC atrophy, which is the case in lesional TLE. In normal MRI patients, as in the case studied here, failure

in the network may be due to abnormal communication between underlying normal structures.

Our results are important from two points of view. First, the lateralization power displayed in cases of MTLE was achieved with a semi-invasive methodology, and second the methodology described here would reduce analysis time drastically. In one or two hours of interictal activity, it would be possible to draw reliable conclusions regarding lateralization, without the need to record actual seizure activity.

Author Disclosures

Jesús Pastor, Eduardo G. Navarrete, Rafael G. Sola and Guillermo J. Ortega have nothing to disclose.

Acknowledgments

G. J. Ortega is grateful to Rosario Ortiz de Urbina, head of Fundación Investigación Biomédica Hospital de la Princesa for her encouraging support. This work has been funded by grants from Fundación Mutua Madrileña, Instituto de Salud Carlos III, through PS09/02116 and PI10/00160 projects, and PIP no. 11420100100261 CONICET. G. J. Ortega is member of CONICET, Argentina.

References

- [1] S. S. Spencer and D. D. Spencer, "Entorhinal-hippocampal interactions in medial temporal lobe epilepsy," *Epilepsia*, vol. 35, no. 4, pp. 721–727, 1994.
- [2] T. Wehner and H. Lüders, "Role of neuroimaging in the presurgical evaluation of epilepsy," *Journal of Clinical Neurology*, vol. 4, no. 1, pp. 1–16, 2008.
- [3] N. Bernasconi, A. Bernasconi, Z. Caramanos, S. B. Antel, F. Andermann, and D. L. Arnold, "Mesial temporal damage in temporal lobe epilepsy: a volumetric MRI study of the hippocampus, amygdala and parahippocampal region," *Brain*, vol. 126, no. 2, pp. 462–469, 2003.
- [4] N. Bernasconi, A. Bernasconi, F. Andermann, F. Dubeau, W. Feindel, and D. C. Reutens, "Entorhinal cortex in temporal lobe epilepsy: a quantitative MRI study," *Neurology*, vol. 52, no. 9, pp. 1870–1876, 1999.
- [5] R. P. Carne, T. J. O'Brien, C. J. Kilpatrick et al., "MRI-negative PET-positive temporal lobe epilepsy: a distinct surgically remediable syndrome," *Brain*, vol. 127, no. 10, pp. 2276–2285, 2004.
- [6] J. Pastor, G. J. Ortega, I. Herrera-Peco et al., "Differential contribution of preoperative studies to diagnosis in temporal lobe epilepsy surgery," *Revista de Neurologia*, vol. 51, no. 7, pp. 393–402, 2010.
- [7] J. G. R. Jefferys, "Hippocampal sclerosis and temporal lobe epilepsy: cause or consequence?" *Brain*, vol. 122, no. 6, pp. 1007–1008, 1999.
- [8] D. King, S. S. Spencer, G. McCarthy, and D. Spencer, "Surface and depth EEG findings in patients with hippocampal atrophy," *Neurology*, vol. 48, no. 5, pp. 1363–1367, 1997.
- [9] F. Bartolomei, F. Wendling, J. -J. Bellanger, J. Régis, and P. Chauvel, "Neural networks involving the medial temporal structures in temporal lobe epilepsy," *Clinical Neurophysiology*, vol. 112, no. 9, pp. 1746–1760, 2001.

- [10] F. Bartolomei, F. Wendling, J. Régis, M. Gavaret, M. Guye, and P. Chauvel, "Pre-ictal synchronicity in limbic networks of mesial temporal lobe epilepsy," *Epilepsy Research*, vol. 61, no. 1–3, pp. 89–104, 2004.
- [11] S. Noachtar and J. Rémi, "The role of EEG in epilepsy: a critical review," *Epilepsy and Behavior*, vol. 15, no. 1, pp. 22–33, 2009.
- [12] G. J. Ortega, I. H. Peco, R. G. Sola, and J. Pastor, "Impaired mesial synchronization in temporal lobe epilepsy," *Clinical Neurophysiology*, vol. 122, no. 6, pp. 1106–1116, 2011.
- [13] J. Pastor, V. Hernando-Requejo, L. Domínguez-Gadea et al., "Impact of experience on improving the surgical outcome in temporal lobe epilepsy," *Revista de Neurología*, vol. 41, no. 12, pp. 709–716, 2005.
- [14] R. G. De Sola, V. Hernando-Requejo, J. Pastor et al., "Pharmacoresistant temporal-lobe epilepsy: exploration with foramen ovale electrodes and surgical outcomes," *Revista de Neurología*, vol. 41, no. 1, pp. 4–16, 2005.
- [15] H. G. Wieser, C. E. Elger, and S. R. G. Stodieck, "The 'foramen ovale electrode': a new recording method for the preoperative evaluation of patients suffering from mesio-basal temporal lobe epilepsy," *Electroencephalography and Clinical Neurophysiology*, vol. 61, no. 4, pp. 314–322, 1985.
- [16] H. G. Wieser and U. Schwarz, "Topography of foramen ovale electrodes by 3D image reconstruction," *Clinical Neurophysiology*, vol. 112, no. 11, pp. 2053–2056, 2001.
- [17] J. Pastor, R. G. Sola, V. Hernando-Requejo, E. G. Navarrete, and P. Pulido, "Morbidity associated with the use of foramen ovale electrodes," *Epilepsia*, vol. 49, no. 3, pp. 464–469, 2008.
- [18] W. H. Press, S. A. Teukolsky, W. T. Vetterling, and B. P. Flannery, *Numerical Recipes, The Art of Scientific Computing*, Cambridge University Press, 3rd edition, 2007.
- [19] M. G. Rosenblum, A. S. Pikovsky, J. Kurths, C. Schaefer, and P. Tass, "Phase synchronization: from theory to data analysis," in *Handbook of Biological Physics*, F. Moss and S. Gielen, Eds., Elsevier Science, Amsterdam, The Netherlands, 2001.
- [20] K. Schindler, H. Leung, C. E. Elger, and K. Lehnertz, "Assessing seizure dynamics by analysing the correlation structure of multichannel intracranial EEG," *Brain*, vol. 130, no. 1, pp. 65–77, 2007.
- [21] S. Knake, C. Triantafyllou, L. L. Wald et al., "3T phased array MRI improves the presurgical evaluation in focal epilepsies: a prospective study," *Neurology*, vol. 65, no. 7, pp. 1026–1031, 2005.
- [22] P. M. Phal, A. Usmanov, G. M. Nesbit et al., "Qualitative comparison of 3-T and 1.5-T MRI in the evaluation of epilepsy," *American Journal of Roentgenology*, vol. 191, no. 3, pp. 890–895, 2008.
- [23] A. J. Barkovich, H. A. Rowley, and F. Andermann, "MR in partial epilepsy: value of high-resolution volumetric techniques," *The American Journal of Neuroradiology*, vol. 16, no. 2, pp. 339–343, 1995.
- [24] M. J. Koeppe and F. G. Woermann, "Imaging structure and function in refractory focal epilepsy," *The Lancet Neurology*, vol. 4, no. 1, pp. 42–53, 2005.
- [25] N. F. Moran, L. Lemieux, N. D. Kitchen, D. R. Fish, and S. D. Shorvon, "Extrahippocampal temporal lobe atrophy in temporal lobe epilepsy and mesial temporal sclerosis," *Brain*, vol. 124, no. 1, pp. 167–175, 2001.
- [26] H. Duvernoy, *The Human Hippocampus*, Springer, New York, NY, USA, 3rd edition, 2005.
- [27] J. Pastor, L. M. de la Prida, V. Hernando-Requejo, and R. G. Sola, "Voltage sources in mesial temporal lobe epilepsy recorded with foramen ovale electrodes," *Clinical Neurophysiology*, vol. 117, no. 12, pp. 2604–2614, 2006.
- [28] F. Mormann, K. Lehnertz, P. David, and C. E. Elger C., "Mean phase coherence as a measure for phase synchronization and its application to the EEG of epilepsy patients," *Physica D*, vol. 144, no. 3, pp. 358–369, 2000.
- [29] F. Mormann, T. Kreuz, R. G. Andrzejak, P. David, K. Lehnertz, and C. E. Elger, "Epileptic seizures are preceded by a decrease in synchronization," *Epilepsy Research*, vol. 53, no. 3, pp. 173–185, 2003.