

Canine Distemper Infection in Crab-eating Fox (*Cerdocyon thous*) from Argentina

Hebe Ferreyra,^{1,5} Marina G. Calderón,² Damián Marticorena,³ Carolina Marull,¹ and Barrios Caro Leonardo⁴

¹Global Health Program, Wildlife Conservation Society, Gaona 360, B° Alto Alberdi, Córdoba City, C.P. 5003, Argentina; ²Centro de Virología Animal (CEVAN-CONICET), Centro de Ciencia y Tecnología “Dr. Cesar Milstein”, Saladillo 2468, C1440FFX Buenos Aires, Argentina; ³Facultad de Ciencias Veterinarias, Universidad Nacional de Buenos Aires, Argentina; ⁴Parque Nacional El Palmar, Entre Ríos, Argentina; ⁵Corresponding author (email: hferreyra@wcs.org)

ABSTRACT: Canine distemper virus (CDV) has been reported worldwide in wild carnivores and has been cited as the cause of population declines in some species. Crab-eating foxes (*Cerdocyon thous*) from El Palmar National Park, Argentina, were observed either dead or exhibiting clinical neurologic signs. Samples were taken from two individuals that were later found to be positive for CDV by direct immunofluorescence in brain tissue. Based on molecular studies, the CDV strain had a high percentage of identity compared to CDV strains affecting dogs in Argentina. This is the first report of CDV infection in wild carnivores in Argentina.

Key words: Argentina, canine distemper, *Cerdocyon thous*, crab-eating fox.

Viral diseases make up 56% of pathogens threatening wild carnivore populations worldwide (Pedersen, 2007), and canine distemper (CD) is probably the most important of these diseases. Several epidemic events originating in domestic dogs have been well studied and documented in wild carnivores (Alexander and Appel, 1994; Cleaveland et al., 2000). Susceptibility to canine distemper virus (CDV) has been observed in gray fox (*Urocyon cinereoargenteus*; Davidson et al., 1992), African wild dog (*Lycaon pictus*; Van de Bildt et al., 2002), black-footed ferret (*Mustela nigripes*; Williams et al., 1998), African lions (*Panthera leo*), and spotted hyenas (*Crocuta crocuta*; Roelke-Parker et al., 1996). Recently, CDV was determined to be the cause of death of a crab-eating fox (*Cerdocyon thous*) in Brazil (Megid et al., 2009).

During 2006, an apparent decrease in the population of crab-eating foxes in El Palmar National Park, Entre Ríos Prov-

ince, Argentina (31°51'S, 58°13'W) was noted by the park rangers who regularly patrol the park and keep a record of wildlife sightings. Coinciding with this apparent population reduction, six foxes were found dead that same year. In 2007, three foxes were observed with locomotion problems (paresis), and an adult male crab-eating fox showing clinical neurologic signs (paresis, self mutilation, chewing, and abnormal behavior) was discovered inside the park buildings, beside the decomposing carcass of another crab-eating fox (only bones and hair remained). A few days later, a female fox was found dead and partially scavenged. The male with neurologic signs was euthanized, and necropsies were performed on both animals. Due to the aforementioned clinical signs observed in one of the animals, priority was given to analyses for rabies and CDV. The heads of both foxes were sectioned and sent refrigerated to Luis Pasteur Zoonosis Institute (Av. Diaz Velez 4821, Buenos Aires, Argentina) for rabies diagnosis using direct immunofluorescence and confirmation by biologic tests. Once rabies was ruled out as a cause of death, sections of cerebrum and cerebellum, which were stored frozen at -70 C, were sent to the Veterinary School of the University of Buenos Aires to be analyzed by direct immunofluorescence with monoclonal anti-CDV antibodies. Park workers had frozen the dead animals, which destroyed tissue structure and made it impossible to obtain valid diagnostic histopathologic results.

TABLE 1. Percent sequence identity among vaccines (Onderstepoort, Convac, and Snyder Hill), Argentine domestic dogs (Arg 1, 2, 3, 23), Argentine fox, and Italian (dog and fox) CDV strains in the 871-bp fragment of the H gene.

Convac	SnyHill	Arg1	Arg2	Arg3	Arg23	ArgFox	dogIt	RedFoxIt	
95.5	92.8	88.3	89.3	88.6	88.6	89	89	89	Ond
	95.2	89.7	90.7	89.7	90	90.3	90.3	90.3	Convac
		90.7	91	90	89.7	90.3	90.3	89.7	SnyderHill
			98.3	97.2	95.5	98.3	95.2	93.4	Arg 1
				97.6	95.2	99.3	96.2	94.1	Arg 2
					94.8	97.6	95.2	93.4	Arg 3
						95.2	96.2	93.8	Arg 23
							95.5	93.4	ArgFox
								94.8	dogIt

Both animals were found to be positive for CDV by direct immunofluorescence. Subsequently, samples of cerebrum and cerebellum from the euthanized male (samples from the female were in poor condition) were sent to the Animal Virology Center (Centro de Ciencia y Tecnología “Dr. Cesar Milstein” CONICET) for molecular analysis. Total RNA was extracted directly from the frozen cerebellum sample with Trizol® Reagent (Life Technologies, Carlsbad, California, USA) following manufacturer’s instructions. A reverse transcription–polymerase chain reaction (RT-PCR) analysis was performed on this sample to detect a 287 base-pair (bp) fragment within the highly conserved region of the NP gene of CDV. No positive results were obtained from the original RNA extracted from cerebellum or RNA dilutions (–3, –4), while positive controls (vaccine strains and local CDV dog strains) gave the expected molecular weight bands (data not shown). Primer sequences were as reported by Frisk et al. (1999). Because no specific bands of the NP gene were obtained, the sample was further screened by amplification of an 871-bp fragment of the H gene with the primers CDVF10B and CDV-R10 (Hashimoto et al., 2001). In this case, we were able to detect this amplicon (position 7991–8861 of the CDV Ond strain) in the fox sample, which was then digested

with the restriction enzyme *NdeI* (Promega, Madison, Wisconsin, USA), and sequenced. Two fragments were observed as consistent with local CDV dog strains (Calderon et al., 2007). For sequencing, the blunt-ended 871 bp was cloned into the pGEM®-T vector (Promega). Competent cells (*Escherichia coli* DH5α) were transformed, plated on LB/ampicillin/isopropyl β-D-thiogalactoside/5-bromo-4-chloro-3-indolyl-β-D-galactoside plates, and incubated overnight at 37 C. Two recombinant plasmids were sequenced in both directions (sp6 and T7) by MacroGen Inc. (Rockville, Maryland). Sequence analysis was performed using Clustal W. The H gene amino acid (aa) sequence accession numbers in the GenBank database are as follows: Arg 1 (AM422846), Arg 2 (AM422847), Arg 3 (AM422848), Arg 23 (AM422868), 111/03B Italian dog (DQ494319), 207/00 RedfoxItaly (DQ228166), and vaccine strains are: Snyder Hill (AAG15490), Convac (CAA84626), and Onderstepoort (AAC26995). The sequence obtained from this report is CDV Fox Arg 2007 (EU624414).

Molecular analyses of the 871-bp fragment in the H gene obtained from the CDV fox strain showed a high degree of identity when compared with CDV strains from dogs in Argentina (95.2–99.3%). In contrast, the fox strain showed a lower (89–90.3%) degree of identity with vaccine strains used as controls (Table 1 and Fig. 1).

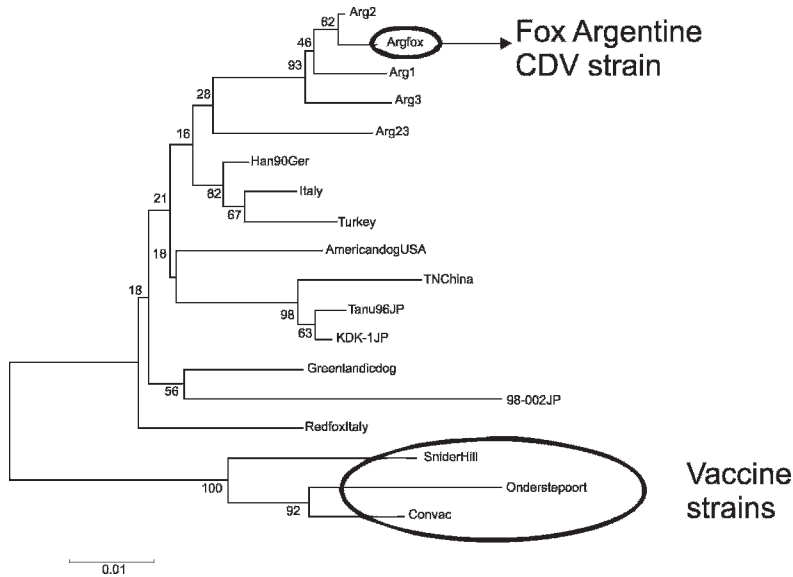


FIGURE 1. Phylogenetic analysis of the deduced amino-acid sequences of CDV hemagglutinin gene fragments from vaccines, local and worldwide strains. Arg 1, 2, 3, 23, and Argfox: Argentine strains belonging to dogs and fox, respectively. Branch lengths indicate phylogenetic distances calculated from distance matrices of deduced amino-acid sequences. Sequence accession numbers are listed in the text.

To our knowledge, this is the first report of CDV infection in free-ranging wild carnivores in Argentina. Megid et al. (2009) recently reported CDV infection in the same fox species in Brazil. Both almost-simultaneous reports alert us to the fact that domestic dog viruses could pose a threat to wild carnivores in the region.

While clinical symptoms and serologic and histopathologic evidence led to the suspicion of distemper infection in a fox (*Pseudalopex griseus*) in Chile (González-Acuña et al., 2003) and in another suspected episode in the same species in 2003 (Berríos and Duran, 2005), the presence of the virus could not be confirmed in these cases. Neurologic manifestations of CDV in dogs may include hyperesthesia, seizures, cerebellar and vestibular signs, and paraparesis or tetraparesis (i.e., involuntary twitching of muscles in a forceful simultaneous contraction, often leading to “chewing gum” fits). Symptoms, however, can be highly variable due to differences in species, age, viral strain, and immune status of the host

(Williams et al., 1998; Deem et al., 2000). In our study, the observed clinical signs were not pathognomonic but were compatible with CDV infection. Therefore, the detection of CDV in brain tissue, the clinical signs observed, and the fact that wild carnivores are highly susceptible to the virus (Deem et al., 2000) support the hypothesis that the cause of death was CD. Even though Aujeszky disease could be considered as an alternative diagnosis in these cases, and there were insufficient samples to rule it out, our diagnosis of CD was confirmed by the presence of CDV. In Argentina, CD is very common in dogs, while Aujeszky disease has not been reported in either wild or domestic carnivores. Unfortunately there have been no previous serologic studies of the fox population or on-site monitoring of crab-eating fox populations. The only historic information prior to these events was registered in the observations and reports of park rangers. Park rangers had never observed animals with these clinical signs since the creation of the national park in

1965 (G. Gill, pers. comm.). Reports of dead animals began in 2006, 6 mo after a plan for the control of exotic species was initiated in the park. This plan authorized the entrance of hunters and their dogs into the protected area. Also, adjacent to the park, there is a high density of unvaccinated free-roaming dogs belonging to local residents. In addition, tourists are allowed to enter the park with their dogs. Regrettably, there is no local veterinarian (the closest is 50 km away) who could provide us with information on a possible CDV epidemic in local dogs at the same time of these observations in foxes. Regardless, CD is common in Argentina, and numerous opportunities exist for interactions between dogs and foxes. Nonetheless, the possibility that the virus might be endemic in the park's carnivore community should not be excluded. However, circulation in wild carnivores over a long period of time warrants some phylogenetic divergence, so given the similarity of the isolated strain with domestic dog viruses, it is very probable that infection was recent, and that dogs played a role in its introduction. In El Palmar National Park, crab-eating foxes live in sympatry with other wild carnivore species, such as the gray fox (*Lycalopex gymnocercus*), and species declared to be of special interest such as the neotropical river otter (*Lontra longicaudis*), crab-eating raccoon (*Procyon cancrivorus*), and the lesser grison (*Galictis cuja*), which could also be potentially susceptible. Mortality or morbidity in these species was not observed, and their populations apparently are not declining; however, these species are not as conspicuous and regularly observed as crab-eating foxes, so disease-related morbidity and mortality could be underestimated.

Although the data gathered are not enough to confirm a causation link between CDV and the fox population decline, the facts and context here documented are suggestive of a CD epidemic in the fox population of El Palmar

National Park. Disease prevention strategies in conservation areas in Argentina are scarce, and risk of disease transmission between populations of wild and domestic animals is highly feasible. In this light, the integration of health sciences with conservation policies will be pivotal in promoting preventive health measures, particularly in protected areas and their buffer zones.

We gratefully thank the head of El Palmar National Park, Parkguard A. Maranta Ochoa, and biologists P. Cichero and G. Gil from Delegación Técnica del Nordeste de Parques Nacionales for providing authorizations to conduct this study and partial financing of the research. Special thanks are due to P. Beldomenico and M. Uhart and two anonymous reviewers for their invaluable contributions to the improvement of this manuscript.

LITERATURE CITED

- ALEXANDER, K. A., AND M. J. G. APPEL. 1994. African wild dogs (*Lycan pictus*) endangered by a canine distemper epizootic among domestic dogs near the Masai Mara National Reserve, Kenya. *Journal of Wildlife Diseases* 30: 481–485.
- BERRÍOS, P., AND C. DURAN. 2005. Principales enfermedades virales de los caninos. Situación en Chile. *Monografías electrónicas de Patología Veterinaria* 2: 68–93.
- CALDERON, M. G., P. REMORINI, O. PERIOLLO, M. IGLESÍAS, N. MATTION, AND J. LA TORRE. 2007. Detection by RT-PCR and genetic characterization of canine distemper virus from vaccinated and non-vaccinated dogs in Argentina. *Veterinary Microbiology* 125: 341–349.
- CLEAVELAND, S., M. J. APPEL, W. S. K. CHALMERS, C. CHILLINGWOETH, M. KAARE, AND C. DYE. 2000. Serological and demographic evidence for domestic dogs as a source of canine distemper virus infection for Serengeti wildlife. *Veterinary Microbiology* 72: 3–4.
- DAVIDSON, W. R., V. F. NETTLES, L. E. HAYES, E. W. HOWERTH, AND C. EDWARD COUVILLION. 1992. Disease diagnosed in gray foxes (*Urocyon cinereoargenteus*) from the southeastern United States. *Journal of Wildlife Diseases* 28: 28–33.
- DEEM, S. L., L. H. SPELMAN, R. A. YATES, AND R. J. MONTALI. 2000. Canine distemper in terrestrial carnivores: A review. *Journal of Zoo and Wildlife Medicine* 31: 441–451.
- FRISK, A. L., M. KONING, A. MORITZ, AND W. BAUMGARTNER. 1999. Detection of canine distemper virus nucleoprotein RNA by reverse

- transcription-PCR using serum, whole blood, and cerebrospinal fluid from dogs with distemper. *Journal of Clinical Microbiology* 37: 3634–3643.
- GONZÁLEZ-ACUÑA, D., R. ORTEGA-VASQUEZ, P. RIVERA-RAMÍREZ, AND J. CABELLO-CABALIN. 2003. Verdacht auf Staupe beim Graufuchs (*Pseudalopex griseus*) im mittleren Chile (Fallbericht). *Zeitschrift für Jagdwissenschaft* 49: 1–4.
- HASHIMOTO, M., Y. UNE, AND M. MOCHIZUKI. 2001. Hemagglutinin genotype profiles of canine distemper virus from domestic dogs in Japan. *Archives of Virology* 146: 149–155.
- MEGID, J., V. A. FEIJÓ DE SOUZA, C. R. TEIXEIRA, A. CORTEZ, R. L. AMORIN, M. B. HEINEMMAN, D. Q. CAGNINI, AND L. J. RICHTZENHAIN. 2009. Canine distemper virus in a crab-eating fox (*Cerdocyon thous*) in Brazil: Case report and phylogenetic analyses. *Journal of Wildlife Diseases* 40: 527–530.
- PEDERSEN, A. B., K. E. JONES, C. L. NUNN, AND S. ALTIZER. 2007. Infectious diseases and extinction risk in wild mammals. *Conservation Biology* 21: 1269–1279.
- ROELKE-PARKER, M. E., L. MUNSON, C. PACKER, R. KOCK, S. CLEAVELAND, M. CARPENTER, S. J. O'BRIEN, A. POSPISCHILL, R. HOFMANN-LEHMANN, H. LUTZ, G. L. MWAMENGELE, M. N. MGASA, G. A. MACHANGE, B. A. SUMMERS, AND M. J. G. APPEL. 1996. A canine distemper virus epidemic in Serengeti lions. *Nature* 379: 441–445.
- VAN DE BILDT, M. W. G., T. KUIKEN, A. M. VISEE, S. LEMA, T. R. FITZJOHN, AND A. D. M. E. OSTERHAUS. 2002. Distemper outbreak and its effect on African wild dog conservation. *Emerging Infectious Diseases* 8: 211–213.
- WILLIAMS, E. S., E. T. THOME, M. J. G. APPEL, AND D. W. BELITSKY. 1998. Canine distemper in black-footed ferrets (*Mustela nigripes*) from Wyoming. *Journal of Wildlife Diseases* 24: 385–398.

Received for publication 5 June 2008.