

# Clinical effects of insular damage in humans

Agustin Ibañez · Ezequiel Gleichgerrcht ·  
Facundo Manes

Received: 3 December 2009 / Accepted: 21 April 2010 / Published online: 29 May 2010  
© Springer-Verlag 2010

**Abstract** Multiple disturbances following lesions of the insula are reviewed in the present article, including those related to autonomic function; gustatory, olfactory, auditory, somatosensory, and multimodal perception, as well as body awareness; the emotion of disgust; mood and willed action, addiction behavior, and language. Given the multiple and varied nature of the impairments revealed by lesion studies, we suggest that the insula, as a multimodal area, has a major role as a convergence zone implicated in the coordination between internal and external information through emotional subjective awareness. Methodological issues are discussed with attention paid to lesion etiology, and lesions involving adjacent areas to the insular cortex.

**Keywords** Insula · Lesion · Awareness · Interoception · Perception · Emotion · Autonomic system

## Introduction

Since its early descriptions by Reil (1809), it has been recognized that the insula is connected to several other structures within the brain. Anatomically, it is in close proximity to the frontal, parietal, and temporal cortices, all of which contribute (orbital, frontal, frontoparietal, and temporal opercula) to the seclusion of the insular cortex deep inside the lateral fissure of the brain (Fig. 1). The association between the insula and other neocortical areas goes well beyond its mere anatomical location. Diffusion tensor imaging-based tractography (e.g. Kalani et al. 2009) has contributed to the characterization of an extensive network of afferent and efferent pathways connecting it to frontal, parietal, and medial temporal structures, including the amygdala, the uncinate fasciculus, internal capsule fibers, and the arcuate fasciculus. Furthermore, links to the basal ganglia via the claustrum and striatum, as well as the thalamus, olfactory cortex and limbic structures have been identified (Augustine 1996). The insula can also be related to the aforementioned cortices, as they are all supplied by branches of the middle cerebral artery (MCA).

It is not surprising that a plethora of cognitive and autonomic functions, as well as lateralization effects have been attributed to the insular cortex. Nonetheless, because of the connections with multiple structures, being able to isolate the real contribution of the insula per se to physiological and cognitive phenomena has been challenging. Lesion studies have been used extensively in neurosciences and the insula has been no exception to this methodological approach. At least three major types of lesions have been identified and investigated in the human insular cortex: vascular, tumoral, and traumatic brain injury (TBI).

There is an important methodological problem with the selection of pathology that can potentially affect

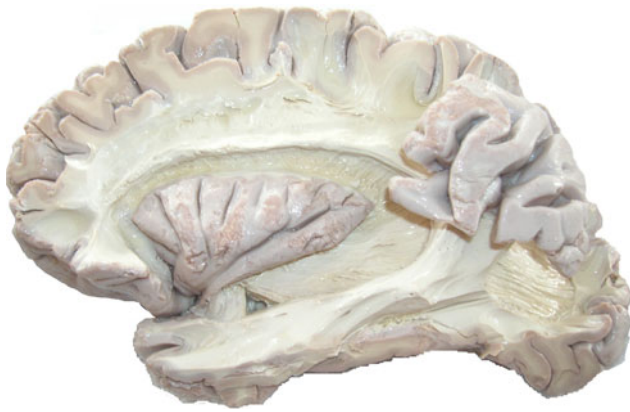---

A. Ibañez · E. Gleichgerrcht · F. Manes (✉)  
Institute of Cognitive Neurology (INECO),  
Castex 3293 (CP 1425), Buenos Aires, Argentina  
e-mail: fmanes@neurologiacognitiva.org  
URL: <http://www.neurologiacognitiva.org/>

A. Ibañez  
Laboratory of Cognitive Neuroscience,  
Universidad Diego Portales, Santiago, Chile

A. Ibañez  
National Scientific and Technical Research Council  
(CONICET), Buenos Aires, Argentina

A. Ibañez · F. Manes  
Institute of Neurosciences Favaloro University,  
Buenos Aires, Argentina



**Fig. 1** Lateral view of human insula exposed by the removal of overlying opercula. Note the close proximity of the frontal, parietal, and temporal cortices which contribute to the seclusion of the insular cortex deep inside the lateral fissure of the brain. Reproduced with the permission of the Museum of neuroanatomy Tomas A Mascitti; Institute of Cognitive Neurology (INECO)

comparisons across studies, especially when group studies are considered. For example, an infarction, intraparenchymal hemorrhage, TBI, or tumours, and neurodegenerative diseases lead to lesions with different forms of neuropathology. To explain this, it is critical to have a detailed understanding of the way in which these patient groups arise. Infarctions may be localized or generalized—resulting in distinct patterns of injury. Intracerebral hematomas damage the neural tissue such as non-hemorrhagic infarctions and invade the space between neurons, as it occurs with tumors. When arterial aneurysms rupture, they typically cause subarachnoid hemorrhage. Although meningiomas are well-circumscribed benign tumors, gliomas, over time, may progress into the anaplastic variant, which in turn may progress to a glioblastoma. It should also be mentioned that, usually, patients who underwent surgery for brain tumors tend to have additional damage of healthy brain tissue from surgery. TBI causes not only a focal brain injury, but involves diffuse injury, which may not show on CT or MRI scans. The most common mass lesions seen after TBI are hematomas and contusions. However, TBI can also produce microscopic changes that cannot be seen on CT scans and that are scattered throughout the brain. This category of injuries is usually referred to as diffuse brain injury, which can occur with or without an associated mass lesion. One type of diffuse brain injury is diffuse axonal injury. On the basis of the above description, we only included for this review patients with focal lesions due to stroke.

Understanding the vascular contribution to the insular cortex is essential in interpreting the results of lesion studies following stroke. First, it must be noted that detailed anatomic descriptions of its vasculature reveal that

arterial contributions to the insular cortex exclusively originate from the MCA, especially from its superior segment (Varnavas and Grand 1999). Besides the insular cortex, insular arteries also supply the extreme capsule, the claustrum and external capsule, and larger insular arteries, extending branches to the medial surfaces of the frontal, temporal, and parietal opercula have been found (Türe et al. 2000). Thus, encountering isolated, focal insular cortex infarction following MCA stroke is markedly unusual. For example, out of 4,800 consecutive first ever acute stroke patients, only four were found to have truly isolated infarction of the insular cortex (Cereda et al. 2002). In this sense, one could question the extent to which autonomic, cognitive, and behavioral changes described by various studies of patients with MCA territory stroke involving the insula are really the result of lesions to the latter, rather than due to extensive MCA territory involvement. For instance, in a recent study, acute infarction involving the insula was associated with a twofold increase in mortality after stroke, but such increased rates disappeared when adjusted for overall infarct volume (Borsody et al. 2009).

Tumorigenesis occurring at the insular cortex is not uncommon. As proposed by Kalani et al. (2009), it is possible that populations of adult neural stem cells housed in structures adjacent to the insula, such as the subventricular zone (Luskin and Boone 1994) and the hippocampus (Palmer et al. 1997) may develop into glioblastomas, which are the most common form of neoplasm occurring in the insula. There are two major issues to consider in lesion studies involving insular gliomas. On the one hand, the vast number of connections with adjacent structures certainly results in increased proneness for metastatic distribution of tumoral cells to adjacent structures, mainly within the temporal lobes (Kalani et al. 2009). On the other hand, resection of insular gliomas, even through microsurgery (Simon et al. 2009), may inevitably affect afferent and efferent projections to related structures. Similarly, when considering surgical treatment of epilepsy arising from the insular cortex, one must consider the high risk for involvement of adjacent and related structures. Although resection of insular lesions in both cancer and epilepsy surgery has been shown to be successful in seizure control (e.g. Roper et al. 1993; Malak et al. 2009; von Lehe et al. 2009), the interpretation of psychological disturbances following these procedures must be interpreted in the context of the complex interaction between the insula and its adjacent structures.

The present review explores the multiple disturbances that have been described following lesions to the insula affecting autonomic functions; gustatory, olfactory, auditory, somatosensory, and multimodal and supramodal perception, as well as body awareness; the emotion of disgust; mood and willed action, addition behavior, and

even language. Lesion studies and related neuroimaging reports suggest that the insula, by means of its multimodality, may play an important role as a convergence zone implicated in the coordination between internal and external information through emotional subjective awareness.

### Clinical and cognitive manifestations of insular stroke

#### Autonomic functions

The association between insular cortex and autonomic control has been extensively studied in the past two decades, but its role in the modulation of autonomic functions, especially cardiovascular, remains controversial. For instance, a study by Fink et al. (2005) suggested that insular infarction may not be directly linked to clinically significant cardiovascular events. The authors examined 150 patients who presented an acute MCA stroke and, of the 72 (38 right, 34 left) in which the lesion involved the insular cortex and they found that no single patient had purely isolated infarction of the insular cortex without involvement of other structures within the MCA territory. Moreover, ECG changes—mainly, ST–T wave abnormalities—were present in 29 out of these 72 patients, but were also present in 23 out of the 78 patients with no insular infarction. These results may be explained by the involvement of adjacent brain regions resulting from MCA stroke which spanned to other structures within the MCA territory. Potentially, the involvement of these structures on cardiovascular functions could have contributed to the ECG abnormalities observed. More recently, however, Christiansen et al. (2005) demonstrated that stroke-induced insular lesions were associated with ST abnormalities, significantly higher rates of sinus tachycardia, as well as ectopic beats. Although the exact nature of the cardiovascular abnormalities resulting from insular cortex lesion remains unclear and there is a substantial amount of evidence to assume that the insula may indeed be a site of origin for cerebrogenic sudden death (Cheung and Hachinski 2000). In fact, clinical outcome seems to differ depending on the side of the brain in which insular lesion occurs and such asymmetry in the anatomical distribution of autonomic, especially cardiovascular, responses has been widely researched in both animal and human subjects. For example, intraoperative stimulation of epileptic patients showed asymmetrical distribution of sympathetic and parasympathetic efferent pathways. Basically, stimulation of the left insular cortex was associated with bradycardia and depressor effects, while right insular cortex stimulation triggered tachycardia and pressor responses with more frequency (Oppenheimer et al. 1992). This is in

accordance with the results reported by other authors who found similar differential response patterns in experimental studies with animals, which were rather associated with rostrocaudal asymmetries (Yasui et al. 1991). Many times, lesion studies in humans overlook the comparison of rostral versus caudal insular portions because of the sometimes arbitrary limits of this anatomical axis in a structure like the insula.

The role of the insula in autonomic functions is not contentious, and its involvement in the expression of cardiovascular activity has been consistently described, as well as its function in modulating other vital structures, such as those of the immune system. Nonetheless, the exact nature of its regulatory activity remains controversial.

#### Taste and gustatory perception

The insula is a relevant area for taste processing (Small et al. 1999) and is considered, together with the most lateral point of the postcentral gyrus, the primary gustatory area (Sewards and Sewards 2001). A taste-responsive region has been reported in the insula (Kobayashi et al. 2002; Small et al. 2003). On the other hand, the insula has projections from the primary olfactory cortex (Carmichael et al. 1994) and neuroimaging studies have shown insular responsivity to odors (e.g., de Araujo et al. 2003; Frasnelli et al. 2009). In fact, taste and smell processing are often experienced together and seem to be partially overlapping in the brain (Stevenson et al. 2008). Neuroimaging studies have reported insular activation, as well as activation of the opercular cortex, in response to tastes and smells presented independently and together as flavor (de Araujo et al. 2003; Small et al. 2003, 2004).

Several studies of insular lesions have reported deficits in gustatory perception (e.g., Cereda et al. 2002; Pritchard et al. 1999; Small et al. 1999; Schafe and Bernstein 1998). It has been suggested that ipsilateral tongue taste intensity is affected by insular lesions (e.g., Mak et al. 2005; Pritchard et al. 1999; Cereda et al. 2002). Olfactory deficits due to insular lesions are nonetheless scarcer than gustatory deficits. One particular case report of a 70-year-old patient with a lesion comprising two-thirds of the left insula and extending into the supramarginal gyrus was tested with fourteen odors presented orthonasally by waving saturated filter paper (Mak et al. 2005). The rates of odors contralateral to the lesion were stronger than the ipsilateral side. Particularly, unpleasant odors had decreasing intensity rates for odors presented to the left compared with the right nostril. This result is consistent with neuroimaging studies observing maximal responsiveness in the left insula to right nostril stimuli (Savic and Gulyas 2000). Another study (Stevenson et al. 2008) has reported odor-induced taste impairments in patients with insular lesions. Those reports

suggest that the insula is a center for multisensory processing related to circuits that simultaneously mediate the perception of taste quality and also the perception of odor-induced taste quality.

### Auditory processing

Classic early studies have identified responsive units to auditory stimuli in the insular cortex (Sudakov et al. 1971). The insula has connections with the medial geniculate nucleus, the primary and association auditory areas, as well as with the temporal pole and the superior temporal sulcus (Augustine 1996; Mesulam and Mufson 1982a, b). As detailed below, the insula is part of the vestibular system. Neuroimaging studies have confirmed the role of auditory processing of the insula (Bamiou et al. 2003; Griffiths et al. 1997; Platel et al. 1997).

Impaired auditory central function has been reported in case studies following insular stroke (Spreen et al. 1965; Hyman and Tranel 1989; Fifer 1993). Bamiou et al. (2006) reported eight patients with unilateral stroke in insula and adjacent areas and eight neurologically normal controls. They assessed pure-tone audiometry/tympanometry, and a central auditory test battery. Patients with insular lesions presented deficits in central auditory function, and especially temporal resolution and sequencing. Three of the patients with preserved primary and association auditory cortex and with relatively preserved cognitive functioning presented nonetheless abnormal auditory test performances. In agreement with the left-auditory cortex specialization hypothesis of temporal processing (Zatorre 2001), the scores of the duration pattern test were worse in cases of lesions in left sides.

Despite these well-established roles of insular cortex in auditory processing, the close proximity of the insula to the primary auditory cortex and auditory association cortex can imply possible confounds: some auditory disturbances could be actually the result of auditory cortex damage as opposed to insular cortex damage.

### Somatosensory systems (SSs) and pain

The SS provides information about body parts and body schematas, localization of touch, stroking and pain, features of external stimulus, and is implicated in all physiological motor actions. Although to some extent controversial, a two-pathway model has been proposed (Dijkerman and de Haan 2007): (1) the recognition–perception pathway (from the anterior parietal cortex via secondary somatosensory cortex to the posterior insula) and (2) an action-related pathway (mainly terminated in the posterior parietal cortex). In fact, research in animal models has suggested the major portion of granular insula is exclusively devoted to

somatic processing (Schneider et al. 1993). At the same time, fMRI studies have suggested that the separation between the cortical processing of visceral and somatosensory stimuli is lowest in the insular cortex (Eickhoff et al. 2006), supporting the integrative role of the insula for a variety of somatosensory processes (Table 1).

Lesion studies support the two-pathway model, but the insular role seems to include more basic somatosensory processes and bodily awareness. Moreover, the insula would play an important integrative role (Eickhoff et al. 2006) in the emergence of awareness related to the monitoring of the somatosensory function (Spinazzola et al. 2008). Studies with human patients with insular or retro-insular lesions reported tactile agnosia (Bohlhalter et al. 2002; Caselli 1991) and tactile object recognition (Reed et al. 1996), but in those studies, parts of the posterior parietal cortex were also affected. Bodily awareness seems to be affected too in patients with lesions of the insula, who may experience somatic hallucinations, somatoparaphrenia (Roper et al. 1993) and sensory self-monitoring deficits (Spinazzola et al. 2008). Somatosensory deficits in three patients with posterior insular stroke, as well as transient somatoparaphrenia, hemisensory deficits for all modalities, hypesthesia, graphesthesia and stereognosis in right insular lesions have all been reported (Cereda et al. 2002, see also Bottini et al. 2002; Moro et al. 2004). Posterior insular lesions have been linked to deficits in bodily awareness (Karnath et al. 2005). Moreover, most of these studies reporting bodily awareness impairments are related to right side insular lesions (see Table 2; Karnath and Baier (2010); for an account of right insular lesions).

**Table 1** Multimodal neglect findings

Test	Left insula <sup>b</sup>	Right insula <sup>b</sup>
DSS visual left	9.8 ± 1.3	6 ± 1.5
DSS visual right	9.6 ± 0.4	9.2 ± 0.4
DSS visual both	9.4 ± 0.3	8.5 ± 0.3
DSS auditory left	9.3 ± 0.8	9.2 ± 0.7
DSS auditory right	10	10
DSS auditory both <sup>a</sup>	8.4 ± 0.9	3.5 ± 1
DSS somesthetic left	10	6.2 ± 1.4
DSS somesthetic right	10	9.7 ± 0.1
DSS somesthetic both <sup>a</sup>	9.8 ± 0.7	3.2 ± 0.8
LBT 20	9.8 ± 0.3	10.8 ± 0.3
LBT 40 <sup>a</sup>	19.6 ± 0.5	21.8 ± 0.5
LBT 60 <sup>a</sup>	29.3 ± 0.4	33.3 ± 0.5

DSS double simultaneous stimulation, LBT line bisection test

<sup>a</sup>  $P < 0.05$

<sup>b</sup> Values are given in mean and SD millimeters from left, reproduced from Manes et al. (1999b)

**Table 2** Summary of studies reviewed

A. Features of lesion studies		B. Affected subjective awareness and internal–external milieu						
Studied Function	Representative Study	Insular area	Other areas	Perception	Interoception	Awareness	Emotion	Sympathetic/parasympathetic functions
Autonomic	Fink et al. (2005)	Bilateral anteroposterior	Adjacent and non-adjacent					Cardiovascular involvement
	Christiansen et al. (2005)	Left and right	Adjacent and non-adjacent					Cardiovascular involvement
	Cheung and Hachinski 2000	Review of multiple lesion types						Cerebrogenic sudden death
	Oppenheimer et al. (1992)	Left and right (stimulation)						Asymmetries of sympathetic and parasympathetic functions
Perceptual	Pritchard et al. (1999)	Left	Adjacent	Taste		Ipsilateral taste intensity awareness		
	Mak et al. (2005)	Left	Adjacent	Taste and olfaction		Ipsilateral olfactory awareness		
	Stevenson et al. (2008)	Multiple	Adjacent and non-adjacent	Multisensory (taste–gustatory)		Odor-induced taste quality awareness		
	Bamiou et al. (2004)	Left and right	Adjacent	Auditory (temporal resolution and sequencing)		Temporal awareness		
Somatosensory	Karnath et al. (2005)	Right posterior	Adjacent and non-adjacent	Object recognition		Multiple bodily awareness involvement		
	Bottini et al. (2002)				Multiple somatosensory abnormalities			
	Moro et al. (2004)							
Vestibular	Cereda et al. (2002)	Right (posterior)	Adjacent		Supramodal (vestibular and somato-propiception)	Elementary sensations		
Pain processing	Moisset and Bouthassira 2007 (Schnitzler and Plover 2000)	Multiple (predominantly anterior)	Adjacent and non-adjacent	Pain thresholds	Hypalgesia Pain thresholds	Pain awareness		
	Bowsher et al. (2004)	Posterior	Adjacent	Pain-related sensations	Allodynia and thermal sensation	Thermal awareness		
Stimuli awareness	Manes et al. (1999a)	Right insular	Adjacent	Multisensory and supramodal neglect	Somesthetic neglect	Interoceptive–exteroceptive awareness		Affective–emotional aspects of pain



Table 2 continued

A. Features of lesion studies		B. Affected subjective awareness and internal–external milieu						
Studied Function	Representative Study	Insular area	Other areas	Perception	Interoception	Awareness	Emotion	Sympathetic/parasympathetic functions
Emotion	Calder et al. (2000)	Left	Adjacent and Caudate nucleus	Multisensory and supramodal deficits in emotion of disgust		Experience of disgust	Self-other recognition of disgust	
Mood and willed action	Manes et al. (1999b)	Right			Anergia, underactivity and tiredness	Willed action and voluntary motor behavior	Depression and mood symptoms	
Language production	Carota et al. (2007)	Left	Adjacent					
Verbal memory	Manes et al. (1999c)	Left					Explicit recovery and delayed recall.	
Smoking behavior	Naqvi et al. (2007)	Multiple	Adjacent		Bodily states		Explicit motivational process and urges to take drugs	Emotional regulation

A. Main features of studies, B. Core process implicated in the hypothesis of insula involvement in subjective awareness of internal–external milieu

The integration of the different body parts with respect to one another is a relevant aspect of the somatosensory system, typically achieved through the integration of visual and proprioceptive inputs together with vestibular inputs. The posterior insula is part of the human vestibular cortex, probably homologous to the parieto-insula vestibular cortex in monkeys (Brandt 1999). Vestibular-like syndrome with dizziness, tandem gait instability, tendency to fall, though without nystagmus and pseudothalamic sensory syndrome (posterior insula lesions) have also been reported (Cereda et al. 2002).

Pain is another important process involved in the somatosensory system. The ‘pain matrix’ implies the primary and secondary somatosensory cortex, the insular cortex, the anterior cingulate cortex (ACC), the thalamus, and the prefrontal cortex (Moisset and Bouhassira 2007). The anterior insular cortex seems to play a supramodal integrative role in the autonomic response to noxious stimuli and affective–emotional components of pain (Schnitzler and Ploner 2000). Neuropathic pain is multidimensional and heterogeneous. Insular lesion and neuroimaging studies have been implicated in pain, allodynia, and hypalgesia (see review Moisset and Bouhassira 2007). Some lesions restricted to the insula apparently reduced pain effects and appropriate reaction to pain stimuli, without influencing pain thresholds directly (see Schnitzler and Ploner 2000 for a review). It seems to be the case that anterior insular lesions do not affect abnormal pain thresholds, but when tested with a cold pain tolerance test (which is mostly linked to the affective/emotional aspects of pain), patients showed greater tolerance contralateral to the side of the lesion. Hypalgesia has been reported in patients with non-restricted insular lesions, including the parietal operculum (Greenspan et al. 1999). Despite the central role of anterior insula in pain, posterior insular lesions may play an additional role (Craig 2002, 2009).

### Neglect

Neglect is the failure to report, or orient to meaningful stimuli (Heilman et al. 1993). This deficit is not secondary to motor or sensory deficits. Neglect is mainly presented in response to actions or stimuli which occur on the side contralateral to the lesion. The right inferior parietal lobe is commonly associated with lesions producing neglect (Heilman et al. 1993; Mesulam 1981). Other areas, including the dorsolateral frontal lobe, the thalamus, and the mesencephalic reticular formation have also been implicated in the expression of neglect syndromes (Brozzoli et al. 2006; Maguire and Ogden 2002). Because paralimbic insular regions are specialized for integration between extrapersonal stimuli and the internal milieu (Mesulam and Mufson 1982a, b; Lovero et al. 2009),

neglect secondary to insular lesion is expected. The insula has connections with the limbic and sensorimotor cortices (Habib et al. 1995), and consequently, lesions to these areas should affect the perceptual attention systems, also leading to neglect.

Manes et al. (1999a) examined nine right handed subjects with insular stroke (4 with right insular and 5 with left insular cerebrovascular accidents) with tests of visual, tactile, and auditory perception. The double simultaneous test (visually, auditory, and somesthetic stimulation) was used to assess the presence of extinction (failure to notice stimulus on the right or left sides when simultaneously stimulated from both sides). In addition, the line bisection task was applied to report unilateral visual neglect. Right insular lesion patients showed greater severity of neglect over the somesthetic, visual, and auditory perception, when compared with left insular damage (see also Manes et al. 1999c). In contrast, left-insular lesion patients presented small measures of neglect in the auditory modality. Furthermore, left-insular lesion patients obtained close-to-perfect scores in the tactile modality (4 of 5 showed perfect performance of the double DST, and one patient had a close-to-perfect score). Later studies confirmed the role of right insular lesions in neglect (for review, see Karnath and Dieterich 2006).

Although neglect is commonly considered as a sign of parietal lobe dysfunction, several reports of non-parietal areas have been also published (Mesulam 1981; Damasio et al. 1980; Ferro et al. 1987; Maguire and Ogden 2002; Pisella et al. 2004). Cortical–limbic–thalamic–reticular interactions provide a system for preparatory activation toward meaningful stimuli (Heilman and Valenstein 1979; Heilman et al. 2000). The insula (especially the anteroventral portion), through its connections with the amygdala, provides a pathway for somatosensory, auditory, olfactory, gustatory, and visceral sensations to reach the limbic system (Calvert 2001; Mesulam and Mufson 1982a, b). Those pathways, in addition to connections with anterior inferior parietal cortex, suggest that insular lesions disrupt connections with areas involved in arousal, attention, and activation. Right insular damage, similar to parietal lobe lesions, may impair external stimuli awareness producing neglect.

#### Emotion: disgust

The involvement of the insula in emotion processing (in this case, disgust) was initially reported in animal studies in the early 1980s. The conditioned taste aversion paradigm was an original procedure which revealed that animals stop learning the aversion to tastes that have been poised and made disgusting following insular lesion (i.e., Zito et al. 1998). After these pioneer works on animal research, in the

mid-90s the field witnessed the beginning of human studies on insular involvement in emotion processing. The emotion research in the last decades suggests relatively independent systems for emotion processing (Sprengelmeyer 2007).

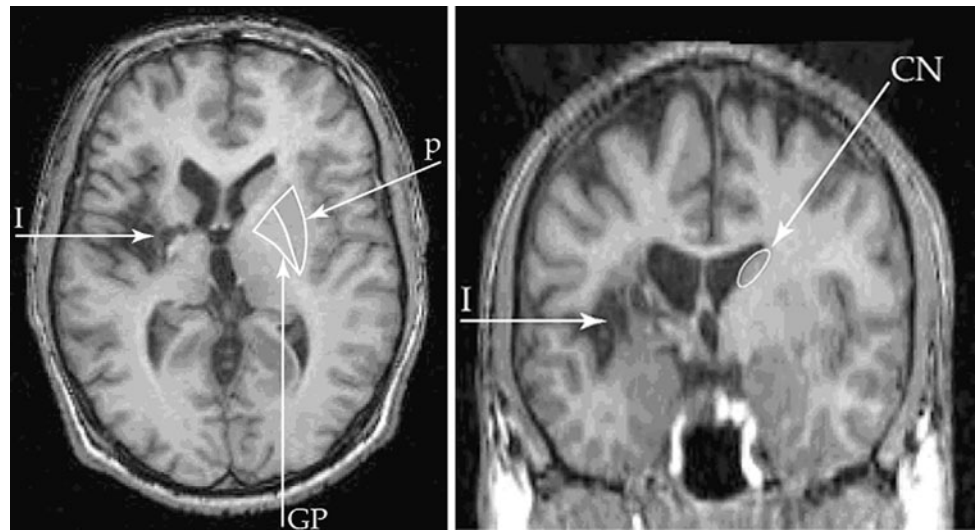
Knowledge for disgust may depend on specific neural areas, as is the case for fear (Adolphs et al. 1995, 2003). Several studies from healthy and lesion participants point to the insula as the main site for the processing of disgust (Sprengelmeyer 2007). fMRI studies have shown engagement of the insula in response to facial expressions of disgust (Jabbi et al. 2007; Phillips et al. 1997; Sprengelmeyer et al. 1998; Wicker et al. 2003).

Moreover, some lesion studies suggest that the insula plays an important role in multimodal facial signs of disgust. For instance, Adolphs et al. (2003) reported a patient (B) with bilateral lesions in the insular cortices. B was completely unable to recognize disgust in different experimental situations (i.e., labeling of facial expressions, description of actions) even when he was able to recognize all other primary emotions. Nevertheless, the fact that patient B presented very widespread lesions (including hippocampi, amygdalae, perirhinal–entorhinal and parahippocampal cortices, basal forebrain nuclei, occipito-parietal cortices, and among others) makes any conclusion about the specific role of the insula in disgust processing limited.

Calder et al. (2000) reported another case study of a patient (NK) with a selective left lesion involving relevant areas related to facial processing of disgust: the posterior part of anterior insula, posterior insula, internal capsule, putamen, and globus pallidus (see Fig. 2). They tested several basic emotions in a multimodal design. This patient showed a selective and impaired multimodal processing of emotional information of disgust related to facial recognition, vocal recognition, non-verbal emotional sounds, and prosodic cues. Briefly, those results support the idea of insula involvement in recognizing social signs of disgust regardless of their modality (emotional deficits were restricted to disgust). NK had no impaired knowledge of the concept of disgust because he did not show any difficulty in correctly classifying four emotions (happiness, sadness, fear, and disgust) illustrated in pictures of scenes. At the same time, he was evaluated on the self-experience of disgust, anger, and fear. Disgust scores were significantly lower than those of controls. The combining deficit in recognizing disgust from facial signs, non-verbal emotional sounds, prosody, and being less disgusted than controls by disgust-provoking situations suggests a role of the insula as a supramodal system for the experience of being disgusted and for the recognition of disgust in others.

In addition, reports of Huntington disease patients who had insula damage showed impaired recognition of disgust (Sprengelmeyer et al. 1997; Wang et al. 2003; but see

**Fig. 2** T1-weighted MR images showing NK lesion including left posterior part of the anterior insula, posterior insula, internal capsule, putamen, and globus pallidus. *Left* axial image. *Right* coronal image also shows damage to the head of the caudate nucleus. *White arrow* insula lesion (*I*). Reproduced from Calder et al. 2000



Milders et al. (2003) for different results), or reduced insular response to disgusted faces in an fMRI study (Hennenlotter et al. 2004).

These results support the possible role of the insula in (1) disgust recognition in others, and at the same time for (2) the experience of being disgusted, or in other words, for seeing and feeling disgusted (Wicker et al. 2003), which is consistent with anatomic and neuroimaging studies. The insula receives information from five sensory modalities (Mesulam and Mufson 1982a, b) and acts as a visceral somatosensory interoceptive cortex (Craig 2002). Those sensorial properties of the insula may account for body states related to the experience of disgust. Furthermore, the insula is engaged during empathic responses (Decety and Jackson 2004). Observing, imagining, and experiencing disgust activates the bilateral anterior insula and adjacent frontal operculum (Jabbi et al. 2008). Those reports suggest that the insular cortex is a convergent zone that integrates body feelings relevant for the emotion of disgust and the processing of the same emotion in others (Pessoa 2008).

#### Mood and willed action

Mood has been related to both limbic and paralimbic areas (cingulate, insula), as well as prefrontal cortex, but with considerable variability (Mayberg et al. 1999). Disconnection between insula and the frontal lobe, anterior cingulate cortex, and amygdalae yield a deficit in mood, willed action and motor behavior.

Manes et al. (1999b) reported six patients with right insular stroke, as compared to seven patients with left insular stroke, six patients with left hemisphere non-insular stroke and patients with right hemisphere non-insular stroke. Patients with right insular lesions presented the

greater frequency of subjective anergia and underactivity, as well as tiredness. Although insular patients presented depressive and other mood symptoms, their severity was not significantly different from non-insular stroke patients. Those deficits were interpreted as (1) interruption of right insula-ACC which affects the limbic influence on voluntary motor system; (2) interruption of insula-frontal lobe connectivity which produces deficits in willed action and; (3) interruption of the insula-amygdalae connectivity which leads to affective-emotional content of perceptual experience. All these aforesaid connections seem to affect the voluntary motor behavior and willed action. In agreement with the above interpretations, bilateral ACC ablation due to cingulotomy (e.g., Cohen et al. 2001) seems to elicit similar emotional experience changes as those reported by Manes et al. (1999b).

The insula seems to play an important role in mood regulation. For instance, Lothe et al. (2008) studied patients with major depressive disorder as well as patients with temporal lobe epilepsy using [ $^{18}\text{F}$ ]MPPF (2'-methoxyphenyl-(*N*-2'-pyridinyl)-*p*-18F-fluoro-benzamidoethylpiperazine) PET, which is used to explore 5-HT<sub>1A</sub> receptors. The total score on the Beck Depression Inventory [BDI, Beck et al. (1961)], which measures mood symptoms, as well as symptoms of psychomotor anhedonia and negative cognition, correlated positively with [ $^{18}\text{F}$ ]MPPF BP in the raphe nuclei and in the insula contralateral to seizure onset. These findings suggest a role for depression and serotonergic pathways in the insula. Statistical parametric mapping analyses have shown that depressed patients exhibit decreased absolute regional metabolism in bilateral (left greater than right) insula (Brooks et al. 2009). Herwig et al. (2009) have shown that brain activation in depression during expecting events of unknown emotional valence



were comparable with activation while expecting certainly negative, but not positive events. Those effects were differentiated from controls in the insular and dorsolateral prefrontal areas. A meta-analysis study has also proposed the insula as one (among others) of the most consistently identified regions in major depressive disorder (Fitzgerald et al. 2008).

### Language

Left temporal lobe is an essential area related to language. The insular cortex has efferent (temporal pole and supratemporal plane) and afferent (temporal lobe, auditory cortex, superior temporal cortex, and temporal operculum) connections with temporal lobes. The insula has been, as a matter of fact, considered a language area for the past decades (Augustine 1996). Lesion (Dronkers 1996) and neuroimaging (Wise et al. 1999) studies have suggested that the critical speech production region in Broca's region is actually the anterior insula. Moreover, Price (2000) argues that the critical site for articulatory planning is the anterior insula, and not the classical Broca area's BA44 and BA45. The insula itself is associated with verbal memory tasks in PET studies (Grasby et al. 1994; Paulesu et al. 1993). Nevertheless, the assertion that the left anterior insula can be considered the actual language site attributed to Broca's region must be taken with caution. Because the anatomical proximity of the insula to major neural systems for speech (e.g. Broca, arcuate fasciculus, and sensory speech areas), no evidence has yet disentangled the possible preponderant and isolate functional role of the insula in language attributed to Broca's area. Despite these caveats, given its anatomical and functional properties, language impairments are expected after left insular stroke.

In fact, language impairments due to insular left lesion constitute one of the clearer lateralized functional roles of insula (see Ackermann 2010). Manes et al. (1999c) compared verbal profiles between a group of four patients with right insular lesion and another with six patients with left insular lesions. Only patients who had performed within normal limits in measures of naming, word association, IQ, visual domain, and mental state were included in the study. Left insular lesion patients had a significantly poorer immediate and delayed verbal memory (Story A Wechsler Memory Scale—Revised Logical Memory I) and logical memory II subtest. They also showed a significant deficit in the delayed recall, as measured by the CERAD (The Consortium to Establish a Registry for Alzheimer's Disease) word list memory and such results suggest an insula involvement of a functional network that mediates verbal memory. Moreover, Mesulam and Mufson (1982a, b) suggested that insular connections provide a fundamental anatomical substrate for learning and memory functions.

It is well known that left insular stroke produces aphasia (Carota et al. 2007; Kreisler et al. 2000; Shuren 1993; Marshall et al. 1996), probably due to functional disconnection between posterior insula and language areas in the temporal lobe. The sudden removal of areas of a functioning brain, as occurs with stroke, may produce distant effects in functionally connected neural structures. This phenomenon is often termed diaschisis. Thus, left insular stroke can produce aphasia as a result of diaschisis. Non-fluent aphasia, phonemic distortion, transient jargon-aphasic fluent aphasia with paraphasia and dysarthria secondary to left posterior lesions of the insula have been reported (Cereda et al. 2002). The left middle insula was identified as the overlapping injured area of 25 patients presenting apraxia of speech (Dronkers 1996). Other language-related deficits such as mutism or auditory agnosia have been reported (Fifer 1993; Habib et al. 1995).

### The role of insular interoception on addiction

Classic studies of addiction have focused on several components of the limbic system. Despite early reports showing the involvement of the amygdala, ventral striatum, and mesolimbic dopamine systems, the involvement of the insula in drug abuse has received increasing interest in the last years. Naqvi and Bechara (2009) revised several neuroimaging studies reporting insula engagement in addiction behaviors and consequently argued for a potential role of the insula in the conscious urges to take drugs. A recent study in rats shows disruption of craving and malaise after inactivation of interoceptive insula (Contreras et al. 2007).

To our knowledge, only one study of addiction in patients with insular lesions has been reported. Naqvi et al. (2007) compared the retrospective assessment changes in smoking behavior of 19 smokers with either the right or the left insular lesion (PIL) and 50 smokers with other non-insular lesions (PNIL). The authors found that PIL were over 100 times more likely than PNIL to undergo interruption of the smoking addiction, without relapse and without a persistent urge to smoke. Deficits were somewhat larger with right insula lesions, although the size of the groups were not enough to yield a statistically difference.

Consistent with this report, other studies (e.g., Gray and Critchley 2007) have highlighted the possible role of interoceptive functions of the insula in addiction. More specifically, Naqvi and Bechara (2009) propose that drug-use rituals are encoded as bodily (interoceptive) effects in the insula and are integrated into an explicit motivational process which leads to addiction. Future research may reveal whether this role of the insula in urging to consume drugs is specific of smoking behavior or implicated in different addictions as well.

## Discussion

In this selective review, we have described the following multiple and disparate deficits resulting from insular cortex stroke: abnormalities of autonomic function (cardiovascular effects and parasympathetic and sympathetic asymmetries); taste intensity, gustatory–olfactory perception and odor-induced taste impairments; deficits in auditory processing (mainly temporal resolution and sequencing), multiple somatosensory and body awareness, as well as pain-related abnormalities; multimodal neglect (somesthetic, visual, and auditory); deficits in the experiencing and recognition of emotion of disgust; anomalous mood and willed action (subjective anergia, underactivity, and tiredness); aphasia, reduced verbal memory and other language-related deficits; and finally, the conscious urge to take recreational drugs. As revealed by the evidence presented in this article, lesions to the insula in humans affect multiple functions of different levels of complexity, ranging from abnormalities in primitive autonomic mechanisms to impairments on high level cognitive functions. On the other side of this spectrum, for example, we can recognize the role of insular cortex in autonomic regulation of immune responses. More specifically, in animal studies, it was shown that the insular cortex modulates the acquisition of conditioned suppression through splenocyte proliferation and production of interleukin-2 and interferon-gamma in behaviorally conditioned immunosuppression paradigms in rats (Pacheco-López et al. 2005). Moreover, no changes in immune response, as revealed by normal hemagglutinating titers (Ramírez-Amaya et al. 1996) or antibody production levels (Ramírez-Amaya and Bermúdez-Rattoni 1999) were observed in rats with insular cortex lesions in paradigms relative to parietal cortex or sham animals. However, on the other extreme of the spectrum, insular lesions seem to affect high level cognition as well. For example, Weller et al. (2009) reported that patients with focal insula damage had impaired performance on decision-making, as they exhibited marked risk-taking compared with healthy controls. Both of these are just mere examples of how lesions to the same structure can lead to radically different behavioral disturbances, as the ones detailed throughout this review.

After careful revision of the human lesion studies detailed above, only partially specific topographic properties of the insula can be proposed. Asymmetrical distributions of insular functions have been identified in the literature before (e.g. sympathetic/parasympathetic function; Craig 2005). Overall, right insular lesions seem to affect mainly the sympathetic system and aroused emotions, eliciting neglect, anergia and reduced willed action. Left insular lesions, on the other hand, are more closely related to alterations of the parasympathetic autonomic

system, and produce deficits of auditory temporal processing and language-related deficits. Lesions to the anterior part of the insula are more frequently associated with impaired awareness of intrapersonal space or interoception, as well as affective dimensions of pain and related mood disturbances and anxiety. Posterior lesions seem to mostly affect extrapersonal integration, coordination of sensory aspects of pain, as well as somatomotor, vestibular, and motor integration together with primary interoceptive representations. For this reason, lesions that combine lateralization with anteroposterior localizations tend to yield more accentuated specific deficits (e.g., right posterior lesion tends to produce aberrant somatosensory sensations while right anterior triggered mood and affective disorders). Further research is needed to understand lateralization profiles of all involved domains of insular lesions.

In addition, such astonishing diversity of deficits following insular lesions can be partially explained by the multimodal properties of the insula. This area presents multiple anatomical and functional connections with various other cortical and subcortical areas (e.g., thalamus; amygdala; anterior cingulate cortex, ventromedial prefrontal cortex, ventral striatum; parietal, occipital, and temporal association cortices), and it is thus involved in multiple neural networks. There are also intra-insular projections that go from anterior to more posterior regions, which also support the role of the insular cortex as an integrative heteromodal association area for the five senses. Yet, besides its widespread connectivity and the diversity of insular lesion effects on cognitive processes, a partial model can be reached to explain the role of the insula. Specifically, this multimodal area of convergence seems to play a fundamental and integrative role in the coordination between internal and external information through emotional subjective awareness. Based on the review of human lesions hereby introduced, we propose an involvement of the insula in the basal subjective states that mediate action preparation through the temporal coordination between interoceptive and exteroceptive process. Following this hypothesis, lesions of the insular cortex, depending both on the kind of lesion and the specific networks implicated should affect the following process: (a) external perception (especially multisensory and supramodal), (b) interoception (autonomic motor control and signals from the body that include pain, temperature, itch, touch, muscular and visceral sensations, vasomotor activity, among others); (c) awareness (about internal or external states); (d) emotion (especially basic emotions such as pain and basic emotional states that will to action). In addition, (e) temporal dynamics of action related to sympathetic and parasympathetic pathways during body homeostasis should be altered by insular lesions. This last process (relationship between autonomic body function and emotional action) has been recently highlighted by Craig

(2005, 2010); and emerging evidence of the relationship between peripheral and central systems in emotional processing has been described (Dufey et al. 2010; Lane et al. 1997). Table 2b summarizes the revised studies showing different alterations of these a–b–c–d–e components (perception, interoception, awareness, emotion, and sympathetic/parasympathetic involvement).

Current knowledge in cognitive neuroscience about the insula partially supports our claims. Three main approaches to (1) internal processing, (2) external processing and (3) integrative properties of insula have been parallel and independently proposed. The work of Craig has articulated the transformation of interoceptive signals into a subjective experience very well, and today it is currently accepted that the insular cortex has a role in interoceptive awareness. Craig has proposed an insular model of awareness based on interoceptive salience, which might provide a pathway for the neuroscience of subjective feelings, emotion and self-awareness (Craig 2002, 2003, 2009; see also Verhagen 2007). Regarding the role in external information processing, Damasio has argued for their importance and convergence for the experience of a feeling; yet, Damasio's model seems to suggest that other areas beyond the insula are responsible for coordination of the body with information about the world (e.g., see Bechara and Naqvi 2004 for a summary). Finally, the integrative role of the insula has been already highlighted. Naqvi and Bechara (2009) proposed that the insula is a region able to integrate bodily states into conscious feelings and into decision-making processes. Insular activity seems to further extend to perceptual integration as well. By reviewing neuroimaging studies, Wiens (2005) attributed the insula with properties of a centrally integrated feedback network converging from the whole body. This integration includes the somesthetic–limbic, insulo–limbic, insulo–orbito–temporal and the prefrontal–striato–pallidal–basal forebrain networks (Shelley and Trimble 2004). Our model supports a central integrative insular role in the motivational coordination between internal and external milieus. In the same line, Uddin and Menon (2009) have recently suggested that the insula is part of a “salience network” integrating external sensory stimuli with internal states. They argue that the insula is positioned as a center mediating interactions between large-scale networks involved in externally and internally oriented cognitive processing. Tsakiris (2010) proposes that insula facilitates the body-ownership experience which arises as an interaction between current multisensory input and internal models of the body.

In summary, this review supports the hypothesis that the insula, due to its reciprocal connections with multiple brain areas, conveys the meaningful action–perception cycle by coordinating the internal and emotional states of the body

with multimodal external information. Nevertheless, this attribution must be interpreted with caution. Most of the studies reported in the literature and reviewed in the present article do not include pure isolated insular lesions, but multiple adjacent areas as well (see Table 2a). Moreover, various studies even included participants with non-adjacent and distant lesions. At the same time, the multiple connection pathways involving the insular cortex suggest that this structure is a convergence zone engaged in multiple networks, and not a specialized and isolated center. Because of these highly interconnected networks, the clinical and cognitive manifestations of insular lesions could indeed be a consequence of diaschisis for instance, due to the changes in regional neuronal metabolism and cerebral blood flow caused by dysfunction in an anatomically separate (distant) but functionally related neuronal region. This would be supported by the fact that some of the insular dysfunctions reported in this review (e.g., cases of aphasia following insular damage) cannot be properly interpreted under the proposed model. Despite these caveats, it is reasonable to conceive the insula as an area of convergence for the neural networks involved in internal/external coordination of subjective awareness.

As stated above, there are a number of limitations associated with human insular lesions resulting from the nature of this brain area. However, additional limitations to lesion studies of the insular cortex in humans include the low number of participants (in many cases, just case reports) usually included in the studies, as well as the partial (in some cases, even biased) evaluation of clinical or cognitive functions. In addition, it is important to consider the etiology and characteristics of the insular lesions that lead to conclusions regarding its clinical consequences. Lesion factors (e.g. size and location of the lesion, possible disruption of neurotransmitter systems) as well as other factors (e.g. neuropsychiatric status, age of onset of the condition) may help in contributing and determining the clinical effects after insular damage.

Further studies should attempt to fill both of these gaps by carrying out multi-center studies which would allow for the recruitment of a larger number of participants and the consideration of an extended evaluation of clinical, affective and cognitive process related to insula. Well-controlled studies are required, with different insular lesion sizes and locations, and with a more comprehensive evaluation that will result in more quantitative and qualitative information. The combination of multi-center studies employing an extended assessment of different, well-described focal insular lesions will further our understanding of the complex and integrative properties of this recently rediscovered brain area which still remains so intriguing.

## References

- Ackermann H, Riecker A (2010) The contribution(s) of the insula to speech production: a review of the clinical and functional imaging literature. *Brain Struct Funct*. doi:10.1007/s00429-010-0257-x
- Adolphs R, Tranel D, Damasio H, Damasio A (1995) Fear and the human amygdala. *J Neurosci* 15:5879–5892
- Adolphs R, Tranel D, Damasio AR (2003) Dissociable neural systems for recognizing emotions. *Brain Cogn* 52:61–69
- Augustine JR (1996) Circuitry and functional aspects of the insular lobe in primates including humans. *Brain Res Brain Res Rev* 22:229–244
- Bamiou DE, Musiek FE, Luxon LM (2003) The insula (Island of Reil) and its role in auditory processing: literature review. *Brain Res Brain Res Rev* 42:143–154
- Bamiou DE, Musiek FE, Stow I, Stevens J, Cipolotti L, Brown MM, Luxon LM (2006) Auditory temporal processing deficits in patients with insular stroke. *Neurology* 67:614–619
- Bechara A, Naqvi N (2004) Listening to your heart: interoceptive awareness as a gateway to feeling. *Nat Neurosci* 7:102–103
- Beck AT, Ward CH, Mendelson M et al (1961) Inventory for measuring depression. *Arch Gen Psychiatry* 4:561–571
- Bohlhalter S, Fretz C, Weder B (2002) Hierarchical versus parallel processing in tactile object recognition: a behavioural–neuro-anatomical study of aperceptive tactile agnosia. *Brain* 125:2537–2548
- Borsody M, Warner Gargano J, Reeves M, Jacobs B, MASCOTS Insula-Stroke Substudy Group (2009) Infarction involving the insula and risk of mortality after stroke. *Cerebrovasc Dis* 27:564–571
- Bottini G, Bisiach E, Sterzi R, Vallar G (2002) Feeling touches in someone else’s hand. *Neuroreport* 13:249–252
- Bowsher D, Brooks J, Enevoldson P (2004) Central representation of somatic sensations in the parietal operculum (SII) and insula. *Eur Neurol* 52(4):211–225
- Brandt T (1999) Cortical visual–vestibular interaction for spatial orientation and self-motion perception. *Curr Opin Neurol* 12(1):1–4
- Brooks JO 3rd, Wang PW, Bonner JC, Rosen AC, Hoblyn JC, Hill SJ, Ketter TA (2009) Decreased prefrontal, anterior cingulate, insula, and ventral striatal metabolism in medication-free depressed outpatients with bipolar disorder. *J Psychiatr Res* 43(3):181–188
- Brozzoli C, Demattè ML, Pavani F, Frassinetti F, Farnè A (2006) Neglect and extinction: within and between sensory modalities. *Restor Neurol Neurosci* 24(4–6):217–232
- Calder AJ, Keane J, Manes F, Antoun N, Young AW (2000) Impaired recognition and experience of disgust following brain injury. *Nat Neurosci* 3(11):1077–1078
- Calvert GA (2001) Crossmodal processing in the human brain: insights from functional neuroimaging studies. *Cereb Cortex* 11(12):1110–1123
- Carmichael ST, Clugnet MC, Price JL (1994) Central olfactory connections in the macaque monkey. *J Comp Neurol* 346:403–434
- Carota A, Annoni JM, Marangolo P (2007) Repeating through the insula: evidence from two consecutive strokes. *Neuroreport* 18(13):1367–1370
- Caselli RJ (1991) Rediscovering tactile agnosia. *Mayo Clinic Proc* 66:129–142
- Cereda C, Ghika J, Maeder P, Bogousslavsky J (2002) Strokes restricted to the insular cortex. *Neurology* 59(12):1950–1955
- Cheung RTF, Hachinski V (2000) The insula and cerebrogenic sudden death. *Arch Neurol* 57:1685–1688
- Christiansen H, Boysen G, Christiansen AF, Johannesen HH (2005) Insular lesions, ECG abnormalities, and outcome in acute stroke. *J Neurol Neurosurg Psychiatry* 76:269–271
- Cohen RA, Paul R, Zawacki TM, Moser DJ, Sweet L, Wilkinson H (2001) Emotional and personality changes following cingulotomy. *Emotion* 1(1):38–50
- Contreras M, Ceric F, Torrealba F (2007) Inactivation of the interoceptive insula disrupts drug craving and malaise induced by lithium. *Science* 318(5850):655–658
- Craig AD (2002) How do you feel? Interoception: the sense of the physiological condition of the body. *Nat Rev Neurosci* 3(8):655–666
- Craig AD (2003) Interoception: the sense of the physiological condition of the body. *Curr Opin Neurobiol* 13(4):500–505
- Craig AD (2005) Forebrain emotional asymmetry: a neuroanatomical basis? *Trends Cogn Sci* 9:566–571
- Craig AD (2009) Emotional moments across time: a possible neural basis for time perception in the anterior insula. *Philos Trans R Soc Lond B Biol Sci* 364(1525):1933–1942
- Craig AD (2010) The sentient self. *Brain Struct Funct*. doi:10.1007/s00429-010-0248-y
- Damasio AR, Damasio H, Chui HC (1980) Neglect following damage to frontal lobe or basal ganglia. *Neuropsychologia* 18(2):123–132
- de Araujo IE, Rolls ET, Kringelbach ML, McGlone F, Phillips N (2003) Taste–olfactory convergence, and the representation of the pleasantness of flavour, in the human brain. *Eur J Neurosci* 18:2059–2068
- Decety J, Jackson PL (2004) The functional architecture of human empathy. *Behav Cogn Neurosci Rev* 3(2):71–100
- Dijkerman HC, de Haan EH (2007) Somatosensory processes subserving perception and action. *Behav Brain Sci* 30(2):189–201 (discussion 201–239)
- Dronkers NF (1996) A new brain region for co-ordinating speech articulation. *Nature* 384:159–161
- Dufey M, Hurtado E, Fernandez AM, Manes F, Ibáñez A (2010) Exploring the relationship between vagal tone and event-related potentials in response to an affective picture task. *Soc Neurosci* 23:1–15
- Eickhoff SB, Lotze M, Wietek B, Amunts K, Enck P, Zilles K (2006) Segregation of visceral and somatosensory afferents: an fMRI and cytoarchitectonic mapping study. *Neuroimage* 31(3):1004–1014
- Ferro JM, Kertesz A, Black SE (1987) Subcortical neglect: quantitation, anatomy, and recovery. *Neurology* 37(9):1487–1492
- Fifer RC (1993) Insular stroke causing unilateral auditory processing disorder: case report. *J Am Acad Audiol* 4(6):364–369
- Fink JN, Selim MH, Kumar S, Voetsch B, Fong WC, Caplan LR (2005) Insular cortex infarction in acute middle cerebral artery territory stroke. *Arch Neurol* 62:1081–1085
- Fitzgerald PB, Laird AR, Maller J, Daskalakis ZJ (2008) A meta-analytic study of changes in brain activation in depression. *Hum Brain Mapp* 29(6):683–695
- Frasnelli J, Lundström JN, Boyle JA, Djordjevic J, Zatorre RJ, Jones-Gotman M (2009) Neuroanatomical correlates of olfactory performance. *Exp Brain Res* [Epub ahead of print]
- Grasby PM, Frith CD, Friston KJ et al (1994) A graded task approach to the functional mapping of brain areas implicated in auditory-verbal memory. *Brain* 117:1271–1282
- Gray MA, Critchley HD (2007) Interoceptive basis to craving. *Neuron* 54(2):183–186
- Greenspan JD, Lee RR, Lenz FA (1999) Pain sensitivity alterations as a function of lesion location in the parasyllian cortex. *Pain* 81(3):273–282
- Griffiths TD, Rees A, Witton C, Cross PM, Shakir RA, Green GGR (1997) Spatial and temporal auditory processing deficits



- following right hemisphere infarction: a psychophysical study. *Brain* 120:785–794
- Habib M, Daquin G, Milandre L, Royere MR, Lanteri A, Salamon G, Khalil R (1995) Mutism and auditory agnosia due to bilateral insular damage: role of the insula in human communication. *Neuropsychologia* 33:327–339
- Heilman KM, Valenstein E (1979) Mechanisms underlying hemispatial neglect. *Ann Neurol* 5:166–170
- Heilman KM, Watson RT, Valenstein E (1993) Neglect and related disorders. In: Heilman KM, Valenstein E (eds) *Clinical neuropsychology*, 3rd edn. Oxford University Press, New York, pp 279–336
- Heilman KM, Valenstein E, Watson RT (2000) Neglect and related disorders. *Semin Neurol* 20(4):463–470
- Hennenlotter A, Schroeder U, Erhard P, Haslinger B, Stahl R, Weindl A et al (2004) Neural correlates associated with impaired disgust processing in pre-symptomatic Huntington's disease. *Brain* 127:1446–1453
- Herwig U, Brühl AB, Kaffenberger T, Baumgartner T, Boeker H, Jäncke L (2009) Neural correlates of 'pessimistic' attitude in depression. *Psychol Med* 7:1–12
- Hyman BT, Tranel D (1989) Hemianesthesia and aphasia: an anatomical and behavioural study. *Arch Neurol* 46:816–819
- Jabbi M, Swart M, Keysers C (2007) Empathy for positive and negative emotions in the gustatory cortex. *Neuroimage* 34:1744–1753
- Jabbi M, Bastiaansen J, Keysers C (2008) A common anterior insula representation of disgust observation, experience and imagination shows divergent functional connectivity pathways. *PLoS One* 3(8):e2939
- Kalani MY, Kalani MA, Gwinn R, Keogh B, Tse VC (2009) Embryological development of the human insula and its implications for the spread and resection of insular gliomas. *Neurosurg Focus* 27(2):E2
- Karnath HO, Dieterich M (2006) Spatial neglect—a vestibular disorder? *Brain* 129(Pt 2):293–305
- Karnath H-O, Baier B (2010) Right insula for our sense of limb ownership and self-awareness of actions. *Brain Struct Funct*. doi: [10.1007/s00429-010-0250-4](https://doi.org/10.1007/s00429-010-0250-4)
- Karnath H-O, Baier B, Nagele T (2005) Awareness of the functioning of one's own limbs mediated by the insular cortex? *J Neurosci* 25:7134–7138
- Kobayashi M, Sasabe T, Takeda M, Kondo Y, Yoshikubo S, Imamura K et al (2002) Functional anatomy of chemical senses in the alert monkey revealed by positron emission tomography. *Eur J Neurosci* 16:975–980
- Kreisler A, Godefroy O, Delmaire C, Debachy B, Leclercq M, Pruvot JP, Leys D (2000) The anatomy of aphasia revisited. *Neurology* 54(5):1117–1123
- Lane R, Reiman E, Ahern G, Schwartz G (1997) Neuroanatomical correlates of happiness, sadness, and disgust. *Am J Psychiatry* 154:926–933
- Lothe A, Didelot A, Hammers A, Costes N, Saoud M, Gilliam F, Ryvlin P (2008) Comorbidity between temporal lobe epilepsy and depression: a [18F]MPPF PET study. *Brain* 131(Pt 10):2765–2782
- Lovero KL, Simmons AN, Aron JL, Paulus MP (2009) Anterior insular cortex anticipates impending stimulus significance. *Neuroimage* 45(3):976–983
- Luskin MB, Boone MS (1994) Rate and pattern of migration of lineally-related olfactory bulb interneurons generated postnatally in the subventricular zone of the rat. *Chem Senses* 19:695–714
- Maguire AM, Ogdan JA (2002) MRI brain scan analyses and neuropsychological profiles of nine patients with persisting unilateral neglect. *Neuropsychologia* 40(7):879–887
- Mak YE, Simmons KB, Gitelman DR, Small DM (2005) Taste and olfactory intensity perception changes following left insular stroke. *Behav Neurosci* 119(6):1693–1700
- Malak R, Bouthillier A, Carmant L, Cossette P, Giard N, Saint-Hilaire JM, Nguyen DB, Nguyen DK (2009) Microsurgery of epileptic foci in the insular region. *J Neurosurg* 110(6):1153–1163
- Manes F, Paradiso S, Robinson RG (1999a) Neuropsychiatric effects of insular stroke. *J Nerv Ment Dis* 187(12):707–712
- Manes F, Paradiso S, Springer JA, Lambert G, Robinson RG (1999b) Neglect after right insular cortex infarction. *Stroke* 30(5):946–948
- Manes F, Springer J, Jorge R, Robinson RG (1999c) Verbal memory impairment after left insular cortex infarction. *J Neurol Neurosurg Psychiatry* 67(4):532–534
- Marshall R, Lazar R, Mohr JP (1996) Semantic conduction aphasia from a posterior insular cortex infarction. *J Neuroimaging* 6:189–191
- Mayberg HS, Liotti M, Brannan SK, McGinnis S, Mahurin RK, Jerabek PA, Silva JA, Tekell JL, Martin CC, Lancaster JL, Fox PT (1999) Reciprocal limbic-cortical function and negative mood: converging PET findings in depression and normal sadness. *Am J Psychiatry* 156(5):675–682
- Mesulam M-M (1981) A cortical network for directed attention and unilateral neglect. *Ann Neurol* 10:309–325
- Mesulam M-M, Mufson E (1982a) Insula of the old world monkey, II: afferent cortical input and comments on the claustrum. *J Comp Neurol* 212:23–37
- Mesulam MM, Mufson EJJ (1982b) Insula of the old world monkey. II: afferent cortical input and comments on the claustrum. *Comp Neurol* 212:38–52
- Milders M, Crawford JR, Lamb A, Simpson SA (2003) Differential deficits in expression recognition in gene-carriers and patients with Huntington's disease. *Neuropsychologia* 41:1484–1492
- Moisset X, Bouhassira D (2007) Brain imaging of neuropathic pain. *Neuroimage* 37(Suppl 1):S80–S88
- Moro V, Zampini M, Aglioti SM (2004) Changes in spatial position of hands modify tactile extinction but not disownership of contralesional hand in two right brain-damaged patients. *Neurocase* 10:437–443
- Naqvi NH, Bechara A (2009) The hidden island of addiction: the insula. *Trends Neurosci* 32(1):56–67
- Naqvi NH et al (2007) Damage to the insula disrupts addiction to cigarette smoking. *Science* 315:531–534
- Oppenheimer SM, Gelb A, Girvin JP, Hachinski VC (1992) Cardiovascular effects of human insular cortex stimulation. *Neurology* 42(9):1727–1732
- Pacheco-López G, Niemi MB, Kou W, Härting M, Fandrey J, Schedlowski M (2005) Neural substrates for behaviorally conditioned immunosuppression in the rat. *J Neurosci* 25(9):2330–2337
- Palmer TD, Takahashi J, Gage FH (1997) The adult rat hippocampus contains primordial neural stem cells. *Mol Cell Neurosci* 8:389–404
- Paulesu E, Frith CD, Frackowiak RSJ (1993) The neural correlates of the verbal component of working memory. *Nature* 362:342–345
- Pessoa L (2008) On the relationship between emotion and cognition. *Nat Rev Neurosci* 2:148–158
- Phillips ML, Young AW, Senior C, Brammer M, Andrew C, Calder AJ, Bullmore ET, Perrett DI, Rowland D, Williams SC, Gray JA, David AS (1997) A specific neural substrate for perceiving facial expressions of disgust. *Nature* 389:495–498
- Pisella L, Berberovic N, Mattingley JB (2004) Impaired working memory for location but not for colour or shape in visual neglect: a comparison of parietal and non-parietal lesions. *Cortex* 40(2):379–390



- Platel H, Baron JC, Wise R et al (1997) The structural components of music perception: a functional anatomical study. *Brain* 120:229–243
- Price CJ (2000) The anatomy of language: contributions from functional neuroimaging. *J Anat* 197(Pt 3):335–359
- Pritchard TC, Macaluso E, Eslinger PJ (1999) Taste perception in patients with insular cortex lesions. *Behav Neurosci* 113:663–671
- Ramírez-Amaya V, Bermúdez-Rattoni F (1999) Conditioned enhancement of antibody production is disrupted by insular cortex and amygdala but not hippocampal lesions. *Brain Behav Immun* 13(1):46–60
- Ramírez-Amaya V, Alvarez-Borda B, Ormsby CE, Martínez RD, Pérez-Montfort R, Bermúdez-Rattoni F (1996) Insular cortex lesions impair the acquisition of conditioned immunosuppression. *Brain Behav Immun* 10(2):103–114
- Reed CL, Caselli RJ, Farah MJ (1996) Tactile agnosia: underlying impairment and implications for normal tactile object recognition. *Brain* 119:875–888
- Reil JC (1809) Untersuchungen über den Bau des grossen Gehirns im Menschen: Vierte Fortsetzung, VIII. *Arch Physiol (Halle)* 9:136–146
- Roper SN, Lévesque MF, Sutherling WW, Engel J Jr (1993) Surgical treatment of partial epilepsy arising from the insular cortex. Report of two cases. *J Neurosurg* 79(2):266–269
- Savic I, Gulyas B (2000) PET shows that odors are processed both ipsilaterally and contralaterally to the stimulated nostril. *Neuroreport* 11:2861–2866
- Schafe GE, Bernstein IL (1998) Forebrain contribution to the induction of a brainstem correlate of conditioned taste aversion. II. Insular (gustatory) cortex. *Brain Res* 800(1):40–47
- Schneider RJ, Friedman DP, Mishkin M (1993) A modality-specific somatosensory area within the insula of the rhesus monkey. *Brain Res* 621:116–120
- Schnitzler A, Ploner M (2000) Neurophysiology and functional neuroanatomy of pain perception. *J Clin Neurophysiol* 17(6):592–603
- Sewards TV, Sewards MA (2001) Cortical association areas in the gustatory system. *Neurosci Biobehav Rev* 25(5):395–407
- Shelley BP, Trimble MR (2004) The insular lobe of Reil—its anatomico-functional, behavioural and neuropsychiatric attributes in humans—a review. *World J Biol Psychiatry* 5(4):176–200
- Shuren J (1993) Insula and aphasia. *J Neurol* 240(4):216–218
- Simon M, Neuloh G, von Lehe M, Meyer B, Schramm J (2009) Insular gliomas: the case for surgical management. *J Neurosurg* 110(4):685–695
- Small DM, Zald DH, Jones-Gotman M, Zatorre RJ, Pardo JV, Frey S et al (1999) Human cortical gustatory areas: a review of functional neuroimaging data. *Neuroreport* 10:7–14
- Small DM, Gregory MD, Mak YE, Gitelman DR, Mesulam MM, Parrish TB (2003) Dissociation of neural representation of intensity and affective valuation in human gustation. *Neuron* 39:701–711
- Small DM, Voss J, Mak YE, Simmons KB, Parrish T, Gitelman D (2004) Experience-dependent neural integration of taste and smell in the human brain. *J Neurophysiol* 92:1892–1903
- Spinazzola L, Pia L, Folegatti A, Marchetti C, Berti A (2008) Modular structure of awareness for sensorimotor disorders: evidence from anosognosia for hemiplegia and anosognosia for hemianaesthesia. *Neuropsychologia* 46:915–926
- Spreen O, Benton AL, Fincham RW (1965) Auditory agnosia without aphasia. *Arch Neurol* 13:84–92
- Sprengelmeyer R (2007) The neurology of disgust. *Brain* 130(Pt 7):1715–1717
- Sprengelmeyer R, Young AW, Sprengelmeyer A, Calder AJ, Rowland D, Perrett DI et al (1997) Recognition of facial expressions: selective impairment of specific emotions in Huntington's disease. *Cognit Neuropsychol* 14:839–879
- Sprengelmeyer R, Rausch M, Eysel UT, Przuntek H (1998) Neural structures associated with recognition of facial expressions of basic emotions. *Proc R Soc Lond B Biol Sci* 265:1927–1931
- Stevenson RJ, Miller LA, Thayer ZC (2008) Impairments in the perception of odor-induced tastes and their relationship to impairments in taste perception. *J Exp Psychol Hum Percept Perform* 34(5):1183–1197
- Sudakov K, McLean PD, Reeves A, Marino R (1971) Unit study of exteroceptive inputs to claustrorocortex in awake sitting squirrel monkeys. *Brain Res* 28:19–34
- Tsakiris M (2010) My body in the brain: a neurocognitive model of body-ownership. *Neuropsychologia* 48:703–712
- Türe U, Yaşargil MG, Al-Mefty O, Yaşargil DC (2000) Arteries of the insula. *J Neurosurg* 92(4):676–687
- Uddin LQ, Menon V (2009) The anterior insula in autism: under-connected and under-examined. *Neurosci Biobehav Rev* 33(8):1198–1203
- Varnavas GG, Grand W (1999) The insular cortex: morphological and vascular anatomic characteristics. *Neurosurgery* 44(1):127–136
- Verhagen JV (2007) The neurocognitive bases of human multimodal food perception: consciousness. *Brain Res Rev* 53(2):271–286
- von Lehe M, Wellmer J, Urbach H, Schramm J, Elger CE, Clusmann H (2009) Insular lesionectomy for refractory epilepsy: management and outcome. *Brain* 132(Pt 4):1048–1056
- Wang K, Hoosain R, Yang RM, Meng Y, Wang CQ (2003) Impairment of recognition of disgust in Chinese with Huntington's or Wilson's disease. *Neuropsychologia* 41:527–537
- Weller JA, Levin IP, Shiv B, Bechara A (2009) The effects of insula damage on decision-making for risky gains and losses. *Soc Neurosci* 4(4):347–358
- Wicker B, Keysers C, Plailly J, Royet JP, Gallese V, Rizzolatti G (2003) Both of us disgusted in my insula: the common neural basis of seeing and feeling disgust. *Neuron* 40:655–664
- Wiens S (2005) Interoception in emotional experience. *Curr Opin Neurol* 18(4):442–447
- Wise RJS, Greene J, Buschel C, Scott SK (1999) Brain regions involved in articulation. *Lancet* 353:1057–1061
- Yasui Y, Breder CD, Saper CB, Cechetto DF (1991) Autonomic responses and efferent pathways from the insular cortex in the rat. *J Comp Neurol* 15:303(3):355–374
- Zatorre RJ (2001) Neural specializations for tonal processing. *Ann NY Acad Sci* 930:193–210
- Zito A, Bechara A, Greenwod C, Van Der Kooy D (1998) The dopamine innervation of the visceral cortex mediates the aversive effects of opiates. *Pharm Biochem Behav* 30:693–699