

Adjuvant therapy of histopathological risk factors of retinoblastoma in Europe: A survey by the European Retinoblastoma Group (EURbG)

Sabine Dittner-Moormann¹ | Madlen Reschke²  | Floor C. H. Abbink³ |
 Isabelle Aerts⁴  | Hatice Tuba Atalay⁵ | Nadezhda Fedorovna Bobrova⁶ |
 Eva Biewald⁷ | Ines B. Brecht⁸ | Shani Caspi⁹ | Nathalie Cassoux⁴ |
 Guilherme Castela¹⁰ | Yelena Diarra¹ | Catriona Duncan¹¹ | Martin Ebinger⁸  |
 David Garcia Aldana¹² | Doris Hadjistilianou¹³ | Tomáš Kepák¹⁴ | Artur Klett¹⁵ |
 Hayyam Kiratli¹⁶ | Erika Maka¹⁷  | Enrico Opocher^{11,18} |
 Katarzyna Pawinska-Wasikowska¹⁹ | Jelena Rascon²⁰ | Ida Russo²¹  |
 Olga Rutynowska-Pronicka²² | Constantino Sábado Álvarez²³ |
 Sonsoles San Roman Pacheco²⁴ | Karel Svojr²⁵  | Beate Timmermann^{26,27} |
 Viktoria Vishnevskia-Dai²⁸ | Angelika Eggert² | Petra Ritter-Sovinz²⁹ |
 Nikolaos E. Bechrakis⁷ | Helen Jenkinson³⁰ | Annette Moll³¹ | Francis L. Munier³² |
 Maja Beck Popovic³³ | Guillermo Chantada³⁴  | François Doz⁴ | Petra Ketteler^{1,27} 

¹ Department of Pediatric Hematology and Oncology, University Duisburg-Essen, University Hospital Essen, Essen, Germany

² Department of Pediatric Oncology and Hematology, Charité - Universitätsmedizin Berlin, Berlin, Germany

³ Amsterdam UMC, Location VU University Medical Centre, Amsterdam, The Netherlands

⁴ Institut Curie, PSL Research University and University of Paris, Paris, France

⁵ Gazi University School of Medicine, Ankara, Turkey

⁶ Filatov Eye Institute Odessa, Odessa, Ukraine

⁷ Department of Ophthalmology, University Duisburg-Essen, University Hospital Essen, Essen, Germany

⁸ Children's Hospital, University of Tuebingen, Tuebingen, Germany

⁹ Pediatric Oncology, Sheba Medical Center, Tel Aviv University, Tel Aviv, Israel

¹⁰ Centro Hospitalar e Universitário de Coimbra, University of Coimbra, Coimbra, Portugal

¹¹ Royal London Hospital and Great Ormond Street Hospital, London, England

¹² Hospital Virgen Macarena, Sevilla, Spain

¹³ Ocular Oncology, Siena University Hospital, Siena, Italy

¹⁴ University Hospital Brno and St. Anna University Hospital/ICRC, Masaryk University, Brno, Czech Republic

¹⁵ East-Tallinn Central Hospital, Tallinn, Estonia

¹⁶ Hacettepe University Hospital, Ankara, Turkey

¹⁷ Department of Ophthalmology, Semmelweis University, Budapest, Hungary

Abbreviations: CNS, central nervous system; EURbG, European Retinoblastoma Group; GALOP, Grupo de America Latina de Oncologia Pediatrica; IRSS, International Retinoblastoma Staging System; OS, overall survival

This is an open access article under the terms of the [Creative Commons Attribution-NonCommercial](https://creativecommons.org/licenses/by-nc/4.0/) License, which permits use, distribution and reproduction in any medium, provided the original work is properly cited and is not used for commercial purposes.

© 2021 The Authors. *Pediatric Blood & Cancer* published by Wiley Periodicals LLC

- ¹⁸ Pediatric Hematology, Oncology and Stem Cell Transplant Division, Padua University Hospital, Padua, Italy
- ¹⁹ Department of Pediatric Oncology and Hematology, University Children's Hospital of Krakow, Krakow, Poland
- ²⁰ Centre for Pediatric Oncology and Hematology, Vilnius University, Vilnius, Lithuania
- ²¹ Department of Pediatric Hematology/Oncology, IRCCS, Ospedale Pediatrico Bambino Gesù, Rome, Italy
- ²² The Children's Memorial Health Institute, Warsaw, Poland
- ²³ Pediatric Hematology and Oncology, University Hospital Vall d'Hebron, Barcelona, Spain
- ²⁴ Hospital La Paz, Madrid, Spain
- ²⁵ Charles University in Prague, 2nd Faculty of Medicine and University Hospital Motol, Prague, Czech Republic
- ²⁶ Department of Particle Therapy, University Hospital Essen, West German Proton Therapy Centre Essen (WPE), West German Cancer Center (WTZ), Essen, Germany
- ²⁷ German Consortium for Translational Cancer Research (DKTK), Essen, Germany German Cancer Research Center (DKFZ), Heidelberg, Germany
- ²⁸ The Goldschleger eye institute, Sheba Medical Center, Tel Aviv University, Tel Aviv, Israel
- ²⁹ Division of Pediatric Hematology/Oncology, Medical University of Graz, Graz, Austria
- ³⁰ Birmingham Children's Hospital, Birmingham, England
- ³¹ Department of Ophthalmology, Amsterdam UMC, Vrije Universiteit Amsterdam, Cancer Center Amsterdam, Amsterdam, The Netherlands
- ³² Jules-Gonin Eye Hospital, Fondation Asile des Aveugles, University of Lausanne, Lausanne, Switzerland
- ³³ Department of Pediatric Hematology and Oncology, University Hospital CHUV University of Lausanne, Lausanne, Switzerland
- ³⁴ Hospital Sant Joan de Deu, Barcelona, Spain

Correspondence

Petra Ketteler, Department of Pediatric Hematology and Oncology, University Hospital Essen, Hufelandstrasse 55, 45122 Essen, Germany.
Email: petra.ketteler@uk-essen.de

Funding information

Deutsche Kinderkrebsstiftung, Grant/Award Numbers: 2018.12, 2016.09

Abstract

Introduction: Advanced intraocular retinoblastoma can be cured by enucleation, but spread of retinoblastoma cells beyond the natural limits of the eye is related to a high mortality. Adjuvant therapy after enucleation has been shown to prevent metastasis in children with risk factors for extraocular retinoblastoma. However, histological criteria and adjuvant treatment regimens vary and there is no unifying consensus on the optimal choice of treatment.

Method: Data on guidelines for adjuvant treatment in European retinoblastoma referral centres were collected in an online survey among all members of the European Retinoblastoma Group (EURbG) network. Extended information was gathered via personal email communication.

Results: Data were collected from 26 centres in 17 countries. Guidelines for adjuvant treatment were in place at 92.3% of retinoblastoma centres. There was a consensus on indication for and intensity of adjuvant treatment among more than 80% of all centres. The majority of centres use no adjuvant treatment for isolated focal choroidal invasion or prelaminar optic nerve invasion. Patients with massive choroidal invasion or postlaminar optic nerve invasion receive adjuvant chemotherapy, while microscopic invasion of the resection margin of the optic nerve or extension through the sclera are treated with combined chemo- and radiotherapy.

Conclusion: Indications and adjuvant treatment regimens in European retinoblastoma referral centres are similar but not uniform. Further biomarkers in addition to histopathological risk factors could improve treatment stratification. The high consensus in European centres is an excellent foundation for a common European study with prospective validation of new biomarkers.

KEYWORDS

biomarker, chemotherapy, childhood cancer, metastasis, radiotherapy, RB1 gene

1 | INTRODUCTION

Retinoblastoma is a malignant tumour of the retina in early childhood. In most European countries, 5-year survival rates of retinoblastoma are above 95%.^{1–3} Advances in multidisciplinary care and early diagnosis prevent the spread of tumour cells beyond the natural border of the eye and, as a consequence, metastasized retinoblastoma is very rare. However, the prognosis of metastatic disease remains poor even with intensive multimodal therapy in high-income countries.^{3,4} In contrast, low- and middle-income countries facing problems of late diagnosis and lower resources report a higher number of patients with advanced retinoblastoma disease. In these countries, systemic metastases are the cause of a significant mortality of retinoblastoma patients.⁵

Most eyes with small- or medium-sized intraocular retinoblastoma are treated with eye-preserving therapies. Primary enucleation remains the standard therapy for advanced ocular disease with suspected risk of extraocular extension.^{6,7} Most children in Europe are cured after enucleation without any further therapy. However, children diagnosed with histopathological risk factors for metastatic spread receive a risk-stratified adjuvant treatment after enucleation to reduce the risk of metastasis. Retrospective data demonstrate that without adjuvant therapy about 20% of patients with histological intermediate- and high-risk factors developed metastatic disease.^{8,9} After introduction of risk-stratified adjuvant treatment, only 0–6% patients with histological risk factors developed metastatic disease.^{9,10} Recent nonrandomised prospective trials using risk-stratified adjuvant chemotherapy demonstrate overall survival (OS) rates for children with advanced retinoblastoma as high as 100% for most risk groups.^{11,12}

In 2009, the International Retinoblastoma Staging and Working Group established consensus guidelines for the pathological examination of the extension of retinoblastoma after enucleation.¹³ The histopathological risk factors for metastatic spread include choroidal invasion, invasion of the anterior chamber, scleral invasion and infiltration of the optic nerve to different extents. Choroidal and scleral invasion favours hematogenous spread, whereas the infiltration of the optic nerve increases the risk of central nervous system (CNS) metastases. Commonly used staging systems are the International Retinoblastoma Staging System (IRSS),¹⁴ the TNM classification¹⁵ and modified St. Jude Classification.¹⁶ For a risk-stratified use of adjuvant treatment, histopathological risk factors are further subgrouped into low-risk, intermediate-risk and high-risk factors.

Although the benefit of adjuvant chemotherapy is apparent, data supporting the prognostic impact of different intensities of chemotherapy and individual histopathological risk factors are limited due to the number of patients and lack of randomised clinical trials in high-income countries.^{17,18} Treatment for retinoblastoma in European referral centres is similar but not uniform, and a variety of different chemotherapy and radiotherapy regimens have been used for adjuvant treatment in the last decades. The European Retinoblastoma Group (EURbG) is a pan-European partnership between professionals involved in the

care of patients affected by retinoblastoma and their families with a common goal to share and disseminate knowledge and experience within Europe (<http://www.eurbg.org>). The results of the here presented survey conducted by the EURbG summarizes and compares the recommendations used for adjuvant treatment in Europe with the aim to agree on a consensus regimen and to build the foundation for a prospective international clinical trial for advanced localised retinoblastoma in Europe.

2 | METHODS

2.1 | Data collection

Representatives of European retinoblastoma referral centres were contacted via the EURbG network. First data collection of guidelines on adjuvant treatment for retinoblastoma was conducted with SurveyMonkey between March 2 and 16, 2018. All EURbG members were invited to submit one response per retinoblastoma referral centre. The survey did not include individual patient data. Extended information, including treatment protocols and outcome data, was gathered via personal communication until October 2020 addressing all responders to the survey.

3 | RESULTS

3.1 | Patient characteristics at the participating centres

Data were collected with an online survey from 26 centres of 17 countries (11 × 1 centre/country, 4 × 2 centres/country, 1 × 3 centres/country and 1 × 4 centres/country). The participating centres were in the following European countries: Austria, Czech Republic, England, Estonia, France, Germany, Hungary, Israel, Italy, Lithuania, Netherlands, Poland, Portugal, Spain, Switzerland, Turkey and Ukraine. The size of the centres and the number of patients with retinoblastoma treated in each centre differ. For this survey, we only requested the number of patients treated with primary enucleation. The number of patients with retinoblastoma treated with primary enucleation depends not only on the total number of patients with retinoblastoma at each centre but also on the rate of patients receiving eye-preserving treatment. Because neither of these aspects was relevant for our study question, the survey focused on absolute number of patients with primary enucleation. Most centres (19/26, 73.0%) treat less than 10 patients per year with primary enucleation, while five centres (19.2%) and two centres (7.7%) perform primary enucleation on 10–19 patients and >20 patients per year, respectively. The number of patients receiving adjuvant therapy after enucleation is less than 10 patients in 88.5% of responding centres and 10–19 patients in the remaining 11.5% of centres each year.

TABLE 1 Current recommended adjuvant treatment after enucleation for different type of histological risk factors

Type of histopathological risk factor	Austria and Germany (RB-Registry)	Czech Republic	France and Lausanne RB SFCE 09	Israel	The Netherlands	Hospital Vall d'Hebron Spain	United Kingdom
Focal choroidal invasion	None	None	None	None	None	None	None
Massive choroidal invasion	3× VEC	6× VEC	2× VCy	6× VEC	6× VEC	6× VEC	4× JOE
Scleral invasion without extraocular disease (S1)	6× VEC	6× VEC	2× EC + 2× VCy	6× VEC	6× VEC	6× VEC	4× JOE
Transscleral extension (S2)	6× VEC + RT (40–50 Gy to the orbit)	6× VEC + RT	3× EC + 3× VCy ^{HR} + HD CTX + orbital RT	Induction CTX + orbital RT according to COG ARET 0321	Induction CTX + orbital RT according to COG ARET 0321	6× VEC + RT	Induction CTX according to COG ARET 0321 + orbital RT
Prelaminar or intralaminar optic nerve infiltration (N1)	None	None	None	None	None	None	None
Postlaminar optic nerve infiltration (N2)	6× VEC	6× VEC	2× EC + 2× VCy	6× VEC	6× VEC	6× VEC	4× JOE
Infiltration of resection margin of optic nerve (N3)	6× VEC + RT (40–50 Gy to the orbit)	6× VEC + RT	3× EC + 3× VCy ^{HR} + HD CTX + RT (45 Gy to the orbit)	Induction CTX + orbital RT according to COG ARET 0321	Induction CTX + orbital RT according to COG ARET 0321	6× VEC + RT (40 Gy to the orbit)	Induction CTX according to COG ARET 0321 + orbital RT

Note. Definition according to IRSS.¹³ CTX according to COG ARET 0321, induction chemotherapy cycle with vincristine, etoposide, cyclophosphamide, cisplatin.

Abbreviations: CTX, chemotherapy; EC, etoposide and carboplatin; HD CTX, high-dose chemotherapy followed by autologous SCT; JOE/VEC, vincristine, etoposide and carboplatin; RT, radiotherapy; VCy, vincristine and cyclophosphamide.

3.2 | Differences in staging systems and treatment guidelines

All but two retinoblastoma centres (92.3%) had guidelines for the indication and type of adjuvant treatment in place. In detail, 23.1% participated in a prospective IRB-approved protocol, 30.8% followed national guidelines, 30.8% institutional guidelines and 15.4% other type of recommendations. The contents of the guidelines of some centres are summarised in Table 1. Histopathological risk factors were determined based on the international guidelines for pathological evaluation in 21 of 26 centres (80.8%).¹³ The most common staging systems for extraocular disease were the IRSS (applied in 61.5% of centres) and the TNM classification (in 42.3% of all centres), with some centres using both staging systems. One centre used the modified St. Jude classification.

3.3 | Diagnostics prior to enucleation

Nearly all centres (88.5%) routinely perform a cross-sectional imaging (magnet resonance imaging or computed tomography scan) of

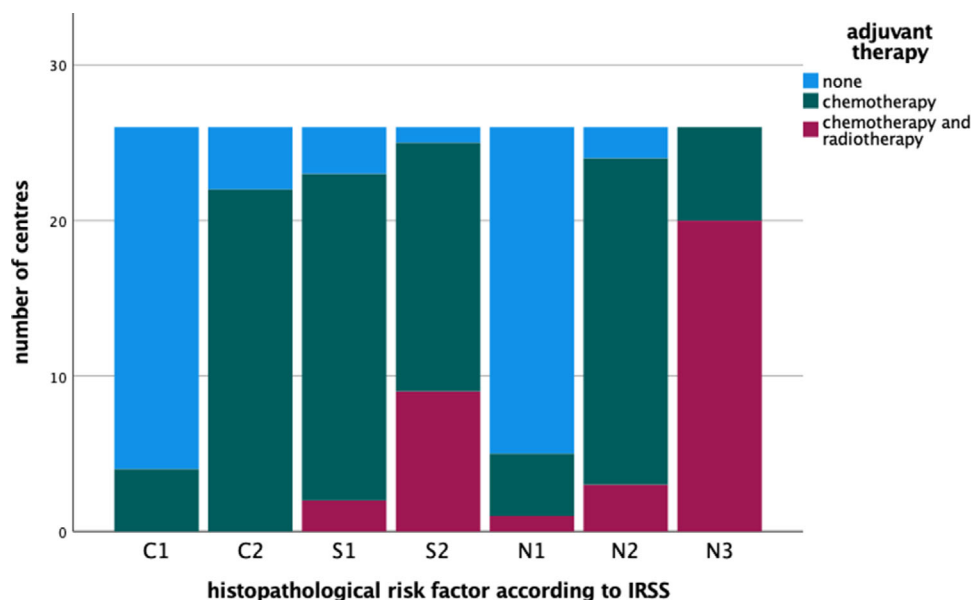
the neurocranium and both eyes after ophthalmological diagnosis of retinoblastoma via indirect ophthalmoscopy in anaesthesia. In most centres, invasive staging procedures such as lumbar puncture and bone marrow aspirates are reserved for patients with high-risk histopathological risk factors (data retrieved from personal communication and treatment guidelines after the survey).

3.4 | Consensus on indications for risk-stratified adjuvant treatment in most centres

Indications for risk-stratified treatment with either chemotherapy and/or radiotherapy are summarised in Table 2 and displayed in Figure 1. In 84.4% of centres, isolated focal choroidal invasion or isolated prelaminar optic nerve invasion are considered as low-risk histopathological risk factors and are not considered an indication for adjuvant therapy. However eight of 26 centres (30.8%) added as an additional comment that a combination of prelaminar optic nerve infiltration and focal choroidal infiltration is treated with adjuvant chemotherapy according to their guidelines. Nearly all centres treat patients with intermediate-risk factors defined as massive choroidal

TABLE 2 Different indications for risk-stratified adjuvant treatment

Histopathological risk factor	No adjuvant treatment	Adjuvant chemotherapy	Adjuvant chemotherapy and radiotherapy
Focal choroidal invasion (IRSS I, C1)	22 (85%)	4 (15%)	0
Massive choroidal invasion (IRSS I, C2)	4 (15%)	22 (85%)	0
Scleral invasion (IRSS I, S1)	3 (12%)	21 (80.8%)	2 (7.7%)
Transscleral extension (IRSS II, S2)	1 (3.9%)	16 (62%)	9 (35%)
Prelaminar optic nerve invasion (IRSS I, N1)	21 (81%)	4 (15%)	1 (3.9%)
Postlaminar optic nerve (IRSS I, N2)	2 (7.7%)	21 (81%)	3 (12%)
Resection margin of the optic nerve (IRSS II, N3)	0	5 (19%)	21 (81%)
Further risk factors highlighted by centres			
Anterior chamber or anterior segment (definition of risk factors in anterior segment varies)		18 (69%)	
Combination of prelaminar optic nerve invasion and focal choroidal invasion		8 (31%)	

**FIGURE 1** Recommendations and guidelines for adjuvant therapy for different risk factors among 26 European retinoblastoma centres

invasion (84.6% with chemotherapy) and postlaminar optic nerve invasion (80.8% with chemotherapy and 11.8% with chemo- and radiotherapy) with adjuvant therapy. In all centres, patients with invasion of the resection margin of the optic nerve receive adjuvant therapy (19.2% with chemotherapy alone, 80.8% with chemotherapy and radiotherapy). In line with this, nearly all centres treated the finding of microscopic extension through the sclera into the orbit with adjuvant

therapy (3.9% without adjuvant therapy, 61.5% with chemotherapy alone, 34.6% with chemotherapy and radiotherapy). In the survey, 69.2% of centres added that they treat invasion of the anterior segment of the eye with adjuvant chemotherapy. The definition of invasion of anterior segment varied and included tumour cell seeding in the anterior chamber and invasion of tumour cells into the iris, trabecular mesh or ciliary body.

3.5 | The combination of chemotherapy agents and regimens are similar

Current chemotherapy regimens in most countries include a combination of vincristine (88.5%), etoposide (96.2%) and carboplatin (100%). In some centres, additional cyclophosphamide (26.9%), ifosfamide (7.7%) or topotecan (7.7%) is applied. Cumulative doses of a selection of chemotherapy regimens are summarised in Table 3. In some centres, high-dose chemotherapy followed by autologous stem cell transplant is used for the treatment of patients with high-risk factors such as extrascleral microscopic spread or invasion of the resection margin of the optic nerve.¹²

3.6 | Intrathecal therapy

Consensus guidelines in some centres recommend additional intrathecal therapy for treatment of patients with invasion of the resection margin of the optic nerve, while other centres use intrathecal therapy only for the treatment of metastatic disease or do not use it at all. The chemotherapy agents used for intrathecal therapy of retinoblastoma in European centres vary and include thiothepa, topotecan, etoposide, cytarabine or cyclophosphamide.

3.7 | Adjuvant treatment results in high OS of localised advanced retinoblastoma despite histopathological risk factors

Only a minority of European centres have published their rates of overall and event-free survival after adjuvant treatment. The reported 5-year OS rates are as high as 100% in most risk groups. In published data, relapses only occurred in the group of patients with invasion of the resection margin or transscleral invasion, resulting in a 5-year OS of 80% (Table 4).

4 | DISCUSSION

European Retinoblastoma Referral Centres agree on most aspects of a risk-stratified adjuvant treatment after primary enucleation for retinoblastoma. However, adjuvant treatment protocols vary between all centres and the small number of patients in each centre complicates gathering of evidence to improve and advance recommendations. There is a consensus that focal choroidal invasion and pre- and intralaminar infiltration of the optic nerve are considered low-risk histopathological features and that these patients should be treated with enucleation alone without adjuvant chemotherapy. This is supported by a 2-year OS of 100% without adjuvant treatment.^{12,19} In most retinoblastoma centres, patients with intermediate histopathological risk factors receive chemotherapy including vincristine, carboplatin and etoposide as adjuvant treatment. In some guidelines,

TABLE 3 Differences in chemotherapy regimens

Chemotherapy agent ^a (mg/m ²)	Germany and Austria since 2016 ^b			Germany and Austria until 2016 ^b			United Kingdom		France and Lausanne ^c			Israel		Netherlands		Czech Republic (COG ARET0332)		Hospital Vall d'Hebron, Spain	
	VEC	RB-A	RB-B	RB-C	RB-C	RB-C	JOE ^d	EC	VCy	VCyHR	VEC	VEC	VEC	VEC	VEC	VEC	VEC	VEC	VEC
Vincristine	1.5	1.5	1.5	1.5	1.5	1.5	1.5	-	1.5	1.5	1.5	1.5	1.5	1.5	2	1.5	1.5	1.5	1.5
Carboplatin	560	-	300	300	300	600	600	800	-	-	-	560	560	560	560	560	560	560	560
Etoposide	300	450	450	-	-	300	300	500	-	-	300	300	300	150	150	300	300	300	300
Cyclophosphamide	-	1200	-	1200	-	-	-	-	1500	3000	-	-	-	-	-	-	-	-	-

^a Calculated per body surface area. Most regimens include calculation per body weight for body weight <10–12 kg that are not displayed in this table.

^b Alternating cycles of RB-A, RB-B, RB-C.

^c Alternating cycles: standard risk: EC and VCy; high risk: EC and VCyHR.

^d JOE and VEC stand for a chemotherapy containing vincristin, etoposide and carboplatin.

TABLE 4 Overall survival of patients with histopathological risk factors

Risk stratification	Germany and Austria ¹⁸	France SIOP abstract RB SFCE 09	France ¹¹
Study design	Retrospective	Prospective	Prospective
Years of recruitment	1997–2009	2010–2018	2001–2007
Outcome parameter	Patient number	5-year OS (%)	Patient number
Type of histopathological risk factors	Patient number	1-year OS (%)	Patient number
Low risk	-	-	70
Intermediate risk	42	100	52
High risk	6	80	1
Minimal or no choroidal involvement and/or prelaminar or no optic nerve involvement			
Massive choroidal invasion (C2), scleral invasion without extraocular disease (S1), postlaminar optic nerve infiltration PLONI (N2)			
Transscleral growth (S2) Infiltration of resection margin of optic nerve (N3)			

Abbreviation: OS, overall survival.

intermediate risk factors are subdivided into a subgroup with massive choroidal infiltration and a subgroup with retrolaminar optic nerve infiltration or intrascleral invasion. The subgroup with isolated massive choroidal infiltration was considered lower intermediate risk and received a reduced number of chemotherapy cycles and, despite this treatment reduction, the reported event-free and OS rates were 100% (Institute Curie, France, unpublished data). This high survival rate supports that reduction of adjuvant therapy is safe in patients with massive choroidal invasion. The finding also raises the question, whether this treatment can be further reduced or omitted. Indeed, results from a multicentre trial in Latin America (Grupo de America Latina de Oncologia Pediatrica [GALOP]) demonstrate a probability of event-free survival of 100% without adjuvant treatment for patients with massive choroidal invasion alone.^{18,20,21}

There is a controversy about the risk for metastasis associated with involvement of anterior segment of the eye. Among other reasons, this is a result of varying definitions of involvement of anterior segment and the common combination of anterior segment involvement with other risk factors for metastasis. Definition of anterior segment involvement includes tumour cell seeds in the anterior chamber, invasion of the iris, of the trabecular meshwork or the ciliary body. Especially isolated seeding into the anterior chamber is rare. In most patients, it occurs in combination with multiple other risk factors that are an indication for adjuvant chemotherapy by themselves.^{11,22} As a result, some studies conclude that isolated seeding into the anterior chamber is an indication for adjuvant chemotherapy while others emphasize that it does not add additional risk for metastasis.^{9,22,23} The latter is in contrast to the current practice in most European centres.

Most, but not all, European centres apply not only adjuvant chemotherapy but also radiotherapy of the orbit for transscleral invasion and for invasion of the resection margin of the optic nerve (high-risk factors, microscopic extraocular spread [IRSS stage II]). Adjuvant chemotherapy regimens for IRSS II in Europe nearly always comprise of six cycles of polychemotherapy with vincristine, carboplatin and etoposide. The modality of radiotherapy of the orbit varies from external beam photon and proton therapy to orbital brachytherapy with 125 iodine seeds while recommended doses are 40–50 Gray.^{24,25} Only small number of patients are treated in this high-risk group in Europe, but extraocular disease recurrence is observed even after adjuvant treatment and the reported 5-year OS is 80%.¹⁹ Some centres that perform high-dose chemotherapy followed by autologous stem cell transplant as consolidation treatment for IRSS II report a 100% cure rates.¹² In line with this, prospective trials of the GALOP demonstrate excellent results with nearly 100% OS in patients with extrascleral involvement after adjuvant treatment with intensive chemotherapy regimen but without radiotherapy.²⁶ Some European retinoblastoma centres and the current GALOP protocol use intrathecal chemotherapy as part of the adjuvant treatment (<https://clinicaltrials.gov/ct2/show/NCT03475121>). There is rational for intrathecal therapy to prevent spread to the CNS, but evidence from prospective studies evaluating the benefit of different agents is scarce.²⁷

The benefit of adjuvant therapy to reduce the risk for metastasis has to be balanced with the potential side effects. Reported

short-term side effects of adjuvant chemotherapy regimens include transient bone marrow suppression and a risk for fever in neutropenia. A treatment-related mortality of 4% was reported by the AHOPCA group in Central America after VEC chemotherapy.⁵ However, in European and in Northern American treatment related mortality after conventional chemotherapy for retinoblastoma has been reported as close to 0%.^{10,19} Ototoxicity has to be monitored regularly, but it seems to be rare in most cohorts.^{28–31} Nonetheless, it remains a possible side effect after high-dose chemotherapy for patients with infiltration of the resection margin of the optic nerve who already have a visual handicap. Adjuvant treatment also prolongs the treatment for retinoblastoma and may increase the psychosocial burden for patients and their families. There is evidence that chemotherapy with alkylating agents or topoisomerase inhibitors increases the risk for second malignancies, especially in patients with heritable retinoblastoma, but the number of second malignancies after adjuvant therapy alone is low.^{10,32,33} In summary, side effects of adjuvant treatment are tolerable but not neglectable. For this reason, adjuvant treatment has to be restricted to the patients with a significant risk of metastatic disease.

The number of patients receiving primary enucleation was low in all participating European retinoblastoma referral centres. Since the introduction of intra-arterial chemotherapy in 2008 and intravitreal chemotherapy treatment in 2012, an increasing number of patients with advanced retinoblastoma receive first-line eye-preserving therapies.^{6,34} Risk factors diagnosed on magnetic resonance imaging at diagnosis correlate with diagnosis of histopathological risk factors and may assist to evaluate the need for enucleation and histopathological assessment of risk factors.^{35,36} However, radiological risk factors are only a proxy for histopathological risk factors, and there is a consensus to indicate adjuvant therapy only on the basis of proven histopathological risk factors. Some potential molecular biomarkers for disseminated retinoblastoma were described, like the detection of *cone-rod homeobox (CRX)* mRNA or GD2 protein expression and the detection of somatic pathogenic *RB1* variant in blood, bone marrow aspirate or cerebral spinal fluid.^{37–39} Some of these biomarkers correlate with metastatic relapse in high-risk patients, but have not been evaluated in a prospective study or in low-risk patients.^{40,41}

In summary, there is evidence that risk-stratified adjuvant treatment for advanced retinoblastoma with histopathological risk factors improves survival. Indications and treatment regimens in European Retinoblastoma Referral centres are similar but not uniform. The low number of patients with retinoblastoma that receive primary enucleation complicates study design. An international collaborative prospective approach is required to gather evidence and to adjust the intensity of adjuvant treatment for each patient. The good level of consensus in treatment regimens and the collaboration within the EURbG network allows to envisage a common European study with prospective validation of new biomarkers. Especially in the light of an increasing number of patients treated with eye-preserving therapies, there is a high need for further molecular and radiological biomarkers in addition to histopathological risk factors for treatment stratification.

ACKNOWLEDGEMENTS

We would like to thank all members of the EURbG for support and the European Reference Network for Paediatric Oncology (ERN PAED-CAN).

Open access funding enabled and organized by Projekt DEAL.

CONFLICT OF INTEREST

The authors declare that there is no conflict of interest.

DATA AVAILABILITY STATEMENT

The data that support the findings of this study are available from the corresponding author upon reasonable request.

ORCID

Madlen Reschke  <https://orcid.org/0000-0003-1706-1160>

Isabelle Aerts  <https://orcid.org/0000-0002-5213-3353>

Martin Ebinger  <https://orcid.org/0000-0002-4229-8058>

Erika Maka  <https://orcid.org/0000-0002-3631-3506>

Ida Russo  <https://orcid.org/0000-0002-7030-8639>

Karel Svojr  <https://orcid.org/0000-0003-1267-4072>

Guillermo Chantada  <https://orcid.org/0000-0002-9375-9336>

Petra Ketteler  <https://orcid.org/0000-0002-8138-0441>

REFERENCES

1. Temming P, Arendt M, Viehmann A, et al. How eye-preserving therapy affects long-term overall survival in heritable retinoblastoma survivors. *J Clin Oncol*. 2016;34(26):3183–3188.
2. Lumbroso-Le Rouic L, Aerts I, Hajage D, et al. Conservative treatment of retinoblastoma: a prospective phase II randomized trial of neoadjuvant chemotherapy followed by local treatments and chemotherapy. *Eye (Lond)*. 2016;30(1):46–52.
3. Gunduz AK, Mirzayev I, Temel E, et al. A 20-year audit of retinoblastoma treatment outcomes. *Eye (Lond)*. 2020;34(10):1916–1924.
4. Dunkel IJ, Krailo MD, Chantada GL, et al. Intensive multimodality therapy for extra-ocular retinoblastoma (RB): a Children's Oncology Group (COG) trial (ARET0321). *J Clin Oncol*. 2017;35(15_suppl):10506–10506.
5. Luna-Fineman S, Chantada G, Alejos A, et al. Delayed enucleation with neoadjuvant chemotherapy in advanced intraocular unilateral retinoblastoma: AHOPCA II, a prospective, multi-institutional protocol in Central America. *J Clin Oncol*. 2019;37(31):2875–2882.
6. Abramson DH, Shields CL, Munier FL, Chantada GL. Treatment of retinoblastoma in 2015: agreement and disagreement. *JAMA Ophthalmol*. 2015;133(11):1341–1347.
7. Ancona-Lezama D, Dalvin LA, Shields CL. Modern treatment of retinoblastoma: a 2020 review. *Indian J Ophthalmol*. 2020;68(11):2356–2365.
8. Honavar SG. Postenucleation adjuvant therapy in high-risk retinoblastoma. *Arch Ophthalmol*. 2002;120(7):923–931.
9. Khelfaoui F, Validire P, Auperin A, et al. Histopathologic risk factors in retinoblastoma: a retrospective study of 172 patients treated in a single institution. *Cancer*. 1996;77(6):1206–1213.
10. Kaliki S. Postenucleation adjuvant chemotherapy with vincristine, etoposide, and carboplatin for the treatment of high-risk retinoblastoma. *Arch Ophthalmol*. 2011;129(11):1422–1427.
11. Chévez-Barrios P, Eagle RC, Krailo M, et al. Study of unilateral retinoblastoma with and without histopathologic high-risk features

- and the role of adjuvant chemotherapy: a Children's Oncology Group Study. *J Clin Oncol*. 2019;37(31):2883–2891.
12. Aerts I, Sastre-Garau X, Savignoni A, et al. Results of a multicenter prospective study on the postoperative treatment of unilateral retinoblastoma after primary enucleation. *J Clin Oncol*. 2013;31(11):1458–1463.
 13. Sastre X, Chantada GL, Doz F, et al. Proceedings of the consensus meetings from the International Retinoblastoma Staging Working Group on the pathology guidelines for the examination of enucleated eyes and evaluation of prognostic risk factors in retinoblastoma. *Arch Pathol Lab Med*. 2009;133(8):1199–1202.
 14. Chantada G, Doz F, Antoneli CBG, et al. A proposal for an international retinoblastoma staging system. *Pediatr Blood Cancer*. 2006;47(6):801–805.
 15. Mallipatna A, Gallie B, Chévez-Barrios P. Retinoblastoma. In: Amin MB, Edge S, Greene F, et al., eds. *AJCC Cancer Staging System*. 8th ed. Switzerland: Springer International Publishing; 2017:819–831.
 16. Pratt CB, Fontanesi J, Lu X, Parham DM, Elfervig J, Meyer D. Proposal for a new staging scheme for intraocular and extraocular retinoblastoma based on an analysis of 103 globes. *Oncologist*. 1997;2(1):1–5.
 17. Chantada GL, Casco F, Fandiño AC, et al. Outcome of patients with retinoblastoma and postlaminar optic nerve invasion. *Ophthalmology*. 2007;114(11):2083–2089.
 18. Chantada GL. Retinoblastoma patients with high risk ocular pathological features: who needs adjuvant therapy? *Br J Ophthalmol*. 2004;88(8):1069–1073.
 19. Künkele A, Wilm J, Holdt M, et al. Neoadjuvant/adjuvant treatment of high-risk retinoblastoma: a report from the German retinoblastoma referral centre. *Br J Ophthalmol*. 2015;99(7):949–953.
 20. Chantada G, Fandiño A, Dávila MTG, et al. Results of a prospective study for the treatment of retinoblastoma. *Cancer*. 2004;100(4):834–842.
 21. Pérez V, Sampor C, Rey G, et al. Treatment of nonmetastatic unilateral retinoblastoma in children. *JAMA Ophthalmol*. 2018;136(7):747–752.
 22. Sreelakshmi KV, Chandra A, Krishnakumar S, Natarajan V, Khetan V. Anterior chamber invasion in retinoblastoma: not an indication for adjuvant chemotherapy. *Invest Ophthalmol Vis Sci*. 2017;58(11):4654–4661.
 23. Baroni LV, Sampor C, Fandiño A, et al. Anterior segment invasion in retinoblastoma: is it a risk factor for extraocular relapse? *J Pediatr Hematol Oncol*. 2014;36(8):e509–e512.
 24. Stannard C, Sealy R, Hering E, et al. Postenucleation orbits in retinoblastoma: treatment with 125I brachytherapy. *Int J Radiat Oncol Biol Phys*. 2002;54(5):1446–1454.
 25. Kim J-Y, Park Y. Treatment of retinoblastoma: the role of external beam radiotherapy. *Yonsei Med J*. 2015;56(6):1478–1491.
 26. Cuenca A. Microscopic scleral invasion in retinoblastoma: clinicopathological features and outcome. *Arch Ophthalmol*. 2009;127(8):1006–1010.
 27. Schaiquevich P, Carcaboso AM, Buitrago E, et al. Ocular pharmacology of topotecan and its activity in retinoblastoma. *Retina*. 2014;34(9):1719–1727.
 28. Qaddoumi I, Bass JK, Wu J, et al. Carboplatin-associated ototoxicity in children with retinoblastoma. *J Clin Oncol*. 2012;30(10):1034–1041.
 29. Jehanne M, Lumbroso-Le Rouic L, Savignoni A, et al. Analysis of ototoxicity in young children receiving carboplatin in the context of conservative management of unilateral or bilateral retinoblastoma. *Pediatr Blood Cancer*. 2009;52(5):637–643.
 30. Soliman SE, D'silva CN, Dimaras H, Dzneldze I, Chan H, Gallie BL. Clinical and genetic associations for carboplatin-related ototoxicity in children treated for retinoblastoma: a retrospective noncomparative single-institute experience. *Pediatr Blood Cancer*. 2018;65(5):e26931.
 31. Smits C, Swen SJ, Theo Goverts S, Moll AC, Imhof SM, Schouten-Van Meeteren AYN. Assessment of hearing in very young children receiving carboplatin for retinoblastoma. *Eur J Cancer*. 2006;42(4):492–500.
 32. Wong JR, Morton LM, Tucker MA, et al. Risk of subsequent malignant neoplasms in long-term hereditary retinoblastoma survivors after chemotherapy and radiotherapy. *J Clin Oncol*. 2014;32(29):3284–3290.
 33. Gombos DS, Hungerford J, Abramson DH, et al. Secondary acute myelogenous leukemia in patients with retinoblastoma: is chemotherapy a factor? *Ophthalmology*. 2007;114(7):1378–1383.
 34. Munier FL, Gaillard M-C, Balmer A, et al. Intravitreal chemotherapy for vitreous disease in retinoblastoma revisited: from prohibition to conditional indications. *Br J Ophthalmol*. 2012;96(8):1078–1083.
 35. Sirin S, De Jong MC, De Graaf P, et al. High-resolution magnetic resonance imaging can reliably detect orbital tumor recurrence after enucleation in children with retinoblastoma. *Ophthalmology*. 2016;123(3):635–645.
 36. Sirin S, Schlamann M, Metz KA, et al. High-resolution MRI using orbit surface coils for the evaluation of metastatic risk factors in 143 children with retinoblastoma: part 1: MRI vs. histopathology. *Neuroradiology*. 2015;57(8):805–814.
 37. Dimaras H, Rushlow D, Halliday W, et al. Using RB1 mutations to assess minimal residual disease in metastatic retinoblastoma. *Transl Res*. 2010;156(2):91–97.
 38. Torbidoni AV, Laurent VE, Sampor C, et al. Association of conerod homeobox transcription factor messenger RNA with pediatric metastatic retinoblastoma. *JAMA Ophthalmol*. 2015;133(7):805–812.
 39. Laurent VE, Otero LL, Vazquez V, et al. Optimization of molecular detection of GD2 synthase mRNA in retinoblastoma. *Mol Med Rep*. 2010;3(2):253–259.
 40. Aschero R, Torbidoni A, Sampor C, et al. Minimally disseminated disease and outcome in overt orbital retinoblastoma. *Pediatr Blood Cancer*. 2019;66(6):e27662.
 41. Laurent VE, Torbidoni AV, Sampor C, et al. Minimal disseminated disease in nonmetastatic retinoblastoma with high-risk pathologic features and association with disease-free survival. *JAMA Ophthalmol*. 2016;134(12):1374–1379.

SUPPORTING INFORMATION

Additional supporting information may be found online in the Supporting Information section at the end of the article.

How to cite this article: Dittner-Moormann S, Reschke M, Abbink FCH, et al. Adjuvant therapy of histopathological risk factors of retinoblastoma in Europe: A survey by the European Retinoblastoma Group (EURBG). *Pediatr Blood Cancer*. 2021;68:e28963. <https://doi.org/10.1002/pbc.28963>