

Determination of Cell Proliferation and Apoptosis in Placentas of Chronically Stressed Rats

COTS DS¹, Rolando A¹, Mugnaini MT¹, Soñez CA¹, Bozzo A¹, Borghi D¹, Gauna Hf^{2*} and Romanini MC¹

¹Laboratory of Cell Biology and Embryology, Anatomy Department, Faculty of Agronomy and Veterinary, Argentina

²Department of Molecular Biology, Faculty of Sciences, National University of Rio Cuarto, Argentina

Abstract

Chronic stress during gestation can alter several mechanisms that maintain homeostasis in the placenta. The aim of this study was to determine both effects of chronic stress on the apoptotic and cell proliferation processes in placentas of rats, during the second half of pregnancy and the immunolocalization of apoptotic and proliferating marked nuclei in the different placental zones. Stress by immobilization was applied to rats from the 4th day of pregnancy until their sacrifice on days 12, 17 or 21. Placental sections were immunolabeled with anti-BrdU and TUNEL. The apoptotic index did not present significant differences between control and stress groups. The gestational day influenced significantly on the apoptotic index, which showed a significant decrease on day 17 of gestation and significant increase on day 21. The proliferating index presented significant differences between gestational stages studied, which showed a significant increase at day 17 and then a significant decrease at day 21. Moreover, the stress treatment applied highly influenced on the proliferation index. In conclusion, chronic stress by immobilization did not produce effects on apoptotic process. However it produces an increase in cellular proliferation index in the three gestation days analyzed, which could generate a deleterious environment for the fetus development.

Keywords: Chronic stress; Apoptosis; Cell proliferation; Placenta

Introduction

The placenta is an extraembryonic tissue located between the maternal and fetal compartments [1]. This structure provides highly specialized functions during gestation that are critical for the normal embryo/fetus development [2]. This structure performs the functions of most of fetal organs throughout gestation due to the immaturity of the embryo [3].

Rodents possess two placental structures: the choriovitelline placenta, which develops first (until the day 11 of pregnancy) and the chorioallantoic placenta, which develops in the second half of gestation, showing considerable developmental changes with advancing gestation. Two prominent regions are formed within the chorioallantoic placenta: 1) Junctional Zone (JZ) and 2) Labyrinth Zone (LZ) [4]. Four differentiated trophoblast cell phenotypes comprising the rat chorioallantoic placenta can be readily identified: 1) trophoblast giant cells, 2) spongiotrophoblast cells, 3) glycogen cells and 4) syncytial trophoblast cells [5-8].

Stressing situations simultaneously activate both the hypothalamic-pituitary-adrenocortical axis and the sympathetic-medullary-adrenal axis, but it has been postulated that both axis respond differently to stressful stimuli [9-13]. The Corticotropin-Releasing Hormone (CRH), secreted by the hypothalamus stimulates the Adrenocorticotropic-Releasing Hormone (ACTH) secretion by the pituitary [14]. In turn, ACTH stimulates the secretion of glucocorticoids by the adrenal cortex. In the course of pregnancy, CRH is also produced by the placenta and has the same biological activity as hypothalamic CRH [15-17]. The fetal sympathetic-medullary-adrenal axis, releases finally adrenaline and noradrenaline to restore homeostasis [18].

Maternal glucocorticoids in stress conditions can cause side effects in relation to placental growth and development, as the alteration of two important processes: apoptosis and cell proliferation. The balance between cell differentiation, cell death and cell proliferation is essential for most of the physiological processes that occur during pregnancy and together maintain tissue homeostasis [19-24].

Apoptosis is a biological phenomenon, which consists in a regulatory and active cellular response to specific stimuli [25-27]. Apoptosis occurs in all placental cell types, and is recognized to be physiologically important for normal placental growth and development [28-30].

Several well characterized morphological features of apoptosis include: nuclear membrane breakdown, chromatin condensation and fragmentation, cell membrane blebbing, and formation of apoptotic bodies [31]. One method for evaluating apoptosis in the placental tissue is the TUNEL (terminal deoxynucleotidyl transferase-mediated deoxyuridine triphosphate nick end labeling) method. The TUNEL staining technique was first described by Gavrieli et al. in 1992 [32]. It detects apoptosis in the final steps of the cascade.

Another process involved in the placental development is cell proliferation, which may be regulated by different proteins for the correct functioning of the tissue. In previous studies, specific techniques to assess cell proliferation were developed, such as incorporation of 5-bromo-2'-deoxyuridine (BrdU), which is readily incorporated into nuclei during the DNA synthetic phase of the cell cycle (S-phase) and acts as an analogue of thymine [33,34].

The aim of this study was to determine both effects of chronic stress on the apoptotic and cell proliferation processes in placentas of rats during the second half of pregnancy and the immunolocalization of apoptotic and proliferating marked nuclei in the different placental zones.

***Corresponding author:** Romanini MC, Laboratory of Cell Biology and Embryology, Anatomy department, Faculty of Agronomy and Veterinary, Argentina, E-mail: mcromanini@yahoo.com.ar

Received February 20, 2013; Published March 20, 2013

Citation: COTS DS, Rolando A, Mugnaini MT, Soñez CA, Bozzo A, et al. (2013) Determination of Cell Proliferation and Apoptosis in Placentas of Chronically Stressed Rats. 2: 664. doi: [10.4172/scientificreports.664](http://dx.doi.org/10.4172/scientificreports.664)

Copyright: © 2013 COTS DS, et al. This is an open-access article distributed under the terms of the Creative Commons Attribution License, which permits unrestricted use, distribution, and reproduction in any medium, provided the original author and source are credited.

Materials and Methods

Animal's

Young female primipar Wistar-albino rats of 200 to 300 g were used. Four pregnant rats per cage were housed and, allowed *ad-libitum* access to food and water and maintained on a constant 12:12 light/dark cycle at constant room temperature ($22^{\circ}\text{C} \pm 2^{\circ}\text{C}$) and humidity (60%) (Laboratory installations were adequate to disposition 6344/96 of the Administración Nacional de Medicamentos, Alimentos y Tecnología Médica, and Argentina. The Conclusions and Recommendation on the Reduction, Refinement and Replacement of Laboratory Animals Procedure of Declaration of Bologna were followed for animal experimentation. All experiments were conducted according to the principles and procedures of the NIH Guide for the Care and Use of Laboratory Animals (NIH publication n°85-23, revised 1985. Females were mated during the proestrous with a same strain male and the day on which spermatozoa were present in a vaginal smear was designated day 0 of pregnancy. Pregnant females were separated into two groups: Control (C) and Stress (S).

Experimental treatment

From the 4th day of pregnancy, pregnant females in the S group were placed for 45 min, in a plastic cylinder, 3 times a week, in the morning and different times to prevent adaptation. This stress procedure was chosen because it has an indirect influence on the placenta via a direct stress on the mother. Chronic stress was evaluated by plasma corticosterone levels. This process lasted until their sacrifice. Pregnant rats of the C and S groups were sacrificed on days 12, 17 and 21 of gestation. These days were chosen because on the 12th day of gestation the definitive structure of placenta is completed, on the 17th it reaches its maximum size, with the LZ continuing to expand thereafter and at a faster rate than the JZ and on the day 21 of gestation we have a full-term placenta. Seven (7) rats per gestation age for each group were obtained randomly ($n=21$ per group). The number of rats was chosen according to the data supplied by the Research Ethics Committee of the UNRC. Placentas were removed and fixed in 10% buffered formaldehyde 48 hours and processed according to the conventional histological technique. Treated rats were injected subcutaneously with 100 mg/kg of BrdU a day before the sacrifice [35].

BrdU detection

The hydrated sections were incubated for 10 min in 3% H₂O₂ to block endogenous peroxidase. Sections with anti-BrdU primary antibody (Sigma®) were incubated overnight at 4°C followed by 30 min room-temperature incubation in biotinylated secondary antibody (Vector Laboratories) and Avidine-Biotine-immunoperoxidasa complex (ABC, Vectastain kit, Vector Laboratories). Finally, the sections were incubated with 3-3'-diaminobenzidine (DAB), in the presence of H₂O₂ to reveal peroxidase expression sites and were counterstained with hematoxylin. Placental tissue without the primary antibody was used as negative control and small intestine sections as positive control.

Terminal deoxynucleotidyl transferase dUTP nick end labeling (TUNEL)

The technique was performed following the protocol provided by the Apoptag Plus *in situ* Apoptosis Peroxidase (Oncor, USA) kit.

The hydrated sections were incubated with K-proteinase during 8-10 minutes in humidified chamber. Endogenous peroxidase

blocking was done with 3% hydrogen peroxide. After being washed with PBS, sections were incubated with equilibrium buffer at room temperature. Terminal Deoxynucleotidyl Transferase (TdT) enzyme and dUTP-digoxigenin were added and incubated at 37°C for 1 h in a humidified chamber. The reaction was then stopped with a stop/wash buffer supplied with the kit, and the slides were incubated with an anti-digoxigenin-peroxidase solution for 30 min at room temperature, revealed with DAB, and counterstained with hematoxylin. Placental tissue without the TdT enzyme was used as negative control and post-lactation mammary gland as positive control.

Quantitative analysis

From each placenta histological section, 7 to 10 images were scanned randomly to build a raw image data base for C and S rats, completely covering the placental tissue. A Zeiss Axiophot microscope with a built in 3.2 Mpx Sony digital camera was used. For each image, positively marked cells either with anti-PCNA (in proliferation process) or with TUNEL technique (in apoptotic process) were quantified using Image J. The number of unmarked cells (contrasted with hematoxylin) was also quantified for each image. Data obtained were transferred to a data base in Excel software for further statistical analysis. The incidence of apoptosis and cell proliferation were determined in each placental tissue at different gestational stages (12, 17 and 21 days) using the Apoptotic Index (AI) and the Proliferative Index (PI), respectively. Both index were determined as the ratio between the number of positive apoptotic or proliferative nuclei (marked), and total cells number, multiplied by 100.

Statistical analysis

Differences among C and S groups and among gestational stages were assessed by two-way ANOVA followed by a DGC post hoc test. In each case, statistical significance was assumed at a P-value <0.05.

Results

TUNEL assay

Different zones of the placenta with apoptotic and normal nuclei are shown in Figure 1.

In histological sections of placenta from C and S rats on the 12th day of pregnancy, apoptotic cells were observed in both JZ and LZ. In C rats on the 17th day, apoptotic cells were mainly observed in JZ and in greater amount than in group S on the same day of gestation. In both C and S groups on the 21st day of pregnancy, apoptotic cells were mainly observed in LZ.

ANOVA test revealed no significant interaction between gestational stages and groups ($p=0.85$). However, significant differences among gestational stages ($p<0.0001$) and no significant differences between groups ($p=0.9282$) were observed.

A post hoc test was performed to determine existing differences among gestation days. Results revealed significant differences between days 12 and 17 ($p=0.00017$) and between 17 and 21 ($p=0.001$). No significant differences were observed between days 12 and 21 ($p=0.254$). These results were observed in the C and S groups.

On the 17th day, apoptosis decreased in both C and S groups, in relation with the 12th day of pregnancy, while this process increased on the 21st day of pregnancy in both groups. On the 17th day, AI showed a decrease in S group in relation with C group, while on the 12th and 21st

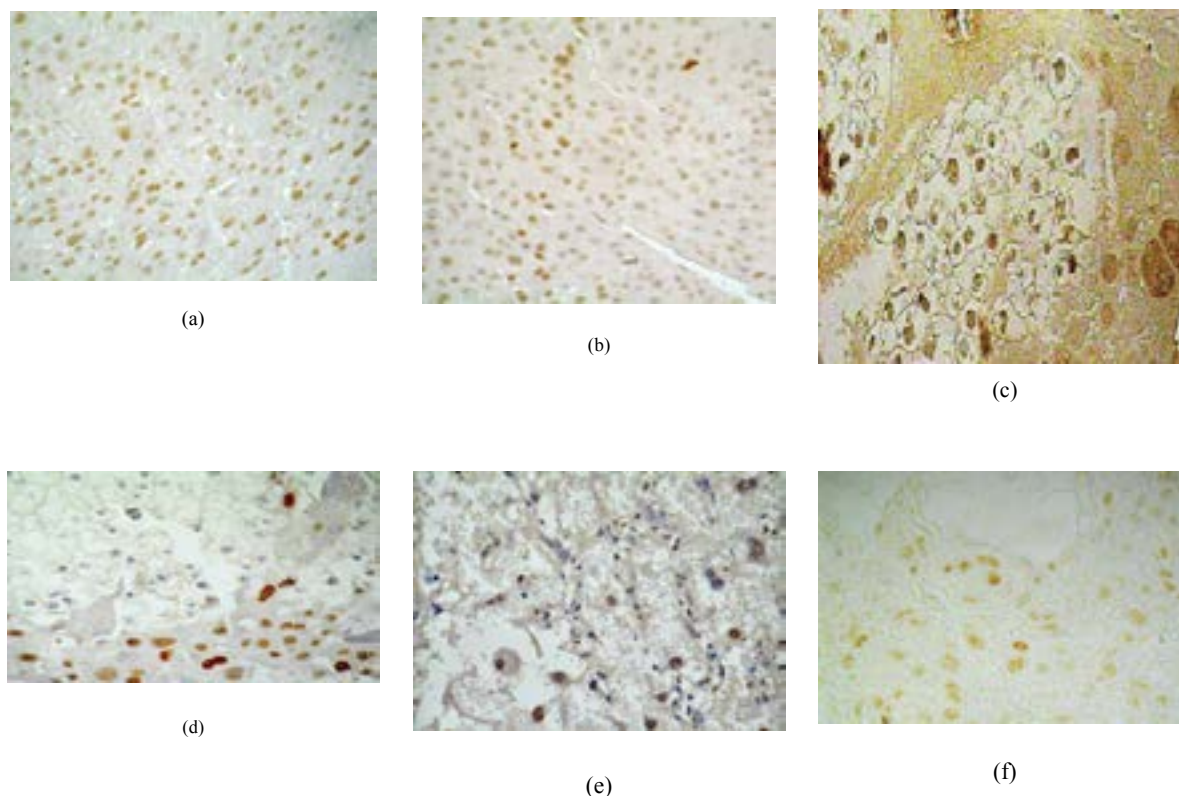


Figure 1: Histological sections of the placental zones from control (A, C, E) and stressed rats (B, D, F) at days 12 (A, B), 17 (C, D) and 21 (E, F) of pregnancy stained by using the TUNEL technique. Arrows indicate positive TUNEL nuclei. Apoptotic nuclei were stained in the spongioblast cells (SC) at the labyrinth zone on days 12 and 21 of pregnancy, control and stress and they were stained in the junctional zone at day 17, in glycogenic cells (GC) in control rats and in the trophoblast giant cells (TGC) in stressed rats.

days, AI increase in the S group compared to C group. Data are shown in Figure 2.

BrdU detection

Different zones of the placenta with proliferating and normal nuclei are shown in Figure 3.

Proliferating nuclei were present in both JZ and LZ. Most proliferative nuclei were observed in the S group, at all gestational stages.

BrdU marked nuclei were more abundant on the 17th day of pregnancy and less frequent on days 12 and 21 of pregnancy. This feature occurred in both groups.

ANOVA test revealed no significant interaction between gestational stages and groups ($p=0.9$). However, significant differences between groups ($p<0.0001$) and among gestational stages ($p=0.002$) were observed.

A post hoc test was performed to determine existing differences among gestation days. Results revealed significant differences between days 12 and 17 ($p=0.0044$) and between 17 and 21 ($p=0.01$). No significant differences were observed between days 12 and 21 ($p=0.91$). These results were observed in C and S groups.

Cell proliferation is higher in S group than in C group at all gestational stages. Data are shown in Figure 4.

Discussion

Apoptosis has been present in normal placenta throughout

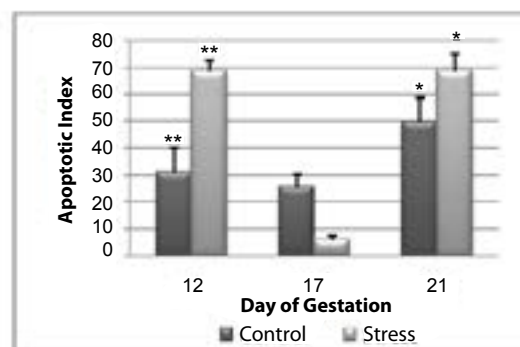


Figure 2: Total apoptotic index in the placenta on days 12, 17 and 21 of pregnancy. Control rats (C) vs. Stress rats (S). A significant decrease in the apoptotic index was detected between day 12 and 17 and day 17 and 21 for both groups C and S. (* $p<0, 05$; ** $p<0, 0001$).

pregnancy. Its concurrent appearance with cell proliferation reflects the growth and remodeling of the placenta. The two processes together maintain tissue homeostasis [21]. In line with other studies [26,29,30] our study has shown that both processes were observed in normal placental tissue development (C group).

Apoptosis and cell proliferation were observed in both placental zones. In LZ, these processes were observed mainly in spongiotrophoblast cells, whereas in JZ, they were observed in

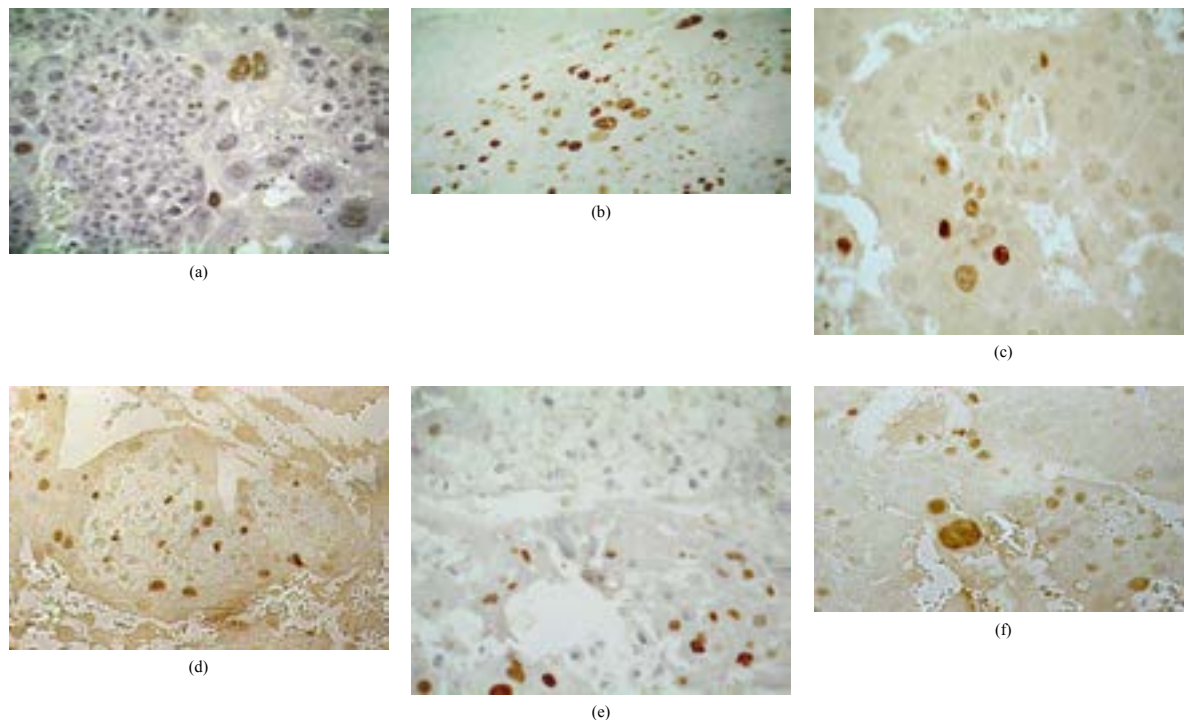


Figure 3: Histological sections of the placental zones from control (A, C, E) and stressed rats (B, D, F) at days 12 (A, B), 17 (C, D) and 21 (E, F) of pregnancy stained by using the BrdU proliferative assay. Arrows indicate positive BrdU nuclei. Proliferating nuclei were staining in the junctional zone in trophoblast giant cells (TGC) and in the spongioblast cells in all stages of pregnancy, control and stress groups.

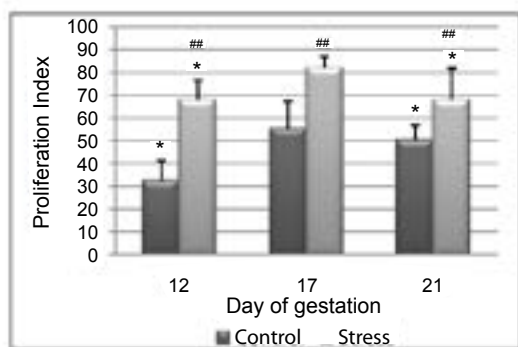


Figure 4: Total proliferation index in the placenta on days 12, 17 and 21 of pregnancy. Control rats (C) vs Stress rats (S). A significant increase in the proliferation index was detected between day 12 and 17 and day 17 and 21 for both groups C and S. (* $p < 0.05$). Significant differences between C and S groups in all gestational stages were observed (## $p < 0.0001$).

trophoblast giant cells. Our results are similar to those reported by Waddell et al. [30], who first proposed that apoptosis was clearly evident in both placental zones, and it was particularly prevalent in the JZ near term. These authors also demonstrated that apoptosis in JZ was stimulated by increased glucocorticoid exposure.

According with [27], apoptosis increases at the end of pregnancy. Agreeing with these authors, we have demonstrated a significant decrease in apoptosis on the 17th day of pregnancy, followed by an increase toward the end of gestation, in both C and S groups, whereas by contrast, cell proliferation showed an increase on the 17th day and a decrease on the 21st day of pregnancy.

Significant differences in AI and in PI were observed among gestational stages analyzed. These results were due to the fact that the placental tissue undergoes changes as pregnancy progresses. As a consequence, apoptosis increased over midterm and term in normal pregnancies. Our Immunohistochemical results showed that positive TUNEL nuclei gradually decreased from day 12 to 17 and gradually increased over day 21. For S group, the immunostaining pattern was very similar to that of C group. However, the number of apoptotic nuclei in placentas of S group was higher than in C group on days 12 and 21, while it was higher in C group on day 17. The opposite situation occurs in terms of cell proliferation. In accordance with Unek et al. [1] in placentas with Intrauterine Growth Restriction, we observed that BrdU expression was very strong during the early days of pregnancy but gradually decreased over midterm and term in normal rats. Our Immunohistochemical results showed that the number of BrdU immunolabeled cells gradually increased from day 12 to 17, being the highest on day 17 and gradually decreasing on day 21, for placental removal during delivery. For S group, the immunostaining pattern was very similar to that of C group. However, the number of BrdU immunolabeled cells in placentas of the S group was higher than in C group placentas on all days, which are in agreement with the results of Acar et al. [19].

On the other hand, statistical analysis about studied groups revealed significant differences between groups in which cell proliferation was studied, but no significant differences were observed between groups in which apoptosis was studied. However, during exposure to a stressor when the hypothalamus-pituitary-adrenal and the sympatho-adrenal axis are activated, individuals may respond differently to an identical stressful stimulus [15]. Normally, placental tissue works as a buffer organ to the effects produced by the stress applied and it has the ability to adapt to different environmental conditions. Therefore,

no significant differences in apoptosis between groups were observed. However, the cell proliferation process was affected by stressful stimulus, probably due to the effects of increased glucocorticoids during abnormal pregnancies [14].

Since the action of glucocorticoids on homeostasis is widespread, affecting most of the tissues, as well as the placenta, one can speculate that the chronic stress applied to mothers can generate a deleterious environment for the fetus development.

The molecular mechanisms, by which glucocorticoids alter cell proliferation in stressed rat placentas, are not yet known [36-38].

In conclusion, chronic stress by immobilization did not produce effects on apoptotic process. However it produces an increase in cellular proliferation index in the three gestation days analyzed, which could generate a deleterious environment for the fetus development.

References

1. Unek G, Ozmen A, Kipmen-Korgun D, Korgun ET (2012) Immunolocalization of PCNA, Ki67, p27 and p57 in normal and dexamethasone-induced intrauterine growth restriction placental development in rat. *Acta Histochem* 114: 31-40.
2. Soares MJ, Chapman BM, Rasmussen CA, Dai G, Kamei T, et al. (1996) Differentiation of trophoblast endocrine cells. *Placenta* 17: 277-289.
3. Acevedo Gallegos S, Espino y Sosa S, Gallardo Gaona J, Velázquez Torres B, Camargo Martin L, et al. (2008) La placenta humana: Revisión. *Perinatol Reprod Human* 22: 230-245.
4. Burdon C, Mann C, Cindrova-Davies T, Ferguson-Smith AC, Burton GJ (2007) Oxidative stress and the induction of cyclooxygenase enzyme and apoptosis in the murine placenta. *Placenta* 13: 724-733.
5. Ain R, Canham LN, Soares MJ (2003) Gestation stage-dependent intrauterine trophoblast cell invasion in the rat and mouse novel endocrine phenotype and regulation. *Dev Biol* 260: 176-190.
6. Davies J, Glasser SR (1968) Histological and fine structural observations on the placenta of the rat. *Acta Anat (Basel)* 69: 542-608.
7. Georgiades P, Ferguson-Smith AC, Burton GJ. (2002) Comparative developmental anatomy of the murine and human definitive placentae. *Placenta* 23: 3-19.
8. Pijnenborg R, Vercruyse L (2006) Mathias Duval on placental development in mice and rats. *Placenta* 27: 109-118.
9. Martí O, Armario A (1998) Anterior pituitary response to stress: time-related changes and adaptation. *Int J Dev Neurosci* 16: 241-260.
10. Kant GJ, Leu JR, Anderson SM, Mougey EH (1987) Effects of chronic stress on plasma corticosterone, ACTH and prolactin. *Physiol Behav* 40: 775-779.
11. Martí O, Andrés R, Armario A (1999) Defective ACTH response to stress in previously stressed rats: dependence on glucocorticoid status. *Am J Physiol* 277: R869-77.
12. Shulkin J (1999) Corticotropin-releasing-hormone signals adversity in both the placenta and the brain; regulation by glucocorticoids and allostatic overload. *J Endocrinol* 161: 349-356.
13. Vigas M, Usdin E, Kventdanský R, Kopin I (1980) Contribution to the understanding of the stress: recent advance. Elsevier North 573-583.
14. Inder WJ, Prickett TC, Ellis MJ, Hull L, Reid R, et al. (2001) The utility of plasma CRH as a predictor of preterm delivery. *J Clin Endocrinol Metab* 86: 5706-5710.
15. Mulder E.J, Robles de Medina PG, Huizink AC, Van den Bergh BR, Buitelaar JK, et al. (2002) Prenatal maternal stress: effects on pregnancy and the (unborn) child. *Early Hum Dev* 70: 3-14.
16. Mayer N, Greco C, Bertuzzi M, Rodríguez N, Vivas A, et al. (2011) Immobilization stress responses in adult rats exposed in utero to immobilization. *Stress and health* 27: 1-10.
17. Weinstock M (2005) Alterations induced by gestational stress in brain and behavior of the offspring. *Prog Neurol* 85: 427-451.
18. Rodríguez N, Mayer N, Gauna HF (2007) Effects of prenatal stress on male offspring sexual maturity. *Biocell* 31: 67-74.
19. Acar N, Korgun ET, Cayli S, Sahin Z, Demir R, et al. (2008) Is there a relationship between PCNA expression and diabetic placental development during pregnancy? *Acta Histochem* 110: 408-417.
20. Burton P, Waddell BJ (1999) Dual function of 11-B hydroxysteroid dehydrogenase in placenta: modulating placenta glucocorticoids passage and local steroid action. *Biol Reprod* 60: 234-240.
21. Chan CC, Lao TT, Cheung AN (1999) Apoptotic and proliferative activities in first trimester placentae. *Placenta* 20: 223-227.
22. Degterev A, Boyce M, Yuan J (2003) A decade of caspases. *Oncogene* 22: 8543-8567.
23. Meresmann G, Olivares C, Vighi S, Alfie M, Irigoyen M, et al. (2010) Apoptosis is increased and cell proliferation is decreased in out-of-phase endometria from infertile and recurrent abortion patients. *Reprod Biol Endocrinol* 8: 126.
24. Roa J (2003) Marcadores moleculares: proliferación e inestabilidad microsatelital. *Gastr Latinoam* 3: 195-199.
25. Angosto M (2003) Bases moleculares de la apoptosis. *Anal Real Nat Farm* 69: 36-64.
26. Austgulen R, Chedwick L, Vogt Isaksen C, Vatten L, Craven C (2002) Trophoblast apoptosis in human placenta at term as detected by expression of a cytokeratin 18 degradation product of caspase. *Arch Pathol Lab Med* 126: 1480-1486.
27. Barrio E, Calvo MT, Romo A, Alvarez R, Gutierrez JI, et al. (2003) Crecimiento intrauterino restringido: estudio de la apoptosis en la placenta. *An Pediatr* 58: 51-54.
28. Mu J, Kanzaki T, Si X, Tomimatsu T, Fukuda H, et al. (2003) Apoptosis and related proteins in placenta of intrauterine fetal death in prostaglandin f receptor-deficient mice. *Biol Reprod* 68: 1968-1974.
29. Straszewski-Chavez SL, Abrahams VM, Mor G (2005) The role of apoptosis in the regulation of trophoblast survival and differentiation during pregnancy. *Endocr Rev* 26: 877-897.
30. Waddell BJ, Hisheh S, Dharmarajan AM, Burton PJ (2000) Apoptosis in rat placenta is zone-dependent and stimulated by glucocorticoids. *Biol Reprod* 63: 1913-1917.
31. De Falco M, Fedele V, Cobellis L, Mastrogiacomo A, Leone S, et al. (2004) Immunohistochemical distribution of proteins belonging to the receptor-mediated and the mitochondrial apoptotic pathways in human placenta during gestation. *Cell Tissue Res* 318: 599-608.
32. Gavrieli Y, Sherman Y, Ben-Sasson SA (1992) Identification of programmed cell death *in situ* via specific labeling of nuclear DNA fragmentation. *J Cell Biol* 119: 493-501.
33. Muskhelishvili L, Latendresse JR, Kodell RL, Henderson EB (2003) Evaluation of cell proliferation in rat tissues with BrdU, PCNA, Ki-67(MIB-5) immunohistochemistry and *in situ* hybridization for histone mRNA. *J Histochem Cytochem* 51: 1681-1688.
34. Rahrant S, Garavito Z, Hurtado H (2000) Técnica inmunocitoquímica para evaluar la proliferación de células en cultivo por la incorporación de bromodeoxiuridina. *Bioméd* 20: 144-150.
35. Bullock G, Petrusz P (1983) Techniques in immunocytochemistry. Academy Press, London. VI, II and III.
36. Zou H, Li Y, Liu X, Wang X (1999) An APAF-1-cytochrome c multimeric complex is a functional apoptosome that activates procaspase-9. *J Biol Chem* 274: 11549-11556.
37. Rodríguez N, Mayer N, Gauna HF (2007) Effects of prenatal stress on male offspring sexual maturity. *Biocell* 31: 67-74.
38. Russel WM, Burch RL (1959) The principles of human experimental technique. London: Methuen. 238.