

## ORIGINAL PAPER

# Structure and evolution of the sexually dimorphic integumentary swelling on the hands of dendrobatid poison frogs and their relatives (Amphibia: Anura: Dendrobatoidea)

Isabela Rodrigues de Souza Cavalcanti<sup>1</sup>  | María Celeste Luna<sup>2</sup>  | Julián Faivovich<sup>2,3</sup>  | Taran Grant<sup>1</sup> 

<sup>1</sup>Department of Zoology, Institute of Biosciences, University of São Paulo, São Paulo, Brazil

<sup>2</sup>División Herpetología, Museo Argentino de Ciencias Naturales 'Bernardino Rivadavia' - CONICET, Buenos Aires, Argentina

<sup>3</sup>Departamento de Biodiversidad y Biología Experimental, Facultad de Ciencias Exactas y Naturales, Universidad de Buenos Aires, Buenos Aires, Argentina

## Correspondence

Taran Grant, Department of Zoology, Institute of Biosciences, University of São Paulo, São Paulo, Brazil.  
Email: taran.grant@ib.usp.br

## Funding information

Agencia Nacional de Promoción Científica y Tecnológica, Grant/Award Number: PICT 2381-2015, PICT 2519-2019, PICT 3349-2018, PICT 346-2019 and PICT 820-2015; Coordenação de Aperfeiçoamento de Pessoal de Nível Superior, Grant/Award Number: 001; Agencia Nacional de Promoción Científica y Tecnológica, Grant/Award Number: PICT 2381-2015 and PICT 820-2015; Fundação de Amparo à Pesquisa do Estado de São Paulo, Grant/Award Number: 2012/10000-5, 2015/21007-9 and 2018/15425-0; Conselho Nacional de Desenvolvimento Científico e Tecnológico, Grant/Award Number: 130046/2018-3 and 306823/2017-9

## Abstract

The hands of adult males of many dendrobatid poison frogs and their relatives possess swelling formed by glandular tissue hypothesized to secrete courtship pheromones delivered to the female during cephalic amplexus. Variation in the occurrence and external morphology of the swelling of finger IV has provided important evidence for dendrobatoid systematics for decades, but its underlying structure has not been investigated. We undertook a detailed comparative analysis of the integument of the hand, including both external morphology and histology, of 36 species representing the diversity of dendrobatoid frogs and several close relatives. The swelling is caused by four densely packed, hypertrophic, morpho-histochemical types of specialized mucous glands (SMGs). We observed type I SMGs on fingers II–V and the wrist, including areas that are not swollen, types II and IV exclusively on finger IV, and type III on finger IV and the wrist. Type I SMGs occur either in isolation or together with types II, III, or IV; types II, III, and IV never occur together or without type I. We delimited 15 characters to account for the variation in external morphology and the occurrence of SMGs. Our data suggest that type I SMGs are a new synapomorphy for Dendrobatoidea and that type II SMGs originated in either the most recent common ancestor (MRCA) of Dendrobatidae or independently in the MRCAs of Aromobatidae and Colostethinae, respectively, while types III and IV are restricted to *Anomaloglossus*. The discovery of these SMGs adds a new dimension to studies of poison frog reproductive biology, which have investigated acoustic, visual, and tactile cues in courtship, mating, and parental care across the diversity of Dendrobatoidea for decades but have almost entirely overlooked the possible role of chemical cues.

## 1 | INTRODUCTION

Amphibian skin is a complex organ that plays a fundamental role in maintaining homeostasis by regulating water, salt, and respiratory gas

exchange and functions as an interface between the internal and external environments (Brizzi et al., 2001,2002,2003; Fox, 1986; Noble, 1931). Additionally, molecules secreted through the skin provide defense against predators and pathogens and enable communication with conspecifics

This is an open access article under the terms of the Creative Commons Attribution-NonCommercial License, which permits use, distribution and reproduction in any medium, provided the original work is properly cited and is not used for commercial purposes.

© 2021 The Authors. Journal of Anatomy published by John Wiley & Sons Ltd on behalf of Anatomical Society.

(Brizzi et al., 2003; Brunetti et al., 2012; Erspamer, 1994; Noble, 1931). These molecules are produced by morphologically and functionally diverse dermal exocrine glands arranged in four main types, all comprising a duct, an intercalary region, a secretory portion, and a myoepithelial sheath: lipid (or wax), mixed (or seromucous), serous (granular or poisonous), and mucous (Brizzi et al., 2002; Brunetti et al., 2012; Toledo & Jared, 1995).

Although multiple gland types with variable functions can be found in some species (Noble, 1931; Toledo & Jared, 1995; Brizzi et al., 2001, 2002; 2003), serous and mucous glands are ubiquitous (Noble, 1931; Toledo & Jared, 1995). Serous glands are syncytial with an alveolus filled with granules (Mills & Prum, 1984; Toledo & Jared, 1995). In contrast, mucous glands are usually smaller and more numerous than serous glands and are formed by a cuboidal or columnar epithelium and lumen. Mucous and serous glands are classified as ordinary or specialized according to their morphology, topography, histochemistry, and function (Brizzi et al., 2002). Ordinary glands are anatomically widespread, whereas specialized glands are topographically restricted and play specific roles in defense, communication, and/or reproduction (Brizzi et al., 2003; Brunetti et al., 2012, 2015). Hence, specialized glands are a secondary sexual character commonly found in anurans (Duellman & Trueb, 1986; Noble, 1931).

Sexually dimorphic skin glands (SDSGs) occur in different regions of the male (Brizzi et al., 2001; Duellman & Trueb, 1986; Noble, 1931) and can either appear or become more prominent during reproduction due to gonadotropic hormones (Brizzi et al., 2003; Fujikura et al., 1988; Rastogi, 1976; Rastogi et al., 1986; Thomas et al., 1993) or persist throughout adult life. Morphological and histochemical studies have shown that SDSGs can be mucous (specialized mucous glands, SMGs; Brizzi et al., 2003; Brunetti et al., 2012; Thomas et al., 1993) or serous (specialized serous glands, SSGs; Brunetti et al., 2012). Both gland types can be hypertrophic and densely packed into clusters that form integumentary protrusions or expansions, usually referred to as swollen regions or macroglands (Thomas et al., 1993; Toledo and Jared, 2005; Brizzi et al., 2001, 2003).

For a century, it has been known that finger IV (*sensu* Fabrezi & Alberch, 1996) is "swollen" in adult males of many species of Dendrobatoidea (Dunn, 1924). The swelling is formed by glandular tissue usually extending along the dorsal and preaxial (medial) integument of the finger (Grant et al., 2006, 2017). The swelling has also been reported to extend proximad from finger IV onto the wrist in some species (Grant et al., 2006) and to occur on both finger IV and finger III in one species (Grant & Rodríguez, 2001). Intraspecific variation observed in large samples of adult males suggests that the swelling is either restricted to or at least more prominent in reproductively active males (e.g., Grant et al., 2006; Myers et al., 1991; Simões, 2016).

The swelling appears to be involved in cephalic amplexus, an uncommon form of amplexus shared by most dendrobatoids and possibly a synapomorphy of the clade (Carvajal-Castro et al., 2020; but see Grant et al., 2006). In cephalic amplexus, the male mounts and loosely embraces the female, bringing the dorsal surfaces of his hand, including the swollen area(s), into contact with the female's loreal region, lips, snout, and lateral portion of the throat (Figure 1), presumably delivering courtship pheromones secreted by the glandular tissue (Grant et al., 2017).

The occurrence and external morphology of the swelling on finger IV have played an important role in dendrobatoid systematics for



**FIGURE 1** *Ameerega parvula* in cephalic amplexus. Note the male's loose grip on the female, with the dorsal surfaces of the hands touching the female's snout, loreal region, lips, and lateral throat. Photo used with permission from Luis A. Coloma

decades (see review by Grant et al., 2006). The swollen finger IV character is unique to Dendrobatoidea, and Grant et al. (2017) reported it to occur in at least some species of 10 genera, including *Ameerega*, *Colostethus*, *Epipedobates*, *Leucostethus*, *Silverstoneia* (Colostethinae), *Hyloxalus* (Hyloxalinae), and the "*Colostethus*" *ruthveni* group (to be described as a new genus; Dendrobatinae) in Dendrobatidae and *Anomaloglossus* (Anomaloglossinae), *Allobates* (Allobatinae), and *Aromobates* (Aromobatinae) in Aromobatidae. Grant et al. (2017) also reported a complex evolutionary history of independent gains and losses, indicating that the swelling is not homologous in all lineages while also suggesting that this scenario might be clarified by improved hypotheses of homology. Grant et al. (2017: S66) concluded their analysis of the evolution of the swollen finger IV by speculating that "histology of the fingers of species that appear to lack swelling on the basis of external morphology might reveal the presence of the same nuptial glands that are conspicuously enlarged in other species [and] that at least some of the independent origins of this swelling will be found to involve histologically distinct structures."

In the present study, we undertook a detailed comparative analysis of the integument of the hand, including both external morphology and histology, of a diverse sample of dendrobatoid frogs in order to (1) identify and characterize the glands that comprise the swelling, (2) assess the anatomical and taxonomic distribution of the glands, (3) evaluate individual and sexual variation, and (4) analyze the evolutionary history of the characters related to the swollen finger IV.

## 2 | MATERIALS AND METHODS

### 2.1 | Terminology

We followed Fabrezi and Alberch (1996) in considering finger I of other tetrapods to be absent in anurans and number the remaining four fingers accordingly (i.e., fingers II–V). We adopted the

terminology of Toledo and Jared (1995) for serous and mucous glands and Brizzi et al. (2003) to distinguish between common and specialized glands. We also employed the terminology of Brunetti et al. (2012) for SDSGs. As noted below (see Character evolution), we employed the phylogenetic hypothesis and taxonomy of Grant et al. (2017) to analyze character evolution. Nevertheless, Marin et al. (2018) restricted *Colostethus* to the *C. latinasus* group of Grant et al. (2017) and transferred all *C. fraterdanieli* group species to *Leucostethus*, and we followed their taxonomic proposal.

## 2.2 | Specimens examined

No new specimens were collected for this study. Although details of the preservation history of each specimen are not known, to our knowledge all were fixed in 10% formalin and stored in 65–70% ethanol, following standard practices (McDiarmid, 1994). Institutional collection abbreviations for voucher specimens are CPZ-UV (Colección de Prácticas Zoológicas, Universidad del Valle, Cali, Colombia), KU (University of Kansas Biodiversity Institute, Lawrence, USA), MZUSP (Museu de Zoologia da Universidade de São Paulo, São Paulo, Brazil), and UMAG (Centro de Colecciones Biológicas, Universidad del Magdalena, Santa Marta, Colombia). Specimens not yet deposited in a permanent institutional collection are identified by their field numbers (MAR, Marco A. Rada). Localities and voucher numbers of all specimens examined are listed in Appendix S1, with information on sex and maturity included in Tables S1 and S2.

In addition to scoring the occurrence of swelling on finger IV, Grant et al. (2006) delimited four character states to account for its external morphological variation, including (1) pre- and postaxial swelling, (2) weak preaxial swelling, (3) strong preaxial swelling, and (4) swelling extending from the wrist, mainly on the preaxial side of the digit. We selected species representing these morphologies, as well as related species reported to lack swelling, from across the phylogeny of Dendrobatoidea (Grant et al., 2017). We also included both males and females of 25 species to confirm sexual dimorphism and, when available, multiple individuals (multiple males of 10 species, multiple females of 2 species) to evaluate individual variation and juveniles (4 species) to confirm absence of specialized glands prior to maturity. In total, we studied 77 specimens representing 36 species of 12 of the 21 recognized dendrobatoid genera (*Allobates*, *Ameerega*, *Andinobates*, *Anomaloglossus*, *Aromobates*, *Colostethus*, *Epipedobates*, *Hyloxalus*, *Leucostethus*, *Mannophryne*, *Phyllobates*, and *Silverstoneia*; Grant et al., 2017; Marin et al., 2018), as well as the “*Colostethus*” *ruthveni* group (Appendix S1). Among the nine genera not sampled (*Adelphobates*, *Dendrobates*, *Ectopoglossus*, *Excidobates*, *Minyobates*, *Oophaga*, *Paruwrobates*, *Ranitomeya*, or *Rheobates*), no species is known to possess swelling. We also studied four specimens of the non-dendrobatoid species *Crossodactylus grandis*, *Hylodes nasus*, and *Hylodes phyllodes* (Hylodidae) and obtained information from the literature on *Melanophryniscus cambaraensis* and *M. macrogranulosus* (Bufonidae; Jeckel et al., 2019).

## 2.3 | External morphology

Although the swelling is confined to finger IV in most species, it has also been reported to extend onto the wrist and occur on finger III (Grant et al., 2006; Grant & Rodríguez, 2001). Consequently, we examined whole hands and individual fingers in dorsal, palmar, and preaxial (medial) views using a Zeiss Discovery V12 Stereomicroscope equipped with an AxioCam ICc 5 digital camera.

## 2.4 | Histology

For histological analysis, we dissected one hand (usually the right one) of each specimen from the arm just proximal to the wrist. Given that the fingers were splayed in all specimens, we aligned them for sectioning by appressing and binding them using a strand of hair. Also, to distinguish between specialized glands restricted to the hand and ordinary glands distributed elsewhere on the body, we compared cutaneous glands from the hand to those in the integument of the dorsum and venter by compiling information from published accounts and obtaining new histological data on the dorsal skin of one male and one female of *Anomaloglossus stephensi*.

We transferred hands from the 70% ethanol storage solution to neutral ethylenediaminetetraacetic acid (EDTA; approximately 14% concentration) for decalcification. We then submitted the decalcified hands and dorsal skin samples to an increasing alcohol series for dehydration (Wolfe, 2019), embedded them in methacrylate glycol resin (Historesin Leica®), and cross-sectioned them at 4.5  $\mu\text{m}$ . We used toluidine blue–basic fuchsin (Junqueira, 1995) and hematoxylin–eosin (Behmer et al., 1976) to observe morphology, periodic acid–Schiff (Bancroft & Stevens, 1982) to identify neutral mucopolysaccharides, alcian blue (Pearse, 1985) to identify acid mucopolysaccharides, and naphthol yellow (Humason, 1962) and bromophenol blue (Pearse, 1985) to identify proteins. We also used Sudan black B to identify lipids (Bancroft & Stevens, 1982). We examined and photographed stained sections using a Nikon Eclipse 80i Light Microscope equipped with a Nikon DS-Ri1 camera.

## 2.5 | Character evolution

We delimited transformation series following the character concept of Grant and Kluge (2004) and using the characters of Grant et al. (2006, 2017) as a starting point. Given the causal relationship between external morphology and the underlying histology, in the absence of evidence of transformational independence we treated variation in each as different properties of the same transformation series. Also, because secondary sexual characters are expected to vary intraspecifically with sexual activity, we coded these characters as “any instance” (cf. Campbell & Frost, 1993), treating the greatest expression of each transformation series as evidence that all equivalent conspecific semaphoronts express that state.

We tested the hypothesized homology and evolutionary history of character-states by constructing a character matrix in Mesquite v. 3.61 (Maddison & Maddison, 2019) and optimizing the characters on the topology of Grant et al. (2017) under Fitch optimization (Fitch, 1971) using Mesquite and YBYRÁ (Machado, 2015) and TNT v.1.5 (Goloboff & Catalano, 2016) to identify and plot synapomorphies. Ideally, analysis of character evolution should be based on the most comprehensive phylogenetic hypothesis available; however, because histological data are available only for the species examined in this study, character optimization would provide little insight into their evolution due to the extensive missing data. As such, we optimized the transformation series on the phylogeny of Grant et al. (2017) pruned to include only the species for which histological data are available.

Similarly, although we scored characters for 41 species (36 ingroup, 5 outgroup), we excluded *Allobates* sp. Caxiuanã (an apparently undescribed species from Caxiuanã Bay, Pará, Brazil), *Anomaloglossus tepequem*, *Colostethus mertensi*, and *Leucostethus* sp. cf. *fraterdanieli* El Tambo (an apparently undescribed species from El Tambo, Cauca, Colombia) from the analysis of character evolution because they have not been included in any phylogenetic analysis to date and their placement among analyzed congeners is unknown, and we excluded *Silverstoneia nubicola* from both the character matrix and analysis of character evolution because the only specimen we examined histologically is female. *Andinobates daleswansonii*, *Aromobates haydeae*, and *Aromobates mayorgai* have not been included in any published phylogenetic analysis to date, but we included them in the pruned topology because they are the only species of these genera that we examined, making their placement in the topology trivial. Santos et al. (2014) identified specimens of the Peruvian populations of *Hyloxalus nexipus* that we included from Peru as *H.* aff. *nexipus*, suggesting that they are not conspecific with the nominal population from Ecuador; nevertheless, Grant et al. (2017) found these specimens and *H. nexipus* sensu stricto to form a polytomy, so we follow Coloma (1995) in referring to them under that name until their taxonomy is clarified. Although our explicit outgroup sampling was highly limited, this has no bearing on our results because no outgroup species is known to possess either the same swelling or SMGs (but see Discussion for comments on SMG homology).

We scored logically dependent characters in hierarchical character systems as inapplicable for taxa lacking the primary character (e.g., the anatomical distribution of a gland, which depends on the occurrence of that gland in the species). To avoid artifacts caused by inapplicable states in the inference of ancestral states, we visualized optimizations by treating inapplicability as a character state (i.e., absence coding; Strong & Lipscomb, 1999). This approach is inappropriate for phylogenetic analysis, as it treats transformations between “inapplicable” and other states as evolutionary events, leading to incorrect tree lengths that can affect the choice of optimal topologies (Strong & Lipscomb, 1999), but in the context of a pre-specified topology it allows the evolution of dependent characters to be unraveled. We do not illustrate or interpret transformations between “inapplicable” and other states.

## 3 | RESULTS

### 3.1 | External morphology

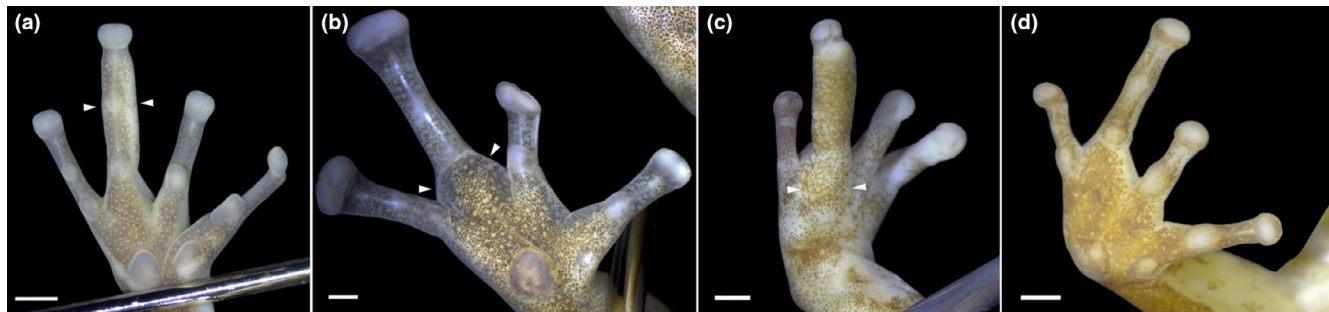
Our observations corroborated previous morphological descriptions and character state delimitations (Grant et al., 2006) and also revealed the condition of swelling restricted to the base of finger IV, not extending past the proximal subarticular tubercle, in male *Hyloxalus anthracinus* and *H. nexipus* (Figure 2, Figures S1–S5). Our observations also corroborated previous reports (see Grant et al., 2006: 68) of variation in the degree of swelling among conspecific adult males, but swelling was detected in all specimens of species in which swelling is present, even in those with the weakest swelling. When present, swelling occurs along the dorsal surface of finger IV (and other fingers in some species; see below), resulting in a dorsally expanded digit, and is usually most easily observed on the preaxial and, less often, postaxial surfaces. We did not observe swelling on the palmar (ventral) surfaces of the fingers or hand.

Our observations also corroborated the extension of swelling onto the dorsal surface of the hand in *Anomaloglossus stepheni* (Figure S14). Similarly, the same type of swelling found on finger IV also occurs on finger III in *Allobates* sp. Caxiuanã and *Colostethus mertensi* and all fingers in *H. jacobuspetersi* (Figures S4, S18, S26). We did not observe swelling of finger III in our sample of *Allobates trilineatus*, although Grant and Rodríguez (2001) observed this in some individuals of three populations. All fingers appear to be subtly thicker in juveniles than adults of both sexes (Figure S7), but this is due to the overall shape and size of digits and not the occurrence of integumentary swelling.

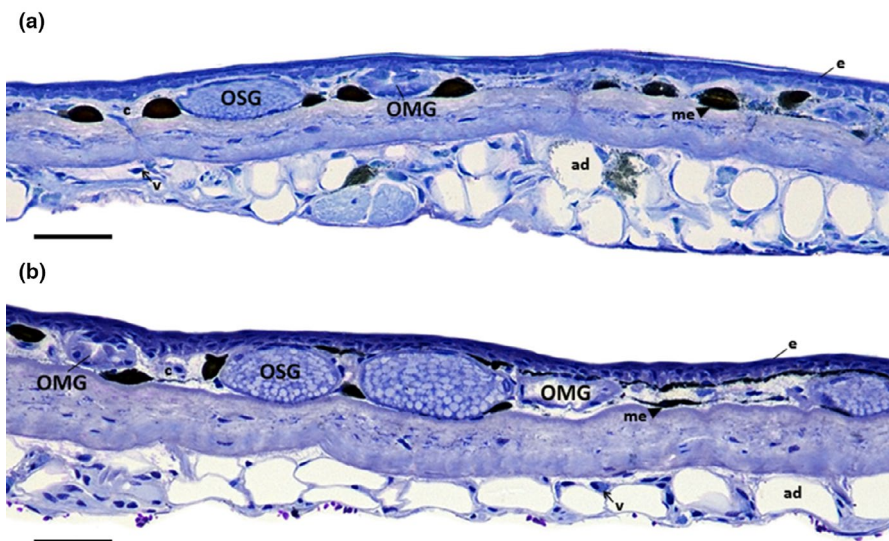
Among taxa reported to lack swelling, we confirmed its absence in *Andinobates daleswansonii*, *Hyloxalus pulchellus*, *Mannophryne olmoneae*, and *Phylllobates vittatus* (Figures S11, S28, S32, S33). However, we observed swelling in *Allobates talamancae* (Figure S5), *A. tapajos* (Figure S6), *Hyloxalus anthracinus* (Figure S25), *H. nexipus* (Figure S27), and *Leucostethus siapida* (Figure S31), all of which had been reported to lack swelling (Coloma, 1995; Dunn, 1924; Edwards, 1971; Frost, 1986; Grant et al., 2006, 2017; Lima et al., 2015; Savage, 1968).

### 3.2 | Dorsum and venter integument histology

We observed no relevant differences in the dorsal integument of male and female *Anomaloglossus stepheni* (Figure 3) or between the dorsal integument of *A. stepheni* and the ventral integument of *Ectopoglossus saxatilis* and *Hyloxalus faciopunctulatus* (Grant et al., 2017). The dorsal integument is composed of an epidermis of 2–3 cell layers and a dermis composed of *stratum spongiosum* and *stratum compactum* separated by a diffuse Eberth-Katschenko layer. The epidermis is thinner above glands than elsewhere. The *stratum spongiosum* contains ordinary mucous and serous glands and blood vessels immersed in loose collagen fibers. Melanophores also occur in the *stratum spongiosum* and can be superficial or deep relative to the glands. The *stratum compactum* comprises a layer of dense collagen fibers that is approximately the same thickness as the *stratum spongiosum*. Immediately beneath the *stratum*



**FIGURE 2** Variation in the occurrence and location of swelling on finger IV and adjacent wrist. (a) Phalangeal swelling (*Leucostethus* cf. *fraterdanieli* Villamaria, adult male; KU 133256). (b) Basal swelling (*Hyloxalus nexipus*, adult male, KU 211827). (c) Metacarpal swelling (*Anomaloglossus stepheni*, adult male, MZUSP 67858). (d) Absence of swelling (*Anomaloglossus stepheni*, adult female, MZUSP 67844). Arrowheads indicate regions where swelling occurs. Scale bars = 500  $\mu\text{m}$



**FIGURE 3** Dorsal integument and tightly bound underlying layer of adipose tissue of *Anomaloglossus stepheni* (a) adult male (MZUSP 67858) and (b) adult female (MZUSP 67844). Labels: ad, adipose cells; c, collagen fibers; e, epidermis; me, melanophore; OMG, ordinary mucous gland; OSG, ordinary serous gland; v, blood vessel. Stain: toluidine blue–basic fuchsine. Scale bars = 100  $\mu\text{m}$

*compactum* is a layer of variable thickness comprising loose collagen fibers, muscle fibers, melanophores, blood vessels, and abundant adipose cells approximately the same size as the overlying glands.

All observed glands comprise a duct, an intercalary region, and a secretory portion. The short, unbranched duct is composed of a bilayer of flat cells that are keratinized near the exterior opening and invaginate towards the secretory portion. The intercalary region connects the duct to the secretory portion and is a bilayer of cubic cells without granules in their cytoplasm. We observed the same duct and intercalary region morphologies in all gland types, but the secretory portion is variable.

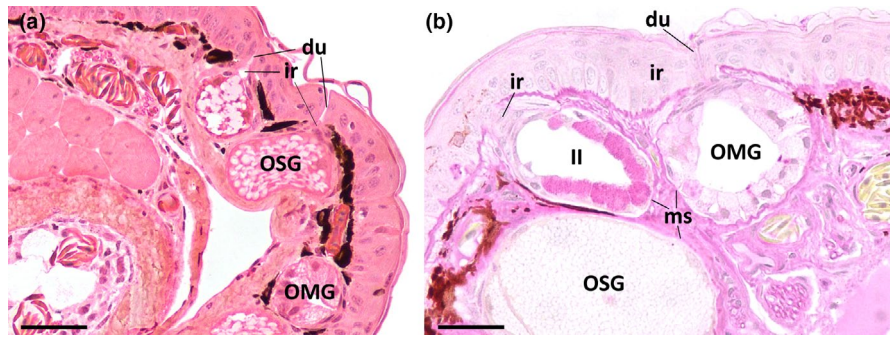
The secretory portion of ordinary serous glands (OSGs) is alveolar, syncytial, and enveloped by a continuous, contractile, myoepithelial sheath (Figures 3, 4a). OSGs are apocrine. Cellular nuclei are mostly round and the gland interior is filled with granules. The content of OSGs varies in terms of granule morphology, but gland histochemistry is uniform, regardless of granule appearance. Histochemistry revealed the presence of neutral mucopolysaccharides, absence of acid mucopolysaccharides, and variable occurrence of proteins (Table 1).

**TABLE 1** Histochemistry of ordinary serous glands (OSG) and ordinary mucous glands (OMG) in dorsal skin of *Anomaloglossus stepheni*

Glands	PAS	AB	NY/BB
OSG	+	-	-/+
OMG	++	-/+	-/+

The strength of histochemical reactions is scored as negative (-), weakly positive (+), positive (++), or variably negative and positive (-/+) to periodic acid–Schiff (PAS) for neutral mucopolysaccharides, alcian blue (AB) for acid mucopolysaccharides, and naphthol yellow (NY) and bromophenol blue (BB) for proteins.

The secretory portion of ordinary mucous glands (OMGs) is alveolar with a broad, empty, lumen composed of a monolayer of cubic cells and enveloped by a discontinuous, contractile, myoepithelial sheath (Figures 3, 4b), and is smaller than that of OSGs (Figure 3). OMGs are merocrine. Cellular nuclei are round and mostly basal. Histochemistry revealed the presence of neutral



**FIGURE 4** Ordinary serous and mucous glands in finger IV. (a) *Ameerega hahneli* (male, MZUSP 159219, hematoxylin-eosin). (b) *Colostethus mertensi* (male, KU 139620, periodic acid-Schiff, naphthol yellow, hematoxylin). Labels: du, duct; ir, intercalary region; ms, myoepithelial sheath; OMG, ordinary mucous gland; OSG, ordinary serous gland; II, type II specialized mucous gland. Scale bars = 50  $\mu$ m

mucopolysaccharides and variation in the occurrence of proteins and acid mucopolysaccharides (Table 1). The epithelium of the secretory portion of the OMGs varies in thickness among glands of the same species, presumably in relation to gland maturity (Brizzi et al., 2003).

### 3.3 | Finger and wrist integument histology

The integument of the fingers and wrist comprises an epidermis of 3–5 cell layers and dermis composed of a conspicuous *stratum spongiosum* and greatly reduced *stratum compactum* (Figures S36–S73). Melanophores are abundant in the dermis and either clumped in specific regions, usually above the glands but sometimes below them, or distributed in a continuous layer immediately beneath the epidermis (Figure S74). Vascularization is greater near glands and in the pre- and postaxial regions of all fingers.

The OSGs and OMGs of all specimens have the same characteristics as those of the dorsum and venter (see above), with the exception that they are larger in the fingers. OSGs are absent from the palmar (ventral) integument but present in the dorsal, preaxial, and postaxial regions of the fingers of all specimens, their distribution being the same in regions with and without swelling. In contrast, OMGs occur in the integument on all sides of the finger, including the palmar side, but in regions of swelling they are distributed predominantly in the palmar integument and are less abundant than other glands. Adult females (and juveniles) have more OMGs than OSGs, while adult males have a similar quantity of both types of glands (e.g., OMG:SMG ratio in *Aromobates haydeeeae* female  $\approx$  5:1, male  $\approx$  1:1).

In addition to OSGs and OMGs, we observed four types of specialized mucous glands (SMGs; Figure 5; Table 2) exclusively in adult males of species that exhibited swelling of finger IV. The SMGs differ from OMGs in the morphology and size of their secretory portion, being conspicuously larger than OMGs and are absent from the palmar integument. The SMGs are usually densely packed, almost to the exclusion of both OMGs and OSGs, to form the swollen macroglands. Like OMGs, the SMGs appear to be merocrine. We

characterize the four SMG types below and illustrate intra- and interspecific variation in supporting information (Figures S36–S73).

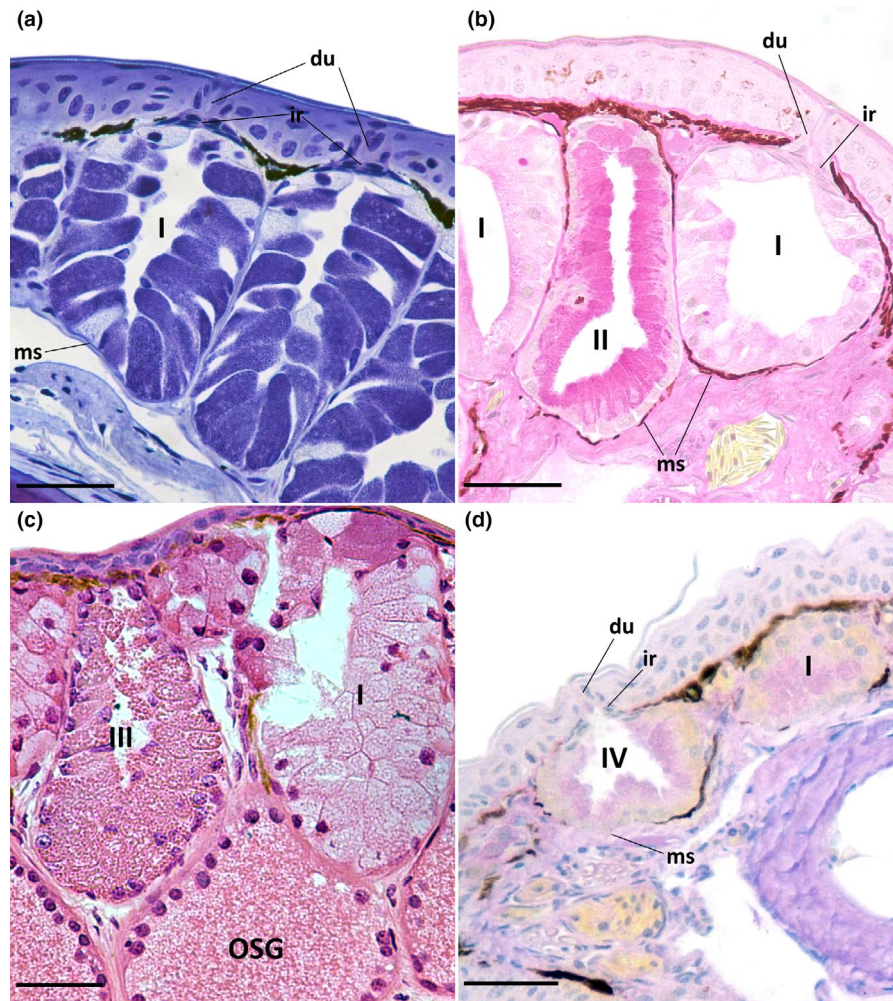
#### 3.3.1 | Type I SMGs

Type I SMGs are characterized by a secretory portion that is alveolar (both alveolar and tubular in *Anomaloglossus stephensi* and *Colostethus panamansis*) with a small, empty lumen formed by a monolayer of cubic or columnar cells filled with granules and enveloped by a discontinuous, contractile, myoepithelial sheath (Figure 5a, Figure S75). Cellular nuclei are round and mostly basal. Histochemistry revealed the presence of neutral mucopolysaccharides and proteins in all type I SMGs and absence of acid mucopolysaccharides in most species (present in only four species; Table 3, Table S2). Cells of the secretory epithelium of a single type I SMG can vary in stain intensity (Figure 6), and a given cell can be positive for more than one stain (Table 3, Table S2), indicating that type I SMGs produce mixed secretions.

Type I SMGs occur in the swollen regions of all species, although they are largest in finger IV even when swelling also occurs in other areas. Type I SMGs also occur in the dorsal region of other fingers (usually present in *Allobates insperatus*, *Al. olfersioides*, *Al. talamancae*, *Al. tapajos*, *Ameerega petersi*, *Anomaloglossus apiau*, *An. kaiei*, *Aromobates haydeeeae*, *Ar. mayorgai*, *C. panamansis*, “*Colostethus*” *ruthveni*, *Epipedobates machalilla*, *Hyloxalus anthracinus*, *H. jacobuspetersi*, *H. nexipus*, *Leucostethus brachistriatus*, and *Silverstoneia erasmios*), despite the lack of externally visible swelling in those fingers. In some species, type I glands are the only type of SMG, whereas in others they co-occur with type II, type III, or type IV SMGs (Table 2). Type I SMGs are distributed adjacent to the epidermis (Figure 7).

#### 3.3.2 | Type II SMGs

Morphologically, type II SMGs differ from type I SMGs primarily in the shape of their secretory portion, which is tubular-alveolar or tear shaped. Like type I SMGs, the secretory portion of type II



**FIGURE 5** The four types of specialized mucous glands (SMGs) in finger IV of Dendrobatoidea. (a) Type I (*Colostethus panamansis*, KU 80406, toluidine blue–basic fuchsin). (b) Type II (*Colostethus mertensi*, KU 139620, periodic acid–Schiff, naphthol yellow; for naphthol yellow without periodic acid–Schiff, see Figure S55c). (c) Type III (*Anomaloglossus stepheni*, MZUSP 67858, hematoxylin–eosin). (d) Type IV (*Anomaloglossus tepequem*, MZUSP 70694, periodic acid–Schiff, naphthol yellow, hematoxylin). Labels: du, duct; ir, intercalary region; ms, myoepithelial sheath; I, type I SMG; II, type II SMG; III, type III SMG; IV, type IV SMG. Scale bars = 50  $\mu$ m

SMGs comprises a small, empty lumen formed by a monolayer of cubic or columnar cells enveloped by a discontinuous, contractile, myoepithelial sheath (Figure 5b), but the granules that fill the secretory cells are more evident than those of type I SMGs. Cellular nuclei are round and basal. Neutral mucopolysaccharides are present in all secretory cells, whereas proteins are variably present and absent and acid mucopolysaccharides are absent (Table 3). When present, both mucopolysaccharides and proteins are distributed throughout the secretory cells (Figure 5b, Figure S55c). The main histochemical difference between type I and II SMGs is the intensity of periodic acid–Schiff staining, with type I being predominantly positive and type II being predominantly strongly positive (Table S2).

Unlike type I SMGs, the taxonomic distribution of type II SMGs is restricted to Dendrobatidae, occurring in most species that exhibit swelling (Table 2). Type II SMGs are restricted to finger IV, where they are distributed throughout the swollen region and do

not extend beyond the macroglands. Within a given macrogland, type II SMGs co-occur with type I SMGs, being either interspersed with them or forming a deeper layer of secretory portions beneath the type I SMGs (Figure 7a,b); this variation in the distribution of type II SMGs within a macrogland varies among conspecific individuals.

### 3.3.3 | Type III SMGs

Type III SMGs are morphologically indistinguishable from type II SMGs, although the granules that fill their secretory cells are even more evident than those of type II (Figure 5c). In contrast, type III SMGs differ markedly in their histochemistry, which shows the presence of proteins and absence of both neutral and acid mucopolysaccharides (Table 3).

TABLE 2 Distribution of specialized mucous gland (SMG) types I-IV in adult males of the species examined in this study (0, absent; 1, present)

Family	Genus	Species	SMG I	SMG II	SMG III	SMG IV	
Aromobatidae	<i>Allobates</i>	<i>insperatus</i>	1	0	0	0	
		sp. Caxiuanã	0	0	0	0	
		<i>femoralis</i>	0	0	0	0	
		<i>olfersioides</i>	1	0	0	0	
		<i>talamancae</i>	1	0	0	0	
		<i>tapajos</i>	1	0	0	0	
		<i>trilineatus</i>	1	0	0	0	
	<i>Anomaloglossus</i>	<i>apiau</i>	1	0	0	0	
		<i>kaiei</i>	1	0	0	0	
		<i>stepheni</i>	1	0	1	0	
		<i>tepequem</i>	1	0	0	1	
	<i>Aromobates</i>	<i>haydeae</i>	1	0	0	0	
		<i>mayorgai</i>	1	0	0	0	
	<i>Mannophryne</i>	<i>olmonae</i>	0	0	0	0	
Dendrobatidae	<i>Ameerega</i>	<i>hahneli</i>	1	1	0	0	
		<i>parvula</i>	1	1	0	0	
		<i>petersi</i>	1	1	0	0	
	<i>Andinobates</i>	<i>daleswansonii</i>	0	0	0	0	
	<i>Colostethus</i>	<i>mertensi</i>	1	1	0	0	
		<i>panamansis</i>	1	1	0	0	
	" <i>Colostethus</i> "	<i>ruthveni</i>	1	0	0	0	
	<i>Epipedobates</i>	<i>anthonyi</i>	1	1	0	0	
		<i>boulengeri</i>	1	1	0	0	
		<i>machalilla</i>	1	1	0	0	
	<i>Hyloxalus</i>	<i>anthracinus</i>	1	1	0	0	
		<i>jacobuspetersi</i>	1	1	0	0	
		<i>nexipus</i>	1	1	0	0	
		<i>pulchellus</i>	0	0	0	0	
	<i>Leucostethus</i>	<i>brachistriatus</i>	1	1	0	0	
		sp. cf. <i>fraterdanieli</i> Villamaria	1	1	0	0	
		sp. cf. <i>fraterdanieli</i> ElTambo	1	1	0	0	
		<i>siapida</i>	1	0	0	0	
	<i>Phyllobates</i>	<i>vittatus</i>	0	0	0	0	
	<i>Silverstoneia</i>	<i>erasmios</i>	1	0	0	0	
		<i>flotator</i>	1	1	0	0	
	Hylodidae	<i>Crossodactylus</i>	<i>grandis</i>	0	0	0	0
			<i>Hylodes</i>	0	0	0	0
<i>phyllodes</i>		0	0	0	0		
Bufonidae	<i>Melanophryniscus</i>	<i>cambaraensis</i>	0	0	0	0	
		<i>macrogranulosus</i>	0	0	0	0	

Among the species we examined, type III SMGs occur exclusively in *Anomaloglossus stepheni*. They are distributed throughout the swelling that extends over finger IV and the wrist. They are also observed in finger III even though there is no indication of swelling on it (Figure S50). Type III SMGs co-occur with type I SMGs, forming an inner layer beneath the type I SMGs (Figure 7).

### 3.3.4 | Type IV SMGs

The secretory portion of type IV SMGs (Figure 5d) is morphologically indistinguishable from types II and III SMGs. However, type IV differs from type III in possessing both neutral mucopolysaccharides and proteins (Table 3). Although the same histochemical content was



observed in types II and IV (Table 3), proteins are present in only some type II SMGs (Table S2) but all type IV SMGs. Furthermore, proteins and neutral mucopolysaccharides are segregated in the secretory cells of type IV SMGs, with the former concentrated around the periphery of the gland and the latter adjacent to the lumen (Figure 5d), whereas both proteins and neutral mucopolysaccharides are distributed throughout the cells in type II SMGs (Figure 5b, Figure S55c).

Type IV SMGs also differ from type III SMGs in being interspersed with type I SMGs in an outer layer adjacent to the epidermis (like type II SMGs), whereas type III SMGs lie beneath the type I SMGs (Figure 7). Among the species we examined, type IV SMGs occur exclusively in *Anomaloglossus tepequem* and are restricted to the swollen area of finger IV.

### 3.4 | Character delimitation

We propose 15 characters to account for the variation in external morphology and histology of the swelling on the hand of adult males. The states scored for all 41 examined species are given in Data S1.

**TABLE 3** Summary of histochemistry of ordinary serous glands (OSGs), ordinary mucous glands (OMGs), and type I–IV specialized mucous glands (SMGs) in fingers (for detailed distribution see Table S2)

Gland	PAS	AB	NY, BB
OSG	-/+	-	-/+
OMG	-/+	-/+	-/+
SMG I	+	-/+	-/+
SMG II	+	-	-/+
SMG III	-	-	+
SMG IV	+	-	+

Histochemical reactions are scored here as negative (-), positive (+), or variably negative and positive (-/+) to periodic acid-Schiff (PAS) for neutral mucopolysaccharides, alcian blue (AB) for acid mucopolysaccharides, and naphthol yellow (NY) and bromophenol blue (BB) for proteins.

#### 3.4.1 | External morphology (characters 1–8)

1. Phalangeal swelling on finger IV of adult males: absent = 0; present = 1.

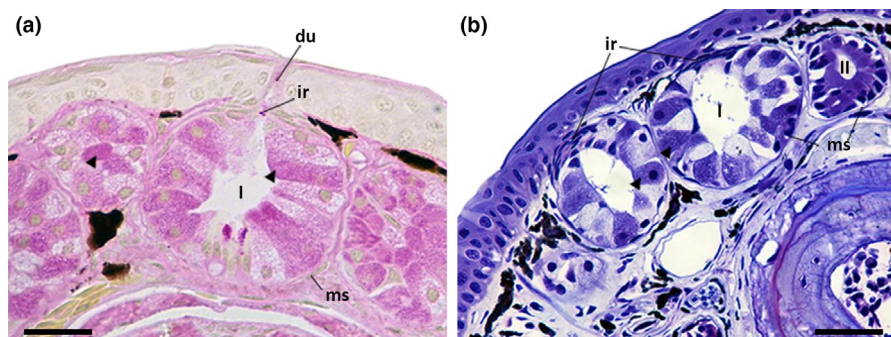
We employ the term “phalangeal swelling” in reference to the topological position of the integumentary swelling, which corresponds to the phalangeal portion of the digits. Specifically, phalangeal swelling arises in the region of the proximal subarticular tubercle (either adjacent to it or near its distal edge) and extends distad along the finger to the base of the disc (Figure 2a). It does not reach the base (i.e., metacarpal portion) of the finger. Contrary to other fingers, we did not observe type I SMGs in the absence of at least weak phalangeal swelling on finger IV, which prevented us from scoring the occurrence of swelling and type I SMGs in this region as separate characters. Future studies revealing that SMGs can occur in the absence of swelling would validate the decoupling of this variation into two characters.

2. Expansion of phalangeal swelling on finger IV of adult males: dorsal and preaxial = 0; dorsal, preaxial, and postaxial = 1.

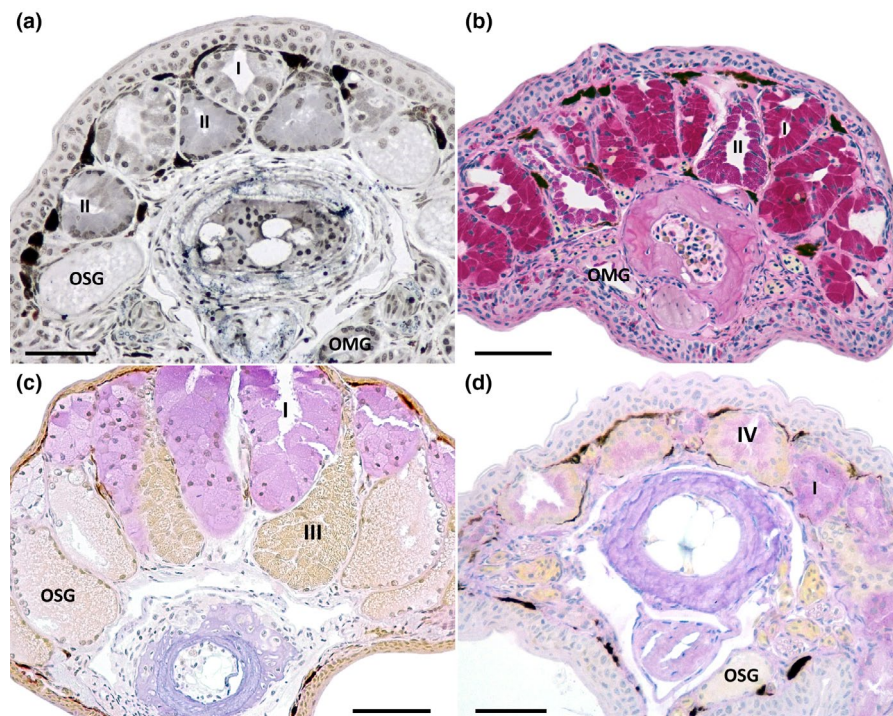
When swelling occurs, it is always present on the dorsal surface of finger IV, resulting in a dorsally expanded digit, and extends mediad to the preaxial surface of the digit, where it is most conspicuous and easily observed in palmar view (state 0). In some species, it also expands laterad to the postaxial surface (i.e., state 1).

3. Degree of preaxial phalangeal swelling on finger IV of adult males: weak = 0; strong = 1.

In palmar view, the preaxial expansion of finger IV (when present) can be weak, often detectable only by comparison with other fingers or with finger IV of females (state 0), or strong, conspicuous. Although we observed intraspecific variation in the degree of swelling, the variation in strongly swollen fingers did not overlap with the variation in weakly swollen fingers. That is, swelling was always conspicuous in adult males of species scored as state 1, although in some individuals it



**FIGURE 6** Variation in the strength of staining of secretory epithelial cells within type I SMGs. (a) *Ameerega hahneli* (MZUSP 159219, periodic acid-Schiff, naphthol yellow, hematoxylin). (b) *Ameerega petersi* (KU 172127, toluidine-basic fuchsin). Labels: du, duct; ir, intercalary region; ms, myoepithelial sheath; I, type I SMG; II, type II SMG. Arrowheads indicate strongly stained cells. Scale bars = 50  $\mu$ m



**FIGURE 7** Topological distribution of specialized mucous glands (SMGs). Type I SMGs are always distributed adjacent to the epidermis. (a) Type II SMGs distributed both beneath and interspersed among type I SMGs (*Ameerega hahneli*, MZUSP 159219, Sudan black B). (b) Type II SMGs distributed beneath the outer layer of type I SMGs (*Leucostethus brachistriatus*, CPZ-UV 4432, periodic acid-Schiff, naphthol yellow, hematoxylin). (c) Type III SMGs distributed beneath the outer layer of type I SMGs (*Anomaloglossus stephensi*, MZUSP 67858, periodic acid-Schiff, naphthol yellow, hematoxylin). (d) Type IV SMGs distributed interspersed with type I SMGs adjacent to the epidermis (*Anomaloglossus tepequem*, MZUSP 70694, periodic acid-Schiff, naphthol yellow, hematoxylin). Labels: OSG, ordinary mucous gland; I, type I SMG; II, type II SMG; III, type III SMG; IV, type IV SMG. Scale bars = 100  $\mu\text{m}$

was as wide or wider as the disc and in others it was narrower. Indeed, it is likely that more than one character state is concealed in state 1, but refining our coding to recognize additional states is hampered by individual variation, presumably related to reproductive condition.

4. Basal swelling on finger IV of adult males: absent = 0; present = 1.

Basal swelling is formed by type I SMGs and confined to the proximal segment of the finger, not extending distad past the proximal subarticular tubercle or proximad onto the dorsal surface of the hand (Figure 2b).

5. Metacarpal swelling in adult males: absent = 0; present = 1.

Metacarpal swelling extends proximad from the area adjacent to finger IV over the dorsal surface of the hand and even onto the wrist in extreme cases (Figure 2c). An alternative to our coding scheme would be to score characters 1, 4, and 5 as alternative homologous states of the same transformation series. However, that hypothesis fails the conjunction test (Patterson, 1982), given the continuous phalangeal, basal, and metacarpal swelling in *Anomaloglossus stephensi*. Similarly, their treatment as a single additive transformation series is refuted by the presence of basal swelling without either

phalangeal or metacarpal swelling and phalangeal swelling without basal or metacarpal swelling.

6. Phalangeal swelling on finger II of adult males: present = 0; absent = 1.

Although type I SMGs occur on finger II of multiple species (see below), we observed phalangeal swelling of finger II exclusively in *Hyloxalus jacobuspetersi*.

7. Phalangeal swelling on finger III of adult males: present = 0; absent = 1.

We did not observe swelling on finger III in our sample of *Allobates trilineatus*; however, we scored it as present on the basis of Grant and Rodríguez (2001). The glandular basis of the swelling is unknown.

8. Phalangeal swelling on finger V of adult males: present = 0; absent = 1.

See Character 11 (below) for comments on the transformational independence of phalangeal swelling and SMGs.

### 3.4.2 | Specialized mucous glands (characters 9–15)

On the basis of our histological data, we identified four types of specialized mucous glands (SMGs) in the hands of adult males (Figure 5). Given their morphological and histochemical differences, we scored each type of SMG as a separate character. Should future evidence demonstrate an ontogenetic relationship between SMG types (see Discussion), then the coding scheme would require revision.

9. Type I SMGs: absent = 0; present = 1.

According to the available data, if a species possesses SMGs, they are always present on finger IV. As such, we do not score type I SMGs located on finger IV as a separate character. In contrast, the presence of SMGs on other fingers is variable, so we score those occurrences as separate characters.

10. Type I SMGs, finger II: absent = 0; present = 1.

Although type I SMGs cause the phalangeal swelling on finger II (character 6, above), these two characters are not taxonomically co-extensive, which establishes their transformational independence. Only *Hyloxalus jacobuspetersi* was scored as presenting both phalangeal swelling and type I SMGs on finger II, while multiple species of *Allobates*, *Ameerega*, *Anomaloglossus*, *Aromobates*, *Colostethus*, *Epipedobates*, *Hyloxalus*, *Leucostethus*, and *Silverstoneia* and possess type I SMGs without swelling.

11. Type I SMGs, finger III: absent = 0; present = 1.

The occurrence of type I SMGs and phalangeal swelling on finger III vary independently. Although both occur in *Allobates* sp. Caxiuanã and *Hyloxalus jacobuspetersi*, all other species that presented type I SMGs on finger III lacked swelling. We scored *A. trilineatus* as unknown for the occurrence of type I SMGs on finger III because Grant and Rodríguez (2001) did not report histological data and the specimens examined in the present study lack swelling or SMGs on finger III.

12. Type I SMGs, finger V: absent = 0; present = 1.

Type I SMGs on finger V and phalangeal swelling on finger V (Character 8, above) are transformationally independent, with only *Hyloxalus jacobuspetersi* scored as presenting both conditions and all other species with type I SMGs on finger V lacking swelling.

13. Type II SMGs: absent = 0; present = 1.

Type II SMGs (Figure 5b) are restricted to the swollen region of finger IV.

14. Type III SMGs: absent = 0; present = 1.

We detected type III SMGs (Figure 5c) in swollen areas (i.e., along length of finger IV and on wrist) as well as finger III, despite the lack of external evidence of swelling in the latter.

15. Type IV SMGs: absent = 0; present = 1.

Type IV SMGs (Figure 5d) are restricted to the swollen region of finger IV.

### 3.5 | Character evolution

On the basis of our taxon sample (Data S2), type I SMGs arose in the most recent common ancestor (MRCA) of Dendrobatoidea and were independently lost in *Allobates femoralis*, *Mannophryne olmonae*, *Hyloxalus pulchellus*, and either the MRCA of Dendrobatinae or independently in *Phyllobates vittatus* and *Andinobates daleswansonii* (Figure 8, ch. 9, ambiguous optimizations not shown). Type II SMGs are absent in all aromobatids and originated either in the MRCA of Dendrobatidae (with a subsequent loss in Dendrobatinae; Figure 8, ch. 13') or as independently derived synapomorphies of Colostethinae and *Hyloxalus* (Figure 8, ch. 13''). Type III SMGs arose deep within Aromobatidae as an autapomorphy of *Anomaloglossus stepheni*. Type IV SMGs were not included in our analysis because they are restricted to *A. tepequem*, which has not been included in any phylogenetic analyses to date. Nevertheless, the presence of the median lingual process and cis-Andean distribution make its placement in *Anomaloglossus* non-controversial (Fouquet et al., 2015; Grant et al., 1997, 2017).

Phalangeal swelling on finger IV either originated in the MRCA of Dendrobatoidea and was lost in the MRCA of Hyloxalinae + Dendrobatinae (Figure 8, ch. 1') or independently in Aromobatidae and Colostethinae (Figure 8, ch. 1''). Phalangeal swelling of finger IV was unambiguously lost in both *Allobates femoralis* and *Mannophryne olmonae* and independently regained in *Hyloxalus jacobuspetersi* and "*Colostethus*" *ruthveni*.

Type I SMGs are common and phylogenetically widespread on finger II (ch. 10: present in the MRCA of Dendrobatoidea, unambiguously lost in *Allobates trilineatus*, *Aromobates mayorgai*, and *Anomaloglossus apiau*, and absent in *Ameerega*, *Colostethus*, *Leucostethus*, and some species of *Epipedobates* and *Silverstoneia*), finger III (ch. 11: present in the MRCA of Dendrobatoidea, unambiguously lost in the most recent common ancestor of Colostethinae and regained in *Silverstoneia erasmios* and *Colostethus panamensis*), and, to a lesser degree, finger V (ch. 12: absent in the MRCA of Dendrobatoidea, independently evolved within *Aromobates*, *Silverstoneia*, *Leucostethus*, *Colostethus*, *Ameerega*, and *Hyloxalus*). In contrast, swelling on those fingers is extremely rare, with swelling on fingers II (ch. 6) and V (ch. 8) restricted exclusively to *Hyloxalus jacobuspetersi* and swelling on finger III (ch. 7) found only in *Allobates trilineatus* (fide Grant & Rodríguez, 2001) and *H. jacobuspetersi*.

**FIGURE 8** Evolution of the characters related to the sexually dimorphic integumentary swelling on the hands of poison frogs and their relatives. Character numbers are given beneath each box, with primitive-derived character states inside each box (see text for character descriptions). Color-coding of synapomorphies is as follows: white = ambiguously optimized; blue = unambiguously optimized, homoplastic, same character state not in all descendants; red = unambiguously optimized, homoplastic, same character state in all descendants; black = unambiguously optimized, non-homoplastic, same character state in all descendants. Alternative optimizations of selected ambiguously optimized synapomorphies indicated by ' and ". Letters above branches correspond to the following key clades discussed in the text: A, Dendrobatoidea; B, Aromobatidae; C, Dendrobatidae; D, Colostethinae; E, Hyloxalinae; F, Dendrobatinae

## 4 | DISCUSSION

### 4.1 | Morphology, histochemistry, and homology

OSGs and OMGs are widespread in the integument of *Anomaloglossus stepheni* and other species of Dendrobatoidea. Our histological observations of the dorsal integument of *A. stepheni* generally agree with published accounts of the OSGs of *Colostethus panamansis* (as *C. inguinalis*; see Grant, 2004), *Dendrobates auratus*, *Epipedobates anthonyi* (including specimens reported as *E. tricolor*; for taxonomy see Graham et al., 2004; Tarvin et al., 2017), *Mannophryne trinitatis*, *Oophaga histrionica*, and *Phylllobates terribilis* (Neuwirth et al., 1979) and the OSGs and OMGs of *Phylllobates bicolor* (Delfino et al., 2010; Moreno-Gómez et al., 2014), *Ameerega picta* (Prates et al., 2011), and *Ectopoglossus saxatilis* and *Hyloxalus faciopunctulatus* (Grant et al., 2017).

Although the defensive chemicals secreted by many dendrobatoid frogs have been studied for decades (Saporito et al., 2012), histochemical assays are lacking for most of them. Consequently, with the exception of Prates et al. (2011), who reported that *Ameerega picta* OSGs lack proteinaceous material and contain neutral and acid mucopolysaccharides, Moreno-Gómez et al. (2014), who reported acid mucopolysaccharides in the OMGs of *Phylllobates bicolor*, and the current study, histochemical information is lacking for dendrobatoid skin glands.

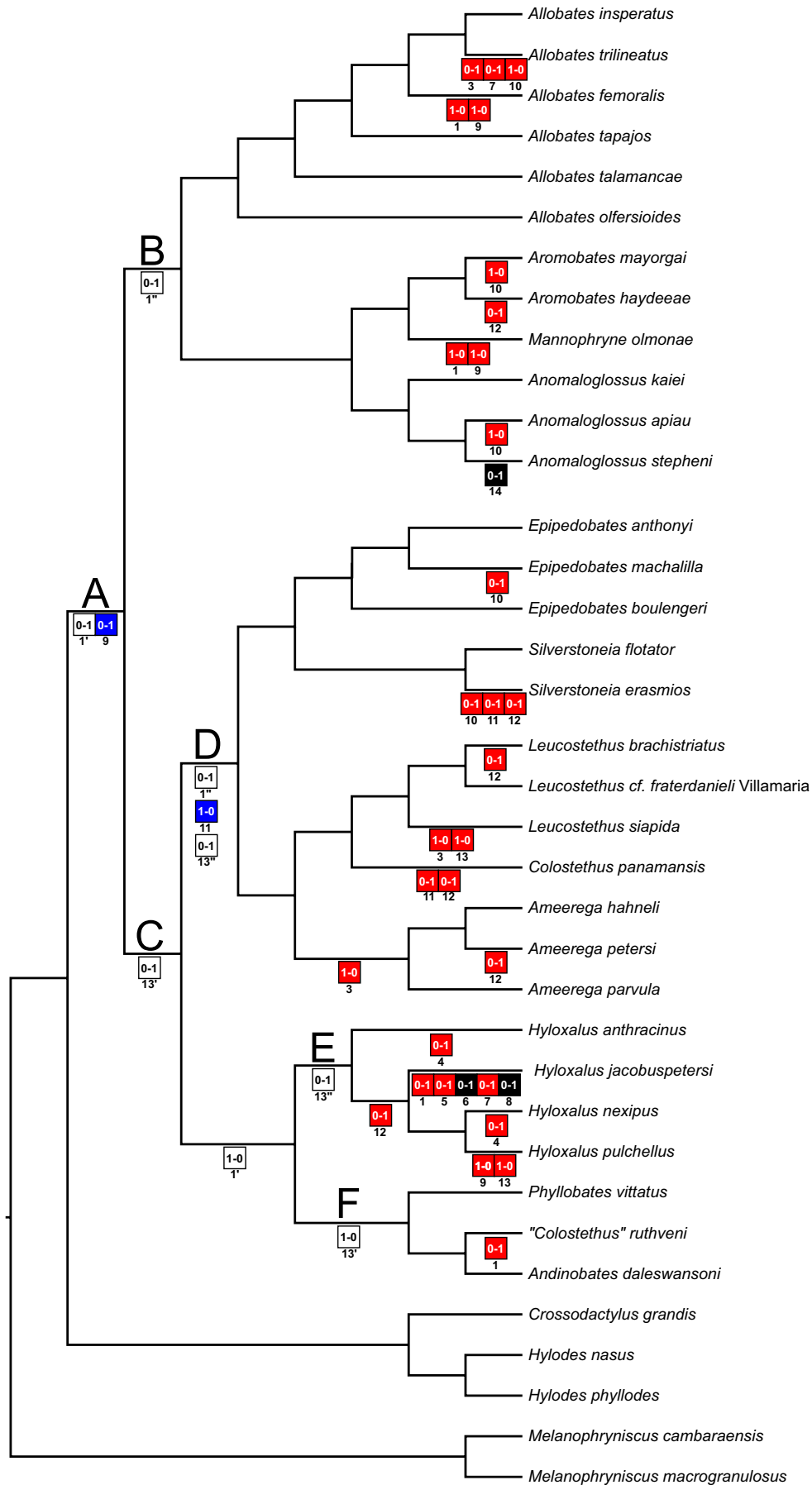
Sexually dimorphic skin glands are widespread in Anura and occur in multiple body regions (Brizzi et al., 2003), with the preaxial surface of finger II and adjacent surfaces of adult males of most species being adorned with nuptial pads composed of a highly variable epidermal component (smooth or possessing epidermal projections—papillary or not—of different sizes and shapes) and a dermis with SDSGs (Luna et al., 2018). In contrast, nuptial pads appear to be absent in dendrobatoids, which instead possess the following three different sexually dimorphic integumentary structures: (1) the black arm gland, a patch of black, apparently glandular tissue on the ventral and medial surfaces of the distal extreme of the upper arm and often extending onto the inner surface of the lower arm known from a few species of the dendrobatid genus *Hyloxalus* (Grant & Ardila-Robayo, 2002; Grant & Castro, 1998; Grant et al., 2006), (2) the supracarpal pad, a conspicuous, glandular (incorrectly described as “nonglandular” by Grant et al., 2006: 68), heavily melanized thickening of the skin above the wrist of males (weak or vestigial in females) known exclusively from *Allobates undulatus* (Myers & Donnelly, 2001) and, in an astonishing instance of independent evolution, two species of *Anomaloglossus* (Fouquet et al., 2020), and (3) swelling on

the fingers (primarily finger IV but also variably present on other fingers) and sometimes the wrist (Dunn, 1924; Grant et al., 2006, 2017). La Marca (1995: 50; see also La Marca, 1994) also reported “non-cornified swollen structures that resemble nuptial pads” on the dorsal surfaces of fingers II and III in *Mannophryne obliterata* that are presumably related to the swelling known in other species, but this hypothesis remains to be confirmed. Although co-occurrence of these sexually dimorphic integumentary structures is rare, the black arm gland and swollen finger IV co-occur in at least *Hyloxalus anthracinus* and *H. nexipus*, and all three species that possess the supracarpal pad also have swelling on finger IV (and possibly the other fingers as well in *Allobates undulatus*). The histology of the black arm gland and supracarpal pad remains unknown, but our results show that the swelling of finger IV is caused by four densely packed, hypertrophic, morpho-histochemical types of SMGs without additional modification of the dermis (except the decreased abundance of OMGs) or epidermis.

Like the sexually dimorphic integumentary structures of dendrobatoids (as well as the upper lip swelling of the hylid *Plectrohyla* and lateral glands of centrolenids; Luna et al., 2018, 2019), the dermal component of nuptial pads is primarily populated by SMGs, sometimes with a few OMGs and rarely with OSGs, while only *Xenopus* nuptial pads are known to contain SSGs (Luna et al., 2018). In contrast, other sexually dimorphic glandular structures described for anurans either contain both SMGs and SSGs (e.g., lateral glands of the hylid tribe Cophomantini; Brunetti et al., 2012, 2015) or only SSGs (e.g., femoral glands of mantellids, inguinal glands of *Cycloramphus*; ventrolateral glands of *Ptychohyla*; inguinal glands of at least one species of *Scinax*; Vences et al., 2007; Gonçalves & Brito-Gitirana, 2008; Brito et al., 2019; Luna et al., 2019).

Given the shared predominance of SMGs in both nuptial pads and the sexually dimorphic integumentary structures of dendrobatoids, the relationship between nuptial pad SMGs and the widespread type I and II SMGs requires additional investigation to determine if they are evolutionary novelties (as assumed here) or homologues of nuptial pad SMGs that underwent a heterotopic shift. The extensive diversity in nuptial pad SMG morphology and histochemistry and lack of clarity regarding the dermal component of the nuptial pads of Hyloidea (Luna et al., 2018), compounded by the highly variable placement of Dendrobatoidea among lineages of Notogaeonura (e.g., Feng et al., 2017; Frost et al., 2006; Grant et al., 2006, 2017; Hime et al., 2021; Jetz & Pyron, 2018), prevent us from investigating the homology of these SMGs further in the present study.

Type I SMGs are morphologically different from the other three types, but types II–IV differ only in histochemistry and position



relative to type I. Given their morphological similarity, investigation of the ultrastructure and ontogeny of these SMGs is merited to determine if they are independent types or developmental stages of type II SMGs. Nevertheless, the fact that we did not observe histochemical variation within individuals or co-occurrence of type II SMGs with either type III or IV SMGs and the cladistic distance between taxa with type II SMGs (restricted to Dendrobatidae) and type III and IV SMGs (restricted to the anobatid genus *Anomaloglossus*) support the current hypotheses. Furthermore, even if they are determined to be developmental stages of type II SMGs, the stages corresponding to types III and IV would still be independently evolved apomorphies within *Anomaloglossus*.

Likewise, type III and IV SMGs could also prove to be developmental stages of the same SMG. However, although the species that possess these glands are closely related (Grant et al., 2017; Vacher et al., 2017; Fouquet et al., 2020), the absence of both neutral and acid mucopolysaccharides in type III SMGs is a major difference that is unlikely to owe to individual or developmental variation, especially given the lack of variation observed in other species and glands (i.e., type III and IV glands were not observed in the same individual, and all examined type I and II glands invariably possess both proteins and mucopolysaccharides).

Whereas type III SMGs produce only proteins, types I, II, and IV produce both proteins and mucous. In caudates and some anurans, glands that secrete proteins and mucous are classified as “mixed” and comprise two morphologically different secretory portions, one that produces mucous and the other that produces proteins (Brizzi et al., 2001, 2002; Seki et al., 1995; Staub & Paladin, 1997). In contrast, type I, II, and IV SMGs are morphologically uniform, with no compartmentalization.

## 4.2 | Character evolution

Although our analysis of character evolution revealed a number of intriguing transformations, including the origin of type I SMGs in the MRCA of Dendrobatoidea—possibly in conjunction with the origin of cephalic amplexus (Carvajal-Castro et al., 2020; but see Grant et al., 2006)—these findings must be interpreted cautiously. Most importantly, the taxon sample for our analysis included only 31 of the more than 350 species of dendrobatoids (Frost, 2021). Although we chose these species as representative of larger lineages, the effect of increased sampling is unpredictable based only on external morphology for several reasons. First, our detailed analysis of external morphology revealed that several species described in the literature as lacking swelling in fact possess SMGs and swelling. On this basis, we predict that much (but not all; e.g., *Allobates femoralis*, *Hyloxalus pulchellus*) of the apparent homoplasy in the occurrence of swelling on finger IV (Grant et al., 2017) will be eliminated by detailed analysis of external morphology and histology. Similarly, the occurrence of SMGs on other fingers was much more prevalent than indicated by external morphology, with type I SMGs present in fingers that lack swelling in several species. Finally, although available evidence

strongly suggests the glandular tissue on the fingers of all species will include type I SMGs, the taxonomic distribution of types II–IV is less predictable.

## 4.3 | Functional implications

A century after the swelling on finger IV was first reported by Dunn (1924), it is now known to be formed by one or two of at least four types of SMGs. In addition to their occurrence in the swollen area of finger IV, SMGs variably occur on all fingers and extend onto the wrist—all surfaces that contact the female during cephalic amplexus (Grant et al., 2017). Although the secretions from dendrobatoid SMGs have yet to be characterized, all four types of SMGs stained positively for proteins, and the molecules synthesized and stored in these SDSGs presumably include proteinaceous courtship pheromones that are transferred to the female during amplexus to affect female physiology and/or behavior, as hypothesized for nuptial pads (Bossuyt et al., 2019; Thomas et al., 1993; Willaert et al., 2013). Secretion of adhesive compounds has also been hypothesized for SMGs (Luna et al., 2018), but the comparatively loose contact between the male's hand and the lateral portion of the female's head in cephalic amplexus, which follows often prolonged and elaborate courtship (see citations below), is inconsistent with that function in dendrobatoids.

Pheromones are generally detected by chemoreceptors in the nasal cavity (Wyatt, 2017), and the proximity of the male's hands to the female's snout during cephalic amplexus suggests the possibility of delivery through the nares to the nasal cavity (olfactory delivery); however, transdermal delivery cannot be dismissed, since contact does not target the female's snout specifically during cephalic amplexus, as it does in anurans and salamanders that possess mental or lateral glands (Arnold et al., 2017; Brunetti et al., 2014; Woodley & Staub, 2021), but also involves the loreal region, lips, and lateral portion of the throat. Furthermore, although phalangeal swelling is likely to contact the snout, the glands that comprise basal and metacarpal swelling (as well as the carpal pad and black arm gland) would not contact or come into close proximity to the snout during amplexus. Amphibian skin is thin, highly permeable, and densely vascularized, so even though cutaneous wounds presumably facilitate diffusion into the female's circulatory system (Organ, 1961; vaccination delivery, Arnold, 1977), they do not appear to be necessary to achieve transdermal delivery. As summarized by Luna et al. (2018), although nuptial pads usually possess asperous or spinous epidermal projections that can cause abrasions or scratches, the nuptial pads of more than 20% of the species they examined using histology or SEM are smooth, without epidermal projections. Nevertheless, both olfactory and transdermal delivery are plausible, and additional research is required to identify the delivery mechanism in these frogs.

The widespread occurrence of these SMGs among dendrobatoids adds a new dimension to studies of the reproductive biology of these frogs, which, for decades, have investigated acoustic,

visual, and tactile cues in courtship, mating, and parental care across the diversity of Aromobatidae (e.g., *Allobates*: Castillo-Trenn & Coloma, 2008; Costa & Dias, 2019; Juncá, 1998; Lima et al., 2002; Montanarin et al., 2011; Rocha et al., 2018; Roithmair, 1994; Souza et al., 2017; Stückler et al., 2019; Zimmermann, 1989; *Anomaloglossus*: Bourne et al., 2001; Pettitt et al., 2012; Juncá, 1998; *Mannophryne*: Dole & Durant, 1974; Greener et al., 2020; Wells, 1980a; *Rheobates*: Lüddecke, 1999) and Dendrobatidae (e.g., *Ameerega*: Costa et al., 2006; Forti et al., 2013; Roithmair, 1994; *Colostethus*: Wells, 1980b; *Dendrobates*: Rojas & Pašukonis, 2019; Summers, 1992, 2014; Wells, 1978; *Epipedobates*: Zimmermann, 1989; *Hyloxalus*: Lötters et al., 2000; Quiguango-Ubillús & Coloma, 2008; *Oophaga*: Crump, 1972; Dreher & Pröhl, 2014; Limerick, 1980; Jungfer, 1985; Jungfer et al., 1996; Silverstone, 1973; Summers, 1992; Yang et al., 2019a, 2019b; *Paruwobates*: Myers & Burrowes, 1987; *Phyllobates*: Zimmermann, 1989; Zimmermann & Zimmermann, 1985; *Ranitomeya*: Caldwell, 1997; Caldwell & Oliveira, 1999) but have almost entirely overlooked the possible role of chemical cues (but see Forester & Wisniewski, 1991; Korbeck & McRoberts, 2005; Schulte, 2016; Schulte & Lötters, 2014; Schulte and Rössler, 2013; Schulte et al., 2011).

Characterization of the composition and effects of SMG secretions and a more detailed understanding of their evolution could shed light on the variation in courtship and breeding observed both in species that employ reproductive amplexus and those that have lost it. For example, *Anomaloglossus stephensi* performs two amplexi, each lasting approximately 50 min, with an interval of approximately 5 h (Juncá, 1998). The first amplexus initiates ovulation, oocytes are transported along the oviduct and enveloped in a dense gelatinous capsule during the interval, and the second amplexus is necessary for oviposition (Juncá & Rodrigues, 2006). The occurrence in males of both type I and type III SMGs raises the possibility that the secretion from one type might cause ovulation and the other oviposition. In contrast, both SMGs and reproductive amplexus are absent in *Phyllobates vittatus* (Lötters et al., 2007; Silverstone, 1976), in which females are significantly more active in tactile stimulation than males (Summers, 2000). Histological and behavioral studies of *Allobates femoralis* from multiple localities could elucidate the process by which amplexus is gained and/or lost, since amplexus is absent in *A. femoralis* from Panguana, Peru (Roithmair, 1994) but present in *A. femoralis* from Reserva Ducke, Brazil (Montanarin et al., 2011)—even though both localities pertain to the same genetic population (Simões et al., 2010)—and unknown in the *A. femoralis* population studied here. Similarly, *Allobates talamancae* lacks amplexus, but the male mounts the female and leans his forelimbs on her upper forelimbs prior to oviposition (Zimmermann, 1989), and we observed both swelling and type I SMGs in this species. Understanding the role of chemical communication in these frogs will provide novel insights into the complexity of the communication system of this clade and the contributions and importance of different classes of cues in multimodal signaling generally (e.g., Hebets et al., 2016; Mitoyen et al., 2019; Starnberger et al., 2014).

## ACKNOWLEDGEMENTS

Wilmar Bolívar-G. (CPZ-UV), Rafe Brown (KU), and Luis Alberto Rueda Solano (UMAG) granted permission to dissect and section specimens in their care; André Morandini granted access to equipment; and Aline Benetti, Phillip Lenkaitis, Enio Mattos, and Luke Welton provided technical support. Luis Coloma graciously allowed us to reproduce his photograph of *Ameerega parvula* in amplexus. We are grateful to Marvin Anganoy, Marta Antoniazzi, Wilmar Bolívar-G., Andrés Brunetti, Pedro Dias, Carlos Jared, Adriana Jeckel, Pedro Mailho-Fontana, José Marian, Rachel Montesinos, Marco Rada, and Geven Rodríguez for their many insights during different stages of this study. The critical reviews provided by Luis Coloma, Lisa Schulte, and an anonymous referee greatly improved the final version of the article. This research was supported by the São Paulo Research Foundation (FAPESP Procs. 2012/10000-5, 2015/21007-9, and 2018/15425-0), the Brazilian National Council for Scientific and Technological Development (CNPq Proc. 306823/2017-9 and 130046/2018-3), the Brazilian Coordenação de Aperfeiçoamento de Pessoal de Nível Superior (CAPES Finance Code 001), and the Argentinian Agencia Nacional de Promoción Científica y Tecnológica (ANPCyT PICT 820-2015, 2381-2015, 3349-2018, 346-2019, 2519-2019).

## CONFLICT OF INTEREST

The authors declare that they have no conflict of interests.

## AUTHOR CONTRIBUTIONS

T.G. conceived of the study and obtained primary funding and samples. I.R. and T.G. designed the study. I.R. performed primary data collection, which was examined, confirmed, interpreted, and analyzed by all authors. I.R. and T.G. prepared the figures and wrote and revised the manuscript, with additional revisions and contributions by M.C.L. and J.F. All authors read and approved the final submission.

## DATA AVAILABILITY STATEMENT

All data generated or analyzed during this study are included in this article.

## ORCID

Isabela Rodrigues de Souza Cavalcanti  <https://orcid.org/0000-0002-0239-933X>

Maria Celeste Luna  <https://orcid.org/0000-0002-6392-8864>

Julián Faivovich  <https://orcid.org/0000-0001-7157-8131>

Taran Grant  <https://orcid.org/0000-0003-1726-999X>

## REFERENCES

- Arnold, S.J. (1977) The evolution of courtship behavior in New World salamanders with some comments on Old World salamandrids. In: Taylor, D.H. & Guttman, S.I. (Eds.) *The reproductive biology of amphibians*. Boston: Springer, pp. 141–183.
- Arnold, S.J., Kiemnec-Tyburczy, K.M. & Houck, L.D. (2017) The evolution of courtship behavior in plethodontid salamanders, contrasting patterns of stasis and diversification. *Herpetologica*, 73, 190–205.

- Bancroft, J.D. & Stevens, A.s (Ed.s) (1982) *Theory and practice of histological techniques*, 2nd edn. Edinburgh: Churchill Livingstone.
- Behmer, O.A., de Tolosa, E.M.C. & de Freitas Neto, A.G. (1976) *Manual de Técnicas para Histologia Normal e Patológica*. São Paulo: EDART São Paulo Livraria e Editora.
- Bossuyt, F., Schulte, L.M., Maex, M., Janssenswillen, S., Novikova, P.Y., Biju, S.D. et al. (2019) Multiple independent recruitment of sodefrin precursor-like factors in anuran sexually dimorphic glands. *Molecular Biology and Evolution*, 36, 1921–1930.
- Bourne, G.R., Collins, A.C., Holder, A.M. & McCarthy, C.L. (2001) Vocal communication and reproductive behavior of the frog *Colostethus beebei* in Guyana. *Journal of Herpetology*, 35(2), 272–281. <https://doi.org/10.2307/1566118>.
- Brito, P., Targueta, C.P., Arruda, W., Santos, F. & Bastos, R.P. (2019) The sexually dimorphic inguinal gland of the frog species *Oloolygon centralis* (Anura: Hylidae) at light and transmission electron microscopy. *Zoologia*, 36, e29356.
- Brizzi, R., Delfino, G. & Jantra, S. (2003) An overview of breeding glands. In: Jamieson, B.G.M. (Ed.) *Reproductive biology and phylogeny of Anura*. Enfield: Science Publishers, pp. 253–317.
- Brizzi, R., Delfino, G., Jantra, S., Alvarez, B.B. & Sever, D.M. (2001) The amphibian cutaneous glands: some aspects of their structure and adaptive role. In: Lymberakis, P., Valakos, E., Pafilis, P. & Mylonas, M. (Eds.) *Herpetologia Candiana*. Irakleio: Natural History Museum of Crete, University of Crete, pp. 43–49.
- Brizzi, R., Delfino, G. & Pellegrini, R. (2002) Specialized mucous glands and their possible adaptive role in the males of some species of *Rana* (Amphibia, Anura). *Journal of Morphology*, 341, 328–341.
- Brunetti, A.E., Hermida, G.N. & Faivovich, J. (2012) New insights into sexually dimorphic skin glands of anurans: the structure and ultrastructure of the mental and lateral glands in *Hypsiboas punctatus* (Amphibia: Anura: Hylidae). *Journal of Morphology*, 273, 1257–1271.
- Brunetti, A.E., Hermida, G.N., Luna, M.C., Barsotti, A.M.G., Jared, C., Antoniazzi, M.M. et al. (2015) Diversity and evolution of sexually dimorphic mental and lateral glands in Cophomantini treefrogs (Anura: Hylidae: Hylinae). *Biological Journal of the Linnean Society*, 114, 12–34.
- Brunetti, A.E., Taboada, C. & Faivovich, J. (2014) The reproductive biology of *Hypsiboas punctatus* (Anura: Hylidae): male territoriality and the possible role of different signals during female choice. *Salamandra*, 50, 215–224.
- Caldwell, J.P. (1997) Pair bonding in spotted poison frogs. *Nature*, 385, 211.
- Caldwell, J.P., de Oliveira, V.R.L. & de Oliveira, V.R.L. (1999) Determinants of biparental care in the spotted poison frog, *Dendrobates vanzolinii* (Anura: Dendrobatidae). *Copeia*, 1999, 565–575.
- Campbell, J.A. & Frost, D.R. (1993) Anguid lizards of the genus *Abronia*: revisionary notes, descriptions of new species, a phylogenetic analysis, and key. *Bulletin of the American Museum of Natural History*, 216, 1–121.
- Carvajal-Castro, J.D., López-Aguirre, Y., Ospina-L, A.M., Santos, J.C., Rojas, B. & Vargas-Salinas, F. (2020) Much more than a clasp: evolutionary patterns of amplexus diversity in anurans. *Biological Journal of the Linnean Society*, 129, 652–663.
- Castillo-Trenn, P. & Coloma, L.A. (2008) Notes on behaviour and reproduction in captive *Allobates kingsburyi* (Anura: Dendrobatidae), with comments on evolution of reproductive amplexus. *International Zoo Yearbook*, 42, 58–70.
- Coloma, L.A. (1995) Ecuadorian frogs of the genus *Colostethus* (Anura: Dendrobatidae). *The University of Kansas Natural History Museum Miscellaneous Publication*, 87, 1–72.
- Costa, R.C., Facure, K.G. & Giaretta, A.A. (2006) Courtship, vocalization, and tadpole description of *Epipedobates flavopictus* (Anura: Dendrobatidae) in southern Goiás, Brazil. *Biota Neotropica*, 6, Costa, S.M. & Dias, E.J.R. (2019) Comportamento territorial, vocalização e biologia reprodutiva de *Allobates olfersioides* (Anura: Aromobatidae). *Iheringia*, 109, e2019031.
- Crump, M.L. (1972) Territoriality and mating behavior in *Dendrobates granuliferus* (Anura: Dendrobatidae). *Herpetologica*, 22, 195–198.
- da Rocha, S.M.C., Lima, A.P. & Kaefer, I.L. (2018) Reproductive behavior of the Amazonian nurse-frog *Allobates paleovarzensis* (Dendrobatoidea, Aromobatidae). *South American Journal of Herpetology*, 13, 260–270.
- Delfino, G., Giachi, F., Nosi, D. & Malentacchi, C. (2010) Serous cutaneous glands in *Phyllobates bicolor* (Anura: Dendrobatidae): an ontogenetic, ultrastructural study on secretory product biosynthesis and maturation. *Copeia*, 2010, 27–37.
- Dole, J.W. & Durant, P. (1974) Courtship behavior in *Colostethus collaris* (Dendrobatidae). *Copeia*, 1974, 988–990.
- Dreher, C.E. & Pröhl, H. (2014) Multiple sexual signals: calls over colors for mate attraction in an aposematic, color-diverse poison frog. *Frontiers in Ecology and Evolution*, 2, 1–10.
- Duellman, W.E. & Trueb, L. (1986) *Biology of amphibians*. New York: McGraw-Hill.
- Dunn, E.R. (1924) Some Panamanian frogs. Occasional Papers of the Museum of Zoology, University of Michigan, 151, 1–17.
- Edwards, S.R. (1971) Taxonomic notes on South American *Colostethus* with descriptions of two new species (Amphibia, Dendrobatidae). *Proceedings of the Biological Society of Washington*, 84, 147–162.
- Erspamer, V. (1994). Bioactive secretions of the amphibian integument. In: Heatwole, H. & Barthalmus, G.T. (Eds.), *Amphibian Biology. The Integument*. Chipping Norton, UK: Surrey Beatty & Sons Pty., Ltd., pp. 178–350.
- Fabrezi, M. & Alberch, P. (1996) The carpal elements of anurans. *Herpetologica*, 52, 188–204.
- Feng, Y.-J., Blackburn, D.C., Liang, D., Hillis, D.M., Wake, D.B., Cannatella, D.C. et al. (2017) Phylogenomics reveals rapid, simultaneous diversification of three major clades of Gondwanan frogs at the Cretaceous–Paleogene boundary. *Proceedings of the National Academy of Sciences*, 114(29), E5864–E5870.
- Fitch, W.M. (1971) Toward defining the course of evolution: minimum change for a specific tree topology. *Systematic Zoology*, 20, 406–416. <https://doi.org/10.1093/sysbio/20.4.406>.
- Forester, D.C. & Wisnieski, A. (1991) The significance of airborne olfactory cues to the recognition of home area by the dart-poison frog *Dendrobates pumilio*. *Journal of Herpetology*, 25, 502–504.
- Forti, L.R., Mott, T. & Strüssmann, C. (2013) Breeding biology of *Ameerega braccata* (Steindachner, 1864) (Anura: Dendrobatidae) in the Cerrado of Brazil. *Journal of Natural History*, 47, 2363–2371.
- Fouquet, A., Jairam, R., Ouboter, P. & Kok, P.J.R. (2020) Two new species of *Anomaloglossus* (Anura: Aromobatidae) of the *stepheni* group from Suriname. *Zootaxa*, 4820, 147–164.
- Fouquet, A., Souza, S.M., Nunes, P.M.S., Kok, P.J.R., Curcio, F.F., de Carvalho, C.M. et al. (2015) Two new endangered species of *Anomaloglossus* (Anura: Aromobatidae) from Roraima State, northern Brazil. *Zootaxa*, 3926, 191–210.
- Fox, H. (1986) Early development of caecilian skin with special reference to the epidermis. *Journal of Herpetology*, 20, 154–167.
- Frost, D.R. (1986) A new species of *Colostethus* (Anura: Dendrobatidae) from Ecuador. *Proceedings of the Biological Society of Washington*, 99, 214–217.
- Frost, D.R. (2021). Amphibian species of the world: an online reference. Version 6.1 (05 June 2021). Electronic Database accessible at <http://research.amnh.org/herpetology/amphibia/index.php>. American Museum of Natural History, New York, USA. <https://doi.org/10.5531/db.vz.0001>
- Frost, D.R., Grant, T., Faivovich, J., Bain, R.H., Haas, A., Haddad, C.F.B. et al. (2006) The amphibian tree of life. *Bulletin of the American Museum of Natural History*, 297, 1–370.



- Fujikura, K., Kurabuchi, S., Tabuchi, M. & Inoue, S. (1988) Morphology and distribution of the skin glands in *Xenopus laevis* and their response to experimental stimulations. *Zoological Science*, 5, 415–430.
- Goloboff, P.A. & Catalano, S.A. (2016) TNT version 1.5, including a full implementation of phylogenetic morphometrics. *Cladistics*, 32, 221–238.
- Gonçalves, V.F. & de Brito-Gitirana, L. (2008) Structure of the sexually dimorphic gland of *Cycloramphus fuliginosus* (Amphibia, Anura, Cycloramphidae). *Micron*, 39, 32–39.
- Graham, C.H., Ron, S.R., Santos, J.C., Schneider, C.J. & Moritz, C. (2004) Integrating phylogenetics and environmental niche models to explore speciation mechanisms in dendrobatid frogs. *Evolution*, 58, 1781–1793.
- Grant, T. (2004) On the identities of *Colostethus inguinalis* (Cope, 1868) and *C. panamensis* (Dunn, 1933), with comments on *C. latinasus* (Cope, 1863) (Anura: Dendrobatidae). *American Museum Novitates*, 3444, 1–24.
- Grant, T. & Ardila-Robayo, M.C. (2002) A new species of *Colostethus* (Anura: Dendrobatidae) from the eastern slopes of the Cordillera Oriental of Colombia. *Herpetologica*, 58, 252–260.
- Grant, T. & Castro, F. (1998) The cloud forest *Colostethus* (Anura, Dendrobatidae) of a region of the Cordillera Occidental of Colombia. *Journal of Herpetology*, 32, 378–392.
- Grant, T., Frost, D.R., Caldwell, J.P., Gagliardo, R., Haddad, C.F.B., Kok, P.J.R. et al. (2006) Phylogenetic systematics of dart-poison frogs and their relatives (Anura: Athesphatanura: Dendrobatidae). *Bulletin of the American Museum of Natural History*, 299, 1–262.
- Grant, T., Humphrey, E.C. & Myers, C.W. (1997) The median lingual process of frogs: a bizarre character of Old World ranoids discovered in South American dendrobatids. *American Museum Novitates*, 3212, 1–40.
- Grant, T. & Kluge, A.G. (2004) Transformation series as an ideographic character concept. *Cladistics*, 20, 23–31.
- Grant, T., Rada, M., Anganoy-Criollo, M., Batista, A., Dias, P.H., Jeckel, A.M. et al. (2017) Phylogenetic systematics of dart-poison frogs and their relatives revisited (Anura: Dendrobatoidea). *South American Journal of Herpetology*, 12, S1–S90.
- Grant, T. & Rodríguez, L.O. (2001) Two new species of frogs of the genus *Colostethus* (Dendrobatidae) from Peru and a redescription of *C. trilineatus* (Boulenger, 1883). *American Museum Novitates*, 3355, 1–24.
- Greener, M.S., Hutton, E., Pollock, C.J., Wilson, A., Lam, C.Y., Nokhbatolfighahai, M. et al. (2020) Sexual dichromatism in the neotropical genus *Mannophryne* (Anura: Aromobatidae). *PLoS One*, 15, e0223080.
- Hebets, E.A., Barron, A.B., Balakrishnan, C.N., Hauber, M.E., Mason, P.H. & Hoke, K.L. (2016) A systems approach to animal communication. *Proceedings of the Royal Society B: Biological Sciences*, 283, 20152889.
- Hime, P.M., Lemmon, A.R., Lemmon, E.C.M., Prendini, E., Brown, J.M., Thomson, R.C. et al. (2021) Phylogenomics reveals ancient gene tree discordance in the amphibian tree of life. *Systematic Biology*, 70, 49–66.
- Humason, G.L. (1962) *Animal tissue techniques*. San Francisco: W. H. Freeman and Company.
- Jeckel, A.M., Caorsi, V.Z., Grant, T. & Borges-Martins, M. (2019) The nuptial pads of *Melanophryniscus* (Anura: Bufonidae), with the unexpected occurrence of nuptial-pad-like structures in females of two species. *Journal of Herpetology*, 53(1), 53–61.
- Jetz, W. & Pyron, R.A. (2018) The interplay of past diversification and evolutionary isolation with present imperilment across the amphibian tree of life. *Nature Ecology and Evolution*, 2, 850–858.
- Juncá, F.A. (1998) Reproductive biology of *Colostethus stepheni* and *Colostethus marchesianus* (Dendrobatidae), with the description of a new anuran mating behavior. *Herpetologica*, 54, 377–387.
- Juncá, F.A. & Rodrigues, M.T. (2006) Morphological changes in the female reproductive organs during mating in *Colostethus stepheni* and associated behaviour. *Amphibia-Reptilia*, 27, 303–308.
- Jungfer, K.-H. (1985) Beitrag zur Kenntnis von *Dendrobates speciosus* O. Schmidt, 1857 (Salienti: Dendrobatidae). *Salamandra*, 21, 263–280.
- Jungfer, K.-H., Weygoldt, P. & Juraske, N. (1996) *Dendrobates vicentei*, ein neuer Pfeilgiftfrosch aus Zentral-Panama. *Herpetofauna*, 18, 17–26.
- Junqueira, L.C.U. (1995) Histology revisited—Technical improvement promoted by the use of hydrophilic resin embedding. *Ciência e Cultura*, 47, 92–95.
- Korbeck, R.G.J. & McRobert, S.P. (2005) Home area recognition via olfactory cues in the tropical poison frog *Dendrobates auratus*. *Russian Journal of Herpetology*, 12, 161–166.
- La Marca, E. (1994) Taxonomy of the frogs of the genus *Mannophryne* (Amphibia; Anura; Dendrobatidae). *Publicaciones de la Asociación de Amigos de Doñana*, 4, 1–75.
- La Marca, E. (1995) Biological and systematic synopsis of a genus of frogs from northern mountains of South America (Anura: Dendrobatidae: *Mannophryne*). *Bulletin of the Maryland Herpetological Society*, 31, 40–78.
- Lima, A.P., Caldwell, J.P. & Biavati, G.M. (2002) Territorial and reproductive behavior of an Amazonian dendrobatid frog, *Colostethus caeruleodactylus*. *Copeia*, 2002, 166–172.
- Lima, A.P., Simões, P.I. & Kaefer, I.L. (2015) A new species of *Allobates* (Anura: Aromobatidae) from Parque Nacional da Amazônia, Pará State, Brazil. *Zootaxa*, 3980, 501–525.
- Limerick, S. (1980) Courtship behavior and oviposition of the poison-arrow frog *Dendrobates pumilio*. *Herpetologica*, 36, 69–71.
- Lötters, S., Jungfer, K.-H., Henkel, F.W. & Schmidt, W. (2007) *Poison, frogs edition*. Frankfurt: Chimaira.
- Lötters, S., Jungfer, K.-H. & Widmer, A. (2000) A new genus of aposematic poison frog (Amphibia: Anura: Dendrobatidae) from the upper Amazon basin, with notes on its reproductive behaviour and tadpole morphology. *Jahreshefte Der Gesellschaft Für Naturkunde in Württemberg*, 156, 233–243.
- Lüdecke, H. (1999) Behavioral aspects of the reproductive biology of the Andean from *Colostethus palmatus* (Amphibia: Dendrobatidae). *Revista de la Academia Colombiana de Ciencias Exactas, Físicas y Naturales*, 23, 303–316.
- Luna, M.C., McDiarmid, R.W. & Faivovich, J. (2018) From erotic excrescences to pheromone shots: structure and diversity of nuptial pads in anurans. *Biological Journal of the Linnean Society*, 124, 403–446.
- Luna, M.C., Vásquez-Almazán, C.R., Faivovich, J. & Brunetti, A.E. (2019) Gland composition in sexually dimorphic skin structures of two species of hylid frogs: *Plectrohyla guatemalensis* and *Ptychohyla hypomykter*. *Amphibia-Reptilia*, 40, 523–529.
- Machado, D.J. (2015) YBYRÁ facilitates comparison of large phylogenetic trees. *BMC Bioinformatics*, 16, 204.
- Maddison, W.P. & Maddison, D.R. (2019) Mesquite: a modular system for evolutionary analysis. Version 3.61. <http://mesquiteproject.org>.
- Marin, C.M., Molina-Zuluaga, C., Restrepo, A., Cano, E. & Daza, J.M. (2018) A new species of *Leucostethus* (Anura: Dendrobatidae) from the eastern versant of the Central Cordillera of Colombia and the phylogenetic status of *Colostethus fraterdanieli*. *Zootaxa*, 4461, 359.
- McDiarmid, R.W. (1994) Preparing amphibians as scientific specimens. In: Heyer, W.R., Donnelly, M.A., McDiarmid, R.W., Hayek, L.-A.-C. & Foster, M.S. (Eds.) *Measuring and monitoring biological diversity: standard methods for amphibians*. Washington: Smithsonian Institution Press, pp. 289–297.
- Mills, J.W. & Prum, B.E. (1984) Morphology of the exocrine glands of the frog skin. *American Journal of Anatomy*, 171, 91–106.
- Mitoyen, C., Quigley, C. & Fusani, L. (2019) Evolution and function of multimodal courtship displays. *Ethology*, 125, 503–515.
- Montanarin, A., Kaefer, I.L. & Lima, A.P. (2011) Courtship and mating behaviour of the brilliant-thighed frog *Allobates femoralis* from Central

- Amazonia: implications for the study of a species complex. *Ethology Ecology and Evolution*, 23, 141–150.
- Moreno-Gómez, F., Duque, T., Fierro, L., Arango, J., Peckham, X. & Ascencio-Santofimio, H. (2014) Histological description of the skin glands of *Phyllobates bicolor* (Anura: Dendrobatidae) using three staining techniques. *International Journal of Morphology*, 32, 882–888.
- Myers, C.W. & Burrowes, P.A. (1987) A new poison frog (*Dendrobates*) from Andean Colombia, with notes on a lowland relative. *American Museum Novitates*, 2899, 1–17.
- Myers, C.W. & Donnelly, M.A. (2001) Herpetofauna of the Yutajé-Corocoro massif, Venezuela: Second report from the Robert G. Goelet American Museum-Terramar Expedition to the northwestern tepuis. *Bulletin of the American Museum of Natural History*, 261, 1–85.
- Myers, C.W., Paolillo, O.A. & Daly, J.W. (1991) Discovery of a defensively malodorous and nocturnal frog in the family Dendrobatidae: phylogenetic significance of a new genus and species from the Venezuelan Andes. *American Museum Novitates*, 3002, 1–33.
- Neuwirth, M., Daly, J.W., Myers, C.W. & Tice, L.W. (1979) Morphology of the granular secretory glands in skin of poison-dart frogs (Dendrobatidae). *Tissue and Cell*, 11, 755–771.
- Noble, G.K. (1931) *The biology of the amphibia*. New York: McGraw-Hill. <https://doi.org/10.5962/bhl.title.82448>.
- Organ, J.A. (1961) Studies of the local distribution, life history, and population dynamics of the salamander genus *Desmognathus* in Virginia. *Ecological Monographs*, 31, 189–220.
- Patterson, C. (1982) Morphological characters and homology. In: Joysey, K.A. & Friday, A.E. (Eds.) *Problems of phylogenetic reconstruction*. New York: Academic Press, pp. 21–74.
- Pearse, A.G.E. (1985). *Analytical Technology*, 4th edn, Histochemistry, Theoretical and Applied. Edinburgh: Churchill Livingstone.
- Pettitt, B.A., Bourne, G.R. & Bee, M.A. (2012) Quantitative acoustic analysis of the vocal repertoire of the golden rocket frog (*Anomaloglossus beebei*). *The Journal of the Acoustical Society of America*, 131, 4811–4820.
- Prates, I., Antoniazzi, M.M., Sciani, J.M., Pimenta, D.C., Toledo, L.F., Haddad, C.F.B. et al. (2011) Skin glands, poison and mimicry in dendrobatid and leptodactylid amphibians. *Journal of Morphology*, 273, 279–290.
- Quiguango-Ubillús, A. & Coloma, L.A. (2008) Notes on behaviour, communication and reproduction in captive *Hyloxalus toachi* (Anura: Dendrobatidae), an endangered Ecuadorian frog. *International Zoo Yearbook*, 42, 78–89.
- Rastogi, R.K. (1976) Seasonal cycle in anuran (Amphibia) testis: the endocrine and environmental controls. *Bolletino di Zoologia*, 43, 151–172.
- Rastogi, R.K., Iela, L., Delrio, G. & Bagnara, J.T. (1986) Reproduction in the Mexican leaf frog, *Pachymedusa dacnicolor* II. *The Male. General and Comparative Endocrinology*, 62, 23–35.
- Roithmair, M.E. (1994) Male territoriality and female mate selection in the dart-poison frog *Epipedobates trivittatus* (Dendrobatidae, Anura). *Copeia*, 1994, 107–115.
- Rojas, B. & Pašukonis, A. (2019) From habitat use to social behavior: natural history of a voiceless poison frog, *Dendrobates tinctorius*. *PeerJ*, 7, e7648.
- Santos, J.C., Baquero, M., Barrio-Amoros, C., Coloma, L.A., Erdtmann, L.K., Lima, A.P. et al. (2014) Aposematism increases acoustic diversification and speciation in poison frogs. *Proceedings of the Royal Society B: Biological Sciences*, 281, 20141761.
- Saporito, R.A., Donnelly, M.A., Spande, T.F. & Garraffo, H.M. (2012) A review of chemical ecology in poison frogs. *Chemoecology*, 22, 159–168.
- Savage, J.M. (1968) The dendrobatid frogs of Central America. *Copeia*, 1968, 745–776.
- Schulte, L.M. (2016) Semiochemicals in anurans: testing different categories with one poison frog species. *Chemical Signals in Vertebrates*, 13, 229–244.
- Schulte, L.M. & Lötters, S. (2014) A danger foreseen is a danger avoided: how chemical cues of different tadpoles influence parental decisions of a Neotropical poison frog. *Animal Cognition*, 17, 267–275.
- Schulte, L.M. & Rössler, D.C. (2013) Do poison frogs recognize chemical cues of the other sex or do they react to cues of stressed conspecifics? *Behavioural Processes*, 100, 32–35. <https://doi.org/10.1016/j.beproc.2013.07.016>.
- Schulte, L.M., Yeager, J., Schulte, R., Veith, M., Werner, P., Beck, L.A. et al. (2011) The smell of success: choice of larval rearing sites by means of chemical cues in a Peruvian poison frog. *Animal Behaviour*, 81, 1147–1154.
- Seki, T., Kikuyama, S. & Yanaihara, N. (1995) Morphology of the skin glands of the crab-eating frog (*Rana cancrivora*). *Zoological Science*, 12, 623–626.
- Silverstone, P.A. (1973) Observations on the behavior and ecology of a Colombian poison-arrow frog, the kōkoé-pá (*Dendrobates histrionicus* Berthold). *Herpetologica*, 29, 295–301.
- Silverstone, P.A. (1976) A revision of the poison-arrow frogs of the genus *Phyllobates* Bibron in Sagra (family Dendrobatidae). *Natural History Museum of Los Angeles County Science Bulletin*, 27, 1–53.
- Simões, P.I. (2016) A new species of nurse-frog (Aromobatidae, *Allobates*) from the Madeira River basin with a small geographic range. *Zootaxa*, 4083, 501–525.
- Simões, P.I., Lima, A.P. & Farias, I.P. (2010) The description of a cryptic species related to the pan-Amazonian frog *Allobates femoralis* (Boulenger 1883) (Anura: Aromobatidae). *Zootaxa*, 28, 1–28.
- Souza, J.R.D., Kaefer, I.L. & Lima, A.P. (2017) The peculiar breeding biology of the Amazonian frog *Allobates subfolionidificans* (Aromobatidae). *Anais da Academia Brasileira de Ciências*, 89, 885–893.
- Starnberger, I., Preininger, D. & Hödl, W. (2014) From uni- to multimodality: towards an integrative view on anuran communication. *Journal of Comparative Physiology Part A*, 200(9), 777–787.
- Staub, N.L. & Paladin, J. (1997) The presence of modified granular glands in male and female *Aneides lugubris* (Amphibia: Plethodontidae). *Herpetologica*, 53, 339–344.
- Strong, E.E. & Lipscomb, D.L. (1999) Character coding and inapplicable data. *Cladistics*, 15, 363–371.
- Stückler, S., Ringler, M., Pašukonis, A., Weinlein, S., Hödl, W. & Ringler, E. (2019) Spatio-temporal characteristics of the prolonged courtship in brilliant-thighed poison frogs, *Allobates femoralis*. *Herpetologica*, 75, 268.
- Summers, K. (1992) Mating strategies in two species of dart-poison frogs: a comparative study. *Animal Behaviour*, 43, 907.
- Summers, K. (2000) Mating and aggressive behaviour in dendrobatid frogs from Corcovado National Park, Costa Rica: a comparative study. *Behavior*, 137, 7–24.
- Summers, K. (2014) Sexual conflict and deception in poison frogs. *Current Zoology*, 60, 37–42.
- Tarvin, R.D., Powell, E.A., Santos, J.C., Ron, S.R. & Cannatella, D.C. (2017) The birth of aposematism: High phenotypic divergence and low genetic diversity in a young clade of poison frogs. *Molecular Phylogenetics and Evolution*, 109, 283–295.
- Thomas, E.O., Tsang, L. & Licht, P. (1993) Comparative histochemistry of the sexually dimorphic skin glands of anuran amphibians. *Copeia*, 1993, 133–143.
- Toledo, R.C. & Jared, C. (1995) Cutaneous granular glands and amphibian venoms. *Comparative Biochemistry and Physiology Part A: Physiology*, 111, 1–29.
- Vacher, J.-P., Kok, P.J.R., Rodrigues, M.T., Lima, J.D., Lorenzini, A. & Martinez, Q. et al. (2017) Cryptic diversity in Amazonian frogs: Integrative taxonomy of the genus *Anomaloglossus* (Amphibia: Anura: Aromobatidae) reveals a unique case of diversification within the Guiana Shield. *Molecular Phylogenetics and Evolution*, 112, 158–173. <https://doi.org/10.1016/j.ympev.2017.04.017>.
- Vences, M., Wahl-Boos, G., Hoegg, S., Glaw, F., Oliveira, E.S., Meyer, A. et al. (2007) Molecular systematics of mantelline frogs from

- Madagascar and the evolution of their femoral glands. *Biological Journal of the Linnean Society*, 92, 529–539.
- Wells, K.D. (1978) Courtship and parental behavior in a Panamanian poison-arrow frog (*Dendrobates auratus*). *Herpetologica*, 34, 148–155.
- Wells, K.D. (1980a) Behavioral ecology and social organization of a dendrobatid frog (*Colostethus inguinalis*). *Behavioral Ecology and Sociobiology*, 6, 199–209.
- Wells, K.D. (1980b) Social behavior and communication of a dendrobatid frog (*Colostethus trinitatis*). *Herpetologica*, 36, 189–199.
- Willaert, B., Bossuyt, F., Janssenswillen, S., Adriaens, D., Baggerman, G., Matthijs, S. et al. (2013) Frog nuptial pads secrete mating season-specific proteins related to salamander pheromones. *The Journal of Experimental Biology*, 216, 4139–4143.
- Wolfe, D. (2019) Tissue processing. In: Suvarna, S.K., Layton, C. & Bancroft, J.D. (Eds.), *Bancroft's theory and practice of histological techniques*, 8th edn. Elsevier: Amsterdam, pp. 73–83.
- Woodley, S.K. & Staub, N.L. (2021) Pheromonal communication in urodelan amphibians. *Cell and Tissue Research*, 383, 327–345.
- Wyatt, T.D. (2017) Pheromones. *Current Biology*, 27, R739–R743. <https://doi.org/10.1016/j.cub.2017.06.039>.
- Yang, Y., Blomenkamp, S., Dugas, M.B., Richards-Zawacki, C.L. & Pröhl, H. (2019a) Mate choice versus mate preference: Inferences about color-assortative mating differ between field and lab assays of poison frog behavior. *The American Naturalist*, 193, 598–607.
- Yang, Y., Servedio, M.R. & Richards-Zawacki, C.L. (2019b) Imprinting sets the stage for speciation. *Nature*, 574, 99–102.
- Zimmermann, H. (1989) Conservation studies on the 'dart-poison' frogs. *International Zoo Yearbook*, 28, 31–38.
- Zimmermann, H. & Zimmermann, E. (1985) Zur fortpflanzungsstrategie des Pfeilgiftfrosches *Phylllobates terribilis* Myers, Daly & Malkin, 1978 (Salientia: Dendrobatidae). *Salamandra*, 21, 281–297.

#### SUPPORTING INFORMATION

Additional supporting information may be found in the online version of the article at the publisher's website.

**How to cite this article:** Cavalcanti, I.R.D.S., Luna, M.C., Faivovich, J. & Grant, T. (2021) Structure and evolution of the sexually dimorphic integumentary swelling on the hands of dendrobatid poison frogs and their relatives (Amphibia: Anura: Dendrobatoidea). *Journal of Anatomy*, 00, 1–19. <https://doi.org/10.1111/joa.13569>