

# Angiogenesis in Potentially Malignant Lesions and Carcinomas during Experimental Oral Carcinogenesis: a Preliminary Study in the Hamster Cheek Pouch

ROMINA F. AROMANDO<sup>1</sup>, ANA R. RAIMONDI<sup>2</sup>, MIGUEL A. PÉREZ<sup>1</sup>,  
VERONICA A. TRIVILLIN<sup>3</sup>, AMANDA E. SCHWINT<sup>3</sup> and MARIA E. ITOIZ<sup>1</sup>

<sup>1</sup>Department of Oral Pathology, Faculty of Dentistry, University of Buenos Aires, Buenos Aires, Argentina;

<sup>2</sup>Research Area Institute of Oncology Angel H. Roffo, School of Medicine,  
University of Buenos Aires, Buenos Aires, Argentina;

<sup>3</sup>Department of Radiobiology, National Atomic Energy Commission, Buenos Aires, Argentina

**Abstract.** Aim: To evaluate vascular morphology and density, angiogenic switch activation, vascular endothelial growth factor (VEGF) expression, and endothelial cell (EC) proliferation in the hamster cheek pouch (HCP) model of oral cancer. Materials and Methods: Immunohistochemical detection of factor VIII, 5'-Bromo-2'-Deoxyuridine (BrdU) and VEGF was performed in pre-malignant and tumoral tissues. Results: Activation of angiogenesis was detected adjacent to epithelial dysplasia. Vascularized area and perimeter ( $p < 0.001$ ) increased in dysplasias and tumors. Tumor blood vessels exhibited an enhanced vascular compression ( $p < 0.001$ ) and structural alterations. EC proliferation was similar in dysplasias and carcinomas. An increase in vascular density, EC proliferation and VEGF expression was found in potentially malignant tissues but not in carcinomas. Conclusion: The angiogenic switch occurs in the dysplastic stage preceding tumor development in the HCP model of oral cancer. In potentially malignant tissues, increased VEGF expression favors EC proliferation and an increase in vascular density. Conversely, in tumors, VEGF is no longer of pivotal importance.

Angiogenesis, the formation of new blood vessels by sprouting or bridging from pre-existing vessels, is crucial for normal development and growth but it is also essential in pathological conditions, such as tumor growth. Angiogenesis precedes tumor formation during chemically-induced

carcinogenesis, suggesting that tumor progression depends on a switch from a pre-vascular to a vascular phase (1). The first report on the angiogenic potential of pre-malignant lesions was provided by Folkman *et al.*, when the induction of angiogenesis during the transition from hyperplasia to neoplasia was demonstrated (1, 2). The time when the quiescent vasculature becomes activated to grow new capillaries is the so-called angiogenic switch (3-5) The angiogenic switch involves the ability of the tumor and its microenvironment to secrete angiogenic factors that stimulate proliferation and migration of endothelial cells (ECs) of the host to form new vessels that provide nutrients and oxygen. Signals that trigger the angiogenic switch include metabolic stress (*i.e.* that produced by hypoxia), genetic mutations (6) and, mainly, the increase in proangiogenic mediators such as fibroblast growth factor (FGF) or vascular endothelial growth factor (VEGF). VEGF is a major proangiogenic factor, well-documented as inducing vascular EC proliferation and vascular sprouting (7). It has been demonstrated that VEGF receptors are present on tumor cells themselves and other cells from the tumor microenvironment, in addition to tumoral ECs (8). VEGF is expressed in vascular ECs and a range of non-ECs including hematopoietic stem cells, macrophages, monocytes and osteoclasts (9-10). The contribution of VEGF to the development of oral dysplasia and invasive carcinomas is not perfectly understood (11). Several studies have demonstrated the expression of VEGF in normal epithelium, potentially malignant lesions and squamous cell carcinoma SCC in human oral mucosa. Whereas some authors have found no correlation between VEGF expression and angiogenesis in human oral dysplasia or carcinoma (12-15), possibly because tumor angiogenesis is mediated by other factors in addition to VEGF (16), other studies have found that an increase in microvessel density (MVD) correlates with an increase in VEGF expression in oral squamous cell carcinoma (17, 18).

Correspondence to: R.F. Aromando, Department of Oral Pathology, Faculty of Dentistry, University of Buenos Aires, Marcelo T. de Alvear 2142 2nd floor "A", C1122 AAH, Buenos Aires, Argentina. Tel: +54 1149641273, Fax: +54 1145083958, e-mail: romina\_aromando@yahoo.com.ar

Key Words: Experimental carcinogenesis, oral cancer, hamster cheek pouch, microvasculature, angiogenic switch, angiogenesis.

Moreover, Gandolfo *et al.* reported that leukoplakia exhibited an increase in VEGF expression and in sub-epithelial vascularization in human oral mucosa, and that this increase was significantly greater in leukoplakia with dysplastic changes than in leukoplakia without dysplasia (19).

According to Folkman (20) the number and structure of tumor-associated blood vessels, the expression of pro- and anti-angiogenic molecules and specific receptors reflects tumor angiogenic potential. In addition, it must be noted that increased proliferation of ECs in blood vessels can induce sprouting of new vessels, with a concomitant increase in vessel density in tissue, or alternatively, only result in increased diameter of pre-existing vessels (21).

In terms of vascular morphology, studies have demonstrated that blood vessels begin to show abnormalities, such as increased vascular density, dilation and hyperpermeability, are collapsed or have incomplete perivascular cell coverage as early as in the hyperplastic/ dysplastic stage (22). Once tumors have arisen, tumor blood vessels do not respect the hierarchy of arterioles, capillaries and venules of the vascular network. Instead, they exhibit a disorderly pattern, are irregular and leaky, generally hemorrhagic and tortuous, and form plexuses that resemble disorganized coils (23). There is also evidence of the existence of 'mosaic-blood vessels' in tumors: their wall is partially composed of ECs and tumor cells that are incorporated during the neoangiogenesis that precedes tumor formation (24).

The hamster cheek pouch (HCP) model of carcinogenesis is the most widely accepted model of oral cancer. The pouch lies within the cheek and is lined by malpighian epithelium. Topical application of the carcinogen 7,12-dimethylbenz [a]anthracene (DMBA) (25-27) induces the phenomenon of field cancerization, similarly to tobacco and alcohol in human mucosa (28). Potentially malignant lesions and squamous cell carcinomas that histologically resemble human carcinomas coexist in the same pouch. As the model recapitulates field cancerization, it is possible to analyze the epithelial changes that occur from a cancerized epithelium with no unusual microscopic findings (NUMF) to hyperplasia, varying degrees of dysplasia, and finally to invasive carcinoma. In this way, by studying phenomena that occur in the connective tissue underlying these potentially malignant lesions it is possible to assess the vascular changes that take place during the process of carcinogenesis. The changes that occur in the microvasculature during the sequential progression of epithelial cancerization have not been fully-characterized, to date, in the HCP.

Our laboratory has previously reported the expression of FGF2 in potentially malignant lesions, as well as in tumors of the HCP (29). We found an increased FGF2 expression in early stages of carcinogenesis, while tumors showed a slight or no expression at all, of this growth factor. The potentially malignant lesions and the tumors expressed FGF receptors 2 and 3. Studies have been performed in the HCP to study

angiogenesis (30, 31) but as far as we are aware of, no studies have been performed to assess the changes in microvasculature during carcinogenesis in this model.

The aim of the present study was to contribute to the characterization of the HCP model of oral cancer, focusing on the similarities to and differences from the process of human oral carcinogenesis. Within this context, the study involved: a) Determination of the point at which the angiogenic switch takes place in the HCP; b) assessment of the potential correlation between VEGF, MVD and proliferation of ECs in potentially malignant lesions and tumors of the HCP; c) analysis of the changes in vascular morphology throughout the process of experimental carcinogenesis in the HCP.

## Materials and Methods

**Tumor induction.** The right cheek pouch of 10 non-inbred young (6 weeks old) Golden Syrian hamsters (Breeding Facility, National Atomic Energy Commission, Ezeiza, Buenos Aires, Argentina) was subjected to topical application of 0.5% DMBA (SIGMA-ALDRICH, Inc., St. Louis, MO, USA) in mineral oil three times a week for 14 weeks in keeping with a standard HCP carcinogenesis protocol (25). Once the tumors had developed (approximately at 11 to 14 weeks), the animals were euthanized according to the NIH Laboratory Animals Guide Care, and the protocol was approved by the Ethics Committee of the University of Buenos Aires. The 10 hamsters developed a total of 14 tumors that were studied herein. Eight normal, non-DMBA-treated hamsters were used as controls. Thirty minutes prior to sacrifice 2 ml of a 1% solution of 5-bromo-2'-deoxyuridine (BrdU) in distilled water (approximately 0.2 g BrdU/kg b.w.) was administered *i.p.* to each hamster. After sacrifice, the pouches were everted, dissected and fixed in 10% formalin in phosphate buffered saline (PBS) (pH 7.0). Specimens containing tumors and premalignant tissue were paraffin-embedded.

**Histology and immunohistochemistry.** Sections (7  $\mu$ m-thick) were H&E stained for routine histopathology. Adjacent 12  $\mu$ -thick sections were used for immunohistochemical demonstration of VEGF and BrdU (32).

Pilot studies were performed with commercial antihuman antibodies to CD31, CD34, CD105, factor VIII and wheat germ lectins to determine the best blood vessel label in hamster tissues (data not shown). Of all the markers studied, factor VIII proved to be the best for visualizing vascular walls in the HCP.

**Histopathology:** Areas of cancerized epithelia with NUMF, areas of hyperplasia, dysplasia and carcinoma were identified in keeping with pre-established criteria (33, 34)

**Immunohistochemical labeling of factor VIII:** Endogenous peroxidase activity was blocked with 100% H<sub>2</sub>O<sub>2</sub> in methanol. Sections were then transferred to PBS (pH 7.4). After antigen unmasking by protease digestion with proteinase K 10% in PBS and permeabilization of tissue with chilled acetone at -20°C for 10 min [modified from Tonar *et al.* (35). Sections were incubated in a polyclonal rabbit antibody to human von Willebrandt Factor (vWF) (DAKO Cytomation, High Wycombe, Surrey, UK) at a dilution of 1/4000 overnight at room temperature. After washing with PBS-albumin, the sections were incubated using the biotin-streptavidine-

peroxidase kit (Multilink Kit; Biogenex, San Ramon, CA, USA): secondary antibody (biotinylated anti-Ig in PBS with carrier protein and preservative) for one hour at room temperature, sections were washed with PBS and then incubated with tertiary antibodies (peroxidase-conjugated streptavidin in PBS with carrier protein and preservative) for one hour at room temperature. The slides were then incubated with 3,3-diaminobenzidine (DAKO Cytomation), counterstained with hematoxylin and mounted.

**Immunohistochemical labeling of VEGF:** Endogenous peroxidase activity was blocked with 100% H<sub>2</sub>O<sub>2</sub> in methanol for 30 min. After antigen unmasking by citrate buffer (pH 4) in a microwave oven at maximum power for 5 min, sections were incubated with a primary antibody against human VEGF raised in goat (VEGF-147, 200 µg/ml; Santa Cruz Biotechnology Inc., California; USA) at a dilution of 1:20 in PBS overnight at room temperature. After washing with PBS-albumin, the sections were incubated with the secondary and tertiary antibodies (secondary antibody) (biotinylated anti-Ig in PBS with carrier protein and preservative) for one hour at room temperature, sections were washed with PBS and then incubated with tertiary antibodies (peroxidase-conjugated streptavidin in PBS with carrier protein and preservative) for 1 h at room temperature using the biotin-streptavidine-peroxidase kit (Multilink Kit; BIOGENEX Laboratories). The slides were then incubated with 3,3-diaminobenzidine (DAKO Cytomation), counterstained with hematoxylin and mounted. A section from a single block of normal human kidney was mounted on each slide to serve as a positive control and for grading the intensity of the reaction (36).

**Immunohistochemical detection of cells synthesizing DNA:** Following antigen retrieval with 0.1 M citrate buffer (pH 6) in a microwave oven, sections were incubated in mouse monoclonal antibody to BrdU (clon IIB5; Biogenex) overnight at 4°C. After washing with PBS-albumin, the sections were incubated with the secondary and tertiary antibodies (secondary antibody) (biotinylated anti-Ig in PBS with carrier protein and preservative) for one hour at room temperature, sections were washed with PBS and then incubated with tertiary antibodies (peroxidase-conjugated streptavidin in PBS with carrier protein and preservative) for 1 h at room temperature using the biotin-streptavidine-peroxidase kit (Multilink Kit; BIOGENEX Laboratories). The slides were then incubated with 3,3-diaminobenzidine (DAKO Cytomation), counterstained with hematoxylin and mounted.

**MVD assessment in potentially malignant lesions.** Vascular sections identified by the endothelial expression of factor VIII were counted at ×400 magnification using a grid fitted into the light microscope eyepiece. One section was assessed per case. Vessel sections were counted in the pouch wall along all the sub-epithelial connective tissue between the basal membrane and the subjacent muscle layer. All the subepithelial connective tissue available in the section was evaluated, correlating each area with the overlying epithelial alteration: NUMF, hyperplasia or dysplasia.

**Analysis of vessel morphology in potentially malignant lesions and tumors.** To study vessel morphology associated with the different epithelial lesions, digital images of the vascular sections immunostained for factor VIII were taken. Vessels were hand-traced employing the ImageJ image analysis software (version 1.43, National Institutes of Health; <http://rsb.info.nih.gov/ij/>), as described by Padera *et al.* (37) and Hagendoorn *et al.* (22). The parameters area, perimeter and aspect ratio (AR) were calculated. AR was considered an indicator of degree of vascular compression in

keeping with the criteria of Hagendoorn *et al.* (22). AR is defined as the ratio between the maximum and minimum axes. An AR of 1 indicates that the vessel section is a perfect circle (major diameter=minor diameter), that there is no compression of the vessel, and that perfusion is optimum. Conversely, when the section deviates from a perfect circle, the AR will increase as the difference between the major and minor diameters widens, indicating a high degree of compression and alterations in vascular perfusion.

**Analysis of VEGF immunohistochemical labeling.** VEGF was quantified in 10 random fields of potentially malignant epithelium adjacent to tumors in each section and in 10 random fields of tumor stroma using a magnification of ×400. Immunostaining was scored from 0 to 2: 0 as negative or less intense than kidney control; 1 as moderate or equal to the control; 2 as intense or stronger than the control.

**Counts of proliferating ECs.** EC proliferation in blood vessels was evaluated as a function of BrdU incorporation. BrdU analysis of ECs was limited to vessels with open lumina. BrdU-positive nuclei in ECs were identified in control, potentially malignant lesions and tumor tissue sections based on their morphological protrusion into the vessel lumen. All the ECs present in the connective tissue available in control pouches (n=8), in the connective tissue underlying potentially malignant lesions (n=11), and in the stroma of tumors (n=14) were analyzed.

**Statistical analysis.** The data are reported as the mean±SD. Statistical analysis was performed by ANOVA and Tukey's test for comparisons a posteriori. Statistical significance was set at  $p<0.05$  using the Primer of Biostatistic Statistical Analysis Program (Copyright 1992, McGraw Hill, Inc., Version 3.02 by Stanton A. Glantz).

## Results

**Factor VIII immunostaining and MVD assessment.** Immunostaining for factor VIII exhibited a positive and homogeneous reaction in all the blood vessel walls in normal and pre-malignant tissues (NUMF, hyperplasia and dysplasia), whereas tumor blood vessels exhibited patchy and fainter labeling. Factor VIII preparations revealed that compared with normal epithelium, the MVD was significantly increased in the connective tissue underlying dysplastic lesions ( $p<0.05$ ) (Figure 1). Carcinomas, on the other hand, contained a lower percentage of vessels compared to dysplasias. (MVD evaluated in different areas is compared in Table I).

**EC proliferation.** EC nuclei with positive staining (BrdU-positive ECs) exhibited brown diaminobenzidine deposits that contrasted with unlabeled blue, hematoxylin-stained nuclei. Analysis of proliferating ECs in vessels revealed an increase in BrdU-positive ECs in dysplasias (5.46±9.66 BrdU-positive ECs per field n=11) and in carcinomas (6.49±6.66 BrdU-positive ECs per field n=14) compared to control endothelia where no proliferation was observed (38) (n=8) ( $p<0.05$ ). Importantly, the proliferation of ECs was similar in dysplasias and carcinomas.

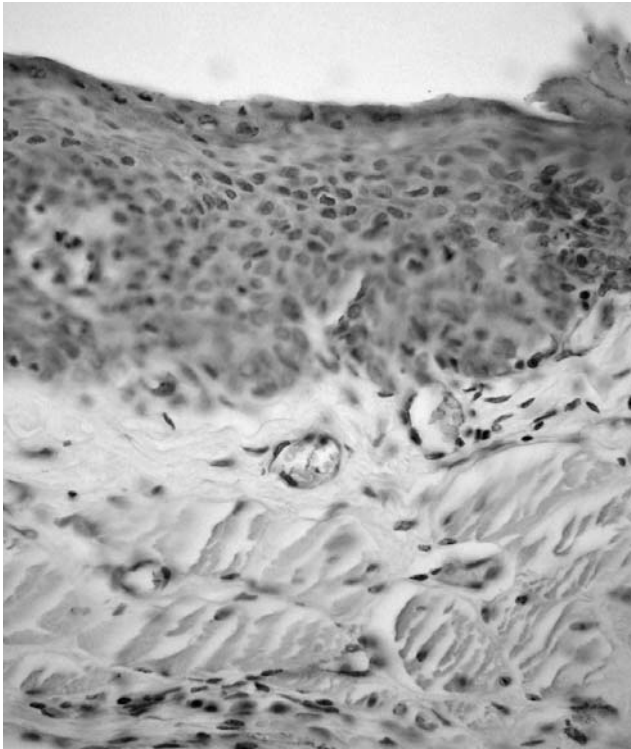


Figure 1. Factor VIII immunostaining reflecting the angiogenic switch in the connective tissue underlying dysplastic epithelium (×400).

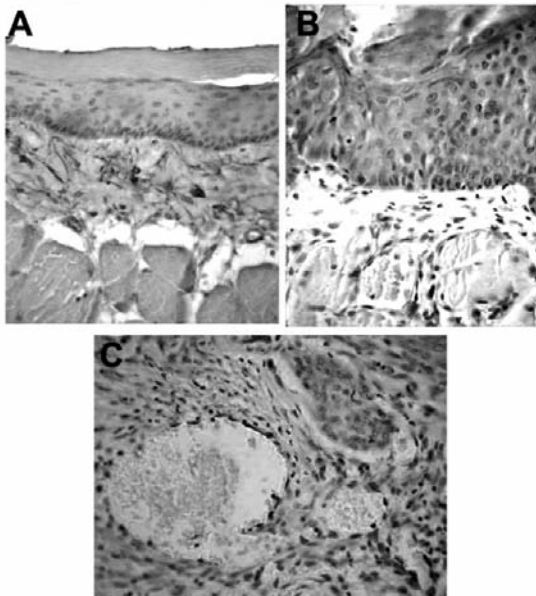


Figure 2. Immunolabeling of factor VIII showing the progressive increase in area and perimeter from control pouch (A), to connective tissue underlying dysplastic epithelium (B) and tumor stroma (C) (×400).

Table I. Number of blood vessels/mm<sup>2</sup> of sub-epithelial connective tissue underlying different tissue areas.

Tissue area	Blood vessels/mm <sup>2</sup>
Normal epithelium (n=11)	85.08±48.32
NUMF (n=6)	58.08±25.46
Hyperplasia (n=6)	108.63±96.11
Dysplasia (n=5)	182.63±104.8***
Tumor (n=8)	68.43±64.43

\*\*\*Dysplasia significantly different from normal epithelium at  $p < 0.05$ .

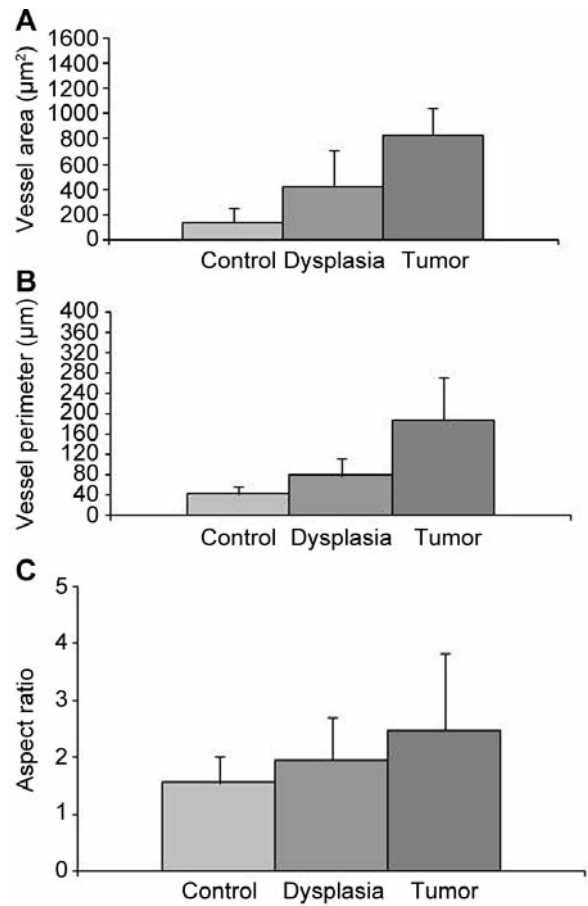


Figure 3. Progressive increase in vascular area (A) and perimeter (B) in areas underlying dysplastic epithelium and tumor stroma compared to vessels in control pouches. The aspect ratio was increased in connective tissue underlying dysplasias and tumor blood vessels compared to controls (C). \* $p < 0.05$  Compared to the control. Data are the mean±SD.

To determine whether increased proliferation of ECs in blood vessels yielded sprouting of new vessels or only resulted in an increased diameter of pre-existing vessels, we assessed the correlation between blood vessel perimeter at

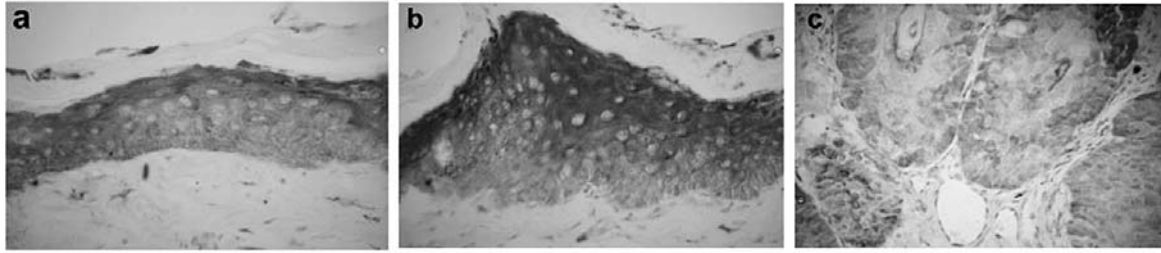


Figure 4. Immunolabeling with antibody against VEGF. Normal oral mucosa (A). A stronger reaction was found in potentially malignant epithelium (B) and a less intense reaction in tumor parenchyma (C) ( $\times 400$ ).

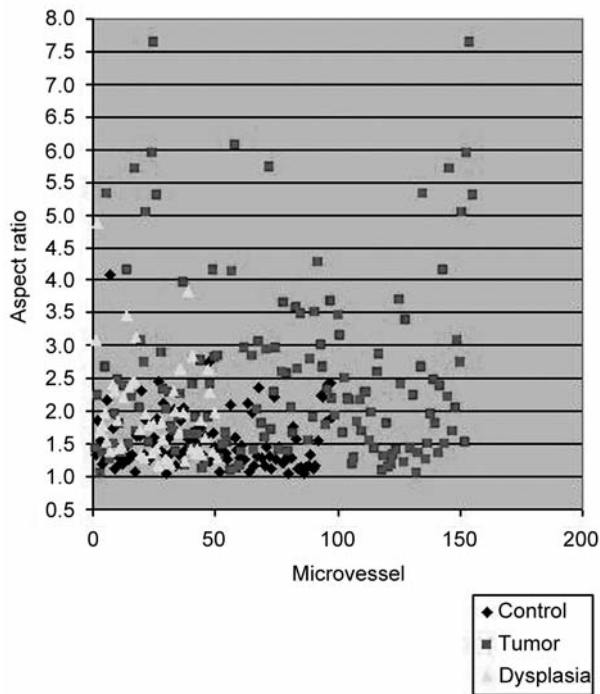


Figure 5. Significant increase in aspect ratio (difference between the major and minor diameters widens) in vessels underlying dysplasias compared to controls ( $p < 0.05$ ) and in vessels of tumor stroma compared to dysplasias ( $p < 0.05$ ).

each stage and MVD, as reported by Eichten *et al.* (21). We found that blood vessel perimeter significantly increased concomitantly with the progressive development of alterations of the overlying epithelia to yield carcinoma (Figure 3A). We found a significant increase in the number of blood vessels at the dysplastic pre-malignant stage, but in carcinomas, the number of blood vessels was lower, although not significant, compared to dysplastic tissue (Table I). In summary, blood vessels increased in perimeter and density in potentially malignant tissue but in tumors, vessels increased only in perimeter without an increase in density,

thus reflecting increased sprouting of new blood vessels (classic angiogenesis) in potentially malignant tissue as opposed to increased diameter without sprouting of vessels in tumors.

*Analysis of vascular morphology variations in potentially malignant lesions and tumor tissue.* A progressive increase in area and perimeter from control pouch to connective tissue underlying dysplastic epithelium and tumor stroma was determined ( $p < 0.05$ ) (Figures 2 and 3A and B). The AR was significantly increased in vessels underlying dysplasia compared with control ( $p < 0.05$ ) and in vessels of tumor stroma compared with dysplasia ( $p < 0.05$ ) (Figures 3C and 5). A significant fraction of tumor vessels had collapsed lumens and in some cases, the tumor vessels formed tangled clumps, exhibiting a disorderly glomerular-like structure. Some tumor blood vessel walls displayed areas composed of ECs alternating with areas composed of tumor cells.

*Immunohistochemical expression of VEGF.* Normal epithelium exhibited moderate VEGF staining but this was lower than that in the kidney used as a positive control of the labeling technique. VEGF staining was scored as moderate-to-intense in potentially malignant lesions adjacent to tumors ( $1.69 \pm 0.63$ ), with no differences between staining in NUMF, hyperplasias and dysplasias. However, VEGF expression in carcinomas was significantly lower than in potentially malignant lesions ( $0.33 \pm 0.60$ ;  $p < 0.05$ ) (Figure 4).

## Discussion

In the present study, we found an increase in MVD associated with dysplastic lesions, concomitantly with a rise in the expression of the angiogenic factor VEGF. These data, together with the increased proliferation of ECs in dysplastic lesions, would indicate that the angiogenic switch precedes tumor development in the HCP and that the switch would thus appear to occur in the dysplastic stage.

ECs in quiescent tissues divide approximately once every two to three years if unstimulated (38). During cancer development, it is well established that the local tissue level of the proangiogenic factor VEGF increases and enhances proliferation of vascular ECs and the sprouting of new blood vessels from pre-existing vascular beds (2). The present study showed an increase in vascular density in dysplasia, associated with an increase in the proliferation of ECs and an increase in VEGF expression in potentially malignant tissue. Conversely, Denhart *et al.* (39), found that normal or mildly dysplastic oral epithelium expressed no VEGF, whilst moderately dysplastic epithelium had a low level of VEGF expression. Carlile *et al.* (12) found no difference between VEGF expression in normal oral mucosa when compared to epithelial dysplasia, indicating that any increase in dysplasia is not accompanied by an increase in VEGF expression. In potentially malignant tissue in the HCP, the increase in VEGF probably favors the proliferation of ECs and an increase in vascular density. In our study, in carcinomas, vascular density did not rise, VEGF expression decreased and EC proliferation was similar to that of dysplasia but did not increase further. This would indicate that in tumor in the HCP, the role of proangiogenic factors is no longer pivotal since ECs would proliferate in response to factors of the tumor microenvironment.

In the HCP, a mild inflammatory reaction takes place in the first days of topical application of the carcinogen. After this, there is no inflammatory process in the pouch and therefore none of the epithelial and connective tissue changes observed in the present analysis are related to inflammatory response.

It is a fact that blood vessels undergo distinct architectural alterations during neoplastic progression (22). These alterations include classic angiogenic changes in EC proliferation, and in vessel diameter, density, and leakage (23). Hagendoorn *et al.* revealed alterations in blood vasculature, architectural changes, and impairment of lymphatic vessels along with increased interstitial fluid pressure in premalignant tissues (22). Our data for the HCP indicate that during squamous carcinogenesis, the blood vessels underlying dysplastic lesions exhibit an increase in density and perimeter, suggesting that the blood flow that reaches the tissue that is on the verge of developing into tumor is greater than in normal tissue. In addition, the blood vessels underlying dysplasia and the vessels of tumor stroma exhibited an increase in area and perimeter, as well as an evident compression, which would correlate with reduced and altered vascular perfusion (22). The presence of vessels with collapsed lumens, or with a tangled, disorderly, glomerular-like pattern in tumors would suggest inadequate perfusion and poor tumor tissue nutrition. There is enough evidence in the literature of the increase in vascularity in carcinomas and potentially malignant disorders of human oral mucosa (40-46, 19). Knowledge of

the angiogenic activity of a potentially malignant lesion of the epithelium is clinically relevant within the context of the biological behaviour of these epithelia. Gandolfo *et al.* reported that leukoplakia exhibited an increase in VEGF expression and in sub-epithelial vascularization (19). This increase was significantly greater in leukoplakia with dysplastic changes than in leukoplakia without dysplasia. The epithelia of leukoplakia without dysplasia can remain as such for a long time, less frequently reverting to a normal epithelium or, much less frequently, evolving towards more aggressive lesions. However, dysplastic lesions are considered to have a higher risk of malignant transformation. This issue is of direct practical value for the evaluation of lesion prognosis.

The vascular changes that take place during HCP carcinogenesis have been observed in different experimental contexts (29-31). However, to date, a characterization of the sequence and degree of those changes throughout the process of carcinogenesis was lacking. The knowledge of these changes is essential when the model is used to assess anti-angiogenic therapies. In our laboratory in particular, this knowledge has been pivotal in studying the effect of boron neutron capture therapy (BNCT) on the vasculature of pre-malignant and malignant tissues in the HCP. BNCT is a binary cancer treatment modality that combines irradiation with a thermal or epithermal neutron beam with boron-10 carriers that are taken up preferentially by neoplastic cells. High linear energy transfer alpha particles and recoiling  ${}^7\text{Li}$  nuclei are emitted during the capture reaction. These particles have a range of 5-9  $\mu\text{m}$  in tissue and are known to have a high relative biological effectiveness. In this way, BNCT potentially targets tumor tissue selectively, mostly sparing normal tissue (47)

In addition, the characterization of vascular changes throughout the process of carcinogenesis is necessary for other studies-in-progress at our laboratory that involve tumor blood vessel 'normalization' in order to improve the efficacy of BNCT. Certain anti-angiogenic agents, mostly anti-VEGF agents, can transiently 'normalize' the abnormal structure and function of tumor vasculature to make it more efficient for oxygen and drug delivery. Drugs that induce vascular normalization can alleviate hypoxia and increase the efficacy of conventional therapies if both are carefully scheduled (48). If one were to judiciously down-regulate VEGF signaling in tumors, then the vasculature might revert back to a more 'normal' state. Indeed, blockade of VEGF signaling passively prunes the immature and leaky vessels of transplanted tumors in mice and actively remodels the remaining vasculature so that it more closely resembles the normal vasculature. This 'normalized' vasculature is characterized by less leaky, less dilated, and less tortuous vessels, with a more normal basement membrane and greater coverage by pericytes. These morphological changes are

accompanied by functional changes, such as lower interstitial fluid pressure, increased tumor oxygenation, and improved penetration of drugs in these tumors (48).

It is known that for BNCT to be effective, boron targeting of all tumor cells is pivotal and tumor blood vessel normalization improves drug delivery to tumors in the HCP (49). Within this context, tumor blood vessel normalization would improve tumor boron targeting and subsequently, BNCT efficacy.

### Conflicts of Interest

The Authors state there are no conflicts of interest.

### Acknowledgements

The Authors wish to acknowledge the generous advice of Dr. Sandra Renou and Dr. María Luisa Paparella on image acquisition and measurements.

This study was supported in part by grants from the National Agency for the Promotion of Science and Technology of Argentina, the National Research Council (CONICET) and the University of Buenos Aires.

### References

- Folkman J, Watson K, Ingber D and Hanahan D: Induction of angiogenesis during the transition from hyperplasia to neoplasia. *Nature* 339: 58-61, 1989.
- Bergers G and Benjamin LE: Tumorigenesis and the angiogenic switch. *Review. Nat Rev Cancer* 3(6): 401-410, 2003.
- Hanahan D and Folkman J: Patterns and emerging mechanisms of the angiogenic switch during tumorigenesis. *J Cell* 86: 353-364, 1996.
- Carmeliet P and Jain RK: Angiogenesis in cancer and other diseases. *Nature* 407(6801): 249-257, 2000.
- Bergers G and Benjamin LE: Tumorigenesis and the angiogenic switch. *Nature Reviews Cancer* 3: 401-410, 2003.
- Bergers G, Hannahan D and Coussens LM: Angiogenesis and apoptosis are cellular parameters of neoplastic progression in transgenic mouse models of tumorigenesis. *Int J Dev Biol* 42: 995-1002, 1998.
- Leung DW, Cachianes G, Kuang WJ, Goeddel DV and Ferrara N: Vascular endothelial growth factor is a secreted angiogenic mitogen. *Science* 246: 1306-1309, 1989.
- Shibuya M. Vascular endothelial growth factor-dependent and independent regulation of angiogenesis. *Mini review. Biochemistry and Molecular Biology Reports* 41(4): 278-286, 2008.
- Korpelainen EI, Karkkainen MJ, Tenhunen A, Lakso M, Rauvala H, Vierula M, Parvinen M and Alitalo K: Overexpression of VEGF in testis and epididymis causes infertility in transgenic mice: evidence for nonendothelial targets for VEGF. *J Cell Biol* 143(6): 1705-1712, 1998.
- Niida S, Kaku M, Amano H, Yoshida H, Kataoka H, Nishikawa S, Tanne K, Maeda N, Nishikawa S and Kodama H: Vascular endothelial growth factor can substitute for macrophage colony-stimulating factor in the support of osteoclastic bone resorption. *J Exp Med* 190(2): 293-298, 1999.
- Johnstone S and Logan RM: The role of vascular endothelial growth factor (VEGF) in oral dysplasia and oral squamous cell carcinoma. *Oral Oncol* 42: 337-342, 2006.
- Carlile J, Harada K, Baillie R, Macluskey M, Chisholm DM, Ogden GR, Schor SL and Schor AM: Vascular endothelial growth factor (VEGF) expression in oral tissues: possible relevance to angiogenesis, tumour progression and field cancerisation. *J Oral Pathol Med* 30(8): 449-457, 2001.
- Speight PM and Morgan PR: The natural history and pathology of oral cancer and precancer. *Commun Dent Health* 10(Suppl 1): 31-41, 1993.
- Moriyama M, Kumagai S, Kawashiri S, Kojima K, Kakihara K and Yamamoto E: Immunohistochemical study of tumour angiogenesis in oral squamous cell carcinoma. *Oral Oncol* 33(5): 369-374, 1997.
- Wong YK, Liu CJ, Kwan PC and Chao SY: Microvascular density and vascular endothelial growth factor immunoreactivity as predictors of regional lymph node metastasis from betel-associated oral squamous cell carcinoma. *J Oral Maxillofac Surg* 61(11): 1257-1262, 2003.
- Chen YJ, Jin YT, Shieh DB, Tsai ST and Wu LW: Molecular characterization of angiogenic properties of human oral squamous cell carcinoma cells. *Oral Oncol* 38(7): 699-705, 2002.
- Shintani S, Li C, Ishikawa T, Mihara M, Nakashiro K and Hamakawa H: Expression of vascular endothelial growth factor A, B, C, and D in oral squamous cell carcinoma. *Oral Oncol* 40(1): 13-20, 2004.
- Shang ZJ and Li JR: Expression of endothelial nitric oxide synthase and vascular endothelial growth factor in oral squamous cell carcinoma: its correlation with angiogenesis and disease progression. *J Oral Pathol Med* 34 (3): 134-139, 2005;.
- Gandolfo M, Keszler A, Lanfranchi H and Itoiz ME: Increased subepithelial vascularization and VEGF expression reveal potentially malignant changes in human oral mucosa lesions. *Oral Surg Oral Med Oral Pathol Oral Rad and Endodontol* 111: 486-493, 2011.
- Folkman J: Angiogenesis in cancer, vascular, rheumatoid and other disease. *Nat Med* 1: 27-31, 1995.
- Eichten A, Hyun WC and Coussens LM: Distinctive features of angiogenesis and lymphangiogenesis determine their functionality during de novo tumor development. *Cancer Res* 67(11): 5211-5220, 2007.
- Hagendoorn J, Tong R, Fukumura D, Lin Q, Lobo J, Padera TP, Xu L, Kucheralapati R and Jain LK: Onset of abnormal blood lymphatic vessel function and interstitial hypertension in early stages of carcinogenesis. *Cancer Res* 66(7): 3360-3364, 2006.
- Mc Donald DM and Baluk P: Significance of blood vessel leakiness in cancer. *Cancer Res* 62: 5381-5385, 2002.
- Chang YS, Di Tomaso E, McDonald DM, Jones R, Jain RK and Munn LL: Mosaic blood vessels in tumors: frequency of cancer cells in contact with flowing blood. *Proc Natl Acad Sci USA* 97(26): 14608-14613, 2000.
- Salley JJ: Experimental carcinogenesis in the cheek pouch of the Syrian hamster. *J Dent Res* 33: 253-262, 1954.
- Morris L: Factors influencing experimental carcinogenesis in the hamster cheek pouch. *J Dent Res* 40: 3-15, 1961.
- Shklar G, Eisenberg E and Flynn E: Immunoenhancing agents and experimental leukoplakia and carcinoma of the hamster buccal pouch. *Prog Exp Tumor Res* 24: 269-282, 1979.

- 28 Slaughter DP, Southwick HW and Smejkal W: Field cancerization in oral stratified squamous epithelium; clinical implications of multicentric origin. *Cancer* 6(5): 963-968, 1953.
- 29 Raimondi AR, Molinolo AA and Itoiz ME: Fibroblast growth factor-2 expression during experimental oral carcinogenesis. Its possible role in the induction of pre-malignant fibrosis. *J Oral Pathol Med* 35(4): 212-217, 2006.
- 30 Nagini S and Letchoumy PV: Of humans and hamsters: a comparative evaluation of carcinogen activation, DNA damage, cell proliferation, apoptosis, invasion, and angiogenesis in oral cancer patients and hamster buccal pouch carcinomas. *Oral Oncol* 45(6): 31-37, 2009.
- 31 Lopes NN, Plapler H, Chavantes MC, Lalla RV, Yoshimura EM and Alves MT: Cyclooxygenase-2 and vascular endothelial growth factor expression in 5-fluorouracil-induced oral mucositis in hamsters: evaluation of two low-intensity laser protocols. *Support Care Cancer* 17(11): 1409-1415, 2009.
- 32 Sternberg LA, Hardy PH, Cuculis JJ and Meyer HG: The unlabeled antibody enzyme method of immunohistochemistry. Preparation and properties of soluble antigen-antibody complex (horseradish peroxidase) and its use in identification of spirochetes. *J Histochem Cytochem* 18: 315-330, 1970.
- 33 Aromando RF, Pérez MA, Heber EM, Trivillin VA, Tomasi VH, Schwint AE and Itoiz ME: Potential role of mast cells in hamster cheek pouch carcinogenesis. *Oral Oncol* 44(11): 1080-1087, 2008.
- 34 Heber EM, Aromando RF, Trivillin VA, Itoiz ME, Nigg DW, Kreimann EL and Schwint AE: Therapeutic effect of boron neutron capture therapy (BNCT) on field cancerized tissue: inhibition of DNA synthesis and lag in the development of second primary tumors in precancerous tissue around treated tumors in DMBA-induced carcinogenesis in the hamster cheek pouch oral cancer model. *Arch Oral Biol* 52(3): 273-279, 2007.
- 35 Tonar Z, Egger GF, Witter K and Wolfesberger B: Quantification of microvessels in canine lymph nodes. *Microscopy Research and Technique* 71: 760-772, 2008.
- 36 Maeda T, Matsumura S, Hiranuma H, Jikko A, Furukawa S, Ishida T and Fuchihata H: Expression of vascular endothelial growth factor in human oral squamous cell carcinoma: its association with tumour progression and p53 gene status. *J Clin Pathol* 51: 771-775, 1998.
- 37 Padera TP, Stoll BR, Tooredman JB, Capen D, Di Tomaso E and Jain RK: Pathology: cancer cells compress intratumour vessels. *Nature* 427(6976): 695, 2006.
- 38 Hirst DG, Denekamp J and Hobson B: Proliferation studies of the endothelial and smooth muscle cells of the mouse mesentery after irradiation. *Cell Tissue Kinet* 13: 91-104, 1980.
- 39 Denhart BC, Guidi AJ, Tognazzi K, Dvorak HF and Brown LF: Vascular permeability factor/vascular endothelial growth factor and its receptors in oral and laryngeal squamous cell carcinoma and dysplasia. *Lab Invest* 77(6): 659-664, 1997.
- 40 Hasina R AND Linggen MW: Angiogenesis in oral cancer. *J Dent Educ* 65: 1282-1290, 2001.
- 41 Williams JK, Carlson GW, Cohen C, Derosé PB, Hunter S and Jurkiewicz MJ: Tumor angiogenesis as a prognostic factor in oral cavity tumors. *Am J Surg* 168: 373-380, 1994.
- 42 Li C, Shintani S, Terakado N, Klosek SK, Ishikawa T, Nakashiro K and Hamakawa H: Microvessel density and expression of vascular endothelial growth factor, basic fibroblast growth factor, and platelet derived endothelial growth factor in oral squamous cell carcinomas. *Int J Oral Maxillofac Surg* 34: 559-565, 2005.
- 43 Gleich LL, Biddinger PW, Paveli ZP and Gluckman JL: Tumor angiogenesis in T1 oral cavity squamous cell carcinoma: role in predicting tumor aggressiveness. *Head Neck* 18: 343-346, 1996.
- 44 Moriyama M, Kumagai S, Kawashiri S, Kojima K, Kakihara K and Yamamoto E: Immunohistochemical study of tumor angiogenesis in oral squamous cell carcinoma. *Oral Oncol* 33: 369-374, 1997.
- 45 Tipoe GL, Jin Y and White FH: The relationship between vascularity and cell proliferation in human normal and pathological lesions of the oral cheek epithelium. *Eur J Cancer* 32B: 24-31, 1996.
- 46 Macluskey M, Chandrachud LM, Pazouki S, Green M, Chisholm DM, Ogden GR, Schor SL and Schor AM: Apoptosis, proliferation and angiogenesis in oral tissues. Possible relevance to tumour progression. *J Pathol* 191: 368-375, 2000.
- 47 Coderre JA and Morris GM: The radiation biology of boron neutron capture therapy. *Radiat Res* 151: 1-18, 1999.
- 48 Jain RK: Normalization of tumor vasculature: an emerging concept in antiangiogenic therapy. *Review. Science* 307(5706): 58-62, 2005.
- 49 Molinari AJ, Pozzi ECC, Monti Hughes A, Heber EM, Garabalino MA, Thorp SI, Miller M, Itoiz ME, Aromando RF, Nigg DW, Trivillin VA and Schwint AE: Tumor Blood Vessel "Normalization" Improves the Therapeutic Efficacy of Boron Neutron Capture Therapy (BNCT) in Experimental Oral Cancer. *Rad Res* 177: 59-68, 2012.

Received June 18, 2014

Revised August 9, 2014

Accepted August 19, 2014