Pediatr Nephrol (2008) 23:559–567
DOI 10.1007/s00467-007-0727-4

ORIGINAL ARTICLE

Development of an experimental hemolytic uremic syndrome in rats

Elsa Zotta · Nestor Lago · Federico Ochoa · Horacio A. Repetto · Cristina Ibarra

Received: 30 July 2007 / Revised: 15 November 2007 / Accepted: 4 December 2007 / Published online: 6 February 2008

Abstract *Escherichia coli* strains producing Shiga toxins (Stxs) colonize the lower gastrointestinal tract and cause watery diarrhea, hemorrhagic colitis, and hemolytic-uremic syndrome (HUS). HUS is characterized by hemolytic anemia, thrombocytopenia, and acute renal failure. Oliguria associated with acute tubular necrosis and microangiopathic thrombosis has been reported as the most common cause of renal failure in Argentinean children. Our study was undertaken to obtain a model of HUS in rats that was similar to the clinical and renal histopathology findings described in humans. Rats were intraperitoneally inoculated with culture supernatant from recombinant *E. coli* expressing Stx2. Glomerular filtrate volume evaluated from clearance of creatinine resulted in a progressive reduction (from 53% at 24 h to 90% at 48 h). Urine volume increased significantly at 24 h but returned to normal levels at 48 h. Evidence of thrombocytopenia, anemia and leukocytosis was documented. Macroscopic analysis revealed a hyperemic peritoneal face with intestinal water accumulation. The kidneys were friable and congestive. Histopathological analysis showed glomerular and tubular necrosis as well as microangiopathic thrombosis. Our findings indicated vascular damage and kidney lesions similar to those described in humans with HUS.

Keywords Hemolytic uremic syndrome · Acute tubular necrosis · Thrombotic microangiopathy · Shiga toxin · Diarrhea

E. Zotta · F. Ochoa · C. Ibarra
Laboratorio de Fisiopatogenia, Depto de Fisiología,
Facultad de Medicina, Universidad de Buenos Aires,
Buenos Aires, Argentina

N. Lago
Laboratorio de Patología Experimental, Depto de Patología,
Facultad de Medicina, Universidad de Buenos Aires,
Buenos Aires, Argentina

H. A. Repetto
Servicio de Pediatría, Hospital Nacional Prof. Alejandro Posadas,
Buenos Aires, Argentina

C. Ibarra (✉)
Depto de Fisiología, Facultad de Medicina,
Paraguay 2155, 7mo piso,
CP 1121 Buenos Aires, Argentina
e-mail: ibarra@fmed.uba.ar

Introduction

Shiga toxin (Stx)-producing *Escherichia coli* (STEC) colonize the distal small intestine and colon and cause a spectrum of disorders, including watery diarrhea, hemorrhagic colitis, and hemolytic–uremic syndrome (HUS) [1]. HUS is a disease defined by thrombotic microangiopathy, hemolytic anemia, thrombocytopenia, and acute renal failure. HUS develops in 10%–15% of small children several days after bloody diarrhea and is the most common cause of acute renal failure in infants in Argentina [2]. The evolution of the disease is variable. The signs of bad prognosis are prolonged anuria or oliguria (longer than 10 days) and persistence of hypertension and proteinuria for 1 year subsequent to an episode of HUS [3–6]. Differently, in patients in whom HUS has a satisfactory course, renal function begins to improve in the second or third week. This improvement is progressive and usually extends for a period of 12 to 18 months, with a slow return to normal renal function. It has also been observed that approximately 10% of Argentinean patients with HUS present polyuria at the onset of the disease as a consequence of tubular, but not glomerular, damage (H.A. Repetto, personal communication of a review of 104 patients in the Hospital Nacional "Prof. A. Posadas", Buenos Aires, Argentina, 2007). Polyuria has also been reported in a case of

HUS following *E. coli* O157: H7 infection in a 67-year-old woman. This patient presented polyuria in the early stages of the disease, with urine output reduced to less than 500 ml on the second day of hospitalization [7]. Approximately 2–4% of patients die during the acute phase, and one-third of the 96% who survive is at risk of having chronic sequelae [3, 8]. Up to now there has not been a specific treatment, and care during the acute phase of the illness is merely supportive.

E. coli serogroup O157 bacteria expressing both Stx1 and Stx2 are the microorganisms most frequently isolated from children with HUS, although strains that express only Stx2 are highly prevalent in Argentina [9, 10]. The commonest source of infection is badly cooked meat [11], although a variety of food vehicles has been linked to STEC infections, including sausages, lettuce, cabbage, alfalfa sprouts and unpasteurized juices and milk [12]. Person-to-person transmission has also been identified in Argentina [13].

Stxs participate in the pathogenesis of post-diarrheal HUS, but the factors that modulate renal response are not well understood.

Induction of experimental HUS to study the renal pathogenesis by simply administering Stxs to rodents has not yet been successful. The administration of Stxs to rabbits and mice is associated with acute tubular necrosis, but the glomerular lesions characteristic of HUS are not observed [14]. Intravenous inoculation of Stx2 to rats leads to renal injury similar to that in mice and is associated with polyuria [15, 16]. Recently, a murine model of HUS using intraperitoneal co-injection of purified Stx2 plus lipopolysaccharide (LPS) showed thrombocytopenia, hemolytic anemia, and renal failure [17]. It has been reported that LPS/endotoxin, which is a major inflammatory mediator produced by gram-negative bacteria, is an important factor in the development of the disease [18]. However, the role of LPS depends on the timing of administration and the proper order. Siegler et al. [19] established a primate model of HUS by co-administration of Stx1 and LPS in different doses. Palermo et al. [20] reported that pretreatment of mice with LPS is able not only to attenuate but also to enhance Stx2 lethality. On the other hand, Louise and Obrig [21] have proposed that LPS might combine with Stx to facilitate the vascular damage characteristic of HUS.

Our study showed that intraperitoneal injection of culture supernatant from recombinant *E. coli* containing Stx2 to rats leads to the development of watery diarrhea, hemolytic anemia, thrombocytopenia, leukocytosis, and kidney lesions similar to those described in humans with HUS.

Materials and methods

Adult male Sprague-Dawley rats weighing 150–250 g were obtained from the animal facility at the School of Pharmacy and Biochemistry, University of Buenos Aires, Argentina. The rats were individually housed under controlled conditions of illumination, humidity, and temperature, with food and water being available ad libitum. Animals were allowed a minimum of 7 days to adapt to housing conditions before undergoing any manipulation.

Determination of Stx2 cytotoxic dose in Vero cells

Recombinant *E. coli* culture containing Stx2 was obtained by incubation overnight at 37°C with shaking at 200 r.p.m. in 5 ml of Luria-Bertani (LB) broth (Difco Laboratories) supplemented with 100 μg/ml ampicillin (Sigma Aldrich Co.). Bacterial cells were then removed by centrifugation, and the resultant supernatant (sStx2) was filtered through 0.22 μm pore size filter units (Millipore Corp.) and assayed for toxicity to Vero cells as previously described [13]. The 50% cytotoxic dose (CD_{50}) corresponds to the dilution required to kill 50% of Vero cells. Stx2 cytotoxicity in culture supernatant from the recombinant *E. coli* (sStx2) was approximately 2×10^6 CD_{50}/ml (1 CD_{50}=0.4 pg/ml). Culture supernatant from recombinant *E. coli* was checked for endotoxin contamination by the Limulus amoebocyte lysate assay (Sigma Aldrich Co.), given that 1 EU/ml is equal to 0.1 ng/ml of United States Pharmacopeia standard *E. coli* endotoxin [22]. Culture supernatant contained less than 40 pg LPS/μg of Stx2 protein.

Determination of lethal dose

Rats were randomly divided into eight groups (n=4 per group). Groups 1 to 4 were injected intraperitoneally with 1 ml to 4 ml of sStx2, and groups 5 to 8 with the same volume of supernatant from *E. coli* DH5α that did not contain Stx2 (sControl). The rats were individually housed under controlled conditions of illumination, humidity, and temperature, with food and water being available ad libitum.

In vivo lethality of sStx2 was evaluated by intraperitoneal injection of serial dose of sStx2 (1–4 ml). The dose corresponding to 3 ml (approximately 20 μg/kg), which induced a mortality of 50% between 48 h and 72 h after injection, was selected. The doses used in the others animal models was variable. The 50% lethal dose (LD_{50}) was found to be 12.5 ng/kg to 225 ng/kg in mice [17, 20], whereas, in rabbits, it was found to be 884 ng/kg [23]. The cytotoxic dose of pure Stx2 in cell culture was found to be 100 ng/ml [18, 24]. We have previously found that sStx2 containing 16 ng/ml of toxin elicits fluid accumulation in rat colon loops [25].

Experiment protocol

Male Sprague-Dawley rats (250±1 g body weight) were randomly divided into two groups of six rats each. One

Table 1 General and renal parameters in rats treated with Stx2. Urine, water intake and creatinine clearance were measured 24 h and 48 h after administration of culture supernatant either containing or not containing Stx2. Data are expressed as mean ± SE of six or ten experiments. *Numbers in parentheses* indicate number of experiments

Parameter	Control group		Experimental group	
Time	24 h	48 h	24 h	48 h
Body weight (g)	251±4 (6)	245±8 (6)	257±5 (6)	192±4* (6)
Food intake (g)	11.9±0.4 (6)	12.3±0.5 (6)	9.5±0.6 (6)	7.4±0.8* (6)
Water intake (ml/day)	42.1±1 (6)	43.0±2.0 (6)	57.9±8.9* (6)	20.5±0.1* (6)
Urine volume (ml/day)	25.1±4.0 (6)	19.1±1.8 (6)	39.2±1.0* (6)	13.0±3.0 (6)
Plasma creatinine (μmol/l)	41±2 (6)	43±2 (10)	98±2* (6)	124±1* (10)
Plasma urea (mmol/l)	6.1±0.2 (6)	6.4±0.3 (10)	24.0±2.0* (6)	31.0±2.0* (10)
Creatinine clearance (ml/min)	1.0±0.2 (6)	1.1±0.2 (6)	0.53±0.01* (6)	0.10±0.02* (6)

*$P<0.01$ versus control group

group was injected with 3 ml, corresponding to 1 LD_{50} of sStx2 (experimental group) and the other group was injected with 3 ml of sControl (control group). Both groups were kept in metabolic cages for 48 h with free access to water and food and under controlled light/dark cycle and temperature. Prior to killing the rats we obtained urine and blood samples. Then, the rats were anesthetized (100 μg ketamine and 10 μg diazepam per gram of body weight, intraperitoneally) and perfused with 4% paraformaldehyde. The kidneys and distal colon were removed, and the tissues were fixed in 10% neutral formalin.

Physiological parameters

Urea and creatinine concentrations in plasma and urine were measured with commercial kits (Wierner Lab, Argentina). Creatinine and urine volume values were used to calculate creatinine clearance (C_{cr}) as a measure of glomerular filtrate volume. The blood parameters were studied by standard methods.

Light microscopy and immunohistochemistry

The kidneys and the colon were quickly extracted and fixed for 48 h in formol buffer 10% in phosphate-buffered saline (PBS) 0.1 M (pH 7.4). The tissue sections were dehydrated and embedded in paraffin. Sections of 5 μm were made with a microtome (Leica RM 2125, Wetzlar, Germany) and mounted on 2% silane-coated slides.

The sections were stained with hematoxylin–eosin, phosphotungstic acid hematoxylin or Jones methenamine silver (JMS) stain, and observed by light microscopy (Nikon Eclipse 2000, NY, USA). For immunohistochemistry studies, the samples were blocked of endogenous peroxidase with hydrogen peroxide (H_2O_2) 0.3% for 10 min. Later, the slides were pre-incubated with nonimmune rabbit serum diluted in PBS (1:100) in a humidity chamber at room temperature for 30 min and incubated with monoclonal anti-verotoxin II (Biodesign International, Maine, USA) directed against the A (slt-2a) or the B (slt-2b) subunits of Stx2. The antibodies were diluted 1:50 in PBS and incubated in a humidity chamber at 4°C overnight. The immunoperoxidase technique was then performed following the protocol for the RTU Vectastain kit (Vector, Peterborough, UK). The antigen was revealed by diaminobenzidine (DAB, Vector). Finally, the sections were dehydrated and mounted for observation.

Statistical analysis

All data are presented as mean ± SEM; n = the number of rats. We used analysis of variance (ANOVA) with the Tukey–Kramer multiple comparisons post-hoc test in GraphPad in Stat version 3.6 to test statistical differences between experimental and control groups. The criterion for statistical significance was $P<0.05$.

Results

1. Physiological parameters

A significant increase in concentrations of both plasma urea and creatinine was observed in the experimental group compared with the control group (Table 1). The urine volume had increased significantly at 24 h, in parallel with an increase in water intake, but it had returned to normal levels at 48 h, associated with a decrease in water and food intake and body weight (Table 1). Volume of glomerular filtrate evaluated from clearance of creatinine (C_{creat}) resulted in a progressive reduction of 53% at 24 h to 90% at 48 h. Evidence of thrombocytopenia, hemolytic anemia and leukocytosis was observed (Table 2). Concentration of plasma lactate dehydrogenase (LDH), used as a marker of intravascular hemolysis, showed a significant increase (Table 2).

Table 2 Blood parameters in rats treated with Stx2. Blood parameters were measured 48 h after administration of culture supernatant either containing or not containing Stx2. Data are expressed as mean ± SE of four or ten experiments. *Numbers in parentheses* indicate number of experiments

Parameter	Control group	Experimental group
Platelets number ($\times 10^9$/l)	84±0.2 (10)	33±0.3* (10)
Leukocytes number ($\times 10^9$/l)	7.3±0.1 (10)	11.2±0.2* (10)
Hemoglobin (mg/100 ml)	14.5±1.3 (10)	9.7±2.0* (10)
Hematocrit (%)	41.3±2.6 (10)	21±5* (10)
LDH (U/l)	308±102 (4)	9736±95* (4)

*$P<0.01$ experimental versus control group, *LDH* lactate dehydrogenase

2. Macroscopic studies

The experimental group exhibited abdominal distention with watery rectal discharge. When opening the abdominal cavity, we observed peritoneum congestion and marked distension of small and large intestine associated with fluid accumulated in the lumen (Fig. 1). Examination of kidneys revealed congestion at the corticomedullary junction.

3. Histological studies

Histological changes in the kidney tissues from the experimental group were examined by light microscopy (Fig. 2). Extensive necrotic glomerular areas with loss of capillary loops were observed. Severe tubular injuries, such as patchy loss of tubular epithelial cells with exposure of denuded basement membrane, desquamation, cytoplasmic vacuolation, pyknosis, and loss of nuclei, were also observed (Fig. 2a). We observed capillary wall thickening from expansion of the subendothelial zone, with glomerular basal membrane wrinkling with the presence of double basal membrane and areas of mesangiolysis in isolated glomeruli by the JMS stain technique (Fig. 2b). Phosphotungstic acid–hematoxylin was used to investigate the appearance of thrombotic microangiopathy. The staining showed the presence of fibrin thrombi in the glomerular capillary lumen and in the urinary space (Fig. 2c). These abnormalities were not found in the kidneys of the control groups (Fig. 2d).

The immunohistochemistry technique revealed the presence of Stx2 in the renal tubules and glomeruli of the experimental group (Fig. 3). Staining was found in the cytoplasm and basal membranes of tubular epithelial cells (Fig. 3a,b), and in the glomerular mesangium (Fig. 3c), while it was not found in the kidneys of the control group (Fig. 3d). Figure 4 shows the histological changes in the distal colon. A noticeable vascular congestion in both the serosa (Fig 4a) and the submucosa (Fig. 4b) was detected. Swelling in enterocytes from colonic crypts and loss of goblet cells were also observed (Fig. 4b and 5a). No change was detected in enterocytes from the colonic surface (Fig. 4c). The histological structure of the distal colon was conserved in the control group (Fig. 4d and 5b).

The immunohistochemistry technique showed binding of Stx2 in the distal colon of the experimental group (Fig 6). The label was observed in the lower third of colonic crypts (Fig 6a,b) and isolated cells in the lamina propria (Fig 6d). Close to these areas the mucosa showed non-specific lesion and focal loss of goblet cells (Fig. 6c).

Discussion

In our study, we developed an experimental HUS model in rats by intraperitoneal inoculation of culture supernatant from recombinant *E. coli* expressing Stx2. The principal findings were thrombocytopenia and hemolytic anemia caused by vascular damage, renal failure caused by glomerular and tubular injury, and watery diarrhea caused by damage to the colonic mucosa.

In this study, Stx2 entered the organism intraperitoneally and arrived at the colon by circulation. We found vascular congestion in the intestinal serosa and peritoneum, and marked damage in colonic crypts but not in superficial epithelium. Although the binding sites for Stxs on the

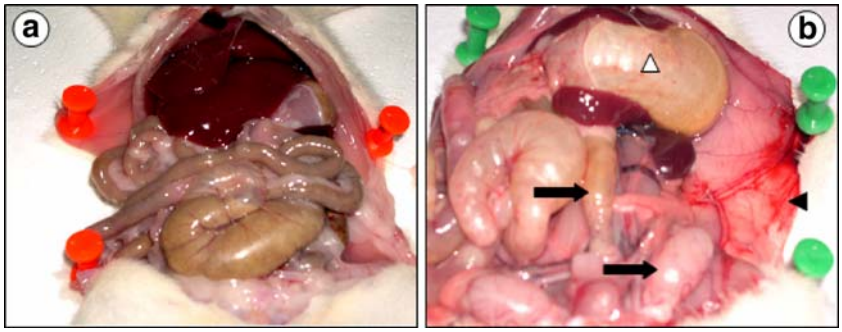

Fig. 1 Macroscopic evaluation of abdominal cavity in the experimental group (**b**) compared with the control group (**a**). Marked distension of the stomach (*white arrowhead*) and the small and large intestines (*black arrows in **b***) by the presence of luminal serous liquid are observed. Marked congestion in the peritoneal surface is also observed (*black arrowhead in **b***)

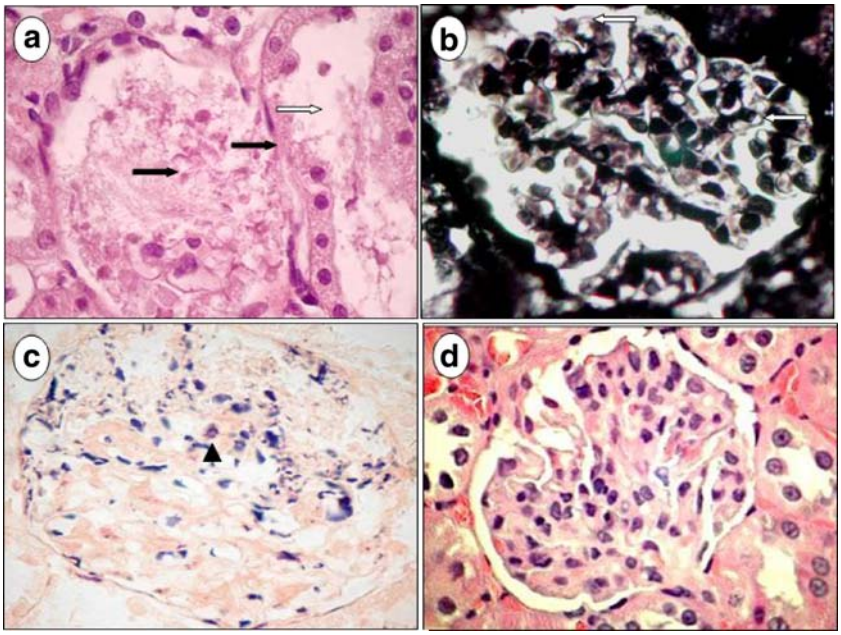

Fig. 2 Histological changes in kidney tissue from the experimental group observed by light microscopy. Necrotic areas in glomeruli and tubules (*black arrows in **a***), tubular dilation (*white arrow in **a***), patchy loss of tubular epithelial cells with exposure of denuded basement membrane are observed (*white arrow in **a***; hematoxylin–eosin). Capillary wall thickening with glomerular basal membrane wrinkling (*white arrows in **b***; JMS) and presence of fibrin thrombi within capillary lumen are also observed (*black arrowhead in **c***; phosphotungstic acid hematoxylin). Normal glomeruli and tubules are observed in the control group (***d***; hematoxylin-eosin). ×1,000

intestinal epithelium have not been well characterized, different Stx binding patterns have been reported [26–28]. In agreement with those data, our data showed that the Stx2 binding pattern was restricted to the distal colonic epithelium. Stx2 was bound to the lower third of distal colonic crypts close to the areas that contained swelling in the enterocytes and focal loss of goblet cells. Since crypts are related to water secretion, fluid accumulated in the intestinal lumen could be the consequence of the alteration of normal water absorption to secretion. However, our model failed to explain bloody diarrhea as observed in HUS patients, because it bypassed the enteric colitis phase of the

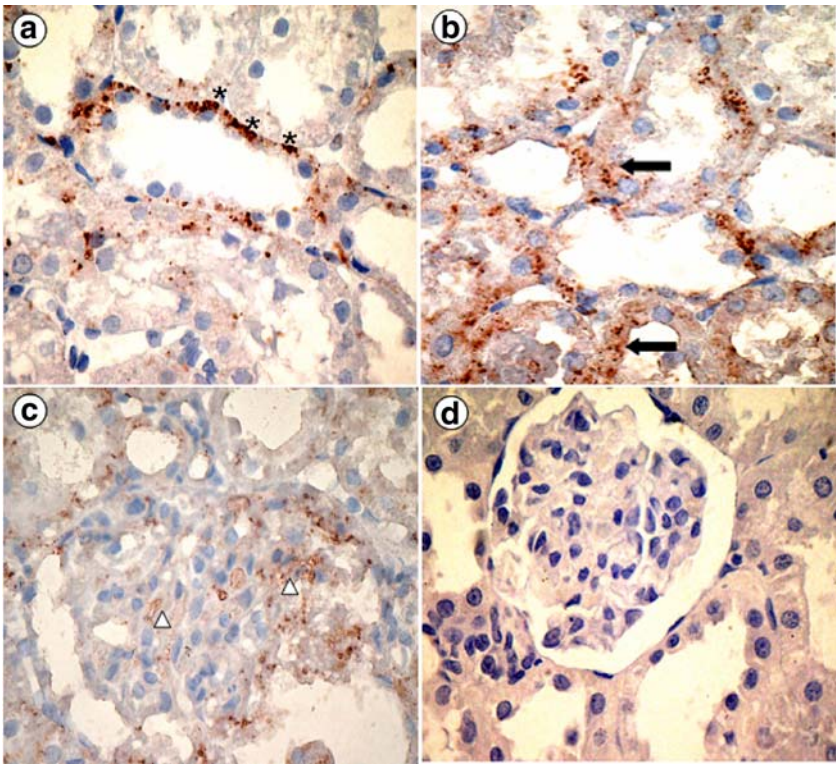

Fig. 3 Stx2 immunoperoxidase staining in kidney. Stx2 is present in the basolateral membranes (*asterisks in **a***) and cytoplasm (*black arrows in **b***) of renal tubules from the experimental group. Glomerular mesangium is also labeled (*white arrowheads in **c***). No staining is observed in the control group (***d***). ×1,000

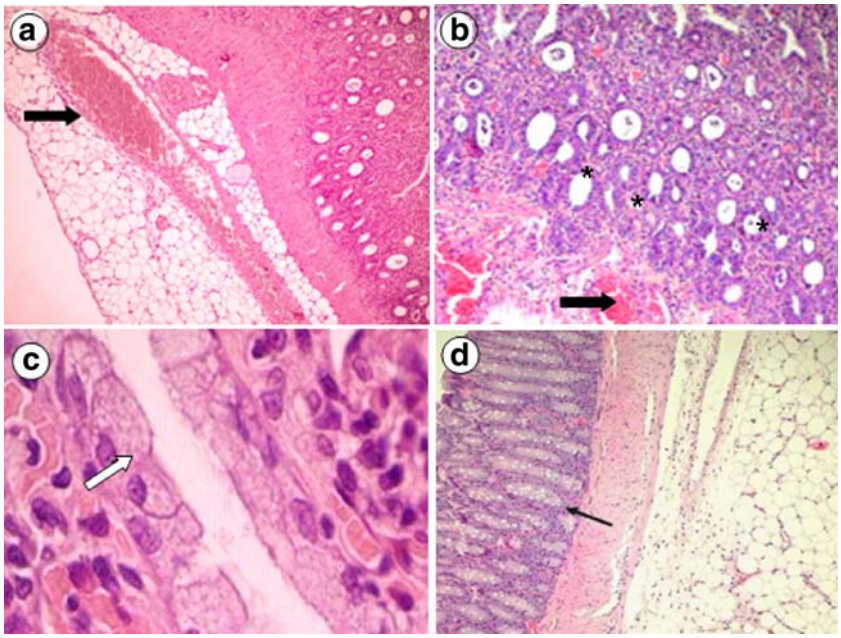

Fig. 4 Histological changes in the distal colon of the experimental group examined by light microscopy. Strong vascular congestion in serosa and submucosa is observed (*black arrow in **a** and **b***). Swelling in enterocytes from colonic crypts and loss of goblet cells (*asterisks in **b***). Superficial epithelium is conserved (*white arrow in **c***). Normal colonic crypts in the control group is shown (*small black arrow in **d***). Hematoxylin–eosin staining. **a, d** ×40, **b** ×100, **c** ×1,000

disease. Neither endothelial and smooth muscle cells nor serosa and peritoneum presented Stx2 binding as reported in other animal models where Stx is in contact with the intestine from the mucosal side [29].

An important hallmark of the pathogenesis of post-diarrheal HUS is the development of acute renal failure, although the mechanisms by which the toxin causes the disease need to be clarified. Different animal models of HUS have been developed to reproduce the complete clinical presentation of the human HUS. However, induction of experimental HUS by simply Stx administration to animals other than baboons [30] has not yet been successful [14]. Our model produced tubular necrosis in agreement with previous reports in rabbits and mice and developed glomerular necrosis with fibrin capillary thrombi characteristic of human HUS [14–16].

Oral inoculation in neonatal piglets with STEC showed similar renal lesions [31], but gnotobiotic piglets showed only vascular damage [26]. A successful model of HUS in baboons, which share an identical distribution of gastrointestinal and renal Gb3 receptor with humans, caused renal failure, with hematuria, proteinuria, thrombocytopenia, schistocytosis, anemia, melena, and histopathological alterations compatible with thrombotic microangiopathy [30].

We found both glomerular and tubular necrosis concomitant with an increase in plasma creatinine and urea concentrations. These changes were associated with a progressive decrease in the glomerular filtrate volume. The urine volume had increased at 24 h and was followed by a decrease at 48 h which was concomitant with a reduction in glomerular filtration. This may reflect a biphasic course of renal failure, with tubular dysfunction followed by glomerular dysfunction. Recently, Sugatani et al. [16] reported acute tubular necrosis and polyuria in rats injected with Stx2 due to an increase in aquaporin type 2 and β2-microglobulin in urine, suggesting that the polyuria may have resulted from suppression of water reabsorption in proximal and collecting tubules. A posterior decrease in water excretion at 48 h may have been a consequence of a 90% reduction in the glomerular filtrate. Stx2 was binding to the basolateral membrane and cytoplasm

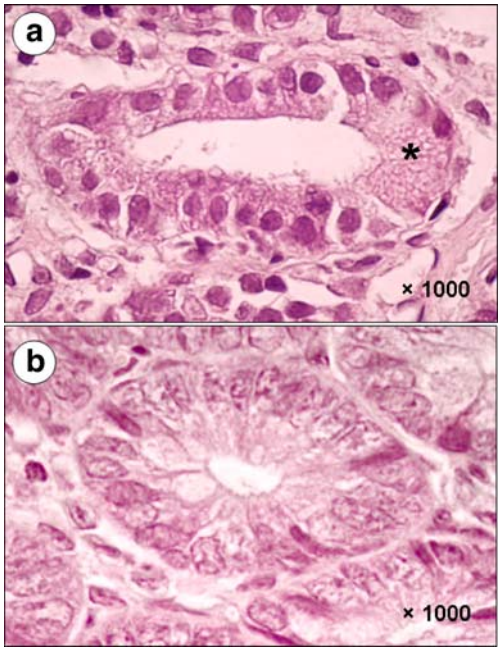

Fig. 5 Colonic crypt from the experimental group shows cytoplasmic swelling (*asterisk*) (**a**) compared with the control group (**b**). ×1,000

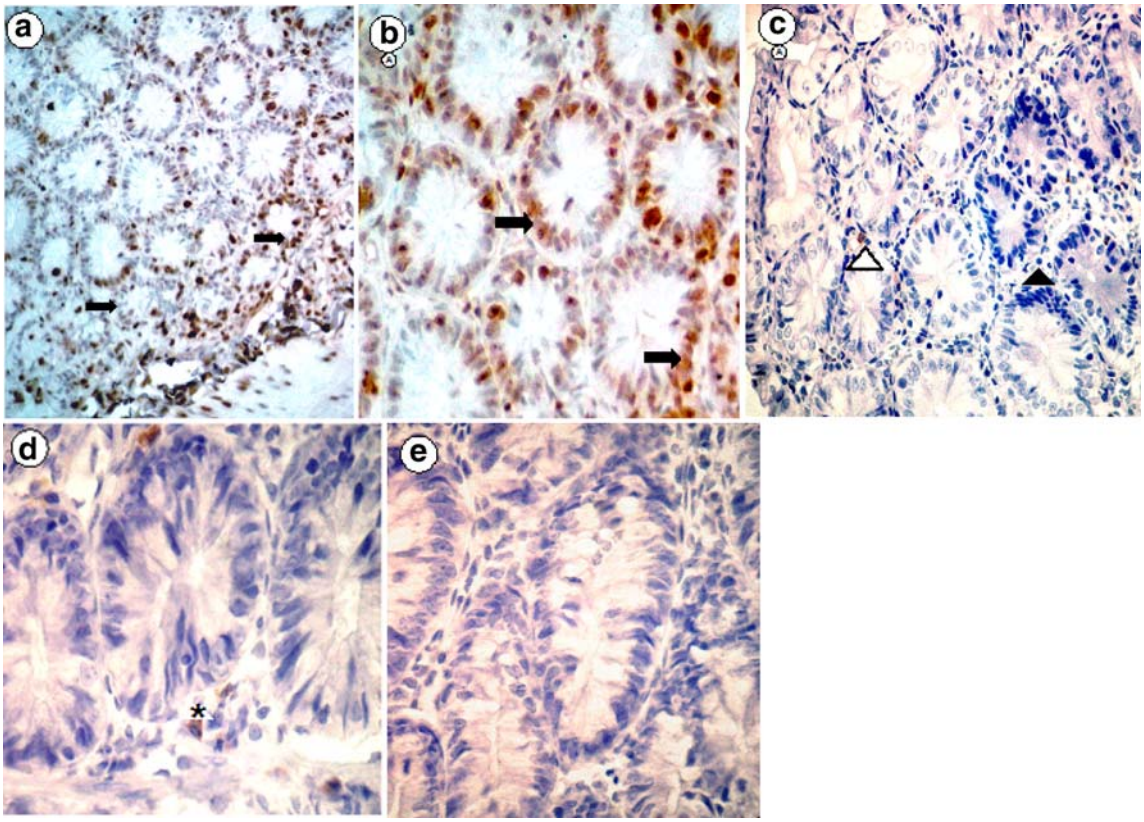

Fig. 6 Stx2 immunoperoxidase staining in the distal colon of the experimental group. Staining is observed in the lower third of colonic crypts (*black arrows in **a** and **b***) and isolated cells in the lamina propria (*asterisk in **d***). Close to these areas the mucosa shows non-specific lesion and focal loss of goblet cells (*white arrowhead and black arrowhead in **c***). No label in colonic mucosa from the control group (**e**). **a** ×200, **b**, **c** ×400, **d**, **e** ×1,000

of proximal and distal renal tubules, as in a previous report [32] that suggested that the kidney lesions can be associated with Stx2 localization.

Moreover, we observed glomerular capillaries with wall thickening by expansion of the subendothelial zone with glomerular basal membrane wrinkling in isolated glomeruli typical of HUS [33]. Our findings are different from those described in the murine model, where Stx2 binding to glomeruli was not detected [17]. Our results indicated that the toxin was reaching the kidney and would have been involved in the development of the mesangiolysis observed.

In addition, similar to that previously described in human HUS [34], we also observed the presence of fibrin thrombi in the capillary lumen [34]. Fibrin thrombi could be associated not only with the Stx2 but also with the presence of additional bacterial factors present in the culture supernatant that may have potentiated the cytotoxin action. It has been reported that LPS may combine with Stx to facilitate vascular damage [21], although it was unlikely in our experiments since a lower level of LPS was found in the culture supernatant. As a consequence of thrombosis, thrombocytopenia and hemolytic anemia developed. We saw a significantly increase in LDH plasmatic concentration that confirmed the development of hemolysis [35].

Thrombocytopenia and hemolytic anemia are the reflection of the consumption of platelets and fragmentation and destruction of erythrocytes when they pass through the partially occluded lumen of glomerular capillaries [36]. Anemia may be also secondary to an alteration in erythrocyte production due to tubular necrosis. In children with HUS, the anemia observed during acute renal failure has been attributed to inadequately low levels of serum erythropoietin associated with tubular damage [37].

In summary, the rats in our HUS model developed watery diarrhea, thrombocytopenia, leukocytosis, hemolytic anemia, glomerular thrombotic microangiopathy and tubular injury from the intraperitoneal injection of bacterial culture supernatant containing Stx2. This study allows us to have a better knowledge of the implied mechanisms related to the evolution of HUS.

Acknowledgments This paper was presented at the 50th Annual Scientific Meeting, Argentine Society of Clinical Investigation (SAIC), Mar del Plata, Argentina, 29th November to 2nd December, 2005, and the 6th International Symposium on Shiga toxin (Verocytotoxin-producing *Escherichia coli* infection, Melbourne, Australia, 29th October to 1st November, 2006. This work was supported by the University of Buenos Aires (M038, M827), the National Council of Research (CONICET, PIP 5587) and ANPCYT (PICT-26224). The

authors gratefully acknowledge Claudio Mirabelli for his excellent technical assistance.

References

1. Griffin PM, Tauxe RV (1991) The epidemiology of infections caused by *Escherichia coli* O157:H7, other enterohemorrhagic *E. coli*, and the associated hemolytic uremic syndrome. Epidemiol Rev 13:60–98
2. Remuzzi G, Ruggenenti P (1995) The hemolytic uremic syndrome. Kidney Int 48:2–19
3. Repetto HA (1997) Epidemic hemolytic-uremic syndrome in children. Nephrology Forum. Kidney Int 52:1708–1719
4. Spizzirri FD, Rahman RC, Bibiloni N, Ruscasso JD, Amoreo OR (1997) Childhood hemolytic uremic syndrome in Argentina: long-term follow-up and prognostic features. Pediatr Nephrol 11:156–160
5. Robson WL, Leung AK, Brant R (1993) Relationship of the recovery in the glomerular filtration rate to the duration of anuria in diarrhea-associated hemolytic uremic syndrome. Am J Nephrol 13:194–197
6. Tonshoff B, Sammet A, Sanden I, Mehls O, Waldherr R, Scharer K (1994) Outcome and prognostic determinants in the hemolytic uremic syndrome of children. Nephron 68:63–70
7. Scully RE, Mark EJ, McNeely WF, Ebeling SH, Phillips LD (1995) Case records of the Massachusetts General Hospital. N Engl J Med 336:1587–1594
8. Tarr PI (1995) *Escherichia coli* O157:H7: clinical, diagnostic, and epidemiological aspects of human infection. Clin Infect Dis 20:1–8
9. Lopez EL, Diaz M, Grinstein S, Devoto S, Mendilaharzu F, Murray BE, Ashkenazi S, Rubeglio E, Woloj M, Vasquez M, Turco M, Pickering LK, Cleary TG (1989) Hemolytic uremic syndrome and diarrhea in Argentine children: the role of Shiga-like toxins. J Infect Dis 160:469–475
10. Rivas M, Balbi L, Miliwebsky ES, Garcia B, Tous MI, Leardini NA, Prieto MA, Chillemi GM, De Principi ME (1998) Hemolytic uremic syndrome in children of Mendoza, Argentina: association with Shiga-toxin producing *Escherichia coli* infection. Medicina (B. Aires) 58:1–7
11. Rivas M, Caletti MG, Chinen I, Refi SM, Roldan CD, Chillemi G, Fiorilli G, Bertolotti A, Aguerre L, Estani SS (2003) Home-prepared hamburger and sporadic hemolytic uremic syndrome, Argentina. Emerg Infect Dis 9:1184–1186
12. Rivas M, Milwebsky E, Chinen I, Deza N, Leotta G (2006) The epidemiology of hemolytic uremic syndrome in Argentina. Diagnosis of the etiologic agent, reservoirs and routes of transmission. Medicina (B. Aires) 66:27–32
13. Exeni R (2001) Síndrome Urémico Hemolítico. Arch Latin Nefr Ped 1:35–56
14. Tesh VL, Burris JA, Owens JW, Gordon VM, Wadolkowski EA, O'Brien AD, Samuel JE (1993) Comparison of the relative toxicities of Shiga-like toxins type 1 and type 2 for mice. Infect Immun 61:3392–3402
15. Zhao YL, Cen XB, Ito M, Yokoyama K, Takagi K, Kitaichi K, Nadai M, Ohta M, Takagi K, Hasegawa T (2002) Shiga-like toxin II derived from *Escherichia coli* O157:H7 modifies renal handling of levofloxacin in rats. Antimicrob Agents Chemother 46:1522–1528
16. Sugatani J, Komiyama N, Mochizuki T, Hoshino M (2002) Urinary concentrating defect in rats given Shiga toxin: elevation in urinary AQP2 level associated with polyuria. Life Sci 71:171–189
17. Keepers T, Psotka M, Gross L, Obrig T (2006) A murine model of HUS: Shiga toxin with lipopolysaccharide mimics the renal damage and physiologic response of human disease. J Am Soc Nephrol 17:3404–3414
18. Karpman D, Connell H, Svensson M, Scheutz F, Alm P, Svanborg C (1997) The role of lipopolysaccharide and Shiga like toxin in a mouse model of *Escherichia coli* O157:H7 infection. J Infect Dis 175:611–620
19. Siegler Rl, Pysher TJ, Lou R, Tesh VL, Taylor FB Jr (2001) Response to Shiga toxin-1, with and without lipopolysaccharide, in a primate model of hemolytic uremic syndrome. Am J Nephrol 21:420–425
20. Palermo M, Alves-Rosa F, Rubel C, Fernandez GC, Fernandez-Alonso G, Alberto F, Rivas M, Isturiz M (2000) Pretreatment of mice with lipopolysaccharide (LPS) or IL-1beta exerts dose dependent opposite effects on Shiga toxin-2 lethality. Clin Exp Immunol 119:77–83
21. Louise C, Obrig T (1992) Shiga toxin-associated hemolytic uremic syndrome: combined cytotoxic effects of Shiga toxin and lipopolysaccharide (endotoxin) on human vascular endothelial cells in vitro. Infect Immun 60:1536–1543
22. Duner KI (1993) A new kinetic single stage Limulus amoebocyte lysate method for the detection of endotoxin in water and plasma. J Biochem Biophys Methods 26:131–142
23. Fujii J, Kinoshita Y, Yutsudo T, Taniguchi H, Obrig T, Yoshida SI (2001) Toxicity of Shiga toxin 1 in the central nervous system of rabbits. Infect Immun 69:6545–6548
24. Pistone Creydt V, Silberstein C, Zotta E, Ibarra C (2006) Cytotoxic effect of Shiga toxin-2 holotoxin and its B subunit on human renal tubular epithelial cells. Microbes Infect 8:410–419
25. Pistone Creydt V, Miyakawa MF, Martin F, Zotta E, Silberstein C, Ibarra C (2004) The Shiga toxin 2B subunit inhibits net fluid absorption in human colon and elicits fluid accumulation in rat colon loops. Braz J Med Biol Res 37:799–808
26. Dean-Nystrom EA, Melton-Celsa AR, Pohlenz JF, Moon HW, O'Brien AD (2003) Comparative pathogenicity of *Escherichia coli* O157 and intimin-negative non-O157 Shiga toxin-producing *E. coli* strains in neonatal pigs. Infect Immun 71:6526–6533
27. Gunzer F, Hennig-Pauka I, Waldmann KH, Sandhoff R, Grone HJ, Kreipe HH, Matussek A, Mengel M (2002) Gnotobiotic piglets develop thrombotic microangiopathy after oral infection with enterohemorrhagic *Escherichia coli*. Am J Clin Pathol 118:364–375
28. Imai Y, Fukui T, Kurohane K, Miyamoto D, Suzuki Y, Ishikawa T, Ono Y, Miyake M (2003) Restricted expression of Shiga toxin binding sites on mucosal epithelium of mouse distal colon. Infect Immun 71:985–990
29. Pruimboom-Brees I, Morgan T, Ackermann M, Nystrom E, Samuel J, Cornick N, Moon H (2000) Cattle lack vascular receptors for *Escherichia coli* O157:H7 Shiga toxins. Proc Natl Acad Sci USA 97:10325–10329
30. Taylor FB Jr, Tesh VL, DeBault L, Li A, Chang AC, Kosanke SD, Pysher TJ, Siegler RL (1999) Characterization of the baboon responses to Shiga-like toxin: descriptive study of a new primate model of toxic responses to Stx-1. Am J Pathol 154:1285–1299
31. Pohlenz JF, Winter KR, Dean-Nystrom EA (2005) Shiga-toxigenic *Escherichia coli*-inoculated neonatal piglets develop kidney lesions that are comparable to those in humans with hemolytic-uremic syndrome. Infect Immun 73:612–616
32. Rutjes N, Binnington B, Smith C, Maloney M, Lingwood L (2002) Differential tissue targeting and pathogenesis of verotoxins 1 and 2 in the mouse animal model. Kidney Int 62:832–845
33. Ruggenenti P, Noris M, Remuzzi G (2001) Thrombotic micro-angiopathy, hemolytic uremic syndrome, and thrombotic thrombocytopenic purpura. Kidney Int 60:831–846
34. Richardson SE, Karmali MA, Becker LE, Smith CR (1988) The histopathology of the hemolytic uremic syndrome (HUS) associated with verocytotoxin producing *Escherichia coli* infections. Hum Pathol 19:1102–1108

35. Kato G, McGowan V, Machado R, Little J, Taylor J VI, Morris C, Nichols J, Wang X, Poljakovic M, Morris Jr S, Gladwin M (2006) Lactate dehydrogenase as a biomarker of hemolysis-associated nitric oxide resistance, priapism, leg ulceration, pulmonary hypertension, and death in patients with sickle cell disease. Blood 107:2279–2285
36. Brain MC (1970) Microangiopathic hemolytic anemia. Annu Rev Med 21:133–144
37. Donato H, Rendo P, Exeni R, Rapetti MC, Antonuccio M, Galvagni A, Grimoldi I, Exeni A (1997) Erythropoietin deficiency in children with acute renal insufficiency due to hemolytic uremic syndrome. Hematología (B. Aires) 1:5–11