



# Diabetes mellitus remission in a cat with hyperadrenocorticism after cabergoline treatment

Diego D Miceli<sup>1,2,3</sup>, Gabriela S Zelarayán<sup>4</sup>, Jorge D García<sup>1</sup>, Viviana Fernández<sup>3</sup> and Sergio Ferraris<sup>3</sup>

Journal of Feline Medicine and Surgery Open Reports  
1–7

© The Author(s) 2021

Article reuse guidelines:

sagepub.com/journals-permissions

DOI: 10.1177/20551169211029896

journals.sagepub.com/home/jfmsopenreports

This paper was handled and processed by the American Editorial Office (AAFP) for publication in *JFMS Open Reports*



## Abstract

**Case summary** A 7-year-old spayed female domestic shorthair cat weighing 5 kg was referred with polyuria, polydipsia, lethargy, abdominal distension and dermatologic abnormalities. Diabetes mellitus was diagnosed and treatment was started with a diet for diabetic cats and insulin glargine (1 IU q12h SC). Hyperadrenocorticism (HAC) was suspected and diagnosed based on clinical signs, increased urinary cortisol:creatinine ratio, lack of suppression on low-dose dexamethasone suppression test and abdominal ultrasonography demonstrating bilateral adrenal enlargement. Oral cabergoline (10 µg/kg every other day) was initiated. After the second administration of cabergoline, the cat suffered from clinical hypoglycemia and no longer required insulin. One month after insulin withdrawal, blood work and urine analysis results showed normoglycemia, a normal serum fructosamine concentration (244 µmol/l) and normal urine analysis without glycosuria. Diabetic remission persisted until its death 7 months later. In addition, cabergoline treatment was associated with improvement in clinical signs such as lethargy, seborrhea, alopecia and abdominal distension.

**Relevance and novel information** To our knowledge, this is the first reported case of the use of cabergoline in a cat with HAC, as well as the first reported case of diabetic remission in a cat with HAC after cabergoline treatment. Cabergoline could be an alternative treatment for diabetic cats with pituitary-dependent HAC. Further work should focus on different protocols with greater number of cases.

**Keywords:** Diabetes mellitus remission; feline Cushing syndrome; cabergoline; pituitary-dependent hyperadrenocorticism

**Accepted:** 14 June 2021

## Case description

A 7-year-old spayed female domestic shorthair cat weighing 5 kg with a body condition score of 3/5 was referred to a private veterinary clinic (Veterinary Paraná, Argentina) with polyuria, polydipsia, lethargy, abdominal distension and dermatologic abnormalities.

On physical examination, the clinical findings were poor general condition, lethargy, muscle weakness, abdominal distension, alopecia, unkempt haircoat, seborrhea, and fragile, thin, dry and inelastic skin (Figure 1). Blood work and urinalysis results showed fasting hyperglycemia, glycosuria, hypercholesterolemia and elevated serum fructosamine concentrations (Table 1). An abdominal ultrasound was performed (Esoate Mylab 20 gold), where bilateral adrenal hyperplasia (right

<sup>1</sup>Endocrinology Unit, Hospital School of Veterinary Medicine, University of Buenos Aires, Faculty of Veterinary Sciences, Buenos Aires, Argentina

<sup>2</sup>Laboratory of Molecular Endocrinology and Signal Transduction, Institute of Experimental Biology and Medicine – CONICET, Buenos Aires, Argentina

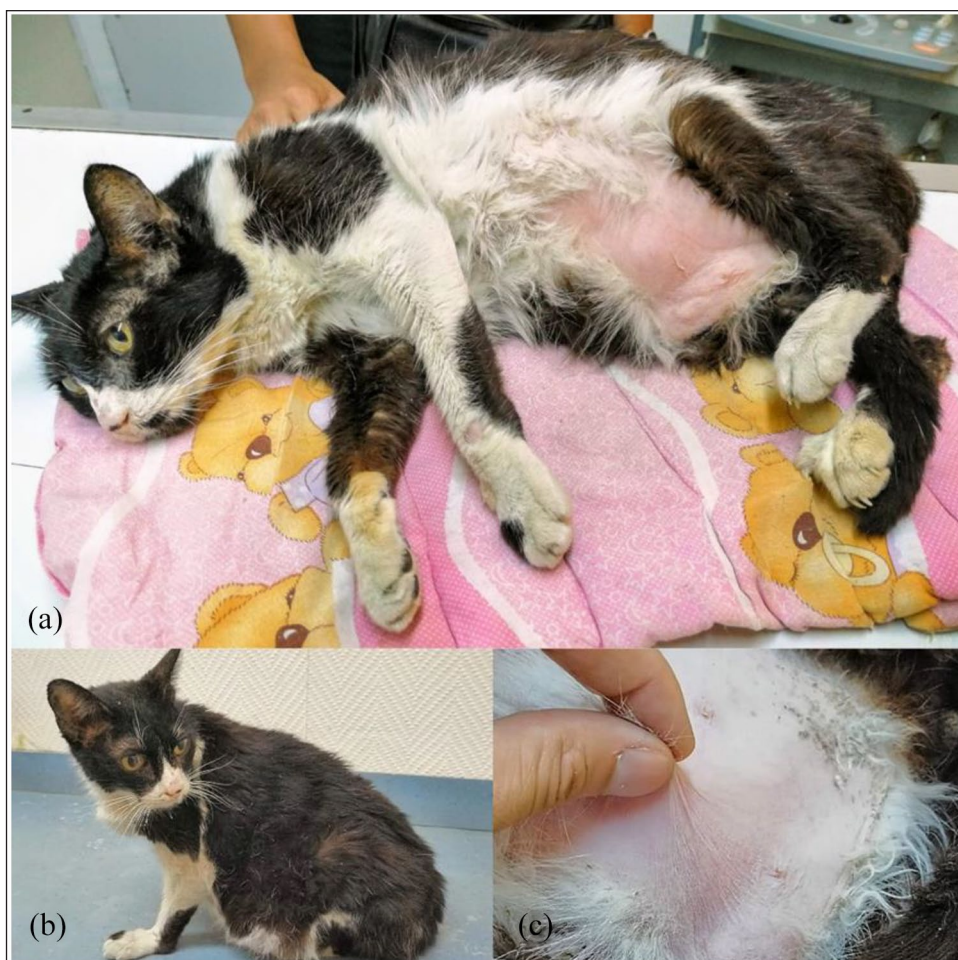<sup>3</sup>Veterinary Science Center, Maimonides University, Buenos Aires, Argentina

<sup>4</sup>Veterinary Paraná, Buenos Aires, Argentina

### Corresponding author:

Diego D Miceli DVM, PhD, Res-CONICET, Endocrinology Unit, Hospital School of Veterinary Medicine, University of Buenos Aires, Faculty of Veterinary Sciences, Buenos Aires, Argentina, and Laboratory of Molecular Endocrinology and Signal Transduction, Institute of Experimental Biology and Medicine – CONICET, Chorroarin 280, Buenos Aires 1427, Argentina  
Email: dmiceli@fvvet.uba.ar





**Figure 1** Clinical features of the cat before cabergoline treatment. (a,b) Lethargy, abdominal distension, alopecia and unkempt haircoat; (c) fragile, thin, dry and inelastic skin

adrenal longitudinal section:  $1.81 \times 0.55$  cm; left adrenal longitudinal section:  $1.40 \times 0.65$  cm) and hepatic steatosis were evidenced (Figure 2). Diabetes mellitus (DM) was diagnosed and dietary and medical treatment was started with a commercial diet for diabetic cats (Royal Canin Diabetic for cats) and insulin glargine (1 IU q12h SC [Lantus; Sanofi-Aventis]). The cat had not been previously treated with glucocorticoids or progestagens.

Two weeks after insulin therapy, the cat had an improved clinical condition and had partially reduced polyuria and polydipsia. After performing the corresponding blood glucose curve, it was decided to increase the insulin glargine dosage to 2 IU q12h SC. The clinical outcome was favorable with the new dosage, as water consumption and urination quickly normalized. After a week a second blood glucose curve was performed, showing values of 5.5–16.6 mmol/l, and the insulin dose was maintained.

After the fourth week of insulin therapy, spontaneous hypersomatotropism and hyperthyroidism were ruled

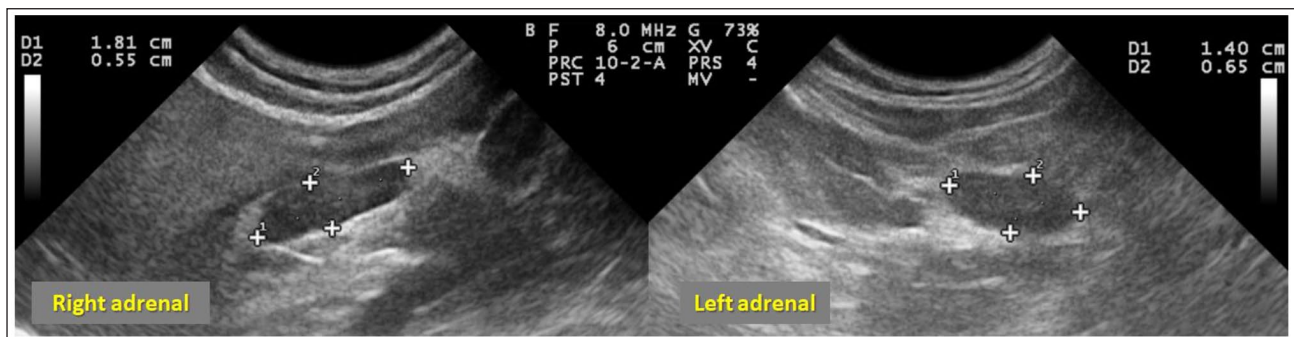
out with normal serum insulin-like growth factor 1 (IGF-1) and total thyroxine concentrations (Table 1). Feline immunodeficiency virus and feline leukemia virus (using an immunochromatographic assay [Speed DUO FeLV-FIV; Virbac]) were negative. Spontaneous hyperadrenocorticism (HAC), specifically pituitary-dependent HAC (PDH), was suspected and diagnosed based on clinical signs, increased urinary cortisol:creatinine ratio (UCCR:  $78.75 \times 10^{-6}$ ; reference interval [RI]  $<36 \times 10^{-6}$ ) and lack of suppression on the low-dose dexamethasone suppression test (LDDST), 0.1 mg/kg dexamethasone (basal cortisol: 5.4 µg/dl; 4h cortisol: 4.1 µg/dl; 8h cortisol: 5.2 µg/dl; cut-off  $<1.4$  µg/dl) (Table 1). CT did not reveal a pituitary mass or visible alteration in the brain.

A dosage of 10 µg/kg PO q48h cabergoline (Dostinex; Pfizer) was prescribed.<sup>1</sup> After the second administration of cabergoline, the cat suffered from clinical hypoglycemia that required emergency veterinary assistance. The last dose of glargine had been received 5 h earlier and the cat had eaten normally. The cat was admitted with

**Table 1** Clinicopathologic findings, hormone analysis and insulin doses of the cat at diagnosis and during cabergoline treatment (months 1 and 3)

	Diagnosis of DM	Diagnosis of HAC	Cabergoline treatment		RI
			Month 1	Month 3	
Glycemia (mmol/l)	22	–	5.4	4.8	4.4–6.6
ALT (U/l)	209	–	143	26	<80
ALP (U/l)	134	–	122	111	<100
Urea (mmol/l)	15.6	–	15.7	14.3	5.4–16
Creatinine ( $\mu\text{mol/l}$ )	70.7	–	97.2	106.1	<141
Cholesterol (mmol/l)	7.2	–	7	6.9	<5.2
Triglycerides (mmol/l)	0.7	–	0.6	0.5	<1.13
Sodium (mmol/l)	151	–	150	152	146–156
Potassium (mmol/l)	4.2	–	4.3	4.1	3.2–5.5
Fructosamine ( $\mu\text{mol/l}$ )	527	410	244	252	200–360
USG	1.034	–	1.030	1.030	$\geq 1.035$
Glycosuria (mmol/l)	60	–	0	0	0
Total thyroxine ( $\mu\text{g/dl}$ )	–	2.1	–	–	1–4
IGF-1 (ng/ml)	–	517	–	–	<800
UCCR ( $\times 10^{-6}$ )	–	78.75	–	36.2	<36
LDDST: cortisol ( $\mu\text{g/dl}$ )					
basal	–	5.4	–	–	1–5
–4h	–	4.1	–	–	<1.4
–8h	–	5.2	–	–	<1.4
Insulin dose (IU q12h)	1	2	0	0	

DM = diabetes mellitus; HAC = hypoadrenocorticism; RI = reference interval; ALT = alanine aminotransferase; ALP = alkaline phosphatase; USG = urine specific gravity; IGF-1 = serum insulin-like growth factor 1; UCCR = urinary cortisol:creatinine ratio; LDDST = low-dose dexamethasone suppression test



**Figure 2** Abdominal ultrasound showing bilateral enlargement of adrenal glands. Right adrenal longitudinal section: 1.81  $\times$  0.55 cm; left adrenal longitudinal section: 1.40  $\times$  0.65 cm

generalized seizures and glycemia of 1.4 mmol/l. A sugar solution by mouth and an IV bolus of dextrose at 0.5 g/kg was administered immediately. The seizures stopped quickly and after 15 mins, glycemia was 9.6 mmol/l. However, sensorium was still depressed and the cat was kept in the intensive care unit under close observation. Six hours later, its neurologic state had already improved, and it had a normal appetite. The cat was kept under medical observation for another 6 h until discharge.

The cat no longer required insulin and maintained blood glucose concentrations within the RI (4.4–6.6 mmol/l). In addition, the cat did not show clinical signs of DM or signs of hypoglycemia. One month after insulin withdrawal, blood work and urinalysis results showed normoglycemia, normal serum fructosamine concentration (244  $\mu\text{mol/l}$ ) and no glycosuria (Table 1).

Remission of DM persisted throughout the life of the animal until its death 7 months later; the cat received cabergoline during the whole observation period. No

direct side effects of cabergoline were observed during the entire study.

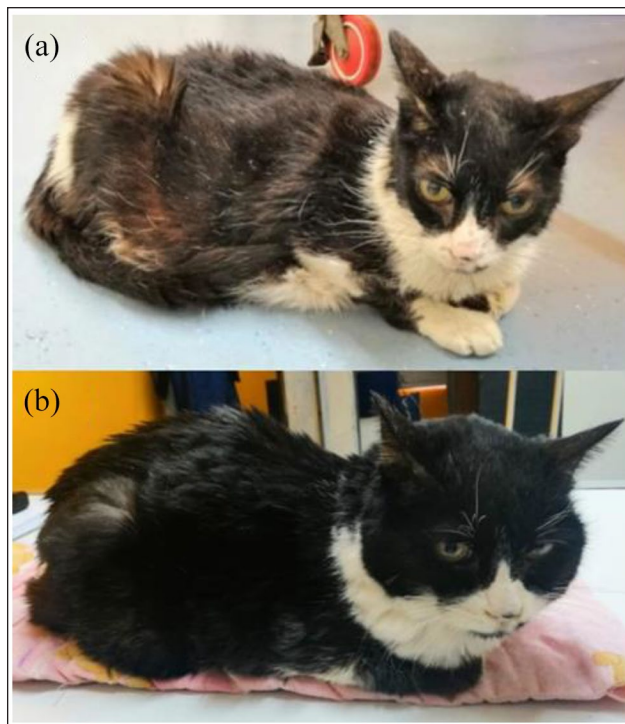
The clinical outcome with cabergoline was favorable. In addition to allowing DM remission, cabergoline treatment improved the clinical signs of HAC, such as lethargy, seborrhea, unkempt haircoat, alopecia and abdominal distension (Figure 1). During the third month of cabergoline treatment, the cat experienced a marked improvement in activity, the haircoat became soft without seborrhea, the alopecic areas were recovered with hair and abdominal distension was reduced (Figures 3 and 4). At the same time, a marked reduction in the UCCR ( $36.2 \times 10^{-6}$ ;  $RI < 36 \times 10^{-6}$ ) was registered.

Seven months after cabergoline treatment, the cat suffered from an acute decompensation and euthanasia was decided on. The cause of the decompensation could not be specified; the owners did not want a necropsy to be performed.

## Discussion

In the case presented in this report, cabergoline was associated with the control of clinical signs of HAC, as well as with diabetic remission. To our knowledge, this is the first reported case of the use of cabergoline in a cat with HAC and the first report to describe a case of DM remission in a cat with HAC after cabergoline treatment.

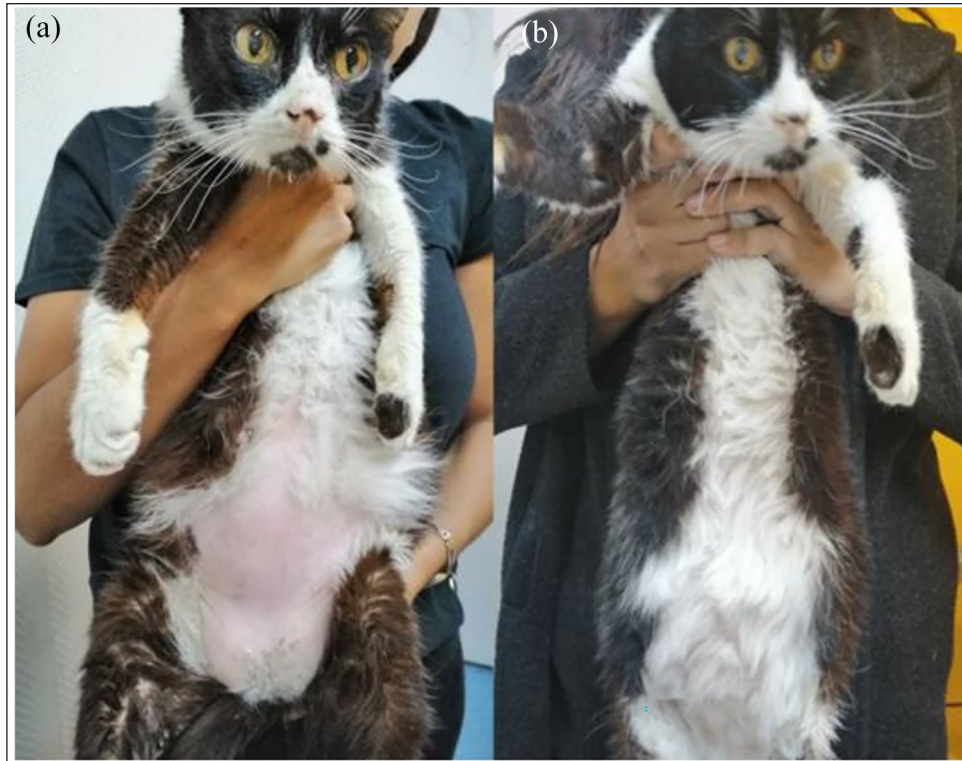Spontaneous HAC, or Cushing syndrome, is a severe metabolic disorder resulting from prolonged exposure to excessive cortisol concentrations.<sup>2</sup> In cats, approximately 80% of cases are due to adrenocorticotrophic hormone (ACTH)-secreting pituitary tumors (pars distalis or pars intermedia), while the remaining 20% are due to cortisol-secreting corticoadrenal tumors (and other steroids).<sup>2-4</sup> Although it is a common endocrine disease in dogs, it is a rare condition in cats; to date, about 200 cases of feline HAC have been reported.<sup>3,4</sup> The most common complications in cats with HAC are DM, chronic kidney disease, bacterial infections, dermatologic abnormalities, pancreatitis and heart disease.<sup>3,4</sup> Excess of glucocorticoids induces a state of insulin resistance that predisposes the development of DM in humans as well as in both dogs and cats.<sup>3-6</sup> Specifically, in cats, the concurrence of DM and HAC is high; it is estimated that around 80–90% of cats with HAC have secondary DM.<sup>3,4</sup> In the case presented in this report, the cat had several indicators that led to suspicion of this concurrence; in addition to the clinical signs of DM, the cat had other clinical signs (abdominal distension, alopecia, unkempt haircoat, seborrhea, and fragile, thin, dry and inelastic skin), which were compatible with suspected HAC. The diagnosis of HAC in diabetic cats may be controversial, owing to the difficulty of interpreting endocrine tests.<sup>2-4</sup> In this case, the cat presented



**Figure 3** Clinical appearance of the cat, lateral view: (a) at diagnosis of hypoadrenocorticism and (b) at month 3 of cabergoline treatment. After treatment with cabergoline, the cat had an improved general clinical condition and haircoat quality

with an increased UCCR, which may also be increased as a result of stress or illness.<sup>7</sup> Likewise, the cat had a lack of suppression on the LDDST test. Although the LDDST is not perfect, it has been described as the screening test of choice in cats with HAC.<sup>2,3</sup> Also, it has been reported that the results of the LDDST in cats with DM are normal.<sup>8</sup> Regarding diagnostic imaging, abdominal ultrasound demonstrated bilateral adrenal enlargement in this cat; it is worth mentioning this because it has been reported that DM does not cause adrenal gland enlargement in cats.<sup>8</sup> Although it has been stated that one-third of cats with HAC do not present with an enlarged pituitary or displacement of the contrast medium during CT scanning,<sup>3</sup> the evidence for HAC would have been stronger if a pituitary mass had been identified in our cat. Therefore, it is important to highlight that it was highly likely that this cat had spontaneous HAC, but that it was not proven with 100% certainty. The cat did not present with a marked insulin resistance, as polydipsia and polyuria, and persistent hyperglycemia were controlled with a standard dose of insulin glargine (2IU q12h SC).

Feline diabetic remission is defined as the absence of clinical signs of DM, normal blood glucose and fructosamine concentrations without medical antidiabetic



**Figure 4** Clinical appearance of the cat, ventral view: (a) at diagnosis of hypoadrenocorticism and (b) at month 3 of cabergoline treatment. After treatment with cabergoline, the abdominal distension was reduced and the alopecic areas were covered with new hair

therapy, for a minimum of 28 days.<sup>9</sup> The cat in this report fulfilled these criteria. Feline diabetic remission was previously described in cats with HAC treated with trans-sphenoidal hypophysectomy, unilateral and bilateral adrenalectomy, pituitary irradiation and also with trilostane.<sup>10–13</sup> In diabetic cats (type 2DM), diabetic remission most often occurs within the first 6 months after the diagnosis of DM.<sup>14</sup> In our cat, diabetic remission was achieved rapidly: around 30 days after insulin therapy and, surprisingly, 3 days after cabergoline treatment with clinical signs of hypoglycemia. In cases of feline secondary DM, such as in this report, diabetic remission could be achieved once the underlying inducing disease is treated effectively.<sup>13,14</sup> However, it is important to highlight that treatment with cabergoline was only associated with diabetic remission and that it is possible that the diabetic remission occurred independent of the treatment with cabergoline.

Hypophysectomy or adrenalectomy represents the definitive treatment for feline HAC; pharmacologic treatment has been evaluated with antisteroidogenic drugs such as mitotane, ketoconazole, aminoglutethimide and metyrapone with varied response and is often disappointing.<sup>3,4,12</sup> Although studies on pharmacologic treatments are scarce, trilostane is considered the most

effective option for feline HAC.<sup>3,15</sup> To our knowledge, pharmacologic treatments with a target in the pituitary gland for feline PDH have so far not been used.

Cabergoline is a long-acting dopamine agonist (DA), with a high affinity for the dopamine receptor 2 (D2R). In human medicine, use of a DA is the mainstay of treatment of hyperprolactinemia and is considered to be a therapeutic option for patients with acromegaly, non-functioning pituitary adenomas and Cushing disease, especially in pregnant women and in patients with persistent or recurrent Cushing disease after trans-sphenoidal surgery.<sup>16,17</sup> Cabergoline normalizes 24 h urinary free cortisol in <40% of cases; in addition, in patients who initially showed a successful response, subsequent follow-up evidenced no sustained control of the disease.<sup>16,17</sup> In veterinary medicine, cabergoline is frequently used as a treatment for pseudopregnancy in dogs.<sup>18</sup> Cabergoline is described as a pharmacologic option for dogs with PDH, reducing ACTH and alpha melanocyte stimulating hormone ( $\alpha$ -MSH) concentrations, UCCR and pituitary tumor size, showing efficacy in 42.5% of cases.<sup>19</sup> In 2021, we published the first reported cases of diabetic remission in three cats with hypersomatotropism after cabergoline treatment.<sup>1</sup> In those cats, cabergoline was effective in reducing insulin requirements progressively

until achieving diabetic remission 3 months after cabergoline treatment. On the contrary, in the cat with PDH in the present report, diabetic remission was achieved after the second administration of cabergoline (3 days after treatment) and abruptly. It is important to highlight that this cat did not show insulin resistance and the insulin dose was 0.4 IU/kg q12h SC, while the doses received in the three cats with hypersomatotropism were higher (0.9–2 IU/kg q12h SC).<sup>1</sup>

Expression of the D2R has been demonstrated in the pituitary gland of cats with hypersomatotropism; a moderate negative correlation between D2R expression and pituitary size was described in the study.<sup>20</sup> It is possible to assume that, as an evident pituitary mass was not observed in the cat of the present report, this small tumor size made the pituitary tumor more likely to respond to cabergoline treatment, as has been observed in dogs affected by PDH.<sup>19</sup>

The mechanism of action of DAs to control DM is complex, but it is likely that the suppression of monoamines and prolactin (PRL) is involved.<sup>21</sup> In animal models, DAs regulate metabolic pathways in the central nervous system and after administration of a DA, levels of noradrenalin and serotonin are reduced, which results in a reduction of hepatic glucose production and adipose tissue lipolysis, and also improved insulin sensitivity.<sup>21</sup> Additionally, the role of PRL on glucose metabolism is controversial; however, several studies showed that PRL induces insulin resistance, weight gain and food intake, favoring the development of type 2 DM.<sup>22,23</sup> In humans, cabergoline has been shown to improve glycemic control and to reduce glycosylated hemoglobin (HbA1c) concentrations.<sup>24</sup> Likewise, cabergoline has been reported to improve metabolic parameters in patients with prolactinoma.<sup>25,26</sup> In turn, cabergoline could play a role in the hypothalamic–pituitary–adrenal (HPA) axis in cats. In dogs, rats and humans, experimental evidence supports D2R expression and function in corticotrophinoma. DAs (cabergoline and bromocriptine) reduce ACTH secretion from cultured human pituitary tumor cells and induce apoptosis in AtT-20 cells, a murine corticotroph pituitary tumor cell line.<sup>27,28</sup> In dogs with PDH, cabergoline reduces ACTH,  $\alpha$ -MSH concentrations and the UCCR.<sup>19</sup> In the cat in this report, the UCCR decreased considerably at month 1 of cabergoline treatment. However, we cannot assume that it was a direct effect of cabergoline on the HPA axis; diabetic remission may have resulted in less stress and, consequently, a lower UCCR. By reducing the UCCR, thus assuming the reduction of hypercortisolism of PDH, the cat can reduce the antagonistic effects of cortisol on insulin.

The short time in which diabetic remission occurred after the second dose of cabergoline is striking and the cause is unknown. Considering that clinical improvements in HAC were observed 3 months after treatment,

it is possible to hypothesize that cabergoline not only has a direct effect on the HPA axis, but also on mechanisms independent of the HPA axis, such as the autonomic nervous system or PRL,<sup>21</sup> which could show their metabolic effects more quickly.

Interestingly, cabergoline was associated with control of clinical signs of HAC in this cat. Three months after treatment, the cat showed substantial clinical improvements: the cat became more active, dermatologic alterations were corrected (the haircoat became soft, seborrhea disappeared and alopecic areas were recovered with new hair) and abdominal distension was reduced. Also, cabergoline was shown to be a safe medication in this cat. Considering that hypoglycemia was caused by the decrease in insulin requirements, no direct side effects of cabergoline were observed during the entire study.

A limitation of this report was not measuring pituitary hormones, such as PRL, ACTH and  $\alpha$ -MSH. It would have been interesting to evaluate the effect of cabergoline at that level. Likewise, another limitation of the study was not having carried out the necropsy to investigate the cause of death and take samples for specific stains to clarify cabergoline's mechanism of action.

## Conclusions

This report details the first case of the use of cabergoline in a cat with HAC, as well as the first case of diabetic remission in a cat with HAC associated with cabergoline treatment. Cabergoline could be a therapeutic alternative for diabetic cats with PDH, not only for controlling DM, but also for controlling hypercortisolism. Further work should focus on different protocols and also with a greater number of cases.

**Conflict of interest** The authors declared no potential conflicts of interest with respect to the research, authorship, and/or publication of this article.

**Funding** The authors received no financial support for the research, authorship, and/or publication of this article.

**Ethical approval** The work described in this manuscript involved the use of non-experimental (owned or unowned) animals. Established internationally recognised high standards ('best practice') of veterinary clinical care for the individual patient were always followed and/or this work involved the use of cadavers. Ethical approval from a committee was therefore not specifically required for publication in *JFMS Open Reports*. Although not required, where ethical approval was still obtained it is stated in the manuscript.

**Informed consent** Informed consent (verbal or written) was obtained from the owner or legal custodian of all animal(s) described in this work (experimental or non-experimental animals, including cadavers) for all procedure(s) undertaken (prospective or retrospective studies). For any animals or people individually identifiable within this publication, informed

consent (verbal or written) for their use in the publication was obtained from the people involved.

## References

- Miceli DD, Vidal PN, Pompili GA, et al. **Diabetes mellitus remission in three cats with hypersomatotropism after cabergoline treatment.** *JFMS Open Reports* 2021; 7. DOI: 10.1177/20551169211018991.
- Boland LA and Barrs VR. **Peculiarities of feline hyperadrenocorticism: update on diagnosis and treatment.** *J Feline Med Surg* 2017; 19: 933–947.
- Galac S and Rosenberg D. **Cushing's syndrome (hypercortisolism).** In: Feldman E, Fracassi F and Peterson M (eds). *Feline endocrinology*. Milan: Edra, 2019, pp 357–380.
- Peterson ME. **Feline hyperadrenocorticism.** In: Mooney CT and Peterson ME (eds). *BSAVA manual of canine and feline endocrinology*. 4th ed. Gloucester: British Small Animal Veterinary Association, 2012, pp 190–198.
- Mazziotti G, Formenti AM, Frara S, et al. **Diabetes in Cushing disease.** *Curr Diab Rep* 2017; 17: 32. DOI: 10.1007/s11892-017-0860-9.
- Miceli DD, Pignataro OP and Castillo VA. **Concurrent hyperadrenocorticism and diabetes mellitus in dogs.** *Res Vet Sci* 2017; 115: 425–431.
- Henry CJ, Clark TP, Young DW, et al. **Urine cortisol:creatinine ratio in healthy and sick cats.** *J Vet Intern Med* 1996; 10: 123–126.
- Kley S, Alt M, Zimmer C, et al. **Evaluation of the low-dose dexamethasone suppression test and ultrasonographic measurements of the adrenal glands in cats with diabetes mellitus.** *Schweiz Arch Tierheilkd* 2007; 149: 493–500.
- Project ALIVE. **Diabetes mellitus terminology.** www.esve.org/ALIVE (2020, accessed December 21, 2020).
- Meij BP, Voorhout G, Van Den Ingh T S, et al. **Transsphenoidal hypophysectomy for treatment of pituitary-dependent hyperadrenocorticism in 7 cats.** *Vet Surg* 2001; 30: 72–86.
- Duesberg CA, Nelson RW, Feldman EC, et al. **Adrenalectomy for treatment of hyperadrenocorticism in cats: 10 cases (1988–1992).** *J Am Vet Med Assoc* 1995; 207: 1066–1070.
- Valentin SY, Cortright CC, Nelson RW, et al. **Clinical findings, diagnostic test results, and treatment outcome in cats with spontaneous hyperadrenocorticism: 30 cases.** *J Vet Intern Med* 2014; 28: 481–487.
- Muschner AC, Varela FV, Hazuchova K, et al. **Diabetes mellitus remission in a cat with pituitary-dependent hyperadrenocorticism after trilostane treatment.** *JFMS Open Reports* 2018; 4. DOI: 10.1177/2055116918767708.
- Gostelow R, Forcada Y, Graves T, et al. **Systematic review of feline diabetic remission: separating fact from opinion.** *Vet J* 2014; 202: 208–221.
- Mellett Keith AM, Bruyette D and Stanley S. **Trilostane therapy for treatment of spontaneous hyperadrenocorticism in cats: 15 cases (2004–2012).** *J Vet Intern Med* 2013; 27: 1471–1477.
- Feelders RA, Newell-Price J, Pivonello R, et al. **Advances in the medical treatment of Cushing's syndrome.** *Lancet Diabetes Endocrinol* 2019; 7: 300–312.
- Palui R, Sahoo J, Kamalanathan S, et al. **Effect of cabergoline monotherapy in Cushing's disease: an individual participant data meta-analysis.** *J Endocrinol Invest* 2018; 41: 1445–1455.
- Root AL, Parkin TD, Hutchison P, et al. **Canine pseudo-pregnancy: an evaluation of prevalence and current treatment protocols in the UK.** *BMC Vet Res* 2018; 14: 170. DOI: 10.1186/s12917-018-1493-1.
- Castillo VA, Gomez NV, Lalia JC, et al. **Cushing's disease in dogs: cabergoline treatment.** *Res Vet Sci* 2008; 85: 26–34.
- Scudder CJ, Mirczuk SM, Richardson KM, et al. **Pituitary pathology and gene expression in acromegalic cats.** *J Endocr Soc* 2018; 3: 181–200.
- Lopez Vicchi F, Luque GM, Brie B, et al. **Dopaminergic drugs in type 2 diabetes and glucose homeostasis.** *Pharmacol Res* 2016; 109: 74–80.
- Ben-Jonathan N, LaPensee CR and LaPensee EW. **What can we learn from rodents about prolactin in humans?** *Endocr Rev* 2008; 29: 1–41.
- Nilsson L, Binart N, Bohlooly-Y M, et al. **Prolactin and growth hormone regulate adiponectin secretion and receptor expression in adipose tissue.** *Biochem Biophys Res Commun* 2005; 331: 1120–1126.
- Andersen IA, Andreassen M and Krogh J. **The effect of dopamine agonists on metabolic variables in adults with type 2 diabetes: a systematic review with meta analysis and trial sequential analysis of randomized clinical trials.** *Diabetes Obes Metab* 2021; 23: 58–67.
- Berinder K, Nystrom T, Hoybye C, et al. **Insulin sensitivity and lipid profile in prolactinoma patients before and after normalization of prolactin by dopamine agonist therapy.** *Pituitary* 2011; 14: 199–207.
- Ciresi A, Amato MC, Guarnotta V, et al. **Higher doses of cabergoline further improve metabolic parameters in patients with prolactinoma regardless of the degree of reduction in prolactin levels.** *Clin Endocrinol (Oxf)* 2013; 79: 845–852.
- Pivonello R, Ferone D, de Herder WW, et al. **Dopamine receptor expression and function in corticotroph pituitary tumors.** *J Clin Endocrinol Metab* 2004; 89: 2452–2462.
- Yin D, Kondo S, Tacheuchi J and Morimura T. **Induction of apoptosis in murine ACTH-secreting pituitary adenoma cells by bromocriptine.** *FEBS Lett* 1994; 339: 73–75.