

We are IntechOpen, the world's leading publisher of Open Access books Built by scientists, for scientists

4,500

Open access books available

119,000

International authors and editors

135M

Downloads

Our authors are among the

154

Countries delivered to

TOP 1%

most cited scientists

12.2%

Contributors from top 500 universities



WEB OF SCIENCE™

Selection of our books indexed in the Book Citation Index
in Web of Science™ Core Collection (BKCI)

Interested in publishing with us?
Contact book.department@intechopen.com

Numbers displayed above are based on latest data collected.
For more information visit www.intechopen.com



Hyperosmolarity of the Tear Film in the Dry Eye

Alejandro Aguilar and Alejandro Berra

Abstract

The dry eye is a complex multifactor illness of the tear film and of the ocular surface characterized by symptoms of discomfort, vision alterations, and instability of the pre-corneal tear film which may bring about potential damage on the ocular surface. Instability of the film will produce increasing osmolarity of the tear film which will trigger epithelium osmotic lesions and inflammation. As these changes take place on the ocular surface, neurophysiologic mechanisms of homeostasis will be altered which will complicate the process even further with the cropping of vicious physiopathologic circuits.

Keywords: dry eye, tear film, hyperosmolarity, inflammation, physiopathologic circuits

1. Introduction

The ocular surface is a delicate portion of the eye's anatomy, where its constituent components maintain a close relationship in order to keep the region's homeostasis, which undoubtedly establishes the presence of a real anatomic-functional unit [1] in which the tear film must uphold the unimpaired health of epithelia of the conjunctiva and cornea and at the same time contribute to the normal physiology of the stroma.

In order that the tear film may carry out this function efficiently, its three layers must be complete and in constant equilibrium. The film's three layers have a close relationship, to such an extent, that any alteration in one of them (composition, secretory, etc.) may drastically impinge on the normal equilibrium of all, thus bringing about the partial or total alteration of the tear film and consequently alteration of the tear film and consequently altering epithelia.

2. Physiology

The dry eye is a pathologic multifactor process of the ocular surface due to a deficiency in quantity and/or quality of the pre-corneal tear film, which in turn makes it unable to keep healthy the epithelia of the cornea and the conjunctiva. This produces epithelial metaplasia of the squamous type and epithelial damage [2].

Even though this flaw may be due to different situations, increase of evaporation, deficiency in its production, and alteration in composition, in all cases the physiopathologic sequence is the increase of the film's osmolarity [3] which appears within the first 24 h of the onset of the process.

The decrease in the production of tears and/or qualitative changes in composition and also the evaporation of the film promote the phenomenon of hyperosmolarity. The evaporation of a smaller volume for a same surface increases osmolarity during the first 24 h from the onset of volumetric decrease [4].

Hyperosmolarity [5] causes epithelial injury in a direct manner as it produces cellular desquamation, complete disappearance of layers of superficial epithelial cells, decreasing of cytoplasmic density, and accumulation of rows of mucus product of goblet cells osmotically altered. This phenomenon is generally evident between 15 and 30 days from the osmolar change of the tear film.

According to Holly and Lamberts [6], the formation of the pre-corneal tear film is essentially a phenomenon of “wettability.” The epithelium of the cornea and conjunctiva must be completely humidified by the aqueous layer of the film. For a complete wettability, the conditions of the ocular surface need that the surface tension of the aqueous layer in the interphase with the epithelium be lower than the surface tension of the epithelium exposed to the medium.

Mucopolysaccharides of the mucin layer are principally responsible in keeping a stable surface tension. Mucus accumulation and destruction of goblet cells due to an increase of the film’s osmolarity brings about an increase in the surface tension, and therefore the wettability of the epithelium is inhibited.

In 1993 I advanced a hypothesis [7] based on the phenomenon of osmosis. The principle of osmosis is characterized by the presence of a solvent flow through a semipermeable membrane, which comes about when the concentration of the solution increases on one of the sides of the membrane. This aqueous movement tends to equalize concentrations on both sides [8]. When this occurs the osmotic phenomenon stops.

The corneal-conjunctival epithelium and the mucin layer of the tear film constitute a perfect biological semipermeable membrane and therefore act as such. When the osmolarity of the aqueous layer increases, the osmotic phenomenon begins producing a solvent flow from the epithelia and mucin layer towards the aqueous layer. This flow, nourished by the osmotic pressure, generates an important force that separates the aqueous layer impeding wettability.

At the same time, dehydration produced in the mucin layer will bring about destruction of mucus which raises higher surface tension, boosting osmolar disequilibrium.

At this point *sicca* lesion has taken place; it is exacerbated with cellular dehydration of the cellular layers of the epithelium generated in the aforementioned process and enters into a physiopathologic vicious circle.

On the other hand, taking into account the presence of the aqueous gradient through the protein water canals present in the stroma and with direction towards the aqueous humor, we shall observe that a new physical force of opposite direction (osmotic force) may modify this movement. This directional change of fluids produced by hyperosmolarity and by the mechanisms it produces may bring about dehydration of sulfated proteoglycans (GAGS) which occupy the spaces among collagen fibers of the stroma [9, 10]. When these glycoproteic structures dehydrate, the correct hydric balance of the stroma will be affected, which will incide in the normal maintenance of transparency of the cornea. Concurrently, alteration of the stroma will produce a loss in the number of goblet cells, with ensuing mucin and tensional alteration formerly described [11].

In this way, hyperosmolarity triggers a series of physiopathologic phenomena with evident feedback effects among them, which in both directions boost each other.

It is germane to this analysis that increase of osmolarity of the tear film in the dry eye, as a condition of stress on the ocular surface, triggers the inflammatory

process and immunologic phenomena as the presence of autoantigens that boost the inflammatory process.

Studies on inflammatory markers such as NF- κ B that migrates from the nucleus to the cytoplasm in the inflammatory process are directly related with the phenomenon of hyperosmolarity of the tear film. Nuclear translocation of NF- κ B is directly proportional to the increase of osmolarity of the tear film.

Berra and Berra [12] compared the nuclear NF- κ B translocation in healthy persons, in postmenopausal women, and in patients with Sjögren's syndrome, and they related them with osmolarity of the tear film and with impression cytology of these patients.

Healthy persons with normal values of osmolarity (300 mOsm/L \pm 10) did not show presence of marker NF- κ B, nor did they show metaplastic changes in the conjunctiva (normal cytology grade 0, according to Nelson's Classification) [13]. Postmenopausal women carriers of a moderate dry eye showed a moderate increase of osmolarity of the tear film (300–400 mOsm/L), moderate presence of factor NF- κ B, and cellular metaplastic alterations grades I–II. On the contrary, patients with a severe dry eye, group with Sjögren's syndrome, showed high values of osmolarity of the film (>400 mOsm/L), a great expression of nuclear translocation of factor NF- κ B, and severe squamous metaplasia (grades II–III).

Khanal et al. [14] compared values of the tear film's osmolarity in healthy persons with patients with dry eye, providing hyperosmolarity in patients with dry eye, and postulated the measuring of the film's osmolarity as one of the diagnostic milestones of the dry eye. Likewise, osmolarity is one of the diagnostic tests recommended by the committee of the National Eye Institute of the United States of America [15].

Laboratory tests prove that even an increase of 1% in the film's osmolarity is capable of inducing epithelial lesions and alter the normal flow of fluids towards the stroma.

Labbé et al. [16] established that dry eye is a clinical-pathological entity that involves the tear film, the lacrimal glands, and the eyelids, and it produces a large range of physiopathologic alterations where hyperosmolarity is one of the principal factors, assigning it a major diagnostic role. Several authors [17, 18] confirm these reports.

Even though the examining film's osmolarity requires sophisticated equipment and a high-grade qualification to carry it out, we may assess its value by indirectly measuring the concentration of sodium of the film, employing Schirmer's paper strips. Following the method of the sweat test, which consists in measuring the concentration of sodium employing filter paper on the epidermis of children with fibrocystic disease of the pancreas, we evaluate the concentration of sodium which we obtain from tears by humidifying a strip of Whatman 41 paper in the habitual way for Schirmer's test.

Subsequently by using colorimetry we measure sodium concentration in same.

Normally the mean concentration of sodium in the tear film is in the range of 134–170 meq/L; in patients with dry eye concentration, it increases to extreme values (500 meq/L). Later, and employing van't Hoff's formula, we may assess the osmotic pressure of the ion sodium and the indirect index of the film's osmolarity.

$$\text{van't Hoff formula: osmotic pressure} = C \times R \times T \quad (1)$$

where C is the concentration of the solution, R the universal constant of gases, and T the absolute temperature.

3. Other investigations

In the last decade, numerous authors have highlighted the importance of hyperosmolarity of the tear film in the pathophysiology of dry eye. Lemp et al. [19] and collaborators also grant a significant diagnostic role. Liv et al. [20] relate the instability of the tear film with the increase in osmolarity and give it a fundamental role in the cascade of pathological events that on the ocular surface is capable of generating.

The importance of hyperosmolarity is such that authors such as Hirata et al. [21] suggest that the increased osmolarity of the tear film induces functional and structural lesions of the corneal nerves and neurotoxicity.

In 2010, Mesmer et al. [22] determined that hyperosmolarity is an important factor in the pathophysiology of dry eye.

More recently, the final report of the pathophysiology subcommittee of the TFOS DEWS II [23] concluded that the core mechanism of dry eye is evaporation-induced tear hyperosmolarity that produces a vicious circle (Figure 1). When osmolarity rises it causes damage on the ocular surface both directly and by initiating inflammation.

This subcommittee concluded: “tear hyperosmolarity is considered to be the trigger for a cascade of signaling events within surface epithelial cells, which leads to the release of inflammatory mediators and proteases. Such mediators, together with the tear hyperosmolarity itself, are understood to cause goblet cell and epithelial cell loss and damage to the epithelial glycocalyx. Inflammatory mediators from activated Tcells, recruited to the ocular surface, reinforce damage. The net result is the characteristic punctate epitheliopathy of DED and a tear film instability which leads at some point to early tear film breakup. This breakup exacerbates and amplifies tear hyperosmolarity and completes the vicious circle events that lead to ocular surface damage.”

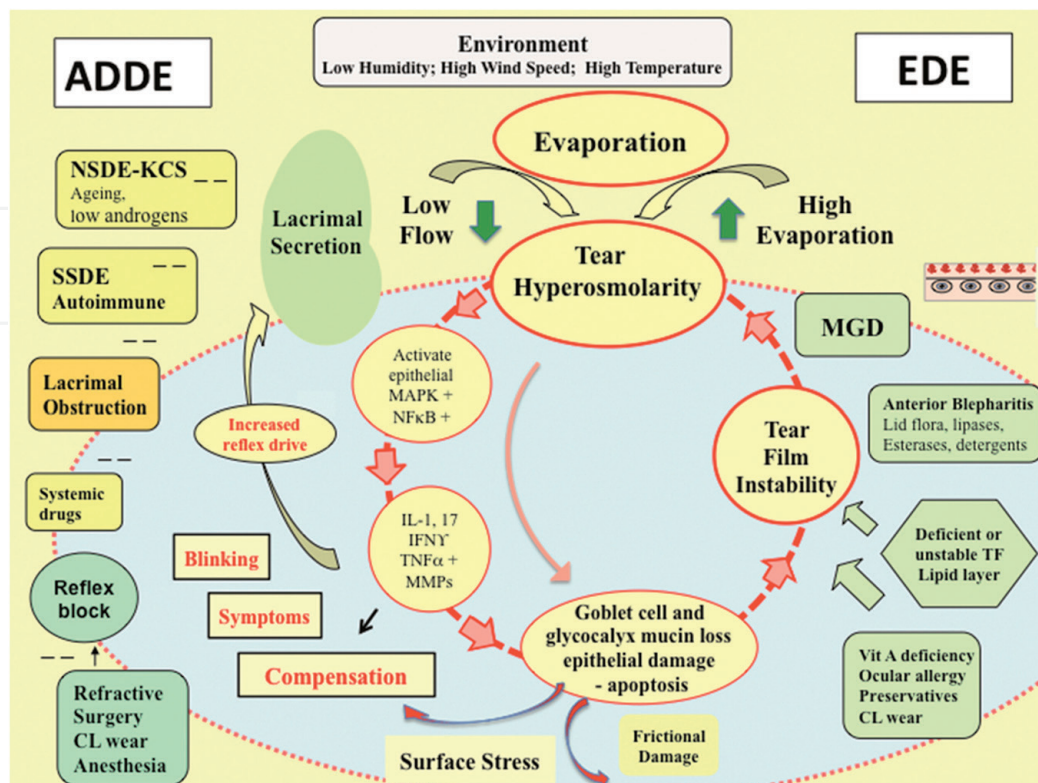


Figure 1. The vicious circle of dry eye disease. Image obtained from TFOS DEWS II 2017 pathophysiology subcommittee.

4. Conclusions

Undoubtedly, dry eye is nowadays one of the problems most commonly diagnosed by ophthalmologists. The dry eye is a complex multifactor illness of the tear film and of the ocular surface (cornea, conjunctiva, palpebral anexus, glands and nerves) characterized by symptoms of discomfort, vision alterations, and instability of the pre-corneal tear film that may bring about potential damage on the ocular surface. Instability of the film will produce increasing of osmolarity of the tear film, which will trigger epithelium osmotic lesions and inflammation. As these changes take place on the ocular surface, neurophysiologic mechanisms of homeostasis will be altered, which will complicate the process even further, with the cropping up of vicious physiopathologic circuits.

The knowledge of its physiopathologic triggering and its early diagnosis will allow a better management of this pathology. In this sense, evaluation of osmolarity of the tear film in these patients, even if it does not give us an etiologic diagnosis of the disease, does give us an efficient tool to diagnose and evaluate the disease, as its values are directly proportional to the severity of the clinical picture of the dry eye, and is always present in these patients.

Author details

Alejandro Aguilar^{1,2*} and Alejandro Berra³

1 Ocular Surface Department, Grupo Médico Las Lomas, San Isidro, Buenos Aires, Argentina

2 Ophthalmology Department, Universidad del Salvador, Buenos Aires, Argentina

3 Research Ocular Department, Universidad de Buenos Aires, Buenos Aires, Argentina

*Address all correspondence to: aguilar.alejandrojavier@usal.edu.ar

IntechOpen

© 2019 The Author(s). Licensee IntechOpen. This chapter is distributed under the terms of the Creative Commons Attribution License (<http://creativecommons.org/licenses/by/3.0>), which permits unrestricted use, distribution, and reproduction in any medium, provided the original work is properly cited. 

References

- [1] Aguilar AJ. Ojo seco, manual sobre fisiopatogenia, diagnóstico y tratamiento. Buenos Aires: Ediciones Científicas Argentinas; 1999. 196 p
- [2] Aguilar AJ, Fonseca L, Croxatto OJ. Sjögren syndrome: A comparative study of impression cytology of the conjunctiva and the bucal mucosa, and salivary gland biopsy. *Cornea*. 1991;**10**:203-206
- [3] Gilbard JP, Farris RL. Tear osmolarity and ocular surface disease in keratoconjunctivitis sicca. *Archives of Ophthalmology*. 1979;**97**:1642-1646
- [4] Holly FJ, Patten JT, Dohlman CH. Surface activity determination of aqueous tear components in dry eye patients and normals. *Experimental Eye Research*. 1977;**24**:479-491
- [5] Gilbard JP, Farris RL, Santamaria J. Osmolarity of tear microvolumes in keratoconjunctivitis sicca. *Archives of Ophthalmology*. 1978;**96**:677-681
- [6] Holly FJ, Lamberts DW. Effect of nonisotonic solutions on tear film osmolarity. *Investigative Ophthalmology & Visual Science*. 1981;**20**:2336-2345
- [7] Aguilar AJ, Rodriguez M, Fonseca L, Marré D. El test de Schirmer como método de medida de la concentración de Sodio del film lagrimal y de su osmolaridad en pacientes portadores de ojo seco: Claves de la fisiopatología de la lesión sicca. *Archivos de Oftalmología de Buenos Aires*. 1993;**68**:189-193
- [8] Glasstone D. Elementos de fisicoquímica. Editorial Médico Quirúrgica: Buenos Aires; 1952. 847 p
- [9] Fujikawa LS, Foster CS, Gipson IK, Colvin RB. Basement membrane components in healing rabbit corneal epithelial rounds: Immunofluorescence and ultrastructural studies. *Journal of Cell Biology*. 1984;**98**:128-138
- [10] Funderburgh JL, Cintron C, Covington HI, Conrad GW. Immunoanalysis of keratan sulfate proteoglycan from corneal scars. *Investigative Ophthalmology & Visual Science*. 1988;**29**:116-124
- [11] Tseng SCG, Hirst LW, Maumenee AE, Kenyon KR, Sun TT, Green WR. Possible mechanisms for the loss of goblet cells in mucin-deficient disorders. *Ophthalmology*. 1984;**91**:545-552
- [12] Berra A, Berra M. Hyperosmolarity induce nuclear translocation of NF-KB in human conjunctiva epithelial cells. *Investigative Ophthalmology & Visual Science*. 2005;**46**:4402
- [13] Nelson JD. Impression cytology. *Cornea*. 1988;**7**(1):71-81
- [14] Khanal S, Tomlinson A, McFadyen A, Diaper C, Ramaesh K. Dry eye diagnosis. *Investigative Ophthalmology & Visual Science*. 2008;**49**(4):1407-1414
- [15] Lemp MA. Report of the National Eye Institute/Industry workshop on clinical trials for dry eye. *The CLAO Journal*. 1995;**21**:221-232
- [16] Labbé A, Brignole-Baudouin F, Baudouin C. Ocular surface investigations in dry eye. *Journal Français d'Ophtalmologie*. 2007;**30**:76-97
- [17] Tomlinson A, Khanal s, Ramaesh K, Diaper C, McFadyen A. Tear film osmolarity: Determination of a referent for dry eye diagnosis. *Investigative Ophthalmology & Visual Science*. 2006;**47**:4309-4315
- [18] Berra I, Aguilar AJ, Berra A. Clinical and laboratory tests in patients with dry

eye, allergic conjunctivitis and dry eye plus allergic conjunctivitis. In: ARVO Meeting 1999 May 14

[19] Lemp MA, Bron AJ, Somez B, et al. Clinical utility of objective tests for dry eye disease. *American Journal of Ophthalmology*. 2011;**151**:792-798

[20] Liv H, Begley C, Chen M. A link between tear instability and hyperosmolarity in dry eye. *Investigative Ophthalmology & Visual Science*. 2009;**50**:3671-3679

[21] Hirata H, Miserska K, Mafurt C, Rosenblatt M. Hyperosmolar tears induce functional and structural alterations of corneal nerves: Electrophysiological and anatomical evidence toward neurotoxicity. *Investigative Ophthalmology & Visual Science*. 2015;**56**(13):8125-8140

[22] Mesmer EM, Bulgen M, Kampik A. Hyperosmolarity of the tear film in dry eye syndrome. *Developments in Ophthalmology*. 2010;**45**:129-138

[23] Bron A et al. TFOS DEWS II pathophysiology report. *The Ocular Surface*. 2017;**15**:438-510

IntechOpen