

Overview of the Inca Frozen Mummies From Mount Lullaillo (Argentina)

Constanza Ceruti

Institute of High Mountain Research at the
Catholic University of Salta (UCASAL)

constanza_ceruti@yahoo.com

Three frozen bodies belonging to a young woman and two infants were found at an elevation of 6.715 meters (22,100 ft.) above sea level, on the summit of volcano Lullaillo, in the Andes of northwestern Argentina. The mummies were discovered (and recovered for ulterior preservation and study) during scientific excavations co-directed by the author of this paper at the highest archaeological site in the world. The mummies belonged to children that were sacrificed five hundred years ago, under the rule of the Inca Empire, as part of a state-controlled ceremony known as *capacocha*. According to the historical sources written during the Hispanic conquest, the Inca human sacrifices were performed in response to natural catastrophes, the death of the Inca emperor, or to propitiate the mountain spirits that grant fertility. The selected children and the young *acllas* or “chosen women” were taken in processions to the highest summits of the Andes to be sacrificed. They were believed to become messengers into the world of the mountain deities and the spirits of the ancestors. Numerous interdisciplinary studies were conducted on the frozen mummies between 1999 and 2004, a time span during which the “Lullaillo children” were preserved at the Catholic University of Salta (UCASAL). These studies included radiological evaluations by conventional X-rays and CT scans, which provided information about condition and pathology of the bones and internal organs; as well as dental studies oriented to the estimation of the ages of the three children at the time of death. Ancient DNA studies and hair analysis were also performed in cooperation with academic institutions in the United States and Europe, including the Institute of Bioscience at the George Mason University, the University of Bradford and the Laboratory of Biological Anthropology at the University of Copenhagen. In this paper we focus on the frozen bodies of mount Lullaillo as objects for bioarchaeological and medical research, providing an overview on the paleopathology of the mummies that are among the best preserved known to date.

Keywords: mummies, paleopathology, sacrifice, Inca Empire, Mount Lullaillo

Introduction

Five hundred years ago, the Inca civilization conducted religious rituals on top of the highest Andean mountains of South America, building shrines on many of their summits and performing human sacrifices atop the most important peaks. The extraordinary preservation of the victims' bodies as well as of many of the grave goods recovered in the extremely cold and dry high elevation Andean environment provides exceptional bio-anthropological evidence for the paleopathological analysis of Inca frozen mummies.

The Inca Empire spread from its capital at Cuzco (located heartland in the Peruvian highlands) northwards to southern Colombia and as far south as central Chile. Since its beginning in 1438 AD until the Spanish conquest in 1532 AD, the Incas achieved the highest level of sociopolitical organization in the history of Andean civilizations. In a span of less than a hundred years they constructed shrines on the summits of nearly two hundred snow-capped peaks over 5,000 m in elevation.

The sacrifice of young women and children on the most prominent mountaintop scenarios was performed as part of an Inca ceremony called *capacocha*, oriented to appease the deities and propitiate the well being of the Inca emperor and the local communities (Duviols 1976). According to the chronicles written during the Spanish conquest, sacrificial victims were sent into the afterlife as messengers to the main deities of the Inca pantheon: the creator god *Viracocha*, the sun god *Inti*, and the thunder deity *Illapa* (Polo 1916). Children were selected because of the shared belief that their purity made them more acceptable to be with the gods (Cobo 1996; cf. Ceruti 2010). Reaching the distant sacred mountains of destination could require months of travel over thousands of miles. Processions would have included priests, their assistants, and inhabitants of the region through which the pilgrimage passed (Molina 1959; cf. Ceruti 2003).

To date more than a hundred Andean mountains with sanctuaries on their peaks have been surveyed by high altitude archaeologists in northern Argentina (see Ceruti 1998, 1999, 2001b, 2003b, 2003c, 2004b, 2005c, 2008a and 2010b; Reinhard and Ceruti 2010; Schobinger 1986, 1996 and 1998). Approximately seventy percent of the documented high altitude archaeological sites show evidence of the impact of destructive processes (Ceruti 2004b). The preservation of the architectural and artifactual evidence of mountaintop sanctuaries is found to be threatened due to human and natural factors. As a result of the activity of treasure hunters and looters in past decades, ever more damaging processes are affecting archaeological structures and bringing about the near-total destruction of mummified bodies and grave goods. This has been the case for the female mummy dynamited at a height of more than 6000 meters alongside an Inca platform near the snow-capped peak of Mt. Quehuar, in northern Argentina (see Reinhard and Ceruti 2005; Ceruti 2001b). The mummy from the snow-capped Chuscha mountain, and the structure there which originally was buried suffered considerable damage by treasure hunters during the early 1920s (see Ceruti 2004c). Similar was the fate of the infant mummy discovered on the heights of mount Chañi in 1905 (see Ceruti 2001 and 2007).

The extinct volcano Lullaillo, located in the Andes of northwestern Argentina, was turned into a ceremonial complex under the influence of the Inca Empire. Built



Figure 1 Volcano Lulllaillaco in northern Argentina (© Constanza Ceruti).

at an altitude of 22,110 ft. (6,739 meters above sea level), the mountain-top shrine of Lulllaillaco is considered to be the highest ceremonial site in the world (Reinhard and Ceruti 2010). Archaeological research conducted by Johan Reinhard and Constanza Ceruti at the Inca ceremonial complex of mount Lulllaillaco led to the discovery and excavation of three Inca frozen mummies and more than one hundred sumptuary offerings that were buried five hundred years ago. The expedition was co-directed by the author of this paper, who personally supervised the archaeological work undertaken on the summit. Team members included Peruvian and Argentinean archaeology students, as well as mountain climbers of both nationalities and indigenous members of the Quechua community. The project was officially authorized by the Direction of Cultural Heritage in Salta and the financial support to undertake the expedition to mount Lulllaillaco was provided by a grant from the National Geographic Society. Assistance for transportation to and from the mountain was provided by the National Army of Argentina, with the collaboration of the local communities of Tolar Grande and San Antonio de los Cobres.

The archaeology of mount Lulllaillaco—including its architectural and landscape features—has been studied and published in detail (cf. Reinhard and Ceruti 2000; Ceruti 2003). It has also been analyzed in the context of Inca religion and sacred landscape in the Andes (Reinhard and Ceruti 2006, 2010). The material offerings associated to the Lulllaillaco mountaintop burials have been described and studied extensively in terms of their social use and symbolic meaning (Ceruti 2003). Expert work has been undertaken on the technological analysis of the textile objects; and pottery items have been subjected to neutron activation analysis to help identify their geographical origin (Bray *et. al.* 2005).



Figure 2 Inca shrine on the summit of mount Llullaillaco, the highest ceremonial site in the world (© Constanza Ceruti).

This article will provide an overview on the paleopathology of the frozen bodies from mount Llullaillaco, among the best preserved Ice mummies known to date. The Llullaillaco mummies have been previously analyzed in the context of the diversity of mummies worldwide (Ceruti 2010); as objects of dedication (Ceruti 2004), and in connection to the religious role of children in the Andes (Ceruti 2008, 2010). This study focuses on the frozen mummies of Llullaillaco as objects of bioarchaeological and medical research.

Materials and methods

Three Inca frozen mummies and associated objects were found at an elevation of 22,100 feet (6.715 m), on the summit of Mount Llullaillaco, in northwestern Argentina. The ancient frozen bodies were buried about 1.7 m. deep inside three pit tombs which had been constructed by enlarging natural niches in the bedrock. They were covered with artificial fill which was used to build a platform on top of the burials. A thin layer of permafrost had formed at the most superficial level of the platform, but the bodies were separated from it and entirely surrounded by volcanic ashes that could be gently excavated using trowels and brushes (Ceruti 2003a; Reinhard and Ceruti 2000).

Placed in a seated position and facing east, the first individual recovered was an infant male, about seven years old, whose body was buried in a hyperflexed posi-



Figure 3 The funerary bundle of the Lullaillo boy in situ (© Constanza Ceruti).

tion, with the legs over his body and wrapped around with ropes. This mummy was covered in a red outer mantle (Ceruti 2003a; Reinhard and Ceruti 2010).

The second individual was a young female known colloquially as the Lullaillo “maiden” and she was about fourteen years old. She was sitting in a laid back position, facing northeast, with her legs crossed and her body covered with two brown outer mantles. A feathered headdress was placed on her head, and a tunic on her shoulder, being both pieces left outside the funerary bundle. Numerous textile and ceramic items of typical Inca style were placed around her body on the bottom of the tomb (Ceruti 2003a; Reinhard and Ceruti 2006).

The tomb located on the eastern sector of the platform was only 80 cm wide and about 1.75 m deep, built in a narrow niche of the bedrock. The body, which got hit by lightning while buried, belonged to a 6 year old child, colloquially known as “the lightning girl.” It had been placed in a seating position and facing west (Ceruti 2003a; Reinhard and Ceruti 2010).

To maintain their preservation, a number of strategies were employed at different stages in the excavation and in the mummies’ subsequent transportation to and storage in a laboratory. During the excavation, the mummy bundles and other artifacts were wrapped in plastic and aluminum foil after they had been recovered from the burials. Kept covered in snow to better protect them against sunlight, they were




Figure 4 The discovery of the Inca female mummy on the summit of Lullallaco (© Constanza Ceruti).

later transported down the mountain wrapped in insulating materials. The laboratory, some 500 km distant. During the 500 km trip to the laboratories on campus, the mummies were kept in wooden boxes containing dry ice. Once in Salta, they were removed from the boxes and placed in freezers.

The governmental authorities entrusted Salta's Catholic University with the temporary custody of the three mummies and the other artifacts recovered from Lullallaco. More than 20 specialists from different parts of the world provided advice as honorary members of a committee established for the preservation of materials recovered from mountaintop sites. A laboratory was set up at the university campus, with three rooms dedicated to the conservation of the mummies and artifacts. Five freezers were connected to a generator that automatically supplied energy in the eventuality of a breakdown of electricity. Each mummy was located in its own freezer, and there was a spare freezer available in the eventuality of an engine failure. The mummies were wrapped first in a layer of sterilized surgical material and then in a layer of acid-free cotton cloth. They were covered in transparent plastic sheets that were sealed to avoid the loss of the humidity in the corpses, as well as the incorporation of humidity from the environment. The bodies were preserved at a temperature of -13°C to slow down as much as possible the chemical and biological processes

Overview of the Inca Frozen Mummies From Mount Lullaillo (Argentina)

responsible for the destruction of soft tissues, without endangering the mummies by exposing them to lower temperatures that could potentially have an impact on the condition of the cellular walls. The microenvironment that surrounded the mummies inside the freezers was controlled with the use of silica gel, with relative humidity values between 45 and 65 percent (see Ceruti 2003b). The temperature and humidity inside the freezers were monitored by thermometers and hygrometers. The laboratory was protected with an alarm system—against fire and robbery—and provided with permanent around-the-clock police protection. The atmosphere in the laboratory was controlled with an air-conditioning system, and cold lights were installed to illuminate the rooms. Access to the laboratory was restricted to the scientists who coordinated the research and to the personnel from Salta's Cultural Patrimony Office (see Reinhard and Ceruti 2010, appendix D).

The strategy of preservation of the Lullaillo frozen mummies involved daily control of the conditions of temperature and humidity in the freezers, combined with limited working sessions in which several interdisciplinary studies were performed simultaneously. Working sessions with the mummies and other organic materials were undertaken as part of a plan of periodic controls that involve macroscopic exams, microbiological analysis, photography, and filming. The sessions with the frozen mummies were limited to a maximum duration of 20 minutes and were planned several months in advance. The participation of different specialists was coordinated in order to maximize the use of the time when the mummies were out of the freezers.



Figure 5 Inca offerings from Mount Lullaillo (© Constanza Ceruti).

Numerous interdisciplinary studies on the Lulluillaco mummies were conducted by the author of this paper between 1999 and 2004, during the time in which the mummies were preserved at the Catholic University of Salta. Research undertaken in consultation with Johan Reinhard involved the participation of local scientists based at the Institute of High Mountain Research in UCASAL (Ceruti *et. al.* 2008). These included radiological evaluations—conventional X-rays and CT scans—which provided information about condition and pathology of the bones and internal organs (Previgliano *et. al.* 2003a and 2003b; Previgliano *et. al.* 2005), and dental studies oriented to the estimation of the ages of the three Lulluillaco children at the time of death (Arias Araoz *et. al.* 2002). DNA analysis was performed in cooperation with the Institute of Bioscience at the George Mason University. The University of Bradford collaborated in the analysis of hair samples from the mummies (cf. Wilson *et. al.* 2007; Brown *et. al.* 2008). The Laboratory of Biological Anthropology at the University of Copenhagen contributed to the 3D reconstruction of the inner organs of the children based on the original CT scans (Villa *et. al.* 2010).

While at Catholic University, examination of the mummies and materials always took place inside the laboratory. In the case of X-ray studies, a complete set of radiological equipment had to be installed in order to avoid any risk in the transportation of the mummies outside the laboratory. The studies that were undertaken were primarily noninvasive in order to maintain the integrity of the mummies' body tissues and interior organs. Microbiological tests performed proved negative, suggesting that microorganisms in the environment had not affected the mummies.

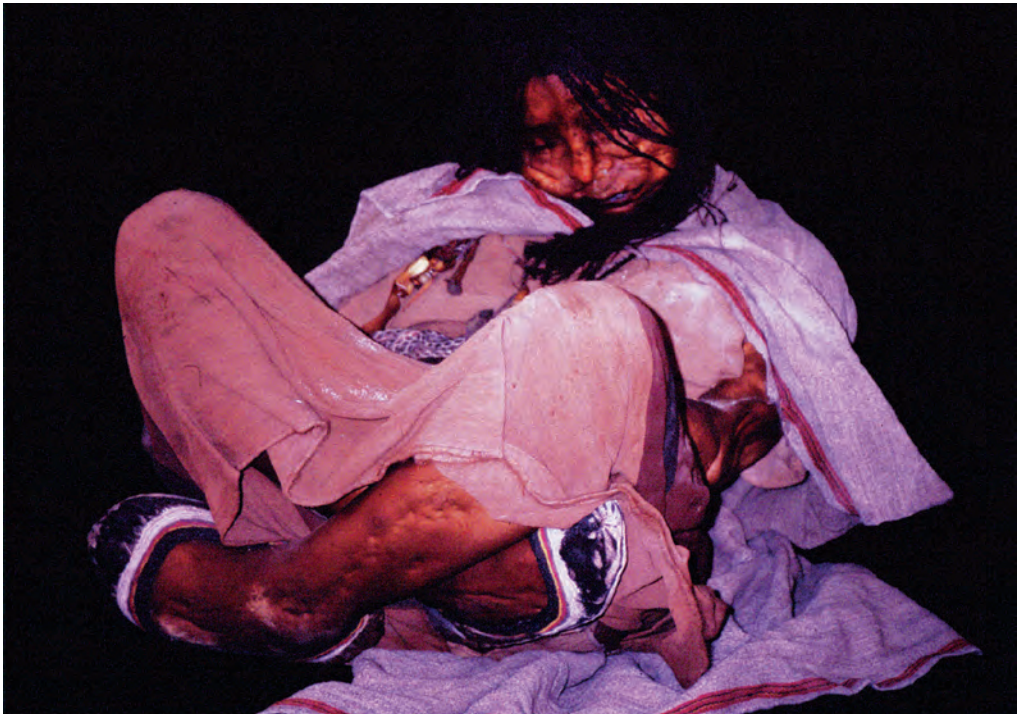

Figure 6 Frozen mummy of the Inca Maiden of Lulluillaco (© Constanza Ceruti).

Overview of the Inca Frozen Mummies From Mount Lullaillo (Argentina)

In August of 2004, the mummies were transferred to a laboratory in the Museum of High Mountain Archaeology (MAAM), which is located in the city center. Nowadays the mummies are preserved in airtight, self-contained capsules and maintained at 220uC, in a mix of liquid nitrogen vapor and 2% oxygen (Corthals *et. al.* 2012). They are alternatively presented to the public view, together with a permanent exhibit on the associated pottery and textile offerings (Reinhard and Ceruti 2010).

Description

The Lullaillo mummies are unusual even among the world's few Ice Mummies (see Aufderheide 2003; Dickson 2011). This is due to the fact that the bodies of the Lullaillo children were frozen immediately at the time of death and have remained so continuously until their discovery five centuries later. The outstanding condition of the mummies was the result of the combination of freezing temperature, mild humidity and the anaerobic environment. The presence of natural disinfectants in the volcanic ashes could also have played a role (Angelique Corthals, personal communication 2004).

The mummy of the Lullaillo boy is wearing a red tunic, leather moccasins, fur anklets, a silver bracelet and a sling wrapped around his head, with his forehead adorned with white feathers. His body is in a hyperflexed position, with his legs tied up with ropes. The Lullaillo maiden is wearing a sleeveless brown dress and a gray shawl—both kept in place with golden pins— and leather moccasins on her feet. She has some bone and metal adornments pending from her right shoulder and red pigments on her face. Her hair is combed in many little braids. The body of the younger girl is partially damaged by the impact of lightning. The skin of her neck and left shoulder is damaged, and she had a cavity in her chest caused by the electrical stroke. She is wearing a sleeveless dress and a shawl, both kept in place with metal pins and moccasins on her feet.

Crania and face

The cranial CT scans of the three Lullaillo mummies show a clear differentiation of white and gray matter in the brain and cerebellum due to the change of the fat into adipocere (Previgliano *et. al.* 2005). By means of computerized 3D reconstructions based on those CT-scans it is also possible to visualize different areas of the brain, including the encephalon, the cerebellum and the medulla (Villa *et. al.* 2011). The computerized 3D reconstructions of the cranium and encephalic mass of the mummies performed at the Laboratory of Bioanthropology at the University of Copenhagen have allowed Niels Lynnerup and Chiara Villa to estimate the volume of the brain and the cranial capacity. With a cranial capacity of 1243 cm³ and a brain volume of 713 cm³, the maiden's brain suffered a volumetric reduction of about 43%. With a cranial capacity of 1224 cm³ and a brain volume of 765 cm³, the lightning girl's brain suffered a volumetric reduction of about 38%. Finally, with a cranial capacity of 1274 cm³ and a brain volume of 832 cm³, the boy's brain suffered the less significant volumetric reduction of about 35%. The volumetric reduction was likely caused post-mortem by dehydration, since there are no evidences of neurological diseases suffered by the children (Villa *et. al.* 2011).



Figure 7 Inca mummy of the Lulluillaco boy (© Constanza Ceruti).

The mummies of the boy and the younger girl show no evidences of pathological conditions associated with the crania and face, with the exception of bi-protrusion, as showed in the cephalometric analysis (Arias Araoz *et. al.* 2002). The dental X-rays show no evidences of cavities in any of the mummies. The two younger children show a pattern of severe wearing of the crowns of the teeth, which could not be observed in the older female (Arias *et. al.* 2002).

Frontal and lateral cranial radiographic views of the maiden and other two mummies show no fractures or signs of trauma; but they do show cranial deformation in the two younger individuals. Occipital-parietal deformation can be observed in the boy, whereas the younger girl evidences both, frontal-parietal and occipital-parietal deformation (Previgliano *et. al.* 2003a).

In the case of the maiden, one of the maxillary sinuses shows a mucous enlargement compatible with sinusitis (Previgliano *et. al.* 2003b). Visual inspection revealed the presence of streaks of mucus under both nostrils. Ulterior tests confirmed the presence of blood around the lips of the boy (Corthals *et. al.* 2012).

Thorax

The thoracic CT scans of the three mummies show that the lungs are expanded, with the main bronchi, lung arteries, aorta and heart in a nearly perfect state of preservation. Even the younger female individual has the inner organ in excellent condition, in spite of the damage caused by lightening on the skin and muscles.

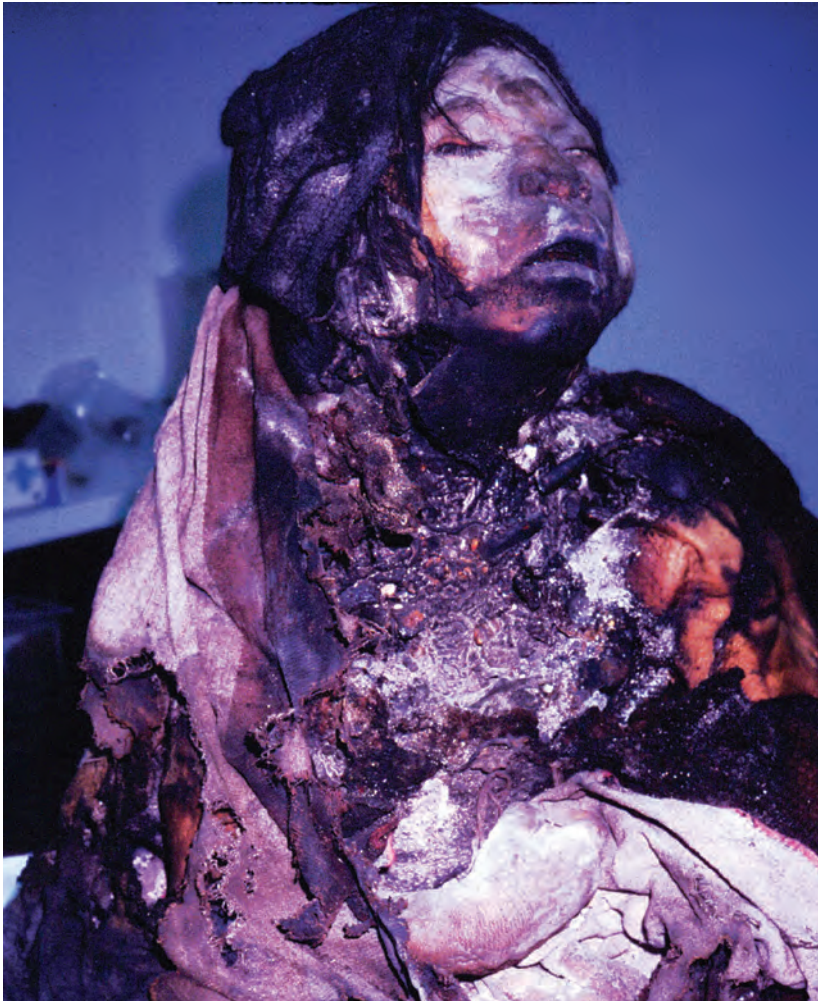

Figure 8 The mummy of the Lightning Girl (© Constanza Ceruti)

The upper lobe of the right lung of the older female shows a triangular hypodense zone corresponding to an abnormal air-trapping area, which led Carlos Previgliano to diagnose that the older female had suffered from obliterative bronchiolitis. The computerized 3D images reveal that there are hyperdense opacities in the aorta and vena cava of the maiden, which seem to correspond to clots with calcifications (Villa *et. al.* 2011). CT-scans and radiological analyses do not show signs of upper respiratory or pulmonary infections in the boy (Previgliano *et. al.* 2003a).

Abdominal cavity

In the abdomen of the three Lullailaco mummies, the majority of the organs, including the pancreas, are in nearly perfect state of conservation. The size of the liver and kidneys is reduced but they maintain their shape; whereas the spleen could not be seen in either of the individuals (Previgliano *et. al.* 2003a).



Figure 9 The Llullaillaco Maiden (© Constanza Ceruti).

The intestines of the mummies contain feces, proving that the children had eaten a solid meal a few hours prior to their death (Previgliano 2003b). The sagittal 3D view of the intestines of the younger girl shows a dilation of the sigmoid and rectum, which can be a sign of constipation or overfeeding (Villa *et. al.* 2011).

The CT images in the pelvic cavity show the primary genital organs, such as the uterus in the older female and the boy's penis, perfectly preserved. A thick layer of fatty tissue is also observable, suggesting that the children were abundantly fed during the weeks prior to their death (Previgliano *et. al.* 2005).

Post cranial X-rays and CT-scans

Radiographs of the rest of the body of the mummies have allowed to rule out degenerative diseases affecting the bones (Previgliano *et. al.* 2005). According to the radiologist, no Harris lines were present, which would have been an indication of periods of malnutrition or disease. Perfect bone mineralization and adequate muscular volume are observable (Previgliano 2003a).

DNA studies

Muscle samples extracted by needle biopsy were originally destined for ancient DNA studies performed at the Institute of Bioscience—George Mason University. The qual-

Overview of the Inca Frozen Mummies From Mount Lullaillo (Argentina)

ity of the samples proved to be the best ancient DNA ever recovered from an ancient body (Keith Mc Kenney, oral communication at the IV World Congress of Mummy Studies in Nuuk, September 2001). The analysis of mitochondrial DNA revealed that the three Lullaillo mummies did not share a common maternal ancestor. Ulterior DNA studies were also performed by Angelique Corthals.

Hair analysis

Hair samples from the Lullaillo mummies were initially studied at the Valley View Regional Hospital in Oklahoma. They all tested positive for cocaine, with levels that revealed intensive consumption, particularly in the case of the maiden (Larry Cartmell, oral communication at the IV World Congress of Mummy Studies in Nuuk, September 2001).

Hair samples were later extracted by Andrew Wilson to be processed at the University of Bradford for paleodietary analysis and for ancient DNA studies – the later in cooperation with Tom Gilbert, from the University of Arizona. Stable isotope analysis on the hair samples of the three mummified children revealed first-hand information on individual diet, such as the fact that it became enriched in animal proteins and C4 plants about five months prior to their deaths (Wilson *et. al.* 2007). The maiden's hair was also analyzed in search for evidences of alcohol ingestion during the final months of her life (Brown *et. al.* 2008). Thus it has been possible to reconstruct aspects of the process in which the children were selected; elevated in status and prepared for the high-altitude pilgrimage that would eventually lead to their sacrifice (Wilson *et. al.* 2013).

Discussion and conclusions

Inca Ice mummies which have been exceptionally preserved in the cold and dry climate of the Andean summits, offer invaluable bioarchaeological evidence for paleopathological studies of life, death, health and cultural practices in the ancient Andes. The frozen bodies of the three Inca children from mount Lullaillo have provided new details about Inca mountaintop sacrifices, including information on the age and sex profile of the selected victims, inferences about their health and glimpses of their social and ethnic origin. The physical evidences have revealed strong coincidences with the ethnohistorical descriptions of the Inca ceremonies, regarding the profile of the victims chosen for the *capacocha* and the sacrificial techniques involved.

Age at death

Following Carmen Nolla's developmental table, the ages of the Lullaillo children were originally estimated in fifteen years for the maiden, seven years for the boy and six and a half years for the girl (Arias Aráoz *et. al.* 2002; Previgliano *et. al.* 2005). The more recent estimations based on the 3D computerized reconstructions of long bones and teeth suggest a younger age for the three children: about 13 years for the older girl and between four and five years for the younger individuals (Villa *et. al.* 2011).

According to the historical sources (Cobo 1996, 235) children younger than ten years old were annually given by ancient Andean communities as tribute to the Inca Empire. Sometimes, the sons and daughters of the local chiefs were given to the Emperor to be

sacrificed, in order to establish an alliance (Hernández Prncipe 1986, 473). There were also chosen women or *acllas*, selected by their beauty at the age of eight, secluded as virgins in special institutions until they became fourteen, and then taken out to be given as wives or to be sacrificed to the gods (Acosta 1962, 241). The Llullaillaco mummies can be interpreted in the light of these historic accounts, providing evidence of the two mechanisms described above. The Llullaillaco maiden, being anywhere between 13 and 15 years old, was most likely a “chosen woman.” The younger children could either have been presented to the Inca by their noble parents, or sent to the city of Cusco as a tribute offered by their home communities (Ceruti 2005a).

Cultural modifications

Artificial cranial deformation, as observed in the X-rays of the Llullaillaco younger individuals, was traditional among Andean communities during the time of the Incas. The historical sources reveal that the beliefs towards the sacred mountains played a part in the practice of artificial cranial deformation, since the heads were expected to reproduce the shape of the volcanoes that were considered to be the “place of origin” of each community (Ulloa Mogollón 1965). Differences in the procedures involved in the artificial cranial deformation, in addition to the results provided by DNA studies, suggest that the three Llullaillaco children probably did not come from the same communal ethnic background.

Pathological condition

The mummy of the Llullaillaco maiden shows radiological evidences that are compatible with maxillary sinusitis (Previgliano *et. al.* 2003a). The abnormal air trapping area in her right lung, observable in the CT scans, was diagnosed as a probable constrictive bronchiolitis (Previgliano *et. al.* 2003a). The etiologies of this pathology are varied, and in this case it appeared to be postinfectious, particularly given the long period of time that, according to the historical sources, the individuals were expected to walk from the capital city of Cuzco towards the mountain where they would be sacrificed (Reinhard and Ceruti 2010).

Results of a study published recently by Angélique Corthals confirmed that the maiden was suffering from a severe pulmonary bacterial infection at the time of death. Shotgun proteomics were used for the first time from an ancient sample to detect the protein expression profile of mouth swabs. The profile of the maiden was consistent with immune system response to severe pulmonary bacterial infection caused by *Mycobacterium* sp. Whereas DNA extraction and amplification only establish pathogen presence rather than active disease, this study provided evidences of active pathogenic infection (Corthals *et. al.* 2012).

The wear of the crowns of the teeth, which is particularly evident in the case of the younger individuals from mount Llullaillaco, could be produced by diet. The typical Andean diet, based on a high proportion of corn, can cause patterns of dental wear due to the grinding of the grain with pestles, a process in which silica particles are incorporated into the flour. The historical sources emphasize the ritual importance of the consumption of corn during Inca ceremonies (Arriaga 1984). This is in all con-

Overview of the Inca Frozen Mummies From Mount Lullaillo (Argentina)

sistent with the shift towards C4 plants revealed by the hair analysis of the Lullaillo children. However, other causes such as bruxism, parasites and stress can not be ruled out (Arias Araoz *et. al.* 2002).

An anatomo-pathologist based in Salta conducted a visual inspection of the areas of the bodies of the mummies that were not covered with clothing. He noticed the presence of a mole on the maiden's left arm and he observed a lesion on one of the boy's left fingers. A histological sample was taken and analyzed. Results showed that the boy had suffered from a condition known as *granuloma anular* (Gerardo Vides Almonacid, personal communication, 2003). The presence of moles and other lesions on visible parts of the bodies of the Lullaillo mummies is intriguing, since according to the ethnohistorical sources, the children selected by the Incas to be sacrificed in the *capacocha* ceremonies had to be unblemished, as a sign of their purity (cf. Ramos Gavilan 1976, 56–62).

Nutritional condition

The perfect bone mineralization, the adequate state of nutrition, as well as the absence of Harris lines in the radiological examination of the mummified bodies from mount Lullaillo indicate that the children belonged to a high social class. In fact, the historical narratives mention that the younger sacrificial victims were usually chosen among the sons and daughters of local chiefs, that were sometimes voluntarily offered to seal an alliance with the Inca emperor (Hernandez Principe 1986).

The Lullaillo children were subjected to a process of overfeeding, which started several weeks in advance and lasted until a few hours before death. CT scan showed their good muscular tone and a thick layer of fat tissue, indicating that the children were properly nourished. In addition, the CT scans showed feces in their intestines, which proved that the consumption of food had continued until a few hours before their death. Historical sources tell us that the sacrificial victims were overfed to guarantee that they would go happy and contempt into the world of the gods (Molina 1959).

Cause of death

The early Spanish chroniclers described different techniques used by the Inca priests to sacrifice human victims in diverse ceremonial contexts such as the *capacochas*. Children could alternatively be sacrificed by strangulation (Cieza 1959: 150), a blow to the head (Cobo 1996, 235; Gutierrez 1963, 233; Ramos Gavilán 1976, 25), by suffocation (Murúa 1946, 263; Ramos Gavilán 1976, 26), or by being buried alive (Betanzos 1996, 46; Cobo 1996, 235). Since no Europeans ever witnessed a sacrificial ceremony on a remote mountaintop shrine, their descriptions were based on secondary sources—mainly informants who had seen Inca sacrifices performed at the Sun temple of Cusco.

Bioarchaeological evidence from diverse mountaintop shrines supports the accounts in the chronicles. Strangulation seems to have brought about the death of two female Inca mummies discovered accidentally on the summit of a coastal hill named cerro Esmeralda, in northern Chile (Checura 1977). Signs of strangulation were also observed in the mummified adult male from mount El Toro, found above 6000 meters in the Andes of western Argentina (Schobinger 1966). Cranial trauma

was the cause of death in the case of the frozen mummies of the young women from mount Ampato and mount Sara Sara, in the Andes of Peru (Reinhard 1997 and 1998). It could also have been the sacrificial techniques used to kill a boy, whose frozen body was found buried on the slopes of mount Aconcagua (Schobinger 2001).

We can even infer that active sacrificial procedures (such as a blow to the head or strangulation) would only have been used by the priests as a last resort, as when death caused by exposure to the cold took too long to occur, or if resistance was offered by the children. The sacrificial role of the priests was apparently reduced to a minimum, making the high altitude mountain environment (with its low temperatures and extreme atmospheric conditions) a key participant in the process of bringing about the deaths of the victims. In other words, the ritual was designed to allow the mountain deity to actually take the life of the victim with the Inca religious attendants serving as subordinate facilitators in the sacrificial ritual.

There is no forensic evidence in the frozen bodies from mount Lulluailaco that could account for strangulation or cranial trauma. Therefore it is likely that these children—particularly the maiden and the lightning girl—died of exposure to the cold. Asphyxia or inebriation could also have played a part (Reinhard and Ceruti 2010). Based on the position of their bodies, we presume that the Lulluailaco maiden and the young girl reached the summit alive and died at the shrine.

The practice of burying children alive or of suffocating them prior to burial is consistent with the physical evidence of the female Lulluailaco children (Previgliano *et. al.* 2003a). From the ethnohistorical standpoint, it appears that the reason for selecting this particular sacrificial procedure was rooted in the belief that only “complete” offerings were acceptable to a major deity, who would be offended by the spilling of blood (cf. Murúa 1946, 263–264).

The Lulluailaco boy could have accidentally died on the way up the mountain, due to complications caused by the extreme elevation. This hypothesis was first enunciated in one of my earlier publications (Ceruti 2003a) as to account for the hyperflexed position of his body and the ropes wrapped around his legs—since those could have been necessary for postmortem transportation of his body to the burial site at the top. Recent studies have proven the presence of blood in samples of the boy’s saliva. The presence of blood in the samples from the mouth swap of the boy has been interpreted as the result of trauma (cf. Corthals *et. al.* 2012); and in the context of a National Geographic TV documentary Corthals mentioned the possibility of a wound causing internal bleeding. Since no conclusive evidences of trauma have been found so far on the CT-scans of the boy’s body, it appears more likely that the blood in the saliva could have been the result of pulmonary edema.

The significance of the Lulluailaco mummies goes beyond the strictly scientific. The international repercussions of the archaeological discovery and the interdisciplinary studies conducted on these frozen bodies have contributed to lend visibility to the needs of the indigenous communities in Argentina, motivating governmental authorities to recognize their rights, and inspiring society in general to become interested in their welfare. Consequently, in recent years, numerous communities have coalesced and formed in several Argentinean provinces, in the context of a

Overview of the Inca Frozen Mummies From Mount Lulllaillaco (Argentina)

strong and sustained native revival movement. In multi-cultural societies like that of Salta, whose social identity was traditionally anchored in the Hispanic arrival and the *gaucho* culture, the Andean cultural heritage has become substantially more highly valued. Since the discovery of the “children of Lulllaillaco” importance has begun to be placed on the study of the Inca civilization both in Salta and in other parts of Argentina, as part of the basic content of the school curriculum. There has also been a noticeable increment in the number of university students studying anthropology and archaeology. There has also been an increase in interest, on the part of the general public, in studying the Quechua language and pre-Columbian cultures. Likewise, there has been a notable augmentation in tourism in the region. This increases the possibility that young people born in rural areas can remain in their communities, instead of being forced to migrate to large cities in search of work (cf. Ceruti 2012).

Acknowledgements

The author would like to thank the institutional support of the National Council of Scientific Research in Argentina (CONICET), the Catholic University of Salta and the National Geographic Society. She would express her gratitude towards Johan Reinhard, Carlos Previgliano, Facundo Arias Araoz, Josefina González Díez, Andrew Wilson, Timothy Taylor, Chiara Villa, Emma Brown, Tom Gilbert, Larry Cartmell, Keith Mc Kenney; Arnaldo Arroyo, Gerardo Vides Almonacid, Martin Callanan, Oddmunn Farbregd, Brit Solli, Kalle Sognnes, Greg Hare, Bob Brier, Arthur Aufderheide, James Dickson, Rubén Gurevech, Niels Lynnerup, Keith McKenney, Gael Lonergan, Angélique Corthals, Andrew Merriwether, Ian Farrington, Clara Abal, Vuka Roussakis, Craig Morris, Juan Schobinger, Thomas Besom and Tamara Bray.

References

- Acosta, J. de. 1962 [1590]. *Historia Natural y Moral de las Indias*. México. Fondo de Cultura Económica.
- Arias Araóz, F., J. Gonzalez Diez and C. Ceruti. 2002. *Estudios Odontológicos de las momias del Lulllaillaco*. *Boletín de la Asociación Argentina de Odontología para Niños*. 31(2/3): 3–10.
- Arriaga, J. de. 1984 [1621]. *La Extirpación de las Idolatrías en Perú*. Programa de Investigaciones sobre Epidemiología Psiquiátrica (CONICET), vol 61. Buenos Aires.
- Betanzos, J. de. 1996 [1557]. *Narratives of the Incas*. Austin: University of Texas Press.
- Bray, T., L. Minc, M. C. Ceruti, J. A. Chávez; R. Perea and J. Reinhard. 2005. “A compositional analysis of pottery vessels associated with the Inca ritual of *capacocha*.” *Journal of Anthropological Archaeology* 24: 82–100. <http://dx.doi.org/10.1016/j.jaa.2004.11.001>
- Brown, E., T. Taylor, M. C. Ceruti, J. Reinhard, A. Healey, A. Nicolau and A. Wilson. 2008. “Evidence for Coca and Alcohol Ingestion in the final months of the Lulllaillaco Maiden’s life.” Póster científico presentado en Simposio de Bioarqueología en Oxford, Reino Unido.
- Ceruti, M. C. 1998. “Prospecciones en Sitios de Alta Montaña en el Noroeste Andino Argentino: Informe Preliminar.” *Tawantinsuyu* 5: 37–43. Canberra.
- . 1999. *Cumbres Sagradas del Noroeste Argentino*. Editorial de la Universidad de Buenos Aires (EUDEBA). Buenos Aires.
- . 2003. *Lulllaillaco: Sacrificios y Ofrendas en un Santuario Inca de Alta Montaña*. Ediciones de la Universidad Católica de Salta (EUCASA). Salta.

- . 2004a. “Human bodies as objects of dedication at Inca mountain shrines (north-western Argentina).” *World Archaeology* 36(1): 103–122. <http://dx.doi.org/10.1080/0043824042000192632>
- . 2004b. *Arqueología de Alta Montaña en La Rioja*. Ediciones de la Universidad Católica de Salta (EUCASA). Salta.
- . 2005a. “Elegidos de los Dioses: Identidad y Status en las víctimas sacrificiales del volcán Llullaillaco y de otros santuarios de altura Inca.” *Boletín de Arqueología* 7 (2003): 263–275.
- . 2005b. “Actores, ritos y destinatarios de las ceremonias incaicas de capacocha: una visión desde la arqueología y la etnohistoria.” *Xama* 15–18 (2002–2005): 287–299.
- . “Excavaciones arqueológicas de alta montaña en el Nevado de Chañi (5.896m.) y el Nevado de Acay (5.716 m.) Provincia de Salta.” *Arqueología argentina en los inicios de un nuevo siglo*. Publicación del XIV Congreso Nacional de Arqueología Argentina. Vol I, 53–69. Universidad Nacional de Rosario.
- . 2008a. “Panorama de los santuarios Inca de alta montaña en Argentina.” *Revista Arqueología y Sociedad* 18: 211–228.
- . 2008b. “Angelitos: culto a momias infantiles en el Noroeste de Argentina.” *Mummies and Science: World Mummies Research*. Proceedings of the VI World Congress on Mummy Studies, edited by P. Atoche Peña, C. Rodríguez Martín, Á. Ramírez Rodríguez and A. C. Aufderheide, 583–589. Santa Cruz, Tenerife: Academia Canaria de la Historia.
- . 2010a *Embajadores del Pasado: los niños del Llullaillaco y otras momias del mundo*. Editorial de la Universidad Católica de Salta (EUCASA). Salta.
- . 2010b. “The Religious Role of Children in the Andes, Past and Present.” *AmS Skrifter* 23: 125–133.
- . 2011. “Santuarios de Altura y Momias Incas en Salta.” *Boletín de Estudios Históricos de Salta* 49: 232–247.
- . In press. *Frozen Mummies and the Archaeology of High Mountains in the Construction of Andean Identity*. Translated by Monica Barnes. Proceedings of the International Symposium on Indigenous Revival and Sacred Sites Conservation. Edited by Fausto Sarmiento. Athens: Department of Geography, University of Georgia.
- , C. Previgliano, J. G. Díez, F. Arias Aráoz and J. Reinhard. 2008. *Síntesis de Estudios Interdisciplinarios en las Momias Congeladas del Volcán Llullaillaco*. En *Problemáticas de la Arqueología Contemporánea*. Actas del XV Congreso Nacional de Arqueología Argentina, vol. 2, 639–645. Universidad Nacional de Río Cuarto.
- Checura Jeria, J. 1977. “Funeraria Incaica en el Co. Esmeralda (Iquique, I Region).” *Estudios Atacameños* (5): 125–141.
- Cieza de León, P. 1959 [1553]. *The Incas of Pedro Cieza de León*. Edited by V. W. Von Hagen. Norman: University of Oklahoma Press.
- Cobo, F. B. 1996 [1652]. *History of the Inca Empire*. Austin: University of Texas Press.
- Corthals, A., A. Koller, D. W. Martin, R. Rieger and E.I. Chen, M. Bernaski, G. Recagno and L. M. Dávalos. 2012. “Detecting the Immune System Response of a 500 Year-Old Inca Mummy.” *PLoS ONE* 7(7): e41244. doi:10.1371/journal.pone.0041244. University of Calgary. Alberta. <http://dx.doi.org/10.1371/journal.pone.0041244>
- Duviols, P. 1976. “La Capacocha. Mecanismo y función del sacrificio humano, su proyección geométrica, su papel en la política integracionista y en la economía redistributiva del Tawantisuyu.” *Allpanchis* 9: 11–57.
- Gutiérrez de Santa Clara, P. 1963 [ca.1603]. *Quinquenarios o Historia de las Guerras Civiles del Perú*. Biblioteca de Autores Españoles, vol. 166. Madrid: Ediciones Atlas.

Overview of the Inca Frozen Mummies From Mount Lullaillo (Argentina)

- Hernández Príncipe, R. 1986 [1621]. "Idolatría del Pueblo de Ocros, cabeza desta comunidad." In *Cultura Andina y Represión*. Edited by P. Duviols, 442–448. Cuzco: Centro de Estudios Rurales Andinos, Bartolomé de las Casas.
- Molina, C. de. 1959 [1575]. *Ritos y Fábulas de los Incas*. Buenos Aires: Editorial Futuro.
- Murúa, F. M. de. 1946 [1590]. *Historia del Orígen y Genealogía Real de los Reyes Incas del Perú*. Biblioteca Missionalia Hispanica, vol. 2, Madrid.
- Polo de Ondegardo, J. 1916 [1571]. *Informaciones Acerca de la Religión y Gobierno de los Incas*. Colección de libros y documentos referentes a la Historia del Perú, vol 3, 1–203. Lima: Sanmartí y Cía.
- Previgliano, C., C. Ceruti, J. Reinhard, F. A. Araoz and J. G. Díez. 2003a. *Radiologic Evaluation of the Lullaillo Mummies*. *American Journal of Roentgenology* 181: 1473–1479. <http://dx.doi.org/10.2214/ajr.181.6.1811473>
- , C. Ceruti, J. Pastrana and M. Matos Molina. 2003b. "Radiographic Studies in the Inca mummies found on Mount Lullaillo." *Proceedings of the IV World Congress on Mummy Studies*. Nuuk, Greenland: Greenland National Archives and Danish Polar Center in Copenhagen.
- , C. Ceruti, F. A. Araoz, J. G. Díez and J. Reinhard. 2005. "Radiología en estudios arqueológicos de momias incas." *Revista Argentina de Radiología* 69(3): 199–210.
- Ramos Gavilán, A. 1976 [1621]. *Historia de Nuestra Señora de Copacabana*. La Paz: Editorial Universo.
- Reinhard, J. 1997. "Sharp Eyes of Science Probe the Mummies of Peru." *National Geographic Magazine* 191(1): 36–43.
- . 1998. "Research Update: New Inca Mummies." *National Geographic Magazine* 194(1): 128–135.
- . 2006. "Sacred Mountains, Ceremonial Sites and Human Sacrifice Among the Incas." *Archeoastronomy* 19: 1–43.
- . 2010. *Inca Rituals and Sacred Mountains: a study of the world's highest archaeological sites*. Los Angeles: Cotsen Institute of Archaeology, University of California Los Angeles.
- . and C. Ceruti. 2000. *Investigaciones arqueológicas en el volcán Lullaillo. Complejo ceremonial incaico de alta montaña*. Salta: Editorial de la Universidad Católica de Salta.
- Schobinger, J. ed. *La momia del Cerro El Toro: Investigaciones arqueológicas en la Cordillera de la Provincia de San Juan*. Mendoza: Universidad de Cuyo.
- . 2001. *El santuario incaico del cerro Aconcagua*. Mendoza: Universidad de Cuyo.
- Ulloa Mogollón, J. de. 1965 [1586]. "Relación de la Provincia de los Collaguas para la discrepción de las Yndias que su magestad manda hacer." *Relaciones Geográficas de Indias* 1: 326–333.
- Villa, C., C. Previgliano, C. Ceruti, F. A. Araoz, J. G. Díez and N. Lynnerup. 2011. "Anthropological and paleopathological analysis of the three Lullaillo child mummies using 3D visualizations from CT-scans." Poster presentation in the second Bolzano Mummy Congress, Mummies from the Ice. South Tyrol Museum of Archaeology, Bolzano.
- Wilson, A., T. Taylor, M. C. Ceruti, J. A. Chávez, J. Reinhard, V. Grimes, W. Meier-Augenstein, L. Cartmell, B. Stern, M. Richards, M. Worobey, I. Barnes and T. Gilbert. 2007. *Stable isotope and DNA evidence for ritual sequences in Inca child sacrifice*. *Proceedings of the National Academy of Sciences of the USA*. 104(42): 16456–16461. <http://dx.doi.org/10.1073/pnas.0704276104>
- , E. Brown, C. Villa, N. Lynnerup, A. Healey, M. C. Ceruti, J. Reinhard, C. Previgliano, F. A. Araoz, J. G. Díez and T. Taylor. 2013. "Archaeological, radiological and biological evidence offer insight into Inca child Sacrifice." *Proceedings of the National Academy of Sciences of the USA*. 110(33): 13.322–13.327.

