


Follicular structures of cows with cystic ovarian disease present altered expression of cytokines

Antonela F. Stassi¹, Natalia C. Gareis^{1,2}, Belkis E. Marelli^{1,2}, Valentina Matiller^{1,2}, Cristian J.M. Leiva¹, Florencia Rey^{1,2}, Hugo H. Ortega^{1,2}, Natalia R. Salvetti^{1,2} and M. Eugenia Baravalle¹ 

Research Article

Cite this article: Stassi AF *et al.* (2019)

Follicular structures of cows with cystic ovarian disease present altered expression of cytokines. *Zygote*. page 1 of 14.
doi: [10.1017/S0967199419000285](https://doi.org/10.1017/S0967199419000285)

Received: 26 December 2018

Revised: 1 April 2019

Accepted: 25 April 2019

Keywords:

Cow; Cystic follicle; Cytokines; Follicular fluid; Ovary

Address for correspondence:

María Eugenia Baravalle. ICiVet-Litoral, Universidad Nacional del Litoral – CONICET, R.P. Kreder 2805. (3080) Esperanza, Santa Fe, Argentina. Tel: +54 3496 420639. Fax: +54 3496 426304. E-mail: ebaravalle@live.com.ar

¹Laboratorio de Biología Celular y Molecular Aplicada, Instituto de Ciencias Veterinarias del Litoral (ICiVet-Litoral), Consejo Nacional de Investigaciones Científicas y Técnicas, (CONICET) – Universidad Nacional del Litoral, Argentina and ²Facultad de Ciencias Veterinarias, Universidad Nacional del Litoral, Argentina

Summary

Ovulation is considered an inflammatory, cytokine-mediated event. Cytokines, which are recognized as growth factors with immunoregulatory properties, are involved in many cellular processes at the ovarian level. In this sense, cytokines affect fertility and are involved in the development of different ovarian disorders such as bovine cystic ovarian disease (COD). Because it has been previously demonstrated that ovarian cells represent both sources and targets of cytokines, the aim of this study was to examine the expression of several cytokines, including IL-1 β , IL-1RA, IL-1RI, IL-1RII, IL-4 and IL-8, in ovarian follicular structures from cows with spontaneous COD. The protein expression of these cytokines was evaluated by immunohistochemistry. Additionally, IL-1 β , IL-4 and IL-8 concentrations in follicular fluid (FF) and serum were determined by enzyme-linked immunosorbent assay (ELISA). In granulosa and theca cells, IL-1RI, IL-1RII, IL-1RA and IL-4 expression levels were higher in cystic follicles than in the control dominant follicles. The serum and FF concentrations of IL-1 β and IL-4 showed no differences between groups, whereas IL-8 concentration was detected only in FF of cysts from cows with COD. The FF and serum concentrations of IL-1 β and IL-8 showed no significant differences, whereas IL-4 concentration was higher in FF than in serum in both the control and COD groups. These results evidenced an altered expression of cytokines in ovaries of cows with COD that could contribute to the pathogenesis of this disease.

Introduction

Cystic ovarian disease (COD) is among the most relevant causes of subfertility in dairy cattle (Garverick, 1997). This disease generates important economic losses to the dairy industry because it increases the calving-to-conception and inter-calving intervals and because, if the condition persists, the animals should be eliminated from the herd (Peter, 2004; Cattaneo *et al.*, 2014). The incidence of this disease in dairy cattle varies from 5 to 30% (Garverick, 1997; Silvia *et al.*, 2002, 2005; Peter, 2004; Vanholder *et al.*, 2006; Probo *et al.*, 2011; Rizzo *et al.*, 2011; Cattaneo *et al.*, 2014; Ortega *et al.*, 2016). COD is the result of several alterations in ovulatory mechanisms and follicular development (Ortega *et al.*, 2016). Despite the causes, when ovulation does not occur, the dominant follicle becomes an anovulatory cystic structure, interfering with normal ovarian function (Peter, 2004). Ovulation is considered an inflammatory event mediated by cytokines (Bukulmez and Arici, 2000; Richards *et al.*, 2008; Oakley *et al.*, 2010; Richards and Pangas, 2010). Cytokines have immunoregulatory effects and are recognized as growth factors involved in many cellular processes in ovarian cells such as apoptosis, proliferation, differentiation, folliculogenesis, oogenesis, luteogenesis and hormone release (Orsi, 2008; Orsi and Tribe, 2008; Field *et al.*, 2014). Cytokines are also important factors affecting fertility and, in some cases, involved in the development of different ovarian disorders, including COD (Sirotkin, 2011; Smolikova *et al.*, 2012; Baravalle *et al.*, 2015).

Cytokines include interleukins (IL) such as IL-1, IL-4 and IL-8. The IL-1 family acts as one of the most important mediators of inflammation (Mu *et al.*, 2010). The first reported and most studied ligands of the IL-1 family are IL-1 α and IL-1 β (Dinarello, 2013). This family also includes two receptors, IL-1 receptor I (IL-1RI) and IL-1 receptor II (IL-1RII) (Sims *et al.*, 1994), and an IL-1 receptor antagonist (IL-1RA). This last protein acts as a ligand that blocks the action of IL-1 by binding to the receptors and inhibiting the signal by lack of the domain that interacts with IL-1 receptor accessory protein, which regulates IL-1 biological activity (Garlanda *et al.*, 2013; Akdis *et al.*, 2016). Both IL-1 α and IL-1 β bind to IL-1RI with similar effects, and can even bind to IL-1RII. However, IL-1RII does not generate signals because it lacks the intracellular domain, acting as decoy receptor (Dinarello, 2013). IL-1 has been found to be biologically active in the follicular fluid (FF) of swine, horses and humans (Hurwitz *et al.*, 1992; Terranova and Rice, 1997). In addition, IL-1 participates in several ovulation-related processes such as

stimulation of progesterone production (Dang *et al.*, 2017), prostaglandin and nitric oxide production by granulosa cells (reviewed by Field *et al.*, 2014), induction of gelatinases, and synthesis of proteases (Ellman *et al.*, 1993; Hurwitz *et al.*, 1993).

IL-4 is extensively recognized for its anti-inflammatory properties but, depending on the tissue and stimuli, this cytokine may also have pro-inflammatory effects (Woods and Judd, 2008). In the ovary, IL-4 is able to affect ovulation by interrupting the inflammatory process by suppressing IL-1 β and tumour necrosis factor- α (TNF- α) production (Bonder *et al.*, 1998). IL-4 plays its role through the interaction with its receptor (IL-4R α).

IL-8 is involved in a large number of ovarian processes including folliculogenesis, steroidogenesis and atresia, and is able to promote luteinization (Garcia-Velasco and Arici, 1998; Bornstein *et al.*, 2004). This cytokine is crucial in ovarian physiology and in many processes like apoptosis and proliferation of granulosa cells and ovarian angiogenesis (Koch *et al.*, 1992; Ujioka *et al.*, 1998; Belayet *et al.*, 2000; Li *et al.*, 2005; Jiemtaweeboon *et al.*, 2011; Ou *et al.*, 2016).

In a previous study, we found that the expression of IL-1 α , IL-6 and TNF- α in bovine cystic follicles is altered, suggesting that the pathogenesis of COD may be related to an altered immune response (Baravalle *et al.*, 2015). In subsequent studies, using an experimental model, we were able to detect changes in a greater number of components of the immune system (Stassi *et al.*, 2017; 2018). However, the results observed in an experimental model should be corroborated in animals with spontaneously developed disease. This will allow the validation of the model previously used and will provide valuable information. In addition, considering the large number of components of the immune system at reproductive level, we consider it important to expand the range of cytokines evaluated to have an integrated view. Based on all these data, and to verify the hypothesis that cytokines involved in the ovulatory process can contribute to the anovulation observed in COD and the consequent development of this disease, the aims of this study were: (i) to evaluate the protein expression of other components of the IL-1 system, including IL-1 β , IL-1RA, IL-1RI, IL-1RII, as well as IL-4 and IL-8, in ovarian follicular structures from control cows and cows with spontaneous COD; (ii) to analyse the protein expression of the same cytokines through folliculogenesis in control cows and cows with spontaneous COD; and (iii) to determine the concentrations of IL-1 β , IL-4 and IL-8 in FF and serum of control cows and cows with spontaneous COD.

Materials and Methods

Animals

Control Group

The control group consisted of 10 healthy multiparous Holstein cows (66.2 \pm 25.4 months old; 2.8 \pm 1.3 lactations) from local dairy farms. To obtain samples at proestrus, the estrous cycle was synchronized starting with the procedure commonly referred to as G6G (Bello *et al.*, 2006), with modifications (Díaz *et al.*, 2015). The synchronization protocol consisted of two doses of prostaglandin (PG) F2 α (150 μ g D+Cloprostenol; Enzaprost DC, Biogénesis Bagó, Garín, Buenos Aires, Argentina) administered 12 h apart on day 0 to induce luteolysis (Hatler *et al.*, 2008), followed by a dose of a gonadotropin-releasing hormone (GnRH) analogue (20 μ g Buserelin acetate; Gonaxal, Biogénesis Bagó, Argentina), administered 2 days later (i.e. day 2) to stimulate the ovulation of the preovulatory follicles present. Six days after this first GnRH dose (i.e. on day 8), the cows received a second dose of GnRH, and 7 days later (i.e. on day 15), cows

received the last two doses of PGF2 α , 12 h apart, to ensure luteolysis. The expected time of ovulation was about 4 days after the administration of the dose of PGF2 α administered on day 15 of the protocol, i.e. approximately on day 19. For this reason, the samples were taken on day 18 of the proestrus stage. The size, growth and regression of all follicles > 5 mm, corpora lutea and dominant follicles were monitored by rectal palpation and ultrasonographic examinations using a real-time B-mode scanner equipped with a 5 MHz linear-array, transrectal transducer (Honda HS101V, Japan) (Amweg *et al.*, 2013).

Spontaneous COD Group

The COD group consisted of 10 multiparous Holstein cows with COD (64.8 \pm 24.9 months old; 3.3 \pm 1.5 lactations) from local dairy farms. Cysts were detected in the routine reproductive examination of the cows, and subsequently confirmed by rectal palpation and ultrasonography, discarding other diseases and abnormalities in the reproductive system. Spontaneous follicular cysts were defined as follicular structures with \geq 20 mm in diameter, persisting in the ovary in the absence of a corpus luteum, interrupting the estrous cycle and without uterine tone (Bartolomé *et al.*, 2005; Vanholder *et al.*, 2006).

Tissue sampling and processing

Ovaries from the cows of both groups were obtained by bilateral ovariectomy (Amweg *et al.*, 2013; Marelli *et al.*, 2014). To prevent the rupture of dominant follicles from the control group and follicular cysts from the COD group during surgery, the FF was aspirated before ovariectomy, using a digital ultrasound system 8300vet Chison equipped with a micro-convex transducer of 5.0 MHz mounted on a transvaginal probe for follicular aspiration (Watanabe Applied Technology Limited, Brazil). The FF was collected in Falcon tubes, refrigerated on ice, and centrifuged at 2000 g for 10 min to obtain pellet cells in a centrifuge refrigerated at 4°C. Pellet cells were immediately frozen at -80°C. After pellet cell extraction, the FF was stored at -80°C until analysis.

After surgery, the ovaries were dissected and follicular structures were measured. Small samples from ovarian tissues were obtained and immediately frozen at -80°C until use for other evaluations. Ovaries were sectioned for an appropriate histological processing, fixed in 4% buffered formaldehyde at 25°C for 8–10 h, washed in phosphate buffered saline (PBS), dehydrated in an ascending series of ethanol, cleared in xylene, and finally embedded in paraffin. Sections of 4 μ m thickness were mounted on slides previously treated with 3-aminopropyltriethoxysilane (Sigma-Aldrich, St. Louis, MO, USA), and then labelled with haematoxylin and eosin (Sigma-Aldrich) for a preliminary observation of all ovarian structures.

Blood samples from cows of both groups were collected via coccygeal venepuncture at the time of ovariectomy, to determine the concentrations of IL-1 β , IL-4 and IL-8. Blood samples were kept at room temperature (22–25°C) for 30 min, placed at 4–8°C for 1 h and finally centrifuged at 400 g for 10 min. Serum was separated and stored at -80°C until analysis.

Follicular classification

Follicles were classified by the criteria established by Braw-Tal and Yossefi (1997) into the following categories: primary, small preantral, large preantral, antral, and atretic follicles. Additionally, we evaluated the dominant follicle (oestrogen active, composed of a complete healthy granulosa cell layer and an active theca interna) and follicular cysts (composed of a layer of granulosa cells of variable thickness and granulosa and theca cells without signs of

luteinization) (Amweg *et al.*, 2013). Only cystic follicles with a complete granulosa cell layer were used.

Immunohistochemistry(IHC)

Histological sections of ovaries from cows of both groups were used for IHC to locate and quantify the protein expression of IL-1 β , IL-1RA, IL-1RI, IL-1RII, IL-4 and IL-8 in the follicular wall. The streptavidin–biotin immunoperoxidase method used has been previously described in Stassi *et al.* (2017) and the antibodies used previously validated by western blot in bovine ovarian samples (Stassi *et al.*, 2018). Homology between the target peptide of the antibody and the corresponding bovine protein was tested with Basic Local Alignment Search Tool (BLAST software; <http://www.ncbi.nlm.nih.gov/BLAST>) to determine the location of the peptide and to confirm antigen specificity. Homology was higher than 90% for all the antibodies.

Briefly, after deparaffinization and hydration, antigen retrieval was performed as detailed in Table 1. Endogen peroxidase activity was inhibited with 3% (vol/vol) H₂O₂ in methanol, and nonspecific binding was blocked with 10% (vol/vol) normal goat serum for all the antibodies except for IL-1RA and IL-4, which were blocked with normal donkey serum. All sections were incubated with the primary antibodies and detection was performed with the secondary biotin-conjugated antibodies (Table 1), which were incubated at 25°C for 30 min. The conditions of the IHC and the suppliers of the antibodies used are reported in Table 1. Antigens were visualized using the CytoScan™ HRP Detection System (Cell Marque, Rocklin, CA, USA), and 3,3-diaminobenzidine (Liquid DAB-Plus Substrate Kit; Zymed, San Francisco, CA, USA) was used as the chromogen. Finally, the slides were washed in distilled water, counterlabelled with haematoxylin, dehydrated, and mounted. To validate endogenous peroxidase activity blockade, some sections were incubated with DAB alone. Specificity was determined by replacing the primary antibodies with goat, rabbit and mouse non-immune sera. The specificity of the secondary antibodies was tested by incubation with the primary antibodies with negative reaction to bovine antigens: anti-human CD45 (clone: PD7/26; Dako, Carpinteria, CA, USA) and anti-human oestrogen receptor α (polyclonal; Cell Marque, Rocklin, CA, USA).

Image analysis

Microscopic images were digitized with a colour video camera Nikon DS-Fi2 mounted on a conventional light microscope Nikon Eclipse Ci-L Ni (Tokyo, Japan), with an objective magnification of $\times 40$, and analysed with Image Pro-Plus 3.0.1 (Media Cybernetics, Silver Spring, MD, USA). The microscope was prepared for Koehler illumination. This was achieved by recording a reference image of an empty field for the correction of unequal illumination (shading correction) and calibrating the measurement system with a reference slide to determine background threshold values. The reference negative slides contained a series of tissue sections labelled in the absence of a primary antibody. The percentage of immunopositive area was calculated from the percentage of total area evaluated through colour segmentation analysis, which extracts objects by locating all objects of a specific colour (brown label). The positive controls were used as inter-assay controls to maximize the levels of accuracy and robustness of the method (Ranefall *et al.*, 1998; Ortega *et al.*, 2010). The methodological details of image analysis as a valid method to quantify protein expression have been described previously (Salveti *et al.*, 2007; Wang *et al.*, 2009; Ortega *et al.*, 2010).

The percentage of the immunopositive-labelled area was calculated separately in each follicular wall layer (granulosa and theca interna) of the primary (only granulosa), small preantral (only granulosa), large preantral, antral, atretic, dominant and cystic follicles defined previously by the criteria established by Braw-Tal and Yossefi (1997) and Amweg *et al.* (2013).

IL-1 β , IL-4 and IL-8 determination in serum and follicular fluid by ELISA

IL-1 β , IL-4 and IL-8 concentrations in serum and FF in control cows and cows with COD were quantified using commercial ELISA kits (bovine IL-1 β and bovine IL-4 ELISA reagent kits from Thermo Scientific Inc., Rockford, USA, and bovine IL-8 ELISA kit from LifeSpan BioSciences, Inc., Washington, USA), following the manufacturer's instructions. The microplates were sensitized overnight with coating antibody and blocked with a solution of 4% serine bovine albumin, 5% sucrose in D-PBS. All FF and serum samples were used undiluted. FF samples, serum, and standards were placed in duplicate in the wells of the plate and incubated at room temperature for 1 h for IL-1 β or for 1.5 h for IL-4. The IL-8-coated plate was provided by the manufacturer. Standards and samples were incubated at 37°C for 2 h. Samples were washed and detection antibody (biotin-conjugated antibody) was added and incubated for 1 h. After appropriate washings, streptavidin conjugated to horseradish peroxidase was added and incubation was performed for 30 min. The reaction was evidenced by the addition of 3,3',5,5'-tetramethylbenzidine (TMB) as chromogen solution (TMB substrate), which was incubated for 20 min for IL-1 β and IL-4 or for 30 min for IL-8. The reaction was stopped with H₂SO₄ and read at 450 nm in an ELISA reader (Microplate Reader, SPECTROstarNano, BGM/LABTECH, Ortenberg, Germany). The detection limit was 7.8 pg/ml for IL-1 β and IL-8 and 15.6 pg/ml for IL-4.

Statistical analysis

The statistical software package SPSS 15.0 for Windows (SPSS Inc., Chicago, IL, USA) was used in this study. The adequate number of images per follicle and the number of follicles per category were confirmed from a sample size calculation that evaluated the number of samples necessary to produce an estimate of the immunopositive area that would fall within 0.4 units of the real value. The appropriate number of images per follicle, depending on the category, was found to be: 15 representative images for cystic and dominant follicles and 10 representative images for antral follicles and all primary follicles (preantral small and large follicles), whereas the number of follicular structures per category was found to be: 1 cystic/dominant follicle per animal and 5–7 follicles of other categories per animal; in the latter, the average of the total number of follicles per animal was determined. Normal distribution was evaluated using the Kolmogorov–Smirnov test.

The data were evaluated to determine whether there were changes in the expression of the molecules evaluated between groups for each category and whether there were changes within each group throughout follicular development. This led us to perform the following statistical analysis: the percentages of immunopositive area in the control group and the animals with COD were compared in each follicular category separately by Student's *t*-test to determine the differences between groups. The percentage of immunopositive area in different follicular categories along folliculogenesis was compared by analysis of variance (ANOVA) followed by Duncan multiple range tests separately in control and COD animals. In all cases, the data were analysed in each follicular wall layer (granulosa and theca interna).

Table 1. Antigen retrieval and primary antibodies incubation conditions used for immunohistochemistry analysis

Protein	Primary antibody type and supplier	Dilution and Incubation	Secondary antibody	Antigen retrieval
IL-1 β	Monoclonal (clone 1D4, AbD Serotec, UK)	1/25 O.N. at 25°C	Goat-anti-mouse IgG (Santa Cruz Biotechnology, Dallas, Texas, USA)	Intense microwave treatment in a domestic microwave oven at 800 W with 0.01 M citrate buffer (pH 6.0)
IL1-RA	Polyclonal (Q-19: sc-8481, Santa Cruz Biotechnology, Inc., CA, USA)	1/25 O.N. at 4°C	Donkey-anti-goat IgG (Santa Cruz Biotechnology, Dallas, Texas, USA)	Intense microwave treatment in a domestic microwave oven at 800 W with 0.01 M citrate buffer (pH 6.0)
IL1-RI	Monoclonal (NBP1-50304, clone 40101; Novus Biologicals, Littleton, USA)	1/100 O.N. at 25°C	Goat-anti-mouse IgG (Santa Cruz Biotechnology, Dallas, Texas, USA)	Proteinase K pre-treatment
IL1-RII	Polyclonal (H-71: sc-292522, Santa Cruz Biotechnology, Inc., CA, USA)	1/25 O.N. at 4°C	Goat-anti-rabbit IgG (Santa Cruz Biotechnology, Dallas, Texas, USA)	No antigen retrieval
IL-4	Polyclonal (AF2469, R&D Systems, Minneapolis, USA)	1/25 O.N. at 4°C	Donkey-anti-goat IgG (Santa Cruz Biotechnology, Dallas, Texas, USA)	Intense microwave treatment in a domestic microwave oven at 800 W with 0.01 M citrate buffer (pH 6.0)
IL-8	Monoclonal ([8M6] ab34100; Abcam, Cambridge, UK)	1/150 O.N. at 4°C	Goat-anti-mouse IgG (Santa Cruz Biotechnology, Dallas, Texas, USA)	Pressure cooker treatment in 1 mM EDTA buffer (pH 8.0) for 20 min

IL, interleukin; O.N., overnight; R, receptor; RA, receptor antagonist.

The results of the ELISA were analysed to determine differences between groups and between the levels in serum and FF within each group, using Student's *t*-test. Differences were considered as significant when *P*-values were < 0.05. Results are expressed as mean \pm standard deviation (SD).

Results

Follicular characterization

The health status of the dominant follicles, which was determined by assessing the 17 β -estradiol/testosterone ratio in FF (Rodgers and Irving-Rodgers, 2010), was >1 (Diaz *et al.*, 2015). In addition, hormonal concentration of spontaneous follicular cysts in FF was evaluated and has been published previously (Amweg *et al.*, 2013; Baravalle *et al.*, 2015).

Expression and immunolocalization of cytokines

IHC allowed the detection and localization of expression of IL-1 β , IL-1RA, IL-1RI, IL-1RII, IL-4 and IL-8 in different follicular structures (Figs 1, 2, 3, 4, 5 and 6 respectively). All negative controls showed negative reactions.

IL-1 β

IL-1 β expression was localized in the cytoplasm of granulosa and theca interna cells of all follicles analysed (Fig. 1). Along folliculogenesis, IL-1 β expression in granulosa and theca cells was similar in control and COD groups (*P* > 0.05; Fig. 7). When each specific follicular structure was compared between groups, IL-1 β expression in granulosa cells of small preantral follicles from control cows was lower than that in those from COD cows (*P* < 0.05; Fig. 8), and no significant differences were detected for the other follicular categories evaluated (*P* > 0.05; Fig. 8).

IL-1RA

IL-1RA expression was detected in the cytoplasm of granulosa and theca interna cells of all the follicles analysed (Fig. 2). Along folliculogenesis, in granulosa cells of the control group, IL-1RA

expression was higher in large preantral follicles than in those of antral and atretic follicles, as well as higher in small preantral follicles than in atretic follicles (*P* < 0.04; Fig. 7). In theca cells, no differences were found between the different follicular categories evaluated (*P* > 0.05; Fig. 7). In the COD group, no differences were observed in granulosa cells but, in theca cells, IL-1RA expression was higher in cysts than in large preantral and atretic follicles (*P* < 0.01; Fig. 7).

Comparison of each specific follicular structure between groups showed that IL-1RA expression in granulosa cells was higher in cysts than in dominant follicles of the control group, as well as higher in the atretic follicles of the COD group than in those of the control group (*P* < 0.05; Fig. 8). In theca cells, IL-1RA expression was higher in cysts than in dominant follicles of the control group and lower in the antral follicles of the control group than in those of COD cows (*P* < 0.05; Fig. 8).

IL-1RI

IL-1RI expression was detected in the cytoplasm of granulosa and theca interna cells of all follicles analysed (Fig. 3). In the control animals, no differences were observed between the different follicular categories analysed during folliculogenesis in both granulosa and theca cells (*P* > 0.05; Fig. 7). In the COD group, IL-1RI expression in granulosa cells was lower in the primary and large preantral follicles than in cysts (*P* < 0.03; Fig. 7). In theca cells of the COD group, the expression was similar between the different follicular categories (*P* > 0.05; Fig. 7).

Instead, comparison between groups for equivalent follicular structures showed that IL-1RI expression was significantly higher in cysts than in dominant follicles of the control group, both in granulosa and theca interna cells (*P* < 0.05; Fig. 8).

IL-1RII

IL-1RII expression was detected in the cytoplasm of granulosa and theca interna cells of all the follicles analysed (Fig. 4). Along folliculogenesis, in granulosa cells of the control group, IL-1RII expression was higher in atretic follicles than in the rest of the follicular categories analysed and lower in antral follicles than in

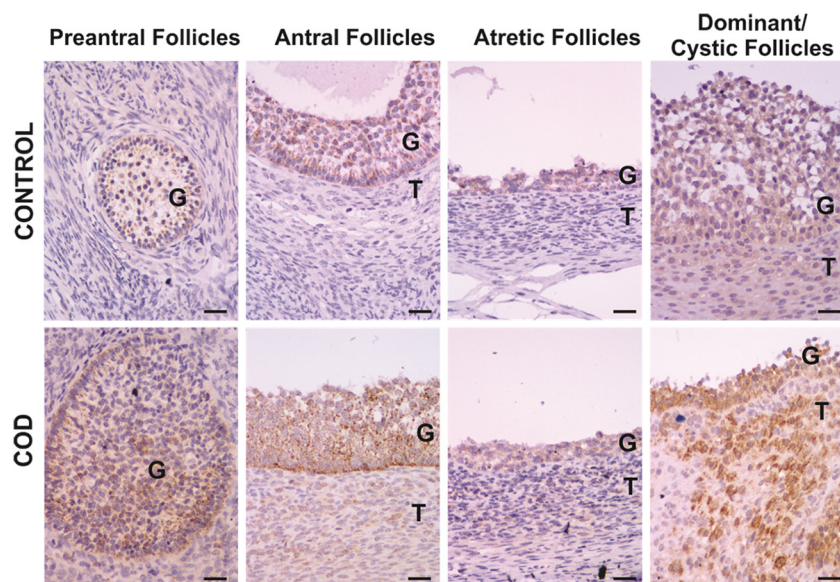


Figure 1. Representative images of IL-1 β immunolabelling in primary, preantral, antral, atretic, dominant and cystic follicles from control ovaries and ovaries from cows with cystic ovarian disease (COD). T: theca cells, G: granulosa cells. Scale bar, 25 μ m.

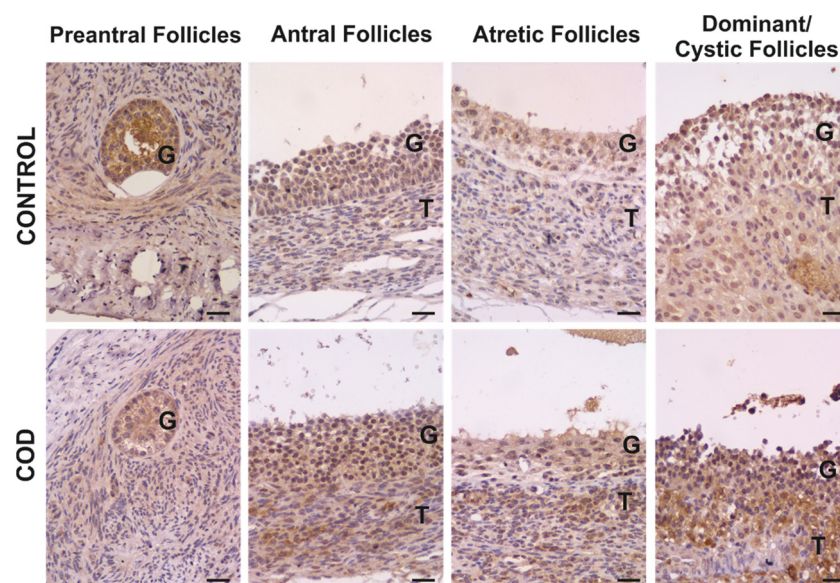


Figure 2. Representative images of IL-1RA immunolabelling in primary, preantral, antral, atretic, dominant and cystic follicles from control ovaries and ovaries from cows with cystic ovarian disease (COD). T: theca cells, G: granulosa cells. Scale bar, 25 μ m.

small preantral follicles ($P < 0.01$; Fig. 7). In the COD group, IL-1RII expression in granulosa cells was higher in cysts and atretic follicles than in preantral and antral follicles ($P < 0.01$; Fig. 7). In theca cells, no differences were found between the different follicular structures analysed in both groups ($P > 0.05$; Fig. 7).

When each specific follicular structure was compared between groups, IL-1RII expression was significantly higher in cysts than in dominant follicles of the control group, both in granulosa and theca interna cells ($P < 0.01$; Fig. 8).

IL-4

IL-4 expression was detected in the cytoplasm of granulosa and theca interna cells of all the follicles analysed (Fig. 5). Along folliculogenesis, in granulosa cells of the control group, IL-4 expression was higher in atretic follicles than in the rest of the follicular categories analysed ($P < 0.03$; Fig. 7). In the COD group, IL-4 expression in granulosa cells was higher in cysts and atretic

follicles than in primary, preantral and antral follicles ($P < 0.01$; Fig. 7). In theca cells, no differences were detected between the different follicular categories evaluated in both groups ($P > 0.05$; Fig. 7).

Conversely, comparison between groups showed that IL-4 expression was significantly higher in cysts than in dominant follicles of the control group, both in granulosa and theca interna cells ($P < 0.05$; Fig. 8).

IL-8

IL-8 expression was detected in the cytoplasm of granulosa and theca interna cells of all the follicles analysed (Fig. 6). In the control group, no differences were observed between the different follicular categories during folliculogenesis, both at the level of granulosa and theca cells ($P > 0.05$; Fig. 7). Instead, in the COD group, IL-8 expression in granulosa cells was higher in antral and atretic follicles than in cysts and lower in primary follicles than in antral

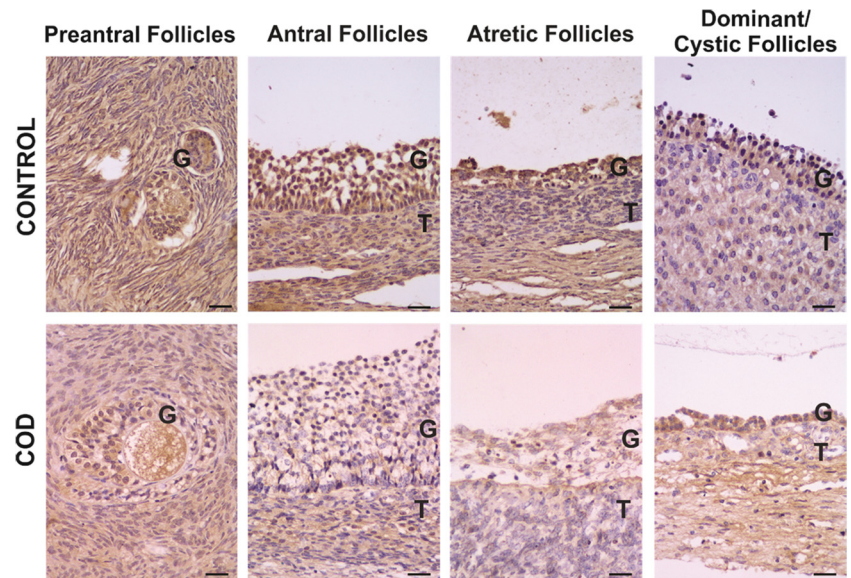


Figure 3. Representative images of IL-1RI immunolabelling in primary, preantral, antral, atretic, dominant and cystic follicles from control ovaries and ovaries from cows with cystic ovarian disease (COD). T: theca cells, G: granulosa cells. Scale bar, 25 μ m.

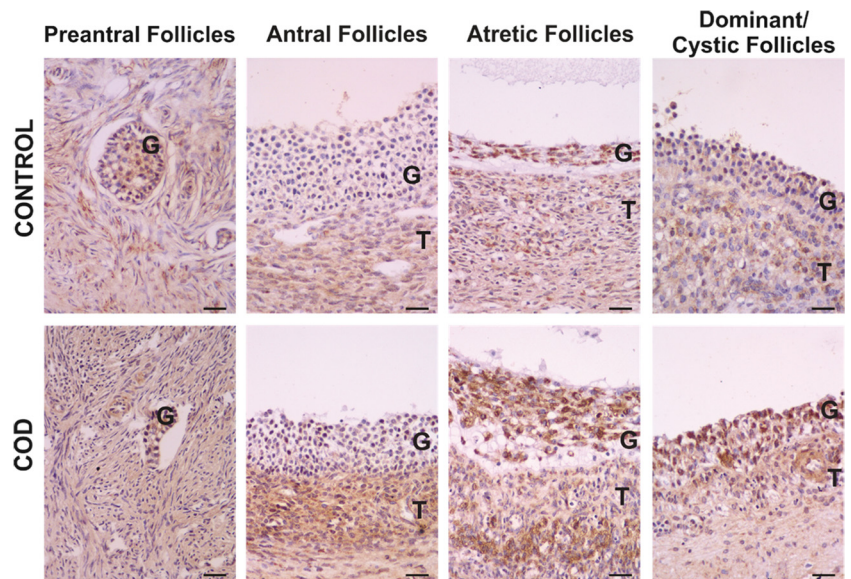


Figure 4. Representative images of IL-1RIII immunolabelling in primary, preantral, antral, atretic, dominant and cystic follicles from control ovaries and ovaries from cows with cystic ovarian disease (COD). T: theca cells, G: granulosa cells. Scale bar, 25 μ m.

follicles ($P < 0.05$; Fig. 7). No significant differences were detected in theca cells between the different follicular categories analysed ($P > 0.05$; Fig. 7).

Comparison of each specific follicular structure between groups showed that IL-8 expression levels of dominant follicles from the control group and cystic follicles were similar ($P > 0.05$; Fig. 8). In theca cells of antral follicles, IL-8 expression was lower in the control group than in COD cows ($P < 0.05$; Fig. 8).

IL-1 β , IL-8 and IL-4 concentrations in serum and follicular fluid

Comparison between groups

Analysis of serum and FF concentrations of IL-1 β and IL-4 showed no significant differences between control and COD cows ($P > 0.05$; Fig. 9). The FF of the control group did not show values higher than the limit of detection of 7.8 pg/ml of IL-8, while the FF of the spontaneous COD group showed mean values of 14.6 pg/ml

(Fig. 9). Therefore, the corresponding statistical analysis could not be performed for IL-8. Analysis of IL-8 serum concentrations showed no significant differences between control and COD cows.

Comparison within the same group

Comparison of IL-1 β between FF and serum concentrations within the same group showed no significant differences between control and COD cows. In contrast, IL-4 levels were higher in FF than in serum in control and COD cows ($P < 0.05$; Fig. 9). The comparison of IL-8 between FF and serum concentrations showed no significant differences in COD cows.

Discussion

The cytokines evaluated in this study have been previously shown to be relevant in ovarian physiology. These cytokines are fundamental to reproductive events such as ovulation and follicular maturation (Brännström *et al.*, 1993; Terranova and Rice, 1997;

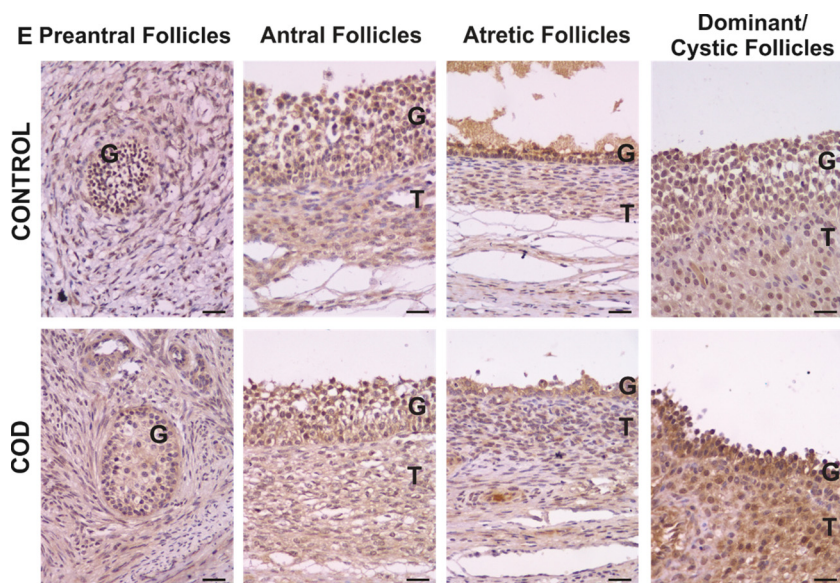


Figure 5. Representative images of IL-4 immunolabelling in primary, preantral, antral, atretic, dominant and cystic follicles from control ovaries and ovaries from cows with cystic ovarian disease (COD). T: theca cells, G: granulosa cells. Scale bar, 25 μ m.

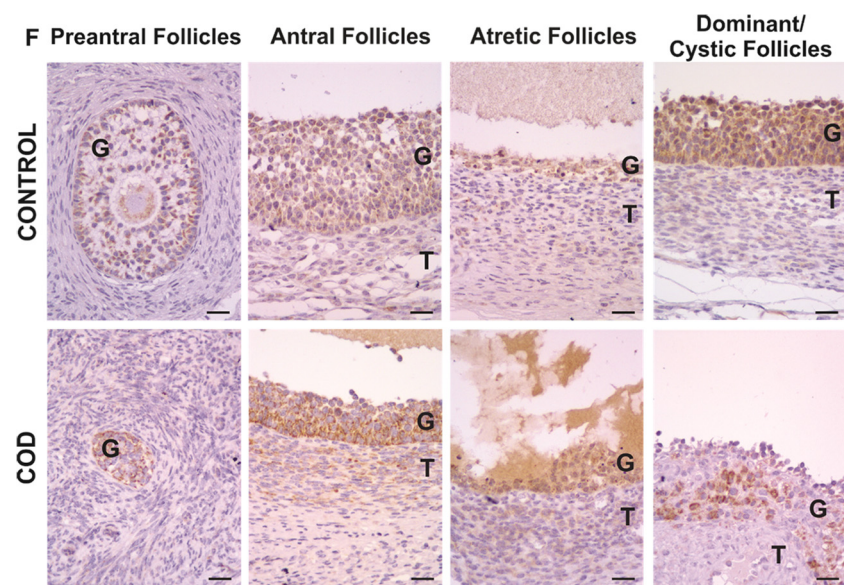


Figure 6. Representative images of IL-8 immunolabelling in primary, preantral, antral, atretic, dominant and cystic follicles from control ovaries and ovaries from cows with cystic ovarian disease (COD). T: theca cells, G: granulosa cells. Scale bar, 25 μ m.

Bukulmez and Arici, 2000). In humans, a vicious cycle between pro- and anti-inflammatory cytokines is thought to play a role in the pathogenesis of polycystic ovary syndrome (PCOS) (Ebejer and Calleja-Agius, 2013; Rashid *et al.*, 2017).

It is well known that IL-1 β plays a role in ovulation. In this study, IL-1 β expression was similar in all follicular categories analysed, except in the small preantral follicles, in which it was lower in the granulosa of the control group than in that of the COD group. In a previous study in which we used an experimental model of induction of persistent follicles in cows, we determined similar differences: in granulosa cells, IL-1 β expression was lower in the small preantral follicles of the control group than in those of groups for 0 and 15 days of follicular persistence (Stassi *et al.*, 2018). These results indicated that both in COD and in the experimental model, IL-1 β expression is slightly modified, and its role in ovulation could be due to the action of other proteins in this system, such as antagonists or receptors. Other studies have shown that, during follicular development, IL-1 regulates the transition of the granulosa

and theca cells from a proliferative to a differentiated stage by favouring proliferation and preventing premature differentiation (Brännström, 2004). An alternative way in which IL-1 acts on follicular development is by facilitating apoptosis, the primordial component of follicular atresia (Chun *et al.*, 1995; Brännström, 2004). This result suggests that IL-1 is involved in the determination of whether follicles progress to ovulation or atresia (Field *et al.*, 2014). These data highlight the relevance of the IL-1 system in the early stages of folliculogenesis. In the present study, the concentrations of IL-1 β were low in both groups. This can be explained by the absence of any apparent disease in the animals included in this study. Also, no differences were found between the follicular cysts and the control group in FF or serum, a result that agrees with those found by the IHC technique and with the results previously shown in the experimental model (Stassi *et al.*, 2018). The results here obtained are in agreement with those of Niu *et al.* (2017), who found similar concentrations of IL-1 β and IL-4 in FF from women with PCOS compared with control patients.

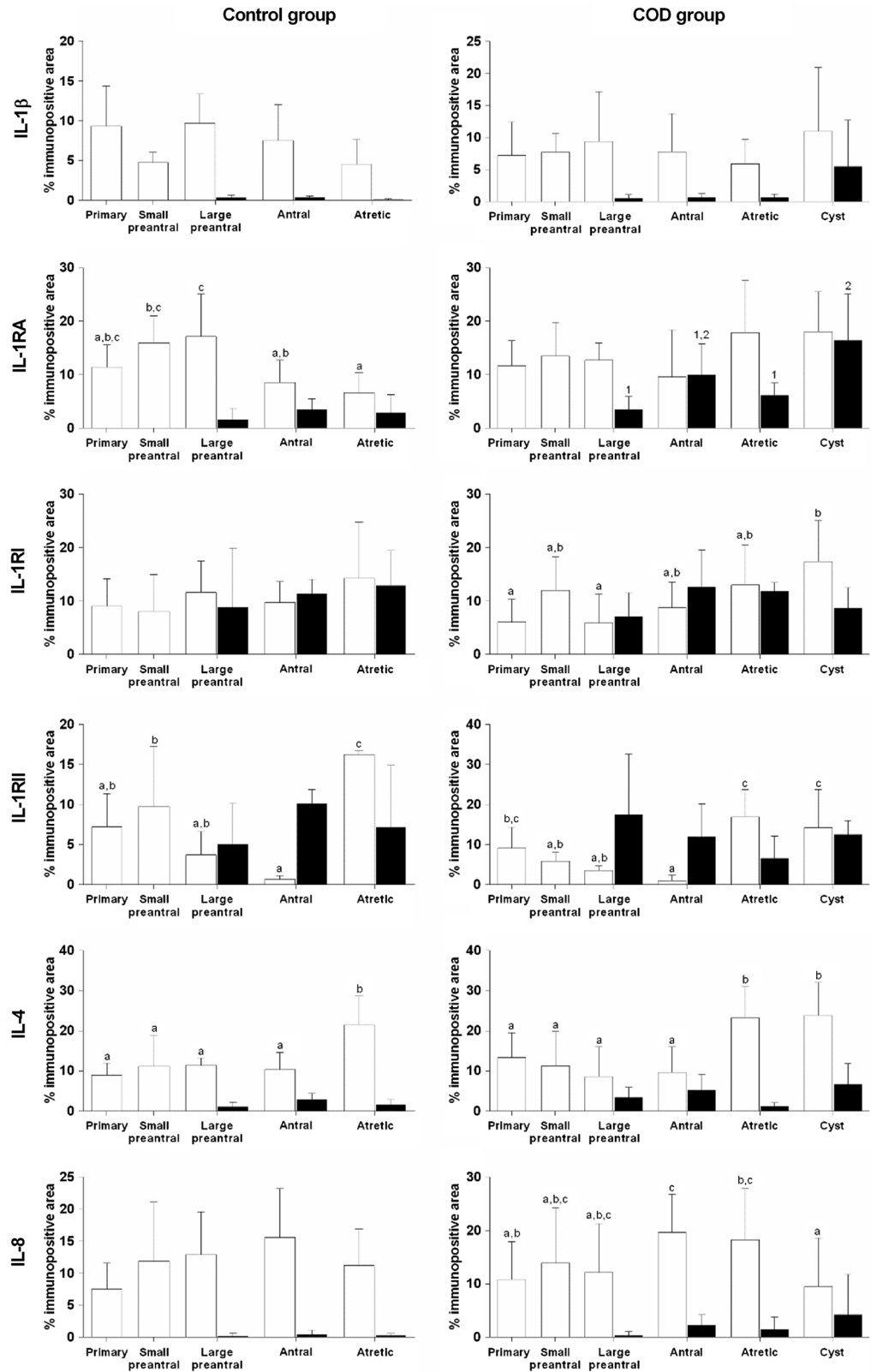


Figure 7. Relative protein expression (measured as percentage of immunopositive area) of IL-1 β , IL-1RA, IL-1RI, IL-1RII, IL-4 and IL-8 in granulosa (open bars) and theca interna (black bars) cells of different follicular categories (control group) and cystic follicles (COD group) within each group. Values represent the mean \pm standard deviation (SD). Bars with different letters (granulosa) or numbers (theca) are different ($P < 0.05$).

An important component of the intraovarian IL-1 system is naturally occurring IL-1RA, which is responsible for attenuating the IL-1 ligand effects. Passos *et al.* (2016) demonstrated the presence of this cytokine in all the structures of the bovine ovary, with low expression in theca cells. These results coincide with IL-1RA

expression here observed throughout folliculogenesis in the control group but not with those observed in the COD group, in which IL-1RA expression throughout folliculogenesis was relatively constant. By intrafollicular injection of this cytokine in mares, Caillaud *et al.* (2005) demonstrated *in vivo* that IL-1RA

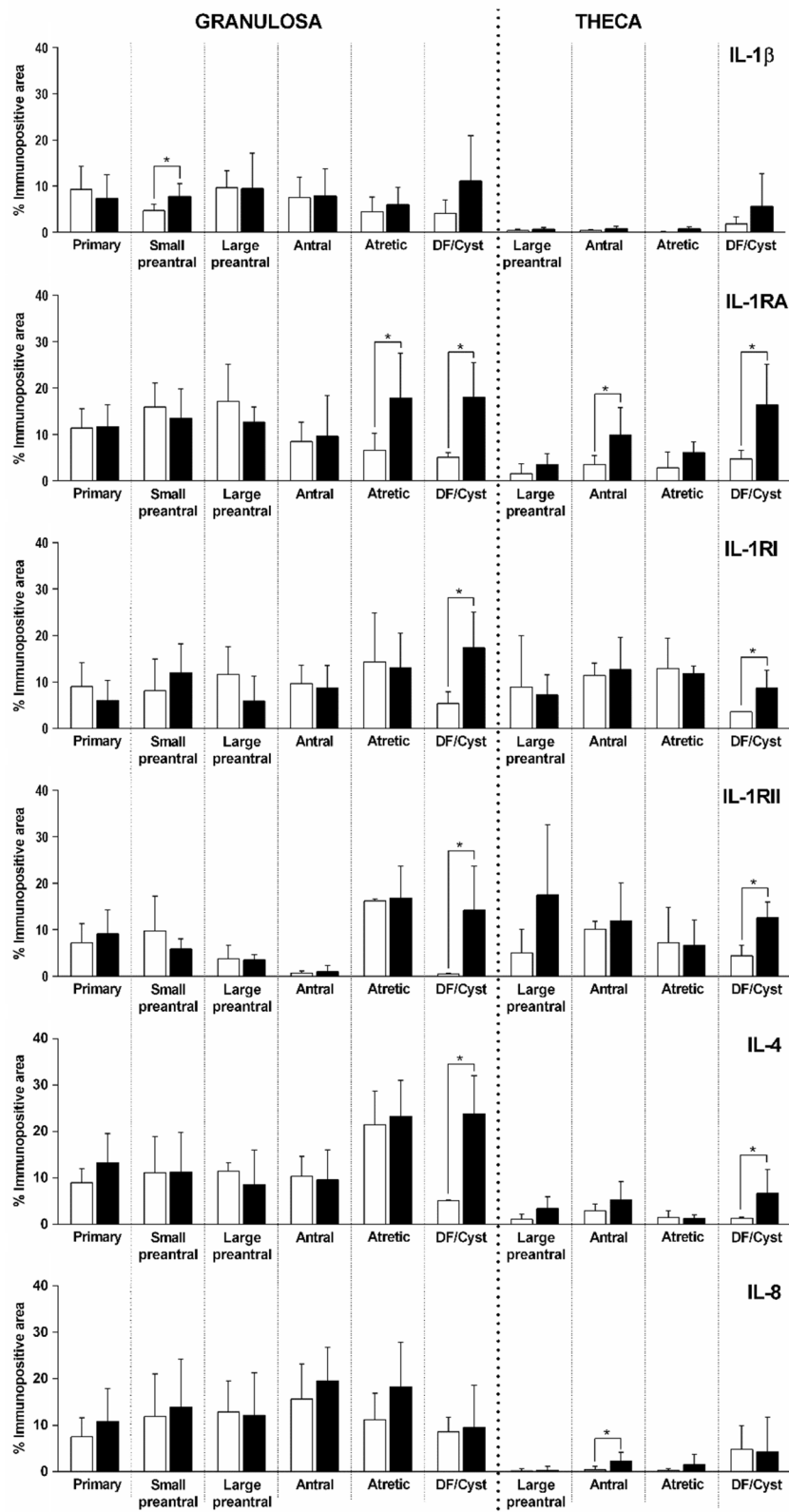


Figure 8. Relative protein expression (measured as percentage of immunopositive area) of IL-1 β , IL-1RA, IL-1RI, IL-1RII, IL-4 and IL-8 in primary, small preantral, large preantral, antral, atretic and dominant follicle (DF) from control ovaries (open bars) and ovaries from cows with COD (black bars), both in granulosa and theca cells. Values represent the mean \pm standard deviation (SD). *Values were significantly different at $P < 0.05$ as compared with the corresponding follicular category.

exerts actions in ovulation, inducing a time-dependent inhibition of hCG-induced ovulation. Therefore, taking into account that the ovulatory process is a cascade of inflammatory reactions and that the organism tries to prevent an exacerbated reaction, it may be

suggested that IL-1RA acts in an autocrine/paracrine manner in the immediate vicinity of cells to minimize the inflammatory response generated by IL-1 β (Rashid *et al.*, 2017). In addition, it has been shown that IL-1RA concentrations in peri-ovulatory

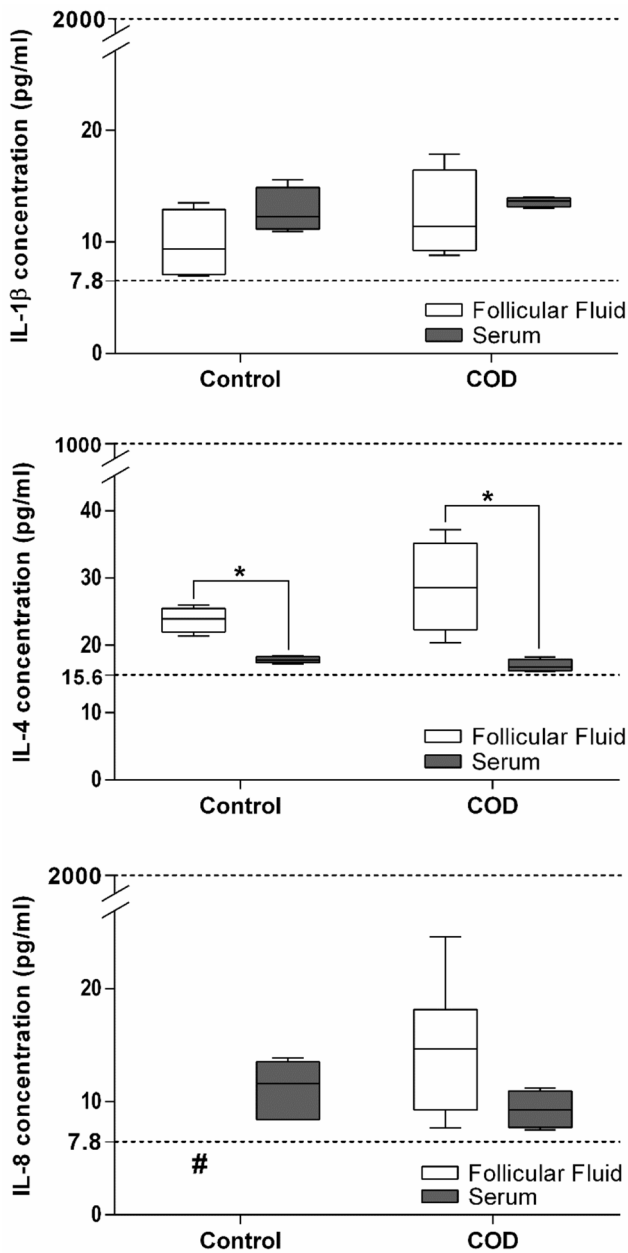


Figure 9. IL-1 β , IL-4 and IL-8 concentrations in serum and FF of dominant follicles from the estrous-synchronized control group and in cystic follicles from cows with COD. Values represent the mean \pm standard deviation (SD). #IL-8 in FF of control animals was not detected (< to 7.8 pg/ml). *Values were significantly different at $P < 0.05$ for comparison of FF and serum within the same group.

human FF are relatively high (Büscher *et al.*, 1999), and that the balance between the levels of IL-1RA and IL-1 in local tissues influences the relative physiological or pathophysiological effects of IL-1 (Arend, 2002). Therefore, it is very likely that circulating IL-1RA diffuses into tissues and influences the local relationship between IL-1RA and IL-1. Our group has previously demonstrated an overexpression of IL-1 α , the other agonist of the IL-1 system, in the granulosa of cysts and persistent follicles (Baravalle *et al.*, 2015; Stassi *et al.*, 2017). This finding could explain the high expression of IL-1RA, to counteract IL-1, observed in follicular cysts both in the present work and in follicles of 15 days of persistence. This was studied in our previous work in relation to dominant follicles in the

control group (Stassi *et al.*, 2018), a situation that could interfere with the ovulatory process.

IL-1RI is the main effector of IL-1 and leads to unleashing of actions of this interleukin. In the present study, we found that IL-1RI immunoexpression was significantly higher in follicular cysts than in the dominant follicles of the control group, in both granulosa and theca interna cells. These results do not reflect those obtained in the experimental model of follicular persistence, in which expression of this receptor showed no differences (Stassi *et al.*, 2018). Conversely, expression of IL-1RI was significantly lower in granulosa of follicles at the first stages of development than in cysts from the COD group, and was constant along folliculogenesis in the control group. Previous studies in rats have described IL-1RI as the main receptor, with high and constant expression during folliculogenesis, and low expression of IL-1RII (Scherzer *et al.*, 1996; Brännström, 2004).

In the present study, IL-1RII expression was significantly higher in cysts than in dominant follicles from the control group, in both granulosa and theca interna cells. IL-1RII, which as mentioned above acts as a decoy receptor, is secreted in a soluble form (Kuhn *et al.*, 2007; Lorenzen *et al.*, 2012; Akdis *et al.*, 2016). IL-1RII modulates the biological activity of IL-1 by several mechanisms by binding 100 times less efficiently to IL-1RA than agonists in the system. Conversely, IL-1RI acts to select ligands, therefore becoming a molecular trap for IL-1 α and IL-1 β (Colotta *et al.*, 1993; Re *et al.*, 1996; Smith *et al.*, 2003; Garlanda *et al.*, 2013). The expression of IL-1RII is promoted by anti-inflammatory signals, including cytokines (IL-4, IL-13, IL-10 and IL-27), prostaglandins, glucocorticoid hormones and aspirin (Spriggs *et al.*, 1992; Colotta *et al.*, 1993, 1994, 1996; Re *et al.*, 1994; Dickensheets and Donnelly, 1997; Kallioliias *et al.*, 2010; Daun *et al.*, 1999), indicating that IL-1RII expression is involved in the anti-inflammatory action of these regulators (Garlanda *et al.*, 2013; Bonecchi *et al.*, 2016). In this study, IL-1RII expression in cystic follicles was increased, and could reflect the activation of endogenous negative regulation pathways of inflammation. In addition, the higher expression of IL-1RII detected in cysts is consistent with that observed in persistent follicles (Stassi *et al.*, 2018). These results support even more the utility of this model induced by prolonged treatment with progesterone in the study of cystogenesis. Through folliculogenesis, expression of IL-1RII in the granulosa cells of the control group was higher in atretic follicles than in other categories, and behaved in the same way in the COD group, showing that expression in cysts is similar to that in atretic follicles. These results could indicate that IL-1RII is responsible for blocking the action of IL-1 in the proliferation of granulosa cells.

These results showed that the complex regulation of the IL-1 system could be unbalanced by an alteration in any of its components. Overexpression of IL-1RI, IL-1RII and IL-1RA in spontaneous follicular cysts is clear evidence that the IL-1 system is unbalanced. The ligand IL-1 β showed no differences, but the receptor responsible for its action could be responsible for an exacerbated action of this cytokine, which as known is involved in proliferation, differentiation and apoptosis (Chun *et al.*, 1995; Brännström, 2004). It has been previously confirmed that cystic follicles of animals with spontaneous COD present an altered proliferation/apoptosis balance (Salveti *et al.*, 2010). Such unusual circumstances favour the persistence of these structures, which continue to secrete altered levels of cytokines, growth factors and hormones, and therefore contribute to COD pathogenesis.

Regarding IL-4, its expression in granulosa and theca interna cells of the dominant follicles from the control group was lower than in cystic follicles. These results coincide with those observed

from the follicles of a progesterone-induced persistence model (Stassi *et al.*, 2018). Through studies in rats, Leo *et al.* (2001) showed that expression of IL-4 and its receptor in preovulatory follicles is increased. In the present study, throughout folliculogenesis, IL-4 expression in the granulosa cells of the control group was higher in atretic follicles than in the other follicular categories. This result could indicate a clear participation of IL-4 in regulation of proliferation of granulosa cells. In the COD group, IL-4 behaved in the same way, as its expression in cysts was similar to that in atretic follicles. In addition, it has been demonstrated that IL-4 stimulates the expression and secretion of IL-1RII, which, as already mentioned, is a decoy receptor that captures IL-1 (Colotta *et al.*, 1993). Because the expression of both IL-1RII and IL-4 was higher in atretic follicles and cysts, we could suggest a co-stimulation in the secretion of these cytokines. These results confirm those of Dembic (2015), who demonstrated that IL-4 has a direct anti-inflammatory effect *in vitro* by suppressing the secretion of IL-1 β , IL-12, IL-10 and TNF- α by monocytes as well as that of IL-1 β and IL-12 by macrophages. In studies performed *in vivo*, it has been shown that, when IL-4 is administered locally or systemically, this cytokine has a strong anti-angiogenic activity (Volpert *et al.*, 1998), a process found altered in cystic follicles (Isobe *et al.*, 2005, 2008).

IL-4 concentrations in FF and serum showed no differences between the COD and control groups, but were higher in FF than in serum in both groups. IL-4 concentration was also higher in FF of persistent follicles, similar to that observed in spontaneous COD (Stassi *et al.*, 2018). These results highlight the fact that this cytokine is regulated locally at the follicular level. Because cytokines carry out the autocrine and paracrine regulation in cells, it is evident that the higher concentrations of these molecules in FF than in serum demonstrate their relationship with ovarian physiology. Therefore, determining the intrafollicular concentrations of cytokines is of special interest in the study of their role in ovarian functions. Our results coincide with those of Gaafar *et al.* (2014), who evaluated cytokine concentrations in FF from women with PCOS and concluded that these concentrations showed no association with PCOS.

Finally, IL-8 expression showed few alterations. IL-8 expression was higher in the theca interna of antral follicles of the COD group than in those of the control group. Considering our previous results in a progesterone-induced experimental model (Stassi *et al.*, 2017), we may suppose that IL-8 participates in the pathogenesis of follicular persistence by contributing to the arrest of follicular development, interfering with folliculogenesis. However, in this study, we did not observe that difference in spontaneous COD. Beyond this, IL-8 is thought to be a potent mediator of the ovulatory process through the stimulation of neutrophil chemotaxis and is associated with luteinization of granulosa and theca cells before ovulation in cattle (Shimizu *et al.* 2012, 2013). In the present study, the expression of this cytokine in the control group was constant throughout folliculogenesis, whereas that in the COD group was higher in the granulosa cells of antral follicles than in primary and cystic follicles. These results suggested that IL-8 could play a role in the regulation of angiogenesis and cell proliferation, as previously reported by other authors (Koch *et al.*, 1992; Schadendorf *et al.*, 1993). An excess of IL-8 may lead to a persistent invasion of neutrophils, and this may in turn impair folliculogenesis and the ovarian reserve (Kitaya and Yamada, 2011). In the present study, in FF from the control group, IL-8 concentration was too low to be measured, whereas, in FF from spontaneous cysts, IL-8 concentration was measurable in all samples. The

increased expression of IL-8 in antral follicles of COD cows and the concentration found in FF of cysts could be responsible for pronounced vasculature development, previously described in follicular cysts (Isobe *et al.*, 2005, 2008).

In summary, cytokines are differentially expressed during folliculogenesis, suggesting the possible influence of cytokines on follicular maturation (De *et al.*, 1992, Deshpande *et al.*, 2000). All cytokines studied were found to be expressed in granulosa and theca cells of follicles at all the stages of development evaluated, in both groups. These findings suggest that variations observed occur from the first stages of follicular development, and could be involved in the difficulty of resuming normal cycles that could be related to the recurrence of COD (Silvia *et al.*, 2002; Vanholder *et al.*, 2006). Our results also showed an altered expression of IL-1RI, IL-1RII, IL-1RA and IL-4, particularly high in follicular cysts of cows with spontaneous COD, demonstrating that the regulation of this intercellular communication is altered. In this sense, the increased expression of IL-1RA and IL-1RII could interfere in the participation of IL-1 in ovulation. Conversely, IL-1RI overexpression might favour the action of this cytokine. Previous results also showed that IL-1 α expression is significantly higher in the granulosa of cysts than in the granulosa of antral follicles of control cows (Baravalle *et al.*, 2015). Taking into account that both ligands bind to the same receptors, we can hypothesise that, in ovaries from animals with spontaneous COD, the IL-1 system is exacerbated. Conversely, the activity of IL-4 added to other anti-inflammatory cytokines, such as TGF- β 1 and IL-6 whose levels were increased in cows with COD, could contribute to blocking ovulation (Matiller *et al.*, 2014; Baravalle *et al.*, 2015). In addition, this study supports our previous results (Stassi *et al.*, 2017; 2018) and provides evidence that cytokine expression in spontaneous COD and follicular persistence induced by prolonged treatment with progesterone in dairy cows is concurrent. These results suggested that this model represents a scenario compatible with spontaneous disease, with the advantage that early stages of disease development can be evaluated. The results allowed us to assume that the cytokines here studied are involved in anovulation and follicular persistence processes associated with COD pathogenesis. However, further studies should be performed to expose the complexities of COD in cattle and clarify the action of cytokines in this disease, and therefore help to develop new preventive or therapeutic strategies.

Acknowledgements. We are grateful to the staff of the Large Animal Health Hospital of the Facultad de Ciencias Veterinarias de la Universidad Nacional del Litoral (Santa Fe, Argentina) for animal care and help with the generation of experimental animals and collection of samples. We also thank DVM Jose Bertoli and DVM Fabian Barberis for assistance with animal care, the staff members of the Laboratorio de Biología Celular y Molecular Aplicada (ICIVET-Litoral UNL CONICET) for their technical support during processing of slides and Biogénesis Bagó for provision of drugs. VM, FR, HHO, NRS and MEB are Research Career Members and AFS, NCG, BEM, CJML are fellows of the National Scientific Research Council (CONICET, Argentina).

Financial support. This study was supported by a grant from the Argentine National Agency for the Promotion of Science and Technology (ANPCyT) (PICT 2011–1274).

Conflict of interest. The authors declare that there is no conflict of interest that could be perceived as prejudicing the impartiality of the research reported.

Ethical standards. All procedures were evaluated and approved by the Institutional Ethics and Security Committee of the Facultad de Ciencias Veterinarias – Universidad Nacional del Litoral, Santa Fe, Argentina (protocol

number: 84/11) and are consistent with the *Guide for the Care and Use of Agricultural Animals in Research and Teaching*, 3rd edition (Federation of Animal Science Societies, 2010).

References

- Akdis M, Aab A, Altunbulakli C, Azkur K, Costa RA, Cramer R, *et al.* (2016) Interleukins (from IL-1 to IL-38), interferons, transforming growth factor β , and TNF- α : receptors, functions, and roles in diseases. *J Allergy Clin Immunol* **138**, 984–1010.
- Amweg AN, Salvetti NR, Stangaferro ML, Paredes AH, Lara HH, Rodríguez FM and Ortega HH (2013) Ovarian localization of 11 β -hydroxysteroid dehydrogenase (11 β HSD): Effects of ACTH stimulation and its relationship with bovine cystic ovarian disease. *Domest Anim Endocrinol* **45**, 126–40.
- Arend WP (2002) The balance between IL-1 and IL-1Ra in disease. *Cytokine Growth Factor Rev* **13**, 323–40.
- Baravalle ME, Stassi AF, Velázquez MML, Belotti EM, Rodríguez FM, Ortega HH and Salvetti NR (2015) Altered expression of pro-inflammatory cytokines in ovarian follicles of cows with cystic ovarian disease. *J Comp Pathol* **153**, 116–30.
- Bartolomé JA, Thatcher WW, Melendez P, Risco CA and Archbald LF (2005) Strategies for the diagnosis and treatment of ovarian cysts in dairy cattle. *J Am Vet Med Assoc* **227**, 1409–14.
- Belayet HM, Kanayama N, Khatun S, Asahina T, Okada Y, Kitamura K, Kobayashi T and Terao T (2000) Pharmacologic doses of interleukin 8 suppositories induce follicular maturation in rabbits. *Cytokine* **12**, 361–7.
- Bello NM, Steibel JP and Pursley JR (2006) Optimizing ovulation to first GnRH improved outcomes to each hormonal injection of ovsynch in lactating dairy cows. *J Dairy Sci* **89**, 3413–24.
- Bonder CS, Dickensheets HL, Finlay-Jones JJ, Donnelly RP and Hart PH (1998) Involvement of the IL-2 receptor gamma-chain (gammapc) in the control by IL-4 of human monocyte and macrophage proinflammatory mediator production. *J Immunol* **160**, 4048–56.
- Bonecchi R, Garlanda C, Mantovani A and Riva F (2016) Cytokine decoy and scavenger receptors as key regulators of immunity and inflammation. *Cytokine* **87**, 37–45.
- Bornstein SR, Rutkowski H and Vrezas I (2004) Cytokines and steroidogenesis. *Mol Cell Endocrinol* **215**, 135–41.
- Brännström M (2004) Potential role of cytokines in ovarian physiology: the case for interleukin-1. In: *The Ovary*, 2nd edn, PCK Leung, EY Adashi, eds, Elsevier Academic Press, Vancouver, pp. 261–71.
- Brännström M, Wang L and Norman RJ (1993) Ovulatory effect of interleukin-1 beta on the perfused rat ovary. *Endocrinology* **132**, 399–404.
- Braw-Tal R and Yossefi S (1997) Studies in-vivo and in-vitro on the initiation of follicle growth in the bovine ovary. *J Reprod Fertil* **109**, 165–71.
- Bukulmez O and Arici A (2000) Leukocytes in ovarian function. *Hum Reprod* **6**, 1–15.
- Büscher U, Chen FC, Kentenich H and Schmiady H (1999) Cytokines in the follicular fluid of stimulated and non-stimulated human ovaries; is ovulation a suppressed inflammatory reaction? *Hum Reprod* **14**, 162–6.
- Caillaud M, Duchamp G and Gérard N (2005) *In vivo* effect of interleukin-1beta and interleukin-1RA on oocyte cytoplasmic maturation, ovulation, and early embryonic development in the mare. *Reprod Biol Endocrinol* **3**, 1–9.
- Cattaneo L, Signorini ML, Bertoli J, Bartolomé JA, Gareis NC, Díaz PU, Bo GA and Ortega HH (2014) Epidemiological description of cystic ovarian disease in Argentine dairy herds: risk factors and effects on the reproductive performance of lactating cows. *Reprod Domest Anim* **49**, 1028–33.
- Chun SY, Eisenhauer KM, Kubo M and Hsueh AJ (1995) Interleukin-1 beta suppresses apoptosis in rat ovarian follicles by increasing nitric oxide production. *Endocrinology* **136**, 3120–7.
- Colotta F, Re F, Muzio M, Polentarutti N, Minty A, Caput D, Ferrara P and Mantovani A (1994) Interleukin-13 induces expression and release of interleukin-1 decoy receptor in human polymorphonuclear cells. *J Biol Chem* **269**, 12403–6.
- Colotta F, Re F, Muzio M, Bertini R, Polentarutti N, Sironi M, Giri JG, Dower SK, Sims JE and Mantovani A (1993) Interleukin-1 type II receptor: a decoy target for IL-1 that is regulated by IL-4. *Science* **61**, 472–5.
- Colotta F, Saccani S, Giri JG, Dower SK, Sims JE, Introna M and Mantovani A (1996) Regulated expression and release of the IL-1 decoy receptor in human mononuclear phagocytes. *J Immunol* **156**, 2534–41.
- Dang X, Zhu Q, He Y, Wang Y, Lu Y, Li X, Qi J, Wu H and Sun Y (2017) IL-1 β up-regulates StAR and progesterone production through the ERK1/2- and p38-mediated CREB signaling pathways in human granulosa-lutein cells. *Endocrinology* **158**, 3281–91.
- Daun JM, Ball RW, Burger HR and Cannon JG (1999) Aspirin-induced increases in soluble IL-1 receptor type II concentrations *in vitro* and *in vivo*. *J Leukoc Biol* **65**, 863–6.
- De M, Sanford T and Wood G (1992) Interleukin-1, Interleukin-6, and tumor necrosis factor- α are produced in the mouse uterus during the estrous cycle and are induced by estrogen and progesterone. *Dev Biol* **151**, 297–305.
- Dembic Z (2015) Cytokines of the Immune System: Interleukins. In: *The Cytokines of the Immune System* **6**, 143–239.
- Deshpande R, Chang M, Chapman J and Michael S (2000) Alteration of cytokine production in follicular cystic ovaries induced in mice by neonatal estradiol injection. *Am J Reprod Immunol* **44**, 80–8.
- Díaz PU, Stangaferro ML, Gareis NC, Silvia W, Matiller V, Salvetti NR, Rey F, Barberis F, Cattaneo L and Ortega HH (2015) Characterization of persistent follicles induced by prolonged treatment with progesterone in dairy cows: an experimental model for the study of ovarian follicular cysts. *Theriogenology* **84**, 1149–60.
- Dickensheets HL and Donnelly RP (1997) IFN-gamma and IL-10 inhibit induction of IL-1 receptor type I and type II gene expression by IL-4 and IL-13 in human monocytes. *J Immunol* **159**, 6226–33.
- Dinarello CA (2013) Overview of the interleukin-1 family of ligands and receptors. *Semin Immunol* **25**, 389–93.
- Ebejer K and Calleja-Agius J (2013) The role of cytokines in polycystic ovarian syndrome. *Gynecol Endocrinol* **29**, 536–40.
- Ellman C, Corbett JA, Misko TP, McDaniel M and Beckerman KP (1993) Nitric oxide mediates interleukin-1-induced cellular cytotoxicity in the rat ovary. A potential role for nitric oxide in the ovulatory process. *J Clin Invest* **92**, 3053–6.
- Field SL, Dasgupta T, Cummings M and Orsi NM (2014) Cytokines in ovarian folliculogenesis, oocyte maturation and luteinisation. *Mol Reprod Dev* **81**, 284–314.
- Gaafar TM, Hanna MOF, Hammady MR, Amr HM, Osman OM, Nasef A and Osman AM (2014) Evaluation of cytokines in follicular fluid and their effect on fertilization and pregnancy outcome. *Immunol Invest* **43**, 572–84.
- García-Velasco JA and Arici A (1998) Chemokines and human reproduction. *Fertil Steril* **71**, 983–93.
- Garlanda C, Dinarello CA and Mantovani A (2013) The interleukin-1 family: back to the future. *Immunity* **39**, 1003–18.
- Garverick HA (1997) Ovarian follicular cysts in dairy cows. *J Dairy Sci* **80**, 995–1004.
- Hatler TB, Hayes SH, Ray DL, Reames PS and Silvia WJ (2008) Effect of sub-luteal concentrations of progesterone on luteinizing hormone and ovulation in lactating dairy cows. *Vet J* **177**, 360–8.
- Hurwitz A, Loukides J, Ricciarelli E, Botero L, Katz E, McAllister JM, Garcia JE, Rohan R, Adashi EY and Hernandez ER (1992) Human intraovarian interleukin-1 (IL1) system: highly compartmentalized and hormonally dependent regulation of the genes encoding IL1, its receptor, and its receptor antagonist. *J Clin Invest* **89**, 1746–1754.
- Hurwitz A, Dushnik M, Solomon H, Ben-Chetrit A, Finci-Yeheskel Z, Milwidsky A, Mayer M, Adashi EY and Yagel S (1993) Cytokine-mediated regulation of rat ovarian function: interleukin-1 stimulates the accumulation of a 92-kilodalton gelatinase. *Endocrinology* **132**, 2709–14.
- Isobe N, Kitabayashi M and Yoshimura Y (2005) Microvascular distribution and vascular endothelial growth factor expression in bovine cystic follicles. *Domest Anim Endocrinol* **29**, 634–45.
- Isobe N, Kitabayashi M and Yoshimura Y (2008) Expression of vascular endothelial growth factor receptors in bovine cystic follicles. *Reprod Domest Anim* **43**, 267–71.
- Jiemtaweaboon S, Shirasuna K, Nitta A, Kobayashi A, Schuberth H, Shimizu T and Miyamoto A (2011) Evidence that polymorphonuclear neutrophils infiltrate into the developing corpus luteum and promote angiogenesis with interleukin-8 in the cow. *Reprod Biol Endocrinol* **8**, 9–79.

- Kallioliadis GD, Gordon RA and Ivashkiv LB** (2010) Suppression of TNF- α and IL-1 signaling identifies a mechanism of homeostatic regulation of macrophages by IL-27. *J Immunol* **185**, 7047–56.
- Kitaya K and Yamada H** (2011) Pathophysiological roles of chemokines in human reproduction: an overview. *Am J Reprod Immunol* **65**, 449–59.
- Koch AE, Polverini PJ, Kunkel SL, Harlow LA, DiPietro LA, Elnor VM, Elnor SG and Strieter RM** (1992) Interleukin 8 as a macrophage derived mediator of angiogenesis. *Science* **258**, 1798–801.
- Kuhn PH, Marjaux E, Imhof A, De Strooper B, Haass C and Lichtenthaler SF** (2007) Regulated intramembrane proteolysis of the interleukin-1 receptor II by α -, β -, and γ -secretase. *J Biol Chem* **282**, 11982–95.
- Leo CP, Pisarska MD and Hsueh AJ** (2001) DNA array analysis of changes in preovulatory gene expression in the rat ovary. *Biol Reprod* **65**, 269–76.
- Li A, Varney ML, Valasek J, Godfrey M, Dave BJ and Singh RK** (2005) Autocrine role of interleukin-8 in induction of endothelial cell proliferation, survival, migration and MMP-2 production and angiogenesis. *Angiogenesis* **8**, 63–71.
- Lorenzen I, Lokau J, Düsterhöft S, Trad A, Garbers C, Scheller J, Rose-John S and Grötzinger J** (2012) The membrane-proximal domain of A disintegrin and metalloprotease 17 (ADAM17) is responsible for recognition of the interleukin-6 receptor and interleukin-1 receptor II. *FEBS Lett* **586**, 1093–100.
- Marelli BE, Díaz PU, Salvetti NR, Rey F and Ortega HH** (2014) mRNA expression pattern of gonadotropin receptors in bovine follicular cysts. *Biol Reprod* **4**, 276–81.
- Matiller V, Stangaferro ML, Díaz PU, Ortega HH, Rey F, Huber E and Salvetti NR** (2014) Altered expression of transforming growth factor β isoforms in bovine cystic ovarian disease. *Reprod Domest Anim* **49**, 813–23.
- Mu Y, Liu J, Wang B, Wen Q, Wang J, Yan J, Zhou S, Ma X and Cao Y** (2010) Interleukin 1 β (IL-1 β) promoter C [-511] T polymorphism but not C [+3953] T polymorphism is associated with polycystic ovary syndrome. *Endocrine* **37**, 71–5.
- Niu Z, Ye Y, Xia L, Fengm Y and Zhang A** (2017) Follicular fluid cytokine composition and oocyte quality of polycystic ovary syndrome patients with metabolic syndrome undergoing *in vitro* fertilization. *Cytokine* **91**, 180–6.
- Oakley OR, Kim H, El-Amouri I, Lin PC, Cho J, Bani-Ahmad M and Ko C** (2010) Periovarian leukocyte infiltration in the rat ovary. *Endocrinology* **151**, 4551–9.
- Orsi NM** (2008) Cytokine networks in the establishment and maintenance of pregnancy. *Hum Fertil* **11**, 222–30.
- Orsi NM and Tribe RM** (2008) Cytokine networks and the regulation of uterine function in pregnancy and parturition. *Neuroendocrinology* **20**, 462–9.
- Ortega HH, Díaz PU, Salvetti NR, Hein GJ, Marelli BE, Rodríguez FM, Stassi AF and Rey F** (2016) Follicular cysts: a single sign and different diseases. a view from comparative medicine. *Curr Pharm Des* **22**, 5634–45.
- Ortega HH, Rey F, Velázquez MML and Padmanabhan V** (2010) Developmental programming: effect of prenatal steroid excess on intraovarian components of insulin signaling pathway and related proteins in sheep. *Biol Reprod* **82**, 1065–75.
- Ou HL, Sun D, Peng YC and Wu YL** (2016) Novel effects of the cyclooxygenase-2-selective inhibitor NS-398 on IL-1 β -induced cyclooxygenase-2 and IL-8 expression in human ovarian granulosa cells. *Innate Immun* **22**, 452–65.
- Passo JRS, Costa JJN, da Cunha EV, Silva AWB, Ribeiro RP, de Souza GB, Barroso PA, Dau AM, Saraiva MV, Gonçalves PB, van den Hurk R and Silva JR** (2016) Protein and messenger RNA expression of interleukin 1 system members in bovine ovarian follicles and effects of interleukin 1b on primordial follicle activation and survival *in vitro*. *Domest Anim Endocrinol* **54**, 48–59.
- Peter AT** (2004) An update on cystic ovarian degeneration in cattle. *Reprod Domest Anim* **39**, 1–7.
- Probo M, Comin A, Mollo A, Cairoli F, Stradaoli G and Veronesi MC** (2011) Reproductive performance of dairy cows with luteal or follicular ovarian cysts after treatment with buserelin. *Anim Reprod Sci* **127**, 135–9.
- Ranefall P, Wester K, Andersson AC, Busch C and Bengtsson E** (1998) Automatic quantification of immunohistochemically stained cell nuclei based on standard reference cells. *Anal Cell Pathol* **17**, 111–23.
- Rashid N, Nigam A, Saxena P, Jain SK and Wajid S** (2017) Association of IL-1 β , IL-1Ra and FABP1 gene polymorphisms with the metabolic features of polycystic ovary syndrome. *Inflamm Res* **66**, 621–36.
- Re F, Muzio M, De Rossi M, Polentarutti N, Giri JG, Mantovani A and Colotta F** (1994) The type II ‘receptor’ as a decoy target for interleukin 1 in polymorphonuclear leukocytes: characterization of induction by dexamethasone and ligand binding properties of the released decoy receptor. *J Exp Med* **179**, 739–43.
- Re F, Sironi M, Muzio M, Matteucci C, Introna M, Orlando S, Penton-Rol G, Dower SK, Sims JE, Colotta F and Mantovani A** (1996) Inhibition of interleukin-1 responsiveness by type II receptor gene transfer: a surface ‘receptor’ with anti-interleukin-1 function. *J Exp Med* **183**, 1841–50.
- Richards JS, Liu Z and Shimada M** (2008) Immune-like mechanisms in ovulation. *Trends Endocrinol Metab* **19**, 191–6.
- Richards JS and Pangas SA** (2010) The ovary: basic biology and clinical implications. *J Clin Invest* **120**, 963–72.
- Rizzo A, Campanile D, Mutinati M, Minoia G, Spedicato M and Sciorsci RL** (2011) Epidural vs intramuscular administration of leirelin, a GnRH analogue, for the resolution of follicular cysts in dairy cows. *Anim Reprod Sci* **126**, 19–22.
- Rodgers RJ and Irving-Rodgers HF** (2010) Morphological classification of bovine ovarian follicles. *Reproduction* **139**, 309–18.
- Salvetti NR, Müller LA, Acosta JC, Gimeno JE and Ortega HH** (2007) Estrogen receptors a and b and progesterone receptors in ovarian follicles of cows with cystic ovarian disease. *Vet Pathol* **44**, 373–8.
- Salvetti NR, Stangaferro ML, Palomar MM, Alfaro NS, Rey F, Gimeno EJ and Ortega HH** (2010) Cell proliferation and survival mechanisms underlying the abnormal persistence of follicular cysts in bovines with cystic ovarian disease induced by ACTH. *Anim Reprod Sci* **122**, 98–110.
- Schadendorf D, Moller A, Algermissen B, Worm M, Sticherling M and Czarnetzki BM** (1993) IL-8 produced by human malignant melanoma cells *in vitro* is an essential autocrine growth factor. *J Immunol* **151**, 2667–2675.
- Scherzer WJ, Ruutinen-Altman KS, Putowski LT, Kol S, Adashi EY and Rohan RM** (1996) Detection and *in vivo* hormonal regulation of rat ovarian type I and type II interleukin-1 receptor mRNAs: increased expression during the periovarian period. *J Soc Gynecol Invest* **3**, 131–9.
- Shimizu T, Imamura E, Magata F, Murayama C and Miyamoto A** (2013) Interleukin-8 stimulates progesterone production via the MEK pathway in ovarian theca cells. *Mol Cell Biochem* **374**, 157–61.
- Shimizu T, Kaji A, Murayama C, Magata F, Shirasuna K, Wakamiya K, Okuda K and Miyamoto A** (2012) Effects of interleukin-8 on estradiol and progesterone production by bovine granulosa cells from large follicles and progesterone production by luteinizing granulosa cells in culture. *Cytokine* **57**, 175–81.
- Silvia WJ, Alter TB, Nugent AM and Laranja da Fonseca LF** (2002) Ovarian follicular cysts in dairy cows: an abnormality in folliculogenesis. *Domest Anim Endocrinol* **23**, 167–77.
- Silvia WJ, McGinnis AS and Hatler TB** (2005) A comparison of adrenal gland function in lactating dairy cows with or without ovarian follicular cysts. *Biol Reprod* **5**, 19–29.
- Sims JE, Giri JG and Dower SK** (1994) The two interleukin-1 receptors play different roles in IL-1 actions. *Clin Immunol Immunopathol* **72**, 9–14.
- Sirotkin A** (2011) Cytokines: signalling molecules controlling ovarian functions. *Int J Biochem Cell Biol* **43**, 857–61.
- Smith DE, Hanna R, Della Friend Moore H, Chen H, Farese AM, MacVittie TJ, Virca GD and Sims JE** (2003) The soluble form of IL-1 receptor accessory protein enhances the ability of soluble type II IL-1 receptor to inhibit IL-1 action. *Immunity* **18**, 87–96.
- Smolikova K, Mlynarcikova A and Scsukova S** (2012) Role of interleukins in the regulation of ovarian functions. *Endocr Regul* **46**, 237–53.
- Spriggs MK, Nevens PJ, Grabstein K, Dower SK, Cosman D, Armitage RJ and McMahan CJ, Sims JE** (1992) Molecular characterization of the interleukin-1 receptor (IL-1R) on monocytes and polymorphonuclear cells. *Cytokine* **4**, 90–5.
- Stassi AF, Baravalle ME, Belotti EM, Amweg AN, Angeli E, Velázquez MML, Rey F, Salvetti NR and Ortega HH** (2018) Altered expression of IL-1 β , IL-1RI, IL-1RII, IL-1RA and IL-4 could contribute to anovulation and follicular persistence in cattle. *Theriogenology* **110**, 61–73.

- Stassi AF, Baravalle ME, Belotti EM, Rey F, Gareis NC, Díaz PU, Rodríguez FM, Leiva CJ, Ortega HH and Salvetti NR** (2017) Altered expression of cytokines IL-1 α , IL-6, IL-8 and TNF- α in bovine follicular persistence. *Theriogenology* **97**, 104–12.
- Terranova P and Rice V** (1997) Cytokine involvement in ovarian processes. *Am J Reprod Immunol* **37**, 50–63.
- Ujioka T, Matsukawa A, Tanaka N, Matsuura K, Yoshinaga M and Okamura H** (1998) Interleukin-8 as an essential factor in the human chorionic gonadotropin-induced rabbit ovulatory process: interleukin-8 induces neutrophil accumulation and activation in ovulation. *Biol Reprod* **58**, 526–30.
- Vanholder T, Opsomer G and de Kruif A** (2006) Etiology and pathogenesis of cystic ovarian follicles in dairy cattle: a review. *Reprod Nut Dev* **46**, 105–19.
- Volpert OV, Fong T, Koch AE, Peterson JD, Waltenbaugh C, Tepper RI and Bouck NP** (1998) Inhibition of angiogenesis by interleukin 4. *J Exp Med* **188**, 1039–46.
- Wang CJ, Zhou ZG, Holmqvist A, Zhang H, Li Y, Adell G and Sun XF** (2009) Survivin expression quantified by Image Pro-Plus compared with visual assessment. *Appl Immunohistochem Mol Morphol* **17**, 530–5.
- Woods AM and Judd AM** (2008) Interleukin-4 increases cortisol release and decreases adrenal androgen release from bovine adrenal cells. *Domest Anim Endocrinol* **34**, 372–82.