Journal of Anatomy

J. Anat. (2019) doi: 10.1111/joa.12968

Development of the chondrocranium of two caiman species, *Caiman latirostris* and *Caiman yacare*

María V. Fernandez Blanco[1,2]

[1]*División Paleontología Vertebrados, Museo de La Plata, Universidad Nacional de La Plata, Unidades de Investigación Anexo Museo, La Plata, Buenos Aires, Argentina*
[2]*CONICET, Argentina*

Abstract

Little is known about the embryonic development and variation of the chondrocranium in Crocodylia and there are no works on any *Caiman* species. Due to the importance of cranial features in the systematics of this clade, investigating the development of the skull in embryonic stages is essential. In this study, we present for the first time the development of the cartilaginous skull of two extant *Caiman* species. Anatomical descriptions of the embryonic chondrocranium of *Caiman latirostris* and *Caiman yacare* were made, paying special attention to their inter- and intraspecific variation. For this purpose, pre-hatching ontogenetic cranial series of these two caiman species were prepared with a double staining and diaphanization technique. The main differences with other crocodylian species were observed in the palatoquadrate, and interspecific variation within the genus was recorded in the hyobranchial apparatus and larynx. Some characters may be distinctive of *Caiman* (posterior and ventral surface of the otic process of the palatoquadrate articulated with the dorsal process of the columella auris, and otic process articulated with the lateral wall of the auditory capsule), Alligatoridae (presence of an epiphanial foramen) or *C. latirostris* and *C. yacare* (Corpus hyoidei with different number and position of foramina and different shapes of its anterior contour and anterior and posterior notch, different degrees of broadening of the distal end of the Cornu branchiale I, and presence/absence of a notch in the posteroventral surface of the cricoid). Homologies of the elements belonging to the hyobranchial apparatus could not be confirmed. As in other tetrapods the trachea consists of incomplete cartilaginous rings. Morphological changes and dissimilarities found in this study are useful as a context to start studying phylogenetic constraints. Moreover, in a heterochronic context, variations may be involved.

Key words: embryonic stages; laryngeal cartilages; morphological variation; neurocranium; ontogeny; skull; splanchnocranium; trachea.

Introduction

Embryonic studies of the distinct species of crocodylians have been carried with regard to internal anatomy (e.g. Parker, 1882; Shiino, 1914; De Beer, 1937) as well as external morphology (e.g. Clarke, 1891; Voeltzkow, 1899; Reese, 1915; Magnusson & Taylor, 1980; Ferguson, 1987; Peterka et al. 2010). The entire skull (e.g. Miall, 1878; Parker, 1882; Meek, 1911; Shiino, 1914; De Beer, 1937; Müller, 1965, 1967; Iordansky, 1973; Bellairs & Kamal, 1981; Klembara, 1991), as well as particular structures of it (Meek, 1893; Goldby, 1925; Klembara, 1993, 2001), are the most studied portions of the skeleton. Research on crocodylian pre-hatching is not particularly abundant in the literature and the embryology is still under-studied. The cartilaginous nature of the pre-hatching skull of crocodylians is poorly understood and few studies have analyzed its cartilaginous structure. The oldest works come from the late 19th and early 20th centuries, comprising a complete analysis of the chondrocranium or elements of it in different species such as *Alligator mississippiensis*, *Crocodylus palustris* and *Crocodylus porosus* (e.g. Parker, 1882; Meek, 1911; Shiino, 1914; Goldby, 1925; De Beer, 1937). However, no studies have analyzed the chondrocranium of any species of caiman. Additionally, embryonic development and its variation have not been explored in any crocodylian species, with the exception of *Melanosuchus niger* (Vieira et al. 2018). Accordingly, there is a lack of information about the pre-hatching anatomy of the chondrocranium and its variation in *Caiman* species.

On the other hand, cranial characters are of great importance in Crocodylia systematics. The majority of taxonomical diagnoses are principally based on morphological traits of

Correspondence
María V. Fernandez Blanco, División Paleontología Vertebrados, Museo de La Plata, Facultad de Ciencias Naturales y Museo, Paseo del Bosque s/n 1900, La Plata, Argentina.
E: victoriafernandezblanco@yahoo.com.ar

Accepted for publication *28 January 2019*

skulls and mandibles (e.g. Daudin, 1802; Spix, 1825). Furthermore, cranial features constitute about 75% of crocodyliform phylogenetic morphological datasets (e.g. Brochu, 2011; Pol et al. 2012; Hastings et al. 2013; Salas-Gismondi et al. 2015, 2016; Bona et al. 2018). As the skull plays a fundamental role in systematic phylogenetic analysis of Crocodylia, investigating its development and morphological change over the time, especially in embryonic stages, is absolutely necessary. In this sense, information from embryological sources can be used for establishing correspondences with adult bones from which characters (including inter- and intraspecific variation) are extracted for later phylogenetic analyses. Thus, the information obtained from the study of ontogeny is, ultimately, crucial for the reconstruction of the evolutionary and biogeographical history of the group.

In view of the fact that organisms change throughout their entirely life, it is essential to determine the ontogenetic variation of their morphological traits. Consequently, the main purpose of this work was to study for the first time the development of the cartilaginous skull of two extant *Caiman* species, providing an accurate source of information to study the homologies of adult cranial bones. To achieve this goal, a detailed and exhaustive description of the anatomy and development of the embryonic chondrocranium (neurocranium and splanchnocranium) of two caimanine species, *C. latirostris* and *C. yacare*, has been elaborated, paying special attention to their inter- and intraspecific variation.

Materials and methods

Pre-hatching ontogenetic cranial series of *C. latirostris* and *C. yacare* were studied. A total of 37 embryos of *C. latirostris* and 34 of *C. yacare* were used. Specimens are housed in the herpetological collection of the Museo de La Plata under a collection number for each ontogenetic series, MLP-R.6490 for *C. yacare* and MLP-R.6491 for *C. latirostris* (Table 1). There is an internal order within each ontogenetic series in which the name of the species is first written and abbreviated (CY = *C. yacare*; CL = *C. latirostris*), followed by the stage number and the number of specimen within each stage for each species. The material was collected during two field trips to the Chaco province in 2012 and 2015. All the eggs belonging to two nests per species were removed from nature and were artificially incubated with constant conditions of relative humidity (95%) and temperature (30 °C ± 1) throughout the embryonic period. Embryos of both species were removed every day until hatching and (previous to the staining) fixed and kept in a 5% formaldehyde solution with calcium carbonate. Embryonic stages of both species were assigned to a specific embryonic stage following Iungman et al. (2008), who developed a criterion for aging embryos of *C. latirostris* using external morphological features. Embryos were prepared for the observation of cartilage and bone according to the double staining and diaphanization technique of Taylor & Van Dyke (1985), slightly modified. For this procedure, the following steps were followed in the already fixed embryos: immersion in baths of successively increasing concentrations of alcohol; embedding in Alcian Blue; submersion in 1% KOH; insertion in Alizarin red; and finally submersion again in 1% KOH. The embryos are left in KOH solution until the material is totally cleared and the view of cartilages and bones is ideal. Afterwards, each specimen is conserved in glycerol. This paper deals with the cartilaginous cranium only; bones will be discussed in another scientific article.

Anatomical descriptions of the chondrocranium were drawn for the stained and prepared materials which displayed a light blue/blue color (Alcian Blue). For the observations and drawings, a Zeiss stereomicroscope with a clear camera and a Nikon Stereo Microscope SMZ745/SMZ745T magnifier with a Nikon NI-150 Illuminator illumination source were used. Photographs were obtained using a Nikon D40 camera. Most descriptions were made on specimens in which the cartilages of the skull were well developed and there was little or no osseous coverage. Certain structures, such as the

Table 1 Specimens studied.

Caiman yacare MLP-R.6490	*Caiman latirostris* MLP-R.6491
CY-17/18-1	CL-20
CY-17/18-2	CL-21
CY-17/18-3	CL-22-1
CY-18-1	CL-22-2
CY-18-2	CL-22-3
CY-19	CL-22-4
CY-20	CL-22-5
CY-21-1	CL-22-6
CY-21-2	CL-22-7
CY-22-1	CL-22-8
CY-22-2	CL-22-9
CY-22-3	CL-22-10
CY-23-1	CL-22-11
CY-23-2	CL-23-1
CY-23-3	CL-23-2
CY-23-4	CL-23-3
CY-23-5	CL-23-4
CY-23-6	CL-23-5
CY-23-7	CL-23-6
CY-23-8	CL-23-7
CY-23-9	CL-23-8
CY-23-10	CL-23-9
CY-23-11	CL-23-10
CY-23-12	CL-23-11
CY-23-13	CL-24-1
CY-23-14	CL-24-2
CY-24-1	CL-25-1
CY-24-2	CL-25-2
CY-24-3	CL-25-3
CY-24-4	CL-25-4
CY-25-1	CL-25-5
CY-25-2	CL-25-6
CY-25-3	CL-27-28-1
CY-25-4	CL-27-28-2
	CL-27-28-3
	CL-27-28-4
	CL-27-28-5

Numbers collected for each ontogenetic series (MLP-R.6490 for *Caiman yacare* and MLP-R.6491 for *Caiman latirostris*) with its own internal order: each individual has its own number.

tectum synoticum or the hypoglossal foramina, could also be clearly observed in specimens of later stages of the two caiman species, and were consequently described. All stages were used for the study of the splanchnocranium.

The appropriate time to collect embryos that had been laid, by which time the chondrocranium would already be developed, was estimated from the study of Iungman et al. (2008). Stages 20 to 27–28 and 17/18–25 were sampled in *C. latirostris* and *C. yacare*, respectively. Stages 17–19 in *C. latirostris* and final stages of *C. yacare* (stages 26–28) could not be sampled due to non-availability of material but this did not affect this study. Stage 26 was not described in *C. latirostris* because of the non-eruption of teeth in this species (exclusive attribute of this stage). Stages 27 and 28 (based on the volume of absorbed yolk and the size of the yolk scar) in *C. latirostris* could not be distinguished, so they were grouped (stages 27–28) in this species. A mixed 17/18 stage was established in *C. yacare* following Iungman et al. (2008).

There are some concepts that need to be clarified at this point. Here, the skull is divided and described according to its components regardless of its nature – neurocranium and splanchnocranium. The neurocranium surrounds the brain and sense organs (De Beer, 1937), whereas the splanchnocranium is the portion of the skull that surrounds the alimentary canal (first portion of the digestive and respiratory tract) and is composed of different visceral arches. Each of these components (neurocranium and splanchnocranium) can be cartilaginous or osseous; thus the skull in a cartilaginous stage is called chondrocranium while the osseous stage is the osteocranium. The main focus of this article is on chondrocranium (neurocranium and splanchnocranium) of *C. latirostris* and *C. yacare*. Nevertheless, the trachea is also described here because of its close relationship to the larynx, which is part of the splanchnocranium.

For almost all the chondrocranium descriptions, De Beer (1937) was followed, except in some cases where certain of its structures (e.g. cupola anterior, alar process, pars parietotectalis and pars paranasalis) were not described by that author in crocodylians. In those cases, Klembara (1991) was followed. Moreover, the terminology of Schumacher (1973) was used for the hyobranchial apparatus and larynx. The identification of the laryngeal cartilages was done following Schumacher (1973) but the terminology was not exactly the same as that author used to avoid confusion (e.g. thyroid cartilage and arytenoid cartilage, see Schumacher, 1973: pp. 176–179). Furthermore, otic and occipital regions were described together to facilitate their description and interpretation, as other authors have done for other reptiles and even other crocodylian species (e.g. Rieppel & Zaher, 2001; Klembara, 2005).

Results

The neurocranium consists of three different regions, which are described below. Following, the visceral arches of the splanchnocranium and the trachea are described.

Neurocranium

The ethmoid region

This region occupies approximately one-third of the total length of the chondrocranium and is defined by the position and development of the nasal capsules. These are anteroposteriorly elongated and their medial walls contact intimately with that of the contralateral capsule constituting the nasal septum (Figs 1A and 2A). The nasal septum is a dorsal growth of the trabecula communis and constitutes the anterior extension of the interorbital septum without a defined limit between them. The nasal septum is continued dorsally and laterally with the pars parietotectalis of the cartilago nasoconchalis (sensu Klembara, 1991). The cartilago nasoconchalis forms the roof and lateral wall of the nasal capsules and comprises two pars, pars parietotectalis and pars paranasalis (or parietotectal cartilage and paranasal cartilage). The laterodorsal wall of the anterior half of the nasal capsule is the pars parietotectalis, which is separated from the greater posterior half pars paranasalis by the concha nasalis. In both species of *Caiman*, the thickness of the nasal septum increases from anterior to posterior and from dorsal to ventral to expand laterally and, at this level, continues with the lamina transversalis anterior, forming the floor of the nasal capsule (Figs 1B and 2B). The height of the septum increases progressively from its anterior part to the point where the sphenethmoid commissure begins. From here, its height decreases slightly and then increases to where the planum supraseptale begins (Figs 2C and 3A).

In dorsal view, the roof–floor junction of the nasal capsule occurs laterally at the level of the posterior margin of the fenestra narina, just where the descending portion of the parietotectal cartilage continues with the lamina transversalis anterior (zona annularis) (Figs 1A, 2A,C and 3A). The fenestra narina is an open space that occupies almost the entire anterior dorsal and lateral half of the capsule (Figs 1A, 2A,C and 3A). It is anteriorly delimited by the cupola anterior, medially and laterally by the parietotectal cartilage, and ventrally by the lamina transversalis anterior. The amplitude of the fenestra means that the zona annularis is not as well developed in *C. latirostris* and *C. yacare* as in other species of crocodylians (De Beer, 1937; Bellairs & Kamal, 1981). The mediodorsal margin of the cupola anterior projects a posteriorly directed alar process, visible only in lateral view (Figs 2C and 3A). The anterior portion of the nasal floor is visible through the fenestra narina (Figs 1A, 2A,C and 3A), where the small and rounded apical foramen can be distinguished, as the exit of the ramus medialis nasi of the profundus branch of the trigeminal nerve (V_1; see De Beer, 1937: 229). Dorsally, each parietotectal cartilage is vaulted and the medial junction between them establishes a groove. The parietotectal cartilage is posteriorly projected onto the sphenethmoid commissure which, in turn, is in continuation with the planum supraseptale of the orbitotemporal region (Figs 1A, 2A,C and 3A). The large space of the fenestra olfactoria lies between the sphenethmoid commissure and the dorsal margin of the nasal septum (Figs 1A and 2A). The lateral fenestra, narrow and elongated, is delimited between the sphenethmoid commissure and the postconcha (Figs 1A and 2A). Finally, both pars of the cartilago nasoconchalis are largely visible in this view. They are separated by the

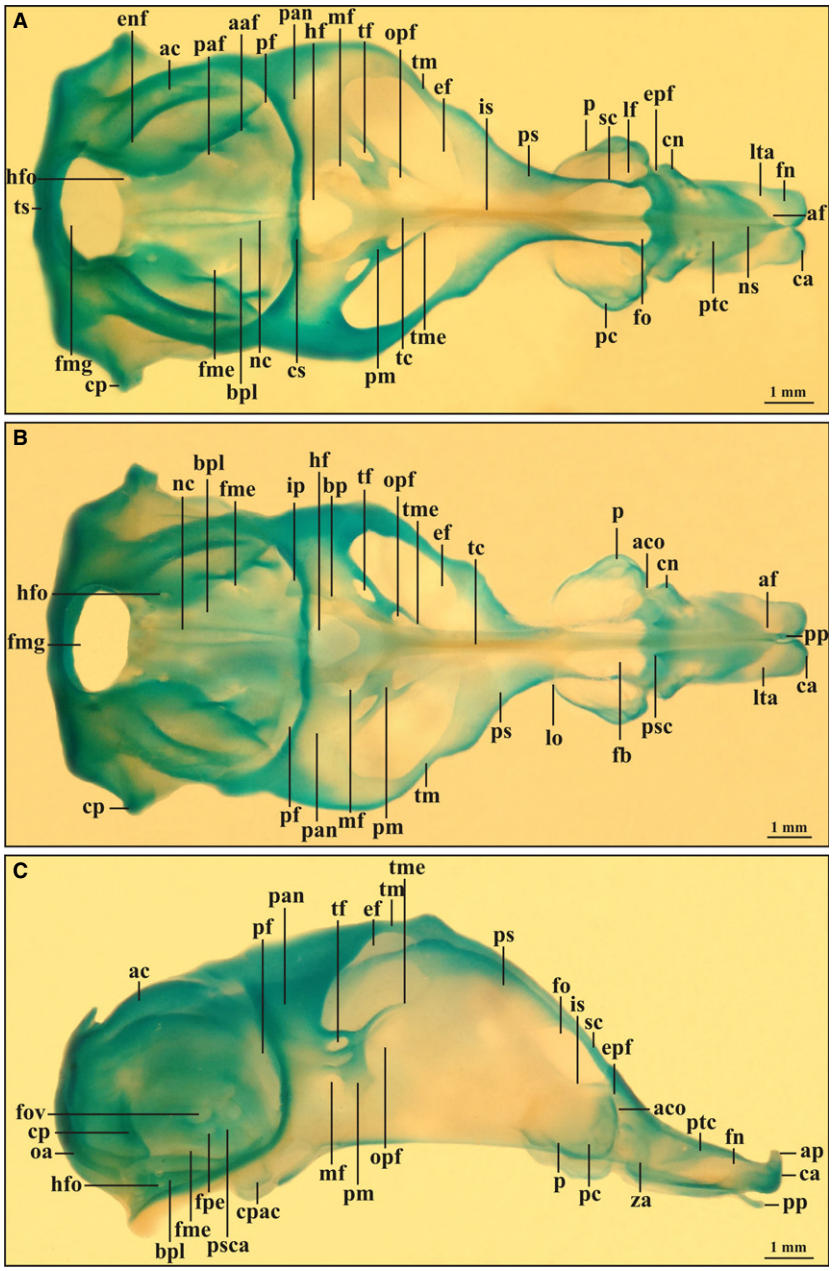

Fig. 1 Chondrocranium of *Caiman latirostris* (MLP-R.6491) and *Caiman yacare* (MLP-R.6490). Dorsal (A) and ventral (B) views of CY-22-1; right lateral view (C) of CL-22-4. aaf, anterius acusticum foramen; ac, auditory capsule; aco, aditus conchae; af, apical foramen; ap, alar process; bp, basitrabecular process; bpl, basal plate; ca, cupola anterior; cn, concha nasalis; cp, crista parotica; cpac, cochlear portion of the auditory capsule; cs, crista sellaris; ef, epioptic fenestra; enf, endolymphatic foramen; epf, epiphanial foramen; fb, fenestra basalis; fme, fissura metotica; fmg, foramen magnum; fn, fenestra narina; fo, fenestra olfactoria; fov, fenestra ovalis; fpe, foramen perilymphaticum; hf, hypophysial fenestra; hfo, hypoglossal foramen; ip, infrapolar process; is, interorbital septum; lf, lateral fenestra; lo, lamina orbitonasalis; lta, lamina transversalis anterior; mf, metoptic fenestra; nc, notochordal canal; ns, nasal septum; oa, occipital arch; opf, optic fenestra; p, postconcha; paf, posterius acusticum foramen; pan, pila antotica; pc, paranasal cartilage; pf, prootic fenestra; pm, pila metoptica; pp, prenasal process; ps, planum supraseptale; psc, paraseptal cartilage; psca, processus subcapsularis; ptc, parietotectal cartilage; sc, sphenethmoid commissure; tc, trabecula communis; tf, trochlear foramen; tm, taenia marginalis; tme, taenia medialis; ts, tectum synoticum; za, zona annularis.

concha nasalis, a backwards invagination into the nasal capsule cavity, which contains a diverticulum of the nasal sac, probably the caviconchal sinus (Witmer, 1995). The vertical orifice through which the concha nasalis opens to the surface is the aditus conchae (Figs 1A, 2A,C and 3A). The hind wall of the nasal capsule is formed by the lamina orbitonasalis, which joins the hind edge of the pars paranasalis to the nasal septum with which it is fused. The

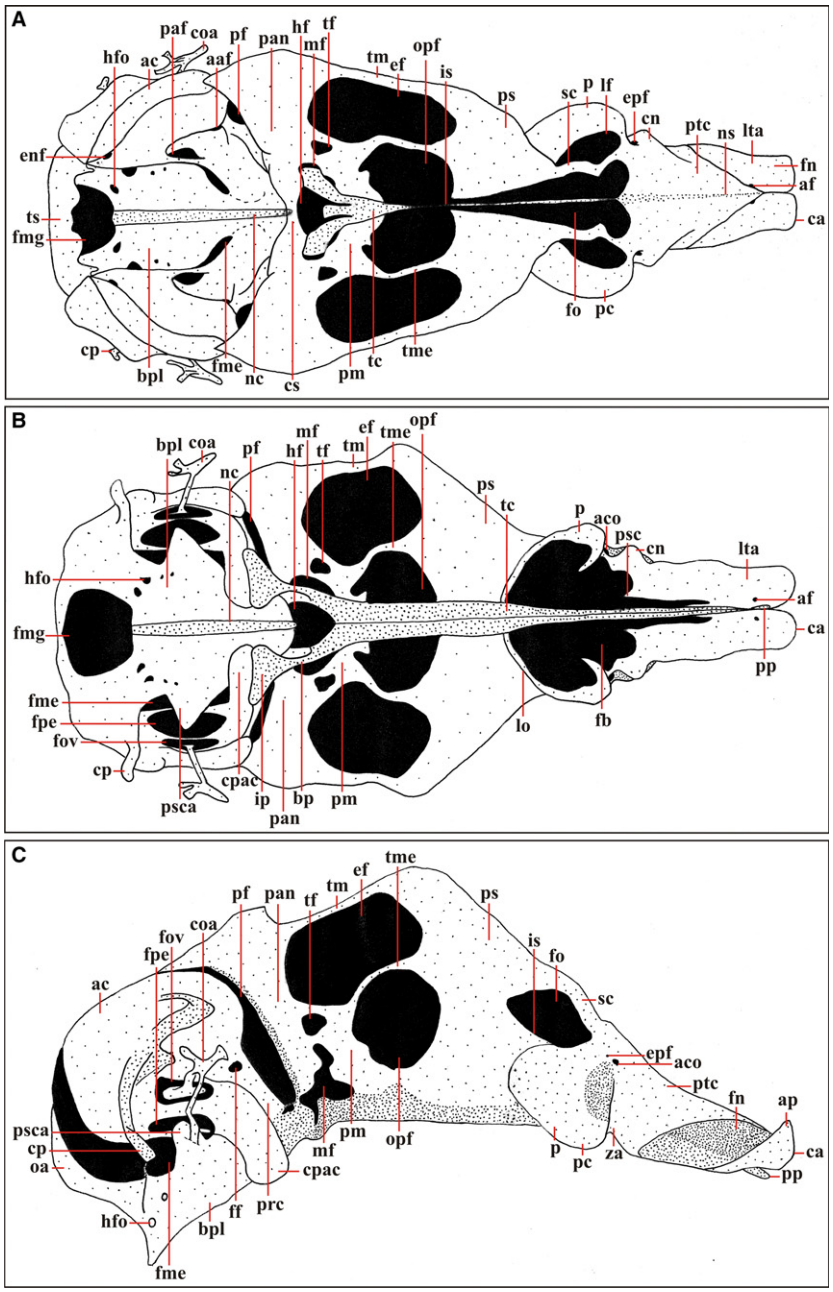

Fig. 2 Reconstruction of the chondrocranium of *Caiman latirostris* (MLP-R.6491) and *Caiman yacare* (MLP-R.6490). Dorsal (A) and ventral (B) views of CL-20, CY-17/18-1 and CY-19; right lateral view of CY-17/18-1 and CY-19 (C). aaf, anterius acusticum foramen; ac, auditory capsule; aco, aditus conchae; af, apical foramen; ap, alar process; bp, basitrabecular process; bpl, basal plate; ca, cupola anterior; cn, concha nasalis; coa, columella auris; cp, crista parotica; cpac, cochlear portion of the auditory capsule; cs, crista sellaris; ef, epioptic fenestra; enf, endolymphatic foramen; epf, epiphanial foramen; fb, fenestra basalis; ff, facial foramen; fme, fissura metotica; fmg, foramen magnum; fn, fenestra narina; fo, fenestra olfactoria; fov, fenestra ovalis; fpe, foramen perilymphaticum; hf, hypophysial fenestra; hfo, hypoglossal foramen; ip, infrapolar process; is, interorbital septum; lf, lateral fenestra; lo, lamina orbitonasalis; lta, lamina transversalis anterior; mf, metoptic fenestra; nc, notochordal canal; ns, nasal septum; oa, occipital arch; opf, optic fenestra; p, postconcha; paf, posterius acusticum foramen; pan, pila antotica; pc, paranasal cartilage; pf, prootic fenestra; pm, pila metoptica; pp, prenasal process; prc, prefacial commissure; ps, planum supraseptale; psc, paraseptal cartilage; psca, processus subcapsularis; ptc, parietotectal cartilage; sc, sphenethmoid commissure; tc, trabecula communis; tf, trochlear foramen; tm, taenia marginalis; tme, taenia medialis; ts, tectum synoticum; za, zona annularis. No scale is given because it is a reconstruction made of different specimens with different sizes.

postconcha is visible as a bulge lateral to the lateral fenestra and posterior to the concha nasalis. It encloses a large cavity that probably contains a diverticulum of the caviconchal sinus and is delimited mostly by the paranasal cartilage, with the lamina orbitonasalis contributing to it caudally.

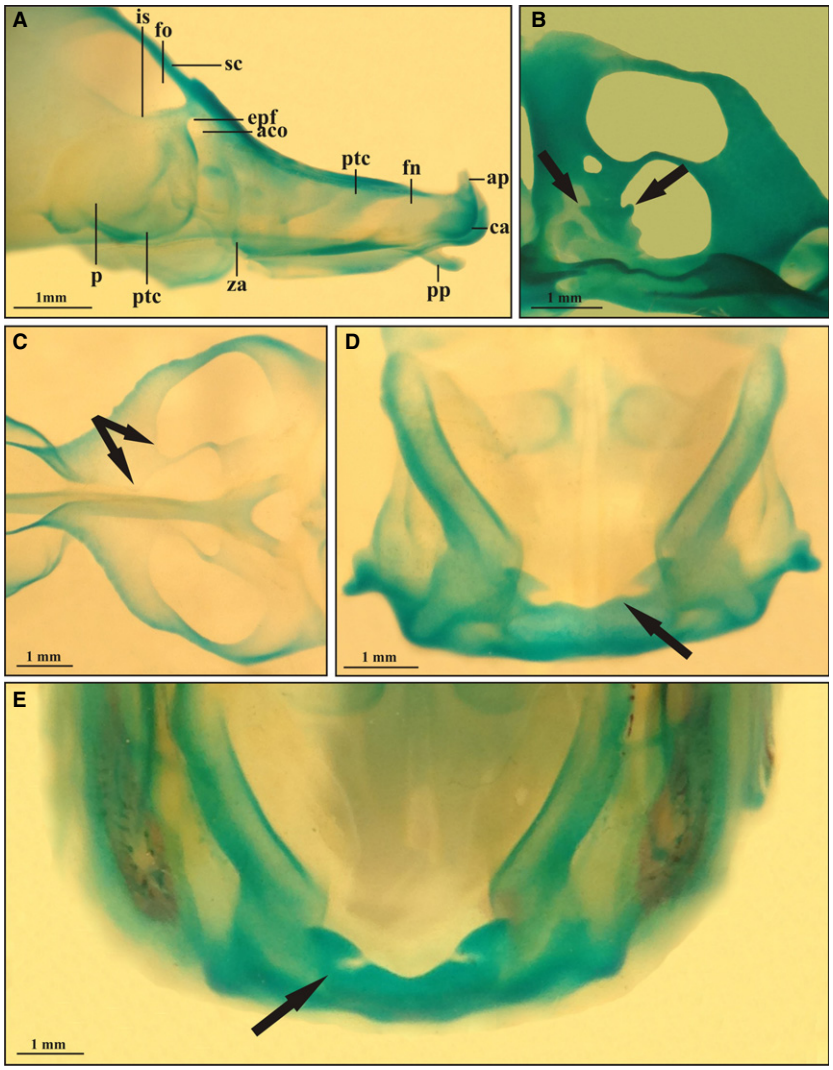

Fig. 3 Details of the chondrocranium of *Caiman latirostris* (MLP-R.6491) and *Caiman yacare* (MLP-R.6490). (A) Right lateral view of the ethmoid region of CY-22-1. (B) Dorsolateral view of the orbitotemporal region of CY-17/18-1. Dorsal view of CL-22-4 of the orbitotemporal (C) and otic-occipital (D) regions. (E) Dorsal view of the otic-occipital region of the CL-22-10. Arrows: anterior and posterior projections of the pila metoptica (B); optic fenestra exceeds anterior to the epioptic fenestra (C); one of the two rounded half projections that are directed anteriorly from the anterior margin of the tectum synoticum (D); fusion of medium and lateral projections of tectum synoticum (E). aco, aditus conchae; ap, alar process; ca, cupola anterior; epf, epiphanial foramen; fn, fenestra narina; fo, fenestra olfactoria; is, interorbital septum; p, postconcha; pp, prenasal process; ptc, parietotectal cartilage; sc, sphenethmoid commissure; za, zona annularis.

In the ventral view of this region is the lamina transversalis anterior, which forms the floor of the anterior middle portion of each capsule and occupies a larger space as development progresses (Figs 1B and 2B). This lamina is arched and its rounded anterior end accompanies the cupola anterior shape which dorsally projects from it (Figs 1B, 2B,C and 3A). The lamina transversalis anterior does not present ectochoanal cartilage, as occurs in other reptiles (e.g. ophidians, De Beer, 1937: p. 248: lámina 90), since the Jacobson's organ, which delimits this cartilage, is reduced in crocodylians. In the anterior region of the floor, located lateral to the nasal septum, there are the paired apical foramina at the point where the prenasal process projects forwards in the midline (Figs 1B and 2B). The prenasal process, odd and with a rounded section, is a rod that thins towards its apex and curves abruptly upwards in its anteroventral trajectory (Figs 2C and 3A). Its anterior end neither exceeds nor reaches the cupola anterior. Behind each apical foramen, the lamina transversalis anterior projects into a paired and short paraseptal cartilage. This cartilage has an acute apex directed towards the fenestra basalis (for the choana; Figs 1B and 2B). This fenestra is narrowed anteriorly, between the trabecula communis and the lamina transversalis anterior, and is broad posteriorly, between the trabecula communis and both pars of the cartilago nasoconchalis. The fenestra basalis is posteriorly delimited by

the lamina orbitonasalis (Figs 1B and 2B,C). The concha nasalis occupies a part of the fenestra basalis, partially dividing it into two portions, an anterior one and a more elongated and wider posterior one (Figs 1A,B and 2A–C).

In lateral view, except for the epiphanial foramen (Figs 2C and 3A), the same structures that were described in the other views are observed. In the anterior area of this region, the rounded surface of the cupola anterior with the alar process and the curved trajectory of the prenasal process is observed. Through the fenestra narina, the anterior portion of the nasal septum and part of the lamina transversalis anterior can be distinguished. Posterior to this fenestra, the pars parietotectalis and pars paranasalis can be distinguished, both separated by the aditus conchae. The aditus conchae shows in its most dorsal portion a foramen that would be considered the epiphanial foramen (see Discussion), which serves as the exit of the ramus lateralis nasi of the profundus branch of the trigeminal nerve (V_1; see De Beer, 1937: 229). The pars paranasalis is the most posterior portion of the lateral wall of the nasal capsule and the sphenethmoid commissure runs dorsal to it. As previously reported, its medioventral portion connects with the lamina orbitonasalis and the latter with the nasal septum.

The orbitotemporal region

In dorsal view, this region extends from the lamina orbitonasalis to the portion of the skull that rises up from the structure formed by the crista sellaris. In lateral view, this region extends from the posterior area of the postconcha to the prootic fenestra.

In dorsal view, given the absence of any ossified frontals and parietals, the skull remains membranous, constituting a broad frontoparietal fenestra. Through it, it is possible to distinguish most of the lateral and floor structures of this region (foramina, fenestrae, taeniae, pilae, trabeculae and trabecula communis; Figs 1A and 2A). The interorbital septum is the posterior continuation of the nasal septum. It grows dorsally from the trabecula communis and diverges dorsally and laterally, forming a cartilaginous area on each side, the planum supraseptale (Figs 1A and 2A). Its dorsal margin increases in height along the area that contacts the planum supraseptale. From here, it suddenly curves posteroventrally until it ends in front of the hypophysial fenestra (Figs 1C and 2C). Its thickness hardly varies anteroposteriorly but it does increase in the dorsoventral direction. The posterior portion of the planum supraseptale is perforated by one foramen and three fenestrae (Figs 1A,C and 2A,C). The largest, most dorsal and lateral, is the epioptic fenestra. Neither nerves nor blood vessels pass through this fenestra (Klembara, 1991). Ventral and medially are the optic fenestra, anteriorly, and the metoptic fenestra, posteriorly. The optic and metoptic fenestrae are ventrally limited by the interorbital septum and the trabeculae, respectively. The optic nerve runs through the optic fenestra, and the oculomotor nerve and arteria ophtalmica leave the metoptic fenestra (Klembara, 1991). In the cartilaginous area delimited by these three fenestrae and by the pila antotica, opens the trochlear foramen. This foramen is divided, on the right or left side, partially or entirely in two orifices in some specimens of *C. yacare* (CY-17/18-3, CY-18-1, CY-18-2) and has a diameter several times greater than in *C. latirostris*. The cartilage areas that delimit all these openings are the taenia marginalis (dorsal margin of the epioptic and prootic fenestrae and the pila antotica), the taenia medialis (separates the epioptic and optic fenestrae), the pila antotica (separates the prootic fenestra from the epioptic fenestra and the trochlear foramen) and the pila metoptica (separates the optic and metoptic fenestrae). The lower area of the pila metoptica in *C. yacare* has an anterior projection towards the optic fenestra and another posterior one towards the metoptic fenestra (Fig. 3B). The prootic fenestra, which lies inside the ganglion of the trigeminal nerve, is anteriorly delimited by the pila antotica, medioventral by the trabeculae, dorsally by the free posterior end of the taenia marginalis and posteriorly by the anterior portion of the auditory capsule. The taenia marginalis is a long, flat, cartilaginous band that forms the dorsolateral border of the cranial cavity. As it grows backward from the planum supraseptale, it widens up to project into a free end that exceeds the level of the pila antotica and overlaps laterally with the anterior third of the auditory capsule (Figs 1A,C and 2A,C). In dorsal views of most specimens of early stages of *C. yacare* ($n = 6$, stages 17/18, 19, 20 and 22), the optic and epioptic fenestrae reach the same level of anterior extension. This is not verified in stage 18 ($n = 2$), where the optic fenestra exceeds the epioptic fenestrae anteriorly (Fig. 3C). This variation can also be appreciated in *C. latirostris* ($n = 3$, stages 20 and 22).

In ventral view, a pair of short trabeculae converge medially and anteriorly into a long trabecula communis, which extends to the floor of the ethmoid region (Figs 1B and 2B). The trabeculopolar angle (Fig. 2C) changes in different stages; it is well marked in CY-17/18-1, CY-17/18-3 and CY-18-1, and could not be determined in CY-17/18-2; it could not be detected in *C. latirostris*. In CY-18-2, the chondrocranium begins to align and this angle disappears completely in CY-19, CY-20 and CL-20. Between the trabeculae and a posterior transverse bar of cartilage, the crista sellaris, the triangular hypophysial fenestra is delimited. The arteria carotis interna passes through the hypophysial fenestra (De Beer, 1937). At the base of the crista sellaris, on each side of the hypophysial fenestra, the foramen for the abducens nerve is located. In early stages (CY-22-1, CL-22-4, CY-18-2, CY-19, CY-20 and CL-22-2), a Y-shaped basitrabecular process is fused to the end of each trabecula. This process expands and flattens distally (infrapolar process; see Discussion) and it is oriented posteriorly and ventrally towards the cochlear portion of the auditory capsule (Figs 1C and 2B).

In the lateral view of *C. yacare*, the dorsal margin of the first section of the taenia marginalis is first curved downwards and then goes up, describing a small notch at the

level of the dorsal edge of the epioptic fenestrae; this notch is slight in *C. latirostris* (Figs 1A,C and 2A,C). Subsequently, at the level of its free posterior area, it forms another smaller notch in the two species. These two notches do not appear to be unique to this caiman species, since they can be observed in *Alligator* and *Crocodylus* (e.g. Bellairs & Kamal, 1981; Klembara, 1991).

The otic-occipital region

This region extends from the pila antotica to the occipital condyle and comprises the auditory capsules, the basal plate and the tectum synoticum.

In dorsal view, the open space between the auditory capsules corresponds to the posterior portion of the frontoparietal fenestra, which is delimited at this level by the dorsal edge of the capsules (laterally) and by the tectum synoticum (posteriorly; Figs 1A and 2A). Through the tectum, both posterior sides of the capsules communicate with each other; this could be observed in this study from the very beginning of the development of the structure. Its development begins at stage 18 with the formation of two cartilage bands that project medially from the lower portion of the posterior wall of each auditory capsule. In the following stages, both cartilage bands join medially, forming a complete sub-rectangular roof. Further development proceeds by extension of the anterior margin of the tectum that is initially concave with two lateral projections (stages 19, 20 and 21; Fig. 1A). These projections continue their development, overtaking in height the dorsal margin of the auditory capsules and curving medially. The final morphology of the tectum synoticum is achieved in stages 22 and 23 of *C. yacare* with the additional formation of two rounded projections that are anteriorly directed from the anterior and medial margin of the tectum (Figs 2A and 3D). In some cases (e.g. CL-22-10, CL-22-11, CY-23-9, CY-23-12, CY-23-13), the medial projections merge with the lateral ones (Fig. 3E). The auditory capsule has a kidney-shaped shape that, in lateral view, has a dorsal section with an anteroposterior length greater than that of the ventral section (Figs 1C, 2C and 4A). Anteriorly, the capsule is separated from the orbital structures by a wide prootic fenestra and, dorsally at this level, the anterior margin of the capsule overlaps with the more posterior portion of the taenia marginalis (Figs 1A,C and 2A,C). Behind the prootic fenestra, the front of the capsule is tied to the anterior portion of the basal plate by a single bar of cartilage, the prefacial commissure, where the rounded facial foramen is enclosed (Figs 2C and 5). The facialis nerve passes by this foramen (Klembara, 1991). Dorsal and posteriorly, each auditory capsule communicates with each other through the tectum synoticum (Figs 1A and 2A). The lateral wall of the capsule is dorsal and posteriorly contoured by the crista parotica (Figs 1A,C and 2A,C). In front of the descending branch of the crista parotica, the capsule is perforated by two oval foramina, one anterodorsal (fenestra ovalis) and the other posteroventral (foramen perilymphaticum; Figs 1C, 2C and 4A). The fenestra ovalis is almost completely covered by the basal part of the columella which rests on the fenestra. Three foramina open into the medial wall of the capsule, one quite broad, dorsal and posterior (endolymphatic foramen) and the other two (anterius and posterius acusticum foramina) located in the ventral margin of the capsule, just at the level of the prefacial commissure (Figs 4B and 5). The anterius acusticum foramen is immediately above and a bit anteriorly than the posterius acusticum foramen, and both foramina are bigger than the facial foramen.

The basal plate is traversed axially by the notochordal canal that decreases in width anteriorly and reaches the hypophysial fenestra, penetrating it (the basicranial fenestra is not formed in crocodylians; Figs 1A and 2A). Laterally, the basal plate is perforated by the hypoglossal foramina, located on each side of the notochordal canal and oriented anteroposteriorly (Figs 1C and 2C). The number of these foramina varies during development in both species. For example, the three specimens of stage 17/18 of *C. yacare* have four foramina: the first two almost imperceptible, the next larger and partially subdivided (probably formed by the union of two foramina), and the fourth with a similar size to the third. In stage 18 of the same species, only three foramina persist, as one of the foramina mentioned above is lost. This process of loss of the anterior foramina culminates in the following stages of *C. yacare* (stages 19–22) where only two foramina of similar size persist, corresponding to the 3rd and 4th. In the only specimen of stage 20 and in the two individuals of stage 22 of *C. latirostris*, there are three foramina, which correspond (by shape and position in comparison with *C. yacare*) to the foramina 2nd to 4th of the complete series. In the remaining specimens of stage 22 of *C. latirostris*, only two foramina are observed, the 3rd and 4th, constituting the definitive condition of the chondrocranium of this species. These foramina serve as the exit of the hypoglossal nerve (Klembara, 1991).

The ventral view distinguishes the basal plate, the processus subcapsularis and the floor of the auditory capsule (cochlear portion; Figs 1B and 2B). The cochlear portion lodges at the ductus cochlearis and is formed by a massive process, apparently cylindrical in transverse section, that originates in the posterior portion of the floor of the auditory capsule and runs through it until it reaches the infrapolar process, but without contacting it. In its path, it develops a medial and ventral curvature, its free anterior end terminating in a structure similar to a condyle. Between the auditory capsule and the basal plate, the fissura metotica opens, an axially elongated opening located below the area where the capsule joins the basal plate, just lateral, dorsal and anterior to the hypoglossal foramina (Figs 1C, 2C, 4 and 5). The glossopharyngeal, vagus and accessorius cranial nerves (IX, X and XI cranial nerves, respectively) and the vein jugularis pass through the most posterior part of the fissura metotica (Klembara, 1991). The processus subcapsularis is a

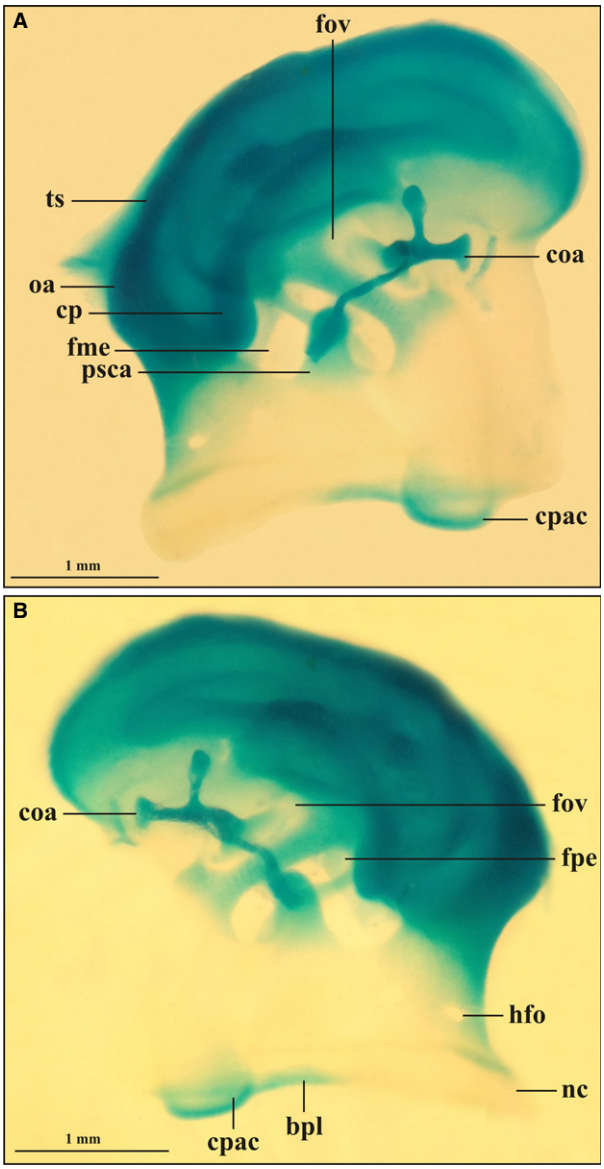

Fig. 4 Right auditory capsule of *Caiman yacare* (MLP-R.6490). Lateral (A) and medial (B) views of CY-19. bpl, basal plate; coa, columella auris; cp, crista parotica; cpac, cochlear portion of the auditory capsule; fme, fissura metotica; fov, fenestra ovalis; fpe, foramen perilymphaticum; hfo, hypoglossal foramen; nc, notochordal canal; oa, occipital arch; psca, processus subcapsularis; ts, tectum synoticum.

dorsal prolongation of the basal plate, also located in front of the hypoglossal foramina, which extends below the auditory capsule and the fissura metotica. Ventrally, the capsules are joined by the occipital arch, completing the ring that encloses the foramen magnum (Figs 1B and 2B). The foramen magnum (not yet dorsally closed by the tectum at stage 18 of *C. yacare*) is oblique and has a circular/rhomboidal shape. Beneath it, the only occipital condyle develops, which is a posterior continuation of the basal plate and surrounds the notochord.

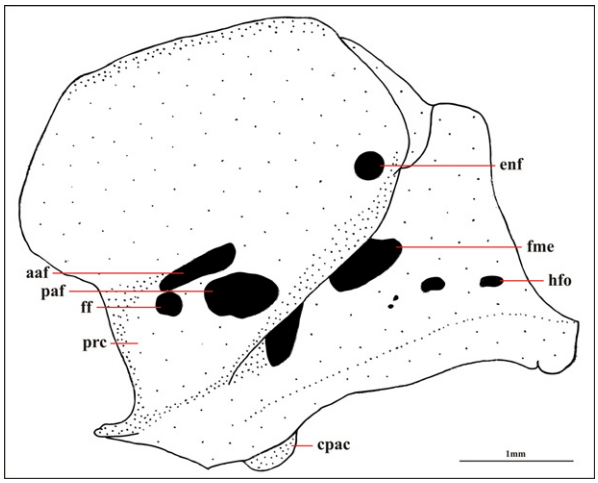

Fig. 5 Drawing of the medial view of the right auditory capsule of *Caiman yacare* (MLP-R.6490; CY-17/18-1). aaf, anterius acusticum foramen; cpac, cochlear portion of the auditory capsule; enf, endolymphatic foramen; ff, facial foramen; fme, fissura metotica; hfo, hypoglossal foramen; paf, posterius acusticum foramen; prc, prefacial commissure.

Splanchnocranium

Mandibular arch

The mandibular arch is composed of a ventral portion that forms the mandible, Meckel's cartilage, and a dorsal portion, the palatoquadrate, which is restricted to the adjacent areas of the auditory capsule.

Meckel's cartilage is composed of two thin branches with a cylindrical section that meet anteriorly in the midline through a cartilaginous mandibular symphysis (Figs 6A and 7A). Each branch is almost rectilinear, runs in an anteroposterior direction and, at the level of the symphysis, presents a triangular bulge. Between this protuberance and the rest of the mandibular branch, there is a small lateral constriction (Figs 6B and 7B). The protuberance and the constriction begin to develop in stages 17/18 and 18 of *C. yacare*, while they are already formed in the earliest stages available of *C. latirostris*. The symphysis between both cartilages extends from the second to the third or fourth alveolus or tooth in formation (Fig. 8A). The most dorsal and posterior end of each branch constitutes the articular fossa, which has an irregular shape; its major axis is anteroposteriorly orientated. This region extends posteroventrally and slightly medially, forming the retroarticular process, which is approximately the same length as the articular area but is more vertically positioned (Figs 6A and 7A).

The palatoquadrate is a very large element that leans against the pila antotica, the prootic fenestra and the anterior portion of the lateral wall of the auditory capsule (Fig. 8B). It is a massive cartilage with a shape of a boomerang with a posterior concavity that constitutes the otic notch. The palatoquadrate is composed of two branches, a



Fig. 6 Meckel's cartilage of *Caiman yacare* (MLP-R.6490), dorsal to the hyobranchial apparatus (A) and right lateral (B) views of CY-19. aa, articular area; rp, retroarticular process.

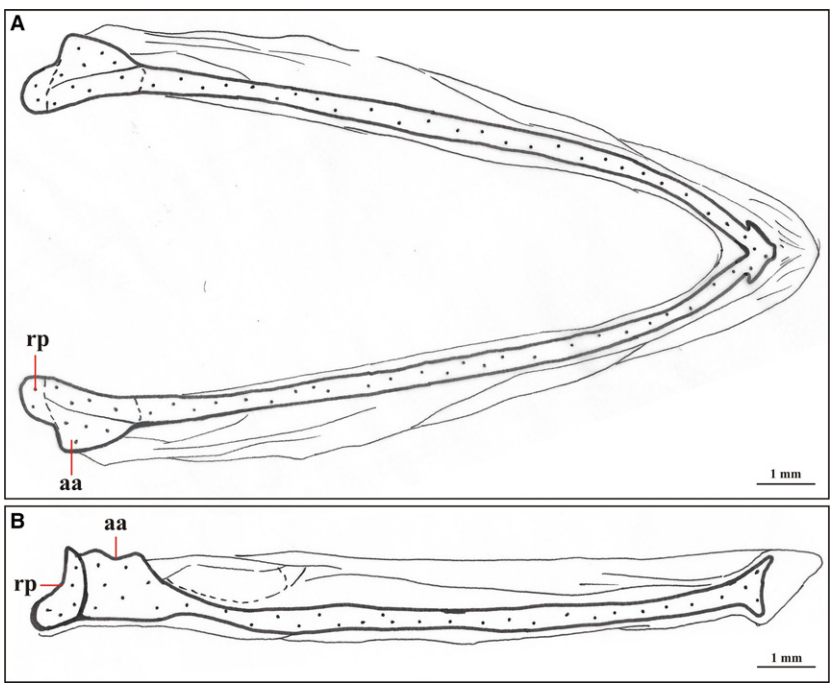

Fig. 7 Drawing of Meckel's cartilage of *Caiman yacare* (MLP-R.6490). Dorsal (A) and right lateral (B) views of CY-22-1. aa, articular area; rp, retroarticular process.

dorsal branch (otic process) and a ventral one (articular portion *sensu* De Beer, 1937). The latter is more elongated and has a triangular-shaped process (pterygoid process) that projects from its medial wall to the trabeculae (Fig. 8C). The otic process is not yet fully developed in early embryos of either species (e.g. CY-17/18-1). The pterygoid process does not present an ascending process in the studied species of *Caiman* as it has been observed in *Crocodylus* (De Beer, 1937: 266, plate 93. 4). Neither the presence of a basal process nor any other structure was observed to be in contact with the basitrabecular process.

Hyoid and branchial arches

The dorsal cartilaginous portion of the hyoid arch is associated with the auditory capsule and is represented by a system of continuous cartilages arranged behind the otic notch. In crocodylians, this cartilage system is composed of the columella auris, whose medial portion ossifies and whose lateral portion (extracolumella) remains cartilaginous. From the medial part of the columella, a processus dorsalis raises up and, from the extracolumella, the pars interhyalis is projected. The pars interhyalis projects downwards to an epihyal cartilage which, in turn, is continuous with a stylohyal cartilage. The latter cartilage is continuous ventrally and attached to the retroarticular process (medial and anterior apex) of Meckel's cartilage.

The columella auris (Fig. 9A) fits into the membrane that obliterates the fenestra ovalis and projects anterolaterally to the point where it splits into two elements, both dilated at its free end. These are the lateral and anterior extracolumella, inserted in the tympanic membrane, and the posterior processus dorsalis, which articulates with the palatoquadrate. Ventral to the bifurcation of extracolumella and processus dorsalis, the pars interhyalis, a semicircular cartilage that is concave anteriorly, projects downwards to the epihyal, which is continued with the stylohyal. These elements are not yet fused in some early embryos and can be distinguished as such (e.g. CY-18-2; Fig. 9B). From stage 23, the dilated portion of the processus dorsalis develops a ventral projection that, in stage 25, approaches the pars interhyalis and in many cases reaches it (Fig. 9C).

The ventral portion of the hyoid arch, added to the remains of the branchial arches, forms the hyobranchial apparatus (hyoid apparatus *sensu* Schumacher, 1973). In the species studied here, as in other crocodylians, this is made up of the Corpus hyoidei and the pair of Cornu branchiale I.

Corpus hyoidei. During all the embryonic development, the Corpus hyoidei is a thin cartilaginous plate, which goes from flat to slightly warped, of an approximately trapezoidal outline, complicated by processes, emarginations and notches. Although its maximum width is in the anterior part and decreases progressively towards the posterior region, the plate undergoes a sharp narrowing in the area of contact with the Cornu branchiale I (Fig. 10). The plaque is located on the floor of the oral cavity between both hemimandibles and serves to anchor the muscles of the tongue (Fig. 8A). In the midline, dorsal and posterior, it presents a slight concavity where the larynx and the first tracheal rings are accommodated (Fig. 10A).

On each side of the middle anterior end of the Corpus hyoidei, there is a lateral and anterior process, flat and lobular, whose anterior border is irregular due to the existence of finger-like projections (Fig. 10A,B). These projections have not yet appeared in CL-20, CL-21, CL-22-1, CY-17/18-1, CY-17/18-2, CY-17/18-3, CY-18-1, CY-18-2, CY-19; its development begins in CL-22-2 and CY-20 (Fig. 10C). Between the middle anterior end and each anterior lateral process, there is a notch that begins to develop in CY-19 and CL-22-2 (Fig. 10C). This notch is more rounded in *C. latirostris* than in *C. yacare*, in which it presents more angular edges (Fig. 10D). The middle anterior end of the Corpus hyoidei also exhibits finger-like projections, as described for the anterior lateral processes. The number and degree of development of these projections varies intraspecifically, regardless of the ontogenetic stage. However, the entire anterior contour of the Corpus hyoidei, formed by the anterior border of middle anterior end and anterior lateral processes, is curved in all specimens of *C. latirostris* and in early stages of *C. yacare* (CY-17/18-1, CY-17/18-2, CY-17/18-3, CY-18-1, CY-18-2, CY-19), and flattens in older specimens of *C. yacare* (Fig. 10B,D).

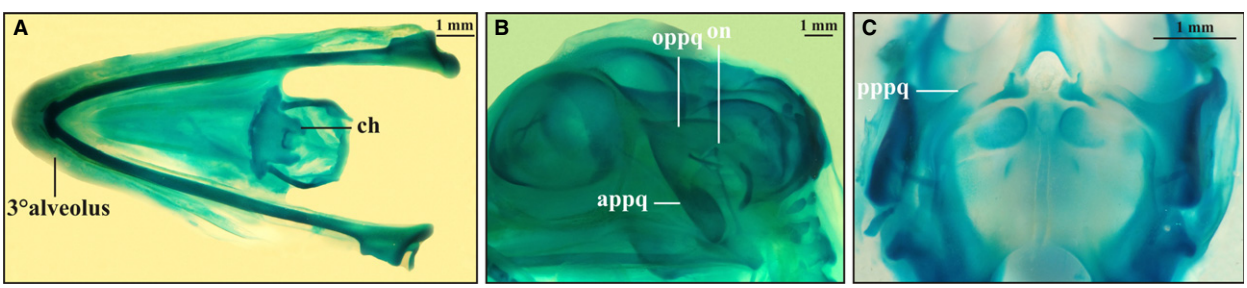

Fig. 8 Details of the palatoquadrate and Corpus hyoidei of *Caiman latirostris* (MLP-R.6491) and *Caiman yacare* (MLP-R.6490). Dorsal view of Meckel's cartilage (A) and ventral view of palatoquadrate (C) of CY-20. (B) Left lateral view of the palatoquadrate of CL-23-2. appq, articular portion of the palatoquadrate; ch, Corpus hyoidei; on, otic notch; oppq, otic process of the palatoquadrate; pppq, pterygoid process of palatoquadrate.

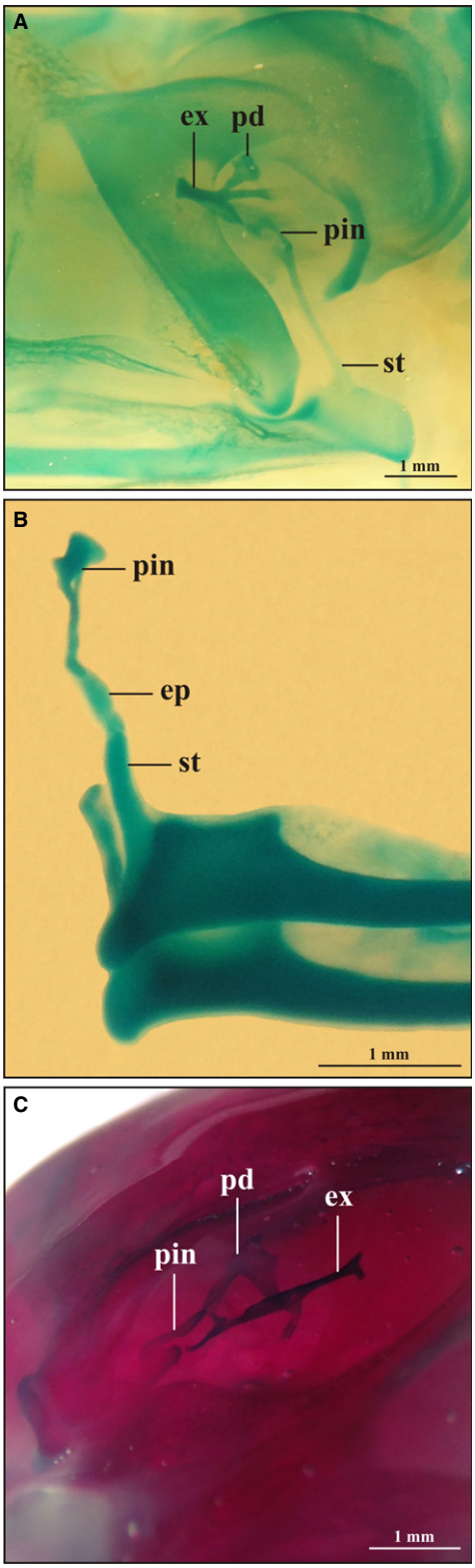

Fig. 9 Columella auris of *Caiman latirostris* (MLP-R.6491) and *Caiman yacare* (MLP-R.6490). (A) Left lateral view of CL-22-6. Posteroventral right lateral view of (B) CY-18-2 and (C) CL-27-28-4. ep, epihyal; ex, extracolumella; pd, processus dorsalis; pin, pars interhyalis; st, stylohyal.

The lateral region of the Corpus hyoidei, between the anterior and posterior lateral processes, is slightly irregular in embryos of both species. The posterior end of the Corpus hyoidei has a rounded indentation that defines two short and rounded posterior lateral processes. The notch is, in general, wider and less deep in *C. latirostris* than in *C. yacare* (Fig. 10B) and, as a result, the posterior lateral processes have a different degree of development in each species (Fig. 10). Almost all embryos of *C. yacare* (except specimens of stages 17/18 and 18, and some individuals of stages 22 and 23) have foramina in the Corpus hyoidei. These foramina are of variable size and can appear unilaterally (Fig. 10E) on both the right and the left side (in the case of a single foramen) or both sides (when there are two foramina) in the anterior, central or posterior region of the Corpus hyoidei (Fig. 10D). A few individuals of *C. latirostris* (CL-20, CL-22-2, CL-22-3 and CL-23-2) have a medium and anterior foramen (Fig. 10C).

Cornu branchiale I. This paired structure articulates between the anterior lateral process and the anterior lateral region of the Corpus hyoidei. In all the observed stages of both species, the Cornu branchiale I appears as a completely separate element but it articulates with the Corpus hyoidei. It has a cylindrical rod shape along its three-fourth proximal length and is expanded and flat at the distal end. The distal end of the Cornu branchiale I is tapered in *C. yacare* (except in four specimens where it dilates slightly; Fig. 10E), but it presents different degrees of broadening in *C. latirostris* (Fig. 10A). The medial margin of the Cornu branchiale I presents a narrowing between the cylindrical and flat section in most specimens of both species (Fig. 10E). The degree of development of this constriction varies without relation to species or stage. Additionally, in five specimens of *C. yacare* and three of *C. latirostris* of the total sample, there is a notch in the medial margin of the Cornu branchiale I, after the narrowing already described (Fig. 11).

Laryngeal cartilages and trachea

The larynx of the species studied, as generally found for non-mammalian tetrapods, consists of a cricoid cartilage and paired arytenoid cartilages (*sensu* Göppert, 1900), deriving from the branchial arches. Although the trachea is not strictly a cranial structure, its first portion is closely related to the larynx, which is why it is described in this section. The arytenoid and cricoid cartilages are evident from stage 20 of *C. yacare* and stage 22 of *C. latirostris*. The cricoid cartilage lodges in the concavity of the Corpus hyoidei, ventral to the arytenoid cartilages (Fig. 10A), and it is open dorsally in the first stages observed. Its ventral area, which rests on the Corpus hyoidei, is flat and expanded. This area is thinned (in the anteroposterior direction) towards each lateral side and grows dorsally in the form of two processes that end up unattached (Fig. 12A). From stage 24 in *C. yacare* and from stage 23 in *C. latirostris* these free ends

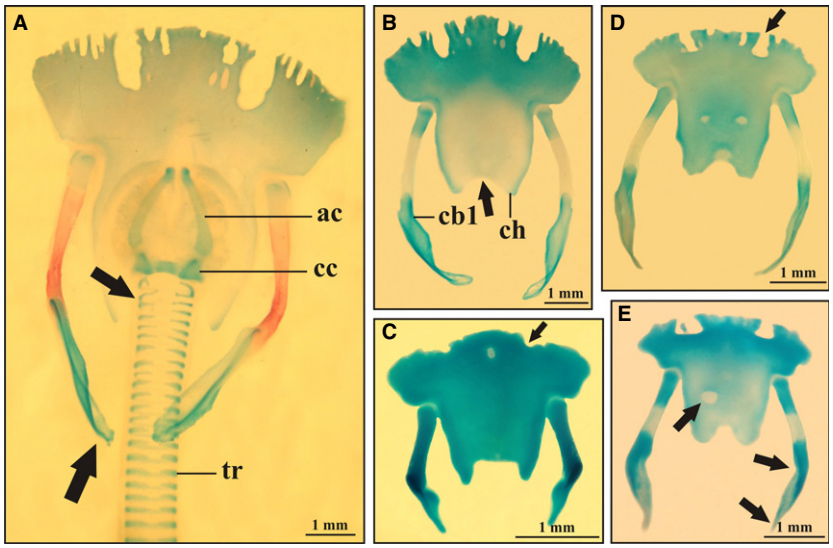

Fig. 10 Dorsal view of the hyobranchial apparatus, laryngeal cartilages and trachea of *Caiman latirostris* (MLP-R.6491) and *Caiman yacare* (MLP-R.6490). (A) CL-27-28-5; (B) CL-24-2; (C) CL-22-2; (D) CY-23-8 (D); (E) CY-22-3. Arrows: enlarged distal end of the Cornu branchiale I and bifurcation of one tracheal ring (A); wide and shallow notch (B); notch between the middle anterior end and each anterior lateral process of the Corpus hyoidei (C); notch with angular edges (D); foramen in the Corpus hyoidei and tapered distal end of the Cornu branchiale I and its medial narrowing (E). ac, arytenoid cartilages; cb1, Cornu branchiale I; cc, cricoid cartilage; ch, Corpus hyoidei; tr, trachea.

show a tongue-shaped growth that extends medially until reaching the midline at the end of the development, leading to the dorsal closure of the cricoid (Fig. 12B). The anteroventral end of the cricoid presents three anterior projections (one in the middle and two laterals) of similar length (Fig. 12C) from stage 22 onwards. From stage 23 the lateral projections of both species are longer than the middle projection (Fig. 12B).

The posteroventral surface of the cricoid cartilage presents a notch that varies between both species. In the case of *Caiman latirostris*, this notch was only observed in four embryos of stage 22 (CL-22-4, CL-22-5, CL-22-6 and CL-22-7), thereafter disappearing. Only four embryos of this species (CL-22-8, CL-22-9, CL-22-10, CL-22-11) present a trace of the mentioned notch as a midline or suture. The notch of *C. yacare* is wider and remains throughout the embryonic development (Fig. 12B).

The arytenoid cartilages of the first studied stages of both species are formed by a rod whose major axis runs anteroposteriorly to the Corpus hyoidei and whose ends are expanded (Fig. 12C); they are dorsal and slightly anterior to the cricoid. From stage 23 in *C. latirostris* and stage 22 in *C. yacare*, a projection begins to grow in the anterior end of the rod and curves anteroventrally, forming the definitive morphology of each arytenoid cartilage until the moment of hatching (Fig. 12D).

The tracheal rings are open dorsally and are placed immediately behind the cricoid cartilage without contacting it (Fig. 10A). They begin to develop in stage 22 of *C. latirostris* (observed only in CL-22-10 and CL-22-11 of this stage) and in stage 23 of *C. yacare* (except CY-23-1, CY-23-3, CY-23-4). From stage 24 on, they are already present in all embryos of both species. Some individuals of the two species have a small underdeveloped cartilaginous nodule in the ventral middle part of the first tracheal ring (Fig. 12E). The developmental sequence of the rings could be established in *C. latirostris* but not in *C. yacare*. Rings begin to develop from the ventral surface to the dorsal one in an anteroposterior direction. The tracheal rings of both species studied remain dorsally opened throughout the embryonic development (Fig. 10A). Although the rings always remain independent of each other, there are

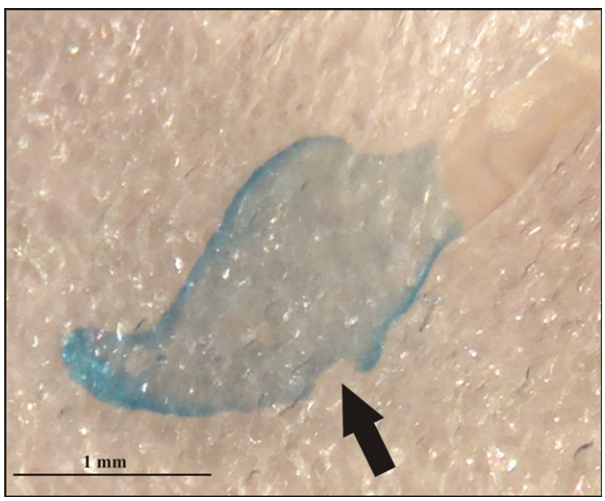

Fig. 11 Distal end of the Cornu branchiale I of *Caiman yacare* (MLP-R.6490; CY-24-3). Arrow: notch in the medial edge.

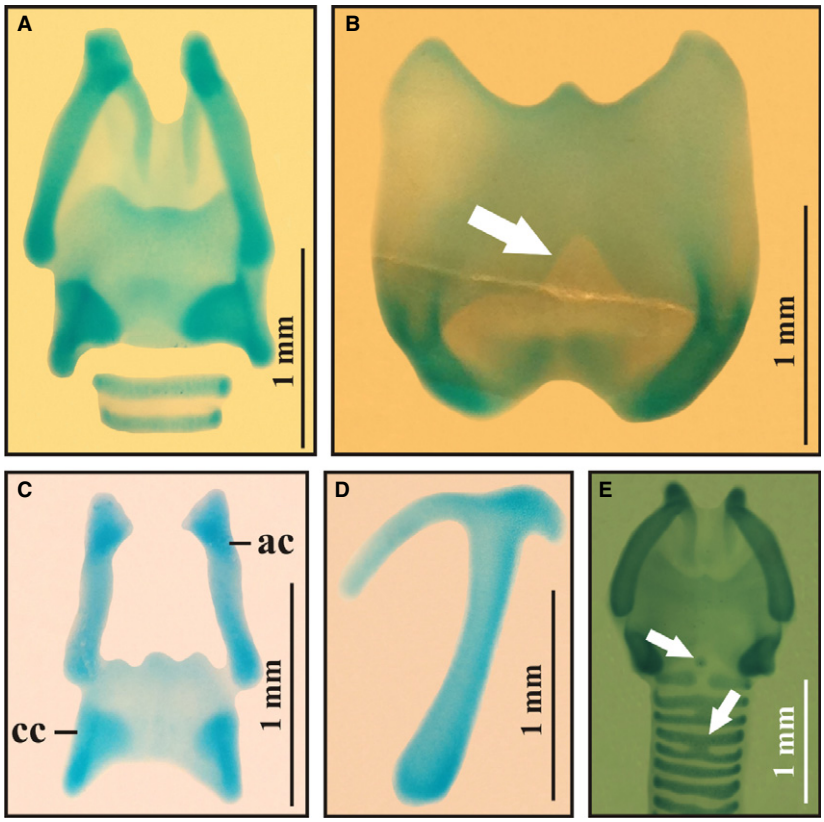

Fig. 12 Laryngeal cartilages and trachea of *Caiman latirostris* (MLP-R.6491) and *Caiman yacare* (MLP-R.6490). (A) Dorsal view of laryngeal cartilages and the first portion of the trachea of CL-23-7. (B) Dorsal view of cricoid cartilage of CY-25-3. (C) Ventral view of laryngeal cartilages of CL-22-11. (D) Lateral view of arytenoid cartilages of CL-25-1. (E) Dorsal view of laryngeal cartilages and trachea of CY-23-11. Arrows: notch in the posteroventral surface of cricoid cartilage (B); cartilaginous nodule in the ventral middle part of the first tracheal ring, and cartilaginous extension from one tracheal ring to another (E). ac, arytenoid cartilages; cc, cricoid cartilage.

individuals of both species in which some rings release a cartilaginous extension that makes contact with the consecutive ring (Fig. 12E). It was also observed that some rings bifurcate at their ends, regardless of their position in the trachea or the species (Fig. 10A).

Discussion

Neurocranium

In general terms, the cartilaginous neurocrania of *C. latirostris* and *C. yacare* are very similar to each other and to that of other crocodylian species. The only feature that varies in relation to other crocodylian species and could be considered unique within Alligatoridae is the presence of the epiphanial foramen in the ethmoid region of both caiman species. This foramen, which is dorsal to the aditus conchae, is homologous in its topological similarities with the epiphanial foramen described by Klembara (1991; Fig. 2C) and its presence differs from that in other crocodylian species because, although it is present in *Alligator mississippiensis* (Klembara, 1991) and *Caiman crocodilus* (Witmer, 1995), it does not appear in the genus *Crocodylus* (De Beer, 1937; Bellairs & Kamal, 1981; Klembara, 1991).

In the ethmoid region, a cupola anterior has been observed in this study, unlike the statement of De Beer (1937), who considers that it is absent in Crocodylia. The absence of this structure according to De Beer (1937) might be due to a different methodological background as proposed by Yaryhin & Werneburg (2017). This structure has also been described by other authors (e.g. Bellairs & Kamal, 1981; Klembara, 1991) and Klembara (1991) recognized an independent origin for it. In *C. latirostris* and *C. yacare,* its origin could not be established. Studying earlier stages may enable us to identify how the cupola anterior arises. The alar process attached to the cupola anterior is not specifically described in crocodylians by De Beer (1937), which makes sense, as there is no cupola anterior in that group. However, this process was observed in this study and by Klembara (1991) and Parker (1882). Moreover, Bellairs & Kamal (1981) described a cupola anterior but not an alar process in crocodylians.

In relation to the orbitotemporal region, at certain ontogenetic stages, the optic and epioptic fenestrae present a

different anterior extension in the two caiman species (Fig. 3C). This could be related to some ontogenetic variation and may reflect a pattern in which, in the middle of development (stages 18–22), the optic fenestra overtakes the epioptic fenestra, whereas, in previous and later stages, they extend equally. Werneburg & Yaryhin (2018) have pointed out that some structures of this region (i.e. taenia marginalis, taenia medialis) show a different degree of development in the full chondrocranium of distinct genera of Crocodylia (i.e. *Mecistops*, *Crocodylus*). It might be interesting to extend the sample to other extant species and further study the morpho-functional implications.

The infrapolar and basitrabecular processes were defined following De Beer (1937) based on a topological criterion: the part that merges with the trabeculae was considered a basitrabecular process and the one that underlies the auditory capsule, an infrapolar process. The basitrabecular process, according to De Beer (1937), is a lateral projection of the most posterior portion of the trabecular bar and is formed of the polar cartilage, when the latter element chondrifies independently. In the particular case of crocodylians, the basitrabecular process originates ventrally from the point of attachment of each trabecula to the basal plate, and is projected backwards underneath the cochlear portion of the auditory capsule, forming the infrapolar process (De Beer, 1937). Klembara (1991) also makes a distinction between both processes (basitrabecular and infrapolar) and discusses the origin and its possible homologies. In this study, only one element was distinguished, always fused to the posterior part of the trabeculae projecting posteroventrally, below the cochlear portion, so it is not possible to distinguish if only one of them (the anterior basitrabecular process) or the infrapolar process (posterior) merges with the first one.

At the level of the otic-occipital region of both species, the occipital arch is formed by a single element (Fig. 2B). However, the presence of several hypoglossal foramina would indicate that more than one occipital arch would have been involved in its constitution (De Beer, 1937). Unlike the three foramina that Klembara (1991) described in *Alligator*, the maximum number of hypoglossal foramina observed in this work was four (or probably five, see Results), which would likely indicate that at least four occipital arches were incorporated in this region. As the presence of a single pair of hypoglossal foramina is no evidence that only a single pair of occipital arches has been included in this morphological configuration (some arches fail to chondrify and are found as septa subdividing a simple foramen; see De Beer, 1937), the definitive number of arches included in the basal plate of caiman species cannot be assumed.

Regarding the tectum that joins dorsally and posteriorly to the auditory capsules in *C. latirostris* and *C. yacare*, in this study a homology is made, by topology, with the tectum synoticum. However, it cannot be ruled out that the posterior tectum could be incorporated here (see De Beer, 1937; Klembara, 1991, 2001).

Splanchnocranium

The main differences between *C. yacare* and *C. latirostris*, and other crocodylian species were recorded in the splanchnocranium. The differences from other crocodylian species have been observed specifically in the palatoquadrate, and interspecific variation within the genus was observed at the level of the hyobranchial apparatus.

Regarding the dorsal portion of the mandibular arch, there is no ascending process of the pterygoid process of the palatoquadrate in *C. latirostris* and *C. yacare*, as described for *Crocodylus* by De Beer (1937: 266, plate 93.4). Moreover, the posterior and ventral surface of the otic process of the palatoquadrate of *Caiman* is articulated with the dorsal process of the columella auris, whereas in *Crocodilus porosus* (Schneider, 1801; *sensu* De Beer, 1937; = *Crocodylus porosus*) there is a cartilaginous fusion (De Beer, 1937). The otic process is articulated with the lateral wall of the auditory capsule in both species of caiman, whereas in *Crocodilus biporcatus* (Cuvier, 1807; sensu De Beer, 1937; = *Crocodylus porosus*) it is linked by connective tissue (De Beer, 1937) or cartilaginous fusion (Edgeworth, 1935). These two last characters (articulation of the otic process of the palatoquadrate) could be distinctive of *Caiman*.

Regarding the ventral portion of the mandibular arch of the caiman species studied here, the articular fossa of Meckel's cartilage is longer than wide and is practically the same size as the retroarticular process, which is arranged almost vertically. It is interesting to note that the articular fossa is wider than it is long and the retroarticular process, almost horizontal, is bigger than the articular fossa in adult specimens of *C. latirostris* and *C. yacare*. This is a remarkable ontogenetic shift that scientists should consider before embarking on any phylogenetic analysis.

The main differences between species were found in the ventral portion of the hyoid arch and branchial arches: the anterior notch of the Corpus hyoidei is more rounded in *C. latirostris* than in *C. yacare*; the anterior contour of the Corpus hyoidei is curved in *C. latirostris* and in the first stages of *C. yacare*, and flat in the remaining *C. yacare* specimens; the posterior notch of the Corpus hyoidei is wider and less deep in *C. latirostris*; most specimens of *C. yacare* have foramina in the Corpus hyoidei, which are variable in position and number (few individuals of *C. latirostris* have a single foramen, middle and anterior); the distal end of the Cornu branchiale I is tapered in most specimens of *C. yacare* and presents different degrees of broadening in *C. latirostris*. These differences could become apomorphies of each species.

Regarding the homologies of the elements of the hyobranchial apparatus, no independent origin of either the anterior processes (middle and lateral) or the posterior lateral processes of the Corpus hyoidei in any of the two species studied has been distinguished. A separate epibranchial associated with the Cornu branchiale I has not been

distinguished either. Consequently, none of the homologies of the structures belonging to the hyobranchial apparatus described below could be corroborated. Eventually, by studying stages previous to those analyzed in this work, these homologies might be confirmed. The Corpus hyoidei would apparently correspond to the basihyal, perhaps fused with the first basibranchial according to De Beer (1937), to the basihyobranchial of Parker (1882) or to the basihyal/basihyoid/hypobranchial of Schumacher (1973). The middle anterior end of the Corpus hyoidei was described as a lingual process by several authors (Shiino, 1914; De Beer, 1937; Romer, 1956; Bellairs & Kamal, 1981). Schumacher (1973) did not specifically describe this process in crocodylians, though he did so for turtles. Klembara (1991) also described this middle anterior projecting part as a lingual process and suggested it might correspond to the basihyal in terms of position. He also proposed that the hypobranchial 1 and 2 would contribute to the posterior area of the middle anterior process and the basibranchial 1 and 2 would contribute to the Corpus hyoidei itself. Cleuren & De Vree (1992) said that there is no lingual process in crocodylians. According to De Beer (1937), each anterior lateral process of the Corpus hyoidei is fused with the corresponding Cornu branchiale (ceratohyal). Romer (1956) and Bellairs & Kamal (1981) also considered that the ceratohyal is incorporated into the Corpus hyoidei in crocodylians; however, they added that it virtually disappears in the adult specimens. Schumacher (1973) mentions similar processes (per position) but in turtles he calls them anterior lateral processes. Shiino (1914) also mentions a Cornu hyale assimilated into the Corpus hyoidei, and Klembara (1991) argues that (by position) the hypohyal would represent this Cornu hyale. Regarding the posterior lateral processes of the Corpus hyoidei, the Cornua branchialia II are represented by these posterior processes according to Shiino (1914) and Fürbringer (1922). De Beer (1937), Romer (1956) and Klembara (1991) agree with the latter and explain that these processes would be the ceratobranchialia II. Bellairs & Kamal (1981) also agree with this last idea and clarify that Cornua branchialia II would virtually disappear in the adult. On the other hand, Cleuren & De Vree (1992) claim that the Cornua branchialia II have been fused or lost. Schumacher (1973) finds some similarity to the rudimentary Cornua branchialia II of lacertilians, but he did not describe them for crocodylians. Schumacher (1973) also mentions posterior processes in turtles similar in position to crocodylians and calls them posterior lateral processes. Cornu branchiale I would correspond to ceratobranchial I according to Parker (1882), De Beer (1937), Romer (1956), Schumacher (1973), Bellairs & Kamal (1981) and Klembara (1991). Shiino (1914) describes Cornu branchiale I but he did not mention anything regarding its homology. According to Schumacher (1973), in young embryos, these Cornua branchialia I are connected with the Corpus hyoidei. This last statement could not be corroborated in this study since they were always observed as separate elements. Moreover, this author identified the free end of the Cornu branchiale I as an epibranchial. Bellairs & Kamal (1981) also suggest the presence of an epibranchial cartilage at the tip of the Cornu branchiale I. In this work, no distinct cartilage was observed at the distal end of the Cornu branchiale I. In conclusion, all the above-mentioned hypotheses of homology of the hyobranchial apparatus are equally likely and none deserves more support than other (Table 2).

Larynx and trachea

In relation to the larynx of *C. latirostris* and *C. yacare*, two laryngeal cartilages have been distinguished which, according to structure and position, were identified as cricoid (odd and ventral) and arytenoid (paired and dorsal) cartilages. The variation of these structures between species occurred specifically in the cricoid cartilage. The posteroventral surface of this cartilage presented a notch that was observed in only four embryos of *C. latirostris* of stage 22 and then disappeared (only four embryos with a trace of

Table 2 Summary of proposed homologies for the hyobranchial apparatus.

References	Corpus hyoidei	Middle anterior process	Anterior lateral process	Posterior lateral processes	Cornu branchiale I
De Beer (1937)	Basihyal + (probably) first basibranchial	Lingual process	Ceratohyal	Ceratobranchial II	Ceratobranchial I
Parker (1882)	Basihyobranchial	–	–	–	Ceratobranchial I
Schumacher (1973)	Basihyal/basihyoid/ hypobranchial	–	–	–	Ceratobranchial I + epibranchial
Shiino (1914)	–	Lingual process	Cornu hyale	Cornu branchiale II	Cornu branchiale I
Romer (1956)	–	Lingual process	Ceratohyal	Ceratobranchial II	Ceratobranchial I
Bellairs & Kamal (1981)	–	Lingual process	Ceratohyal	Ceratobranchial II	Ceratobranchial I + epibranchial
Klembara (1991)	Hypobranchial 1 and 2 or Basibranchial 1 and 2	Lingual process (= Basihyal)	Cornu hyale (= Hypohyal)	Ceratobranchial II	Ceratobranchial I

the cited notch). In contrast, the notch in *C. yacare* was broad and continues so throughout embryonic development. This constitutes a good feature to be included in phylogenetic systematics for characterizing and distinguishing between the two caiman species.

Santos et al. (2011) say that in some species of reptiles the trachea consists of incomplete cartilaginous rings. Their statement agrees with our observations in this work. Moreover, Santos et al. (2011) studied adult specimens of *C. latirostris* and detected the same pattern as here. Supporting this idea, Di Pietro et al. (2014) and Kuehne & Junqueira (2000) detected the same pattern in adult specimens of serpents and amphibians, respectively. In contrast, it seems that in post-hatching *Alligator* (Reese, 1915; Lafortune et al. 2005) and some birds (Çevik-Demirkan et al. 2007), the cartilaginous rings are closed.

Conclusions

The main differences in the chondrocranium between *C. yacare* and *C. latirostris,* and other crocodylian species were recorded in the splanchnocranium. Differences with other crocodylian species have been observed in the palatoquadrate, and interspecific variation within the genus was observed at the level of the hyobranchial apparatus and larynx. Some of these characters could be distinctive of *Caiman*, its two extant species or even Alligatoridae. The variation found in this study is useful to give us an idea about the phylogenetic constraints, and they could be studied in a heterochronic context in comparison with other crocodylian species. The incorporation of earlier embryonic stages would be useful to discern the homologies of the hyobranchial apparatus and the basitrabecular and infrapolar processes that remained undiscovered in this work. Moreover, the enlargement of the sample to other populations would help determine whether the singular foramina found in the Corpus hyoidei constitute a random presence or a general pattern of these species, with some underlying explanation. The post-hatching ontogenetic shift in the proportions and relative position of the articular fossa and the retroarticular process, and the ecological and biomechanical implications will be evaluated in a future morphofunctional study of the mandible.

Acknowledgements

This work is part of my PhD Thesis. I would first like to express my gratitude to my directors of my dissertation, Paula Bona (P.B.) and Leandro Alcalde, who supervised me during that process. I specially want to thank P.B. who also provided me invaluable assistance with this manuscript. I would like to express my gratitude to the people of 'Estancia El Cachapé', in Chaco province, who collaborated with the field trips. I am grateful to Marcela Tomeo, Martín D. Ezcurra and Alejandro Otero for helping me with the graphical section. I thank those people in the Instituto de Limnología 'Dr. Raúl A. Ringuelet', in La Plata city, who allowed me to develop part of this work there and sustained me. I appreciate the work of the Dirección de Fauna y Áreas Naturales Protegidas de la provincia del Chaco, which gave me permission to work in the area. Finally, I want to acknowledge the helpful comments of the reviewer Ingmar Werneburg and the editorial work of Anthony Graham. This research was funded by grants from the National Agency for Scientific and Technological Promotion (PICT 2016 N° 0159) and the Council National Scientific and Technical Research (PIP 112201301-00733).

References

Bellairs ADA, Kamal AM (1981) The chondrocranium and the development of the skull in recent reptiles. In: *Biology of the Reptilia*. (eds Gans C, Parsons TS), pp. 1–264. London: Academic Press.

Bona P, Ezcurra M, Barrios F, et al. (2018) A new Palaeocene crocodylian from southern Argentina sheds light on the early history of caimanines. *Proc R Soc B* **285**, 20180843.

Brochu CA (2011) Phylogenetic relationships of *Necrosuchus ionensis* Simpson, 1937 and the early history of caimanines. *Zool J Linn Soc* **163**, S228–S256.

Çevik-Demirkan A, Haziroğlu RM, Kürtül I (2007) Gross morphological and histological features of larynx, trachea and syrinx in Japanese quail. *Anat Histol Embryol* **36**, 215–219.

Clarke SF (1891) The habits and embryology of the American alligator. *J Morphol* **5**, 181–214.

Cleuren J, De Vree F (1992) Kinematics of the jaw and hyolingual apparatus during feeding in *Caiman crocodilus*. *J Morphol* **212**, 141–154.

Cuvier GL (1807) Sur les différentes espèces de crocodiles vivans et sur leurs caractères distinctifs. *Ann du Mus Hist Nat Paris* **10**, 8–66.

Daudin FM (1802) *Histoire Naturelle, Générale et Particulière des Reptiles. 2nd edn.*, p. 452. Paris: F Dufart.

De Beer GR (1937) *The Development of the Vertebrate Skull*, p. 555. Chicago: The University of Chicago Press.

Di Pietro DO, Alcalde L, Williams JD (2014) Nasal cartilages, hyobranchial apparatus, larynx, and glottal tubes in four species of Hydropsini (Serpentes: Dipsadidae: Xenodontinae). *Vertebr Zool* **64**, 103–111.

Edgeworth FH (1935) *The Cranial Muscles of Vertebrates*, p. 493. Cambridge: University Press.

Ferguson MWJ (1987) Post-laying stages of embryonic development for crocodilians. In: *Wildlife Management: Crocodiles and Alligators*. (eds Webb GJW, Manolis SC, Whitehead PJ), pp. 427–444. Sydney: Surrey Beatty and Sons Pty Ltd, in association with the Conservation Commission of the Northern Territory.

Fürbringer M (1922) Das Zungenbein der Wirbeltiere, insbesondere der Reptilien und Vögel. *Abh Heidelb Akad Wiss Math Nat Kl B* **11**, 1–164.

Goldby F (1925) The development of the columella auris in the Crocodilia. *J Anat* **59**, 301–325.

Göppert E (1900) Der Kehlkopf der Amphibien und Reptilian. *Morph Jb* **28**, 1–27.

Hastings AK, Bloch JI, Jaramillo CA, et al. (2013) Systematics and biogeography of crocodylians from the Miocene of Panama. *J Vertebr Paleontol* **33**, 239–263.

Iordansky NN (1973) The skull of the Crocodilia. In: *Biology of the Reptilia*. (eds Gans C, Parsons TS), pp. 201–260. London: Academic Press.

Iungman J, Piña CI, Siroski P (2008) Embryological development of *C. latirostris* (Crocodylia: Alligatoridae). *Genesis* **46**, 401–417.

Klembara J (1991) The cranial anatomy of early ontogenetic stages of *Alligator mississippiensis* (Daudin, 1802) and the significance of some of its cranial structures for the evolution of tetrapods. *Palaeontogr Abt* **215**, 103–171.

Klembara J (1993) The parasphenoid and associated dermal structures of the parabasisphenoid of *Alligator mississippiensis* (Daudin, 1802). *Palaeontogr Abt* **228**, 143–164.

Klembara J (2001) Postparietal and prehatching ontogeny of the supraoccipital in *Alligator mississippiensis* (Archosauria, Crocodylia). *J Morphol* **249**, 147–153.

Klembara J (2005) Ontogeny of the partial secondary wall of the otoccipital region of the endocranium in prehatching *Alligator mississippiensis* (Archosauria, Crocodylia). *J Morphol* **266**, 319–330.

Kuehne B, Junqueira LCU (2000) Histology of the trachea and lung of *Siphonops annulatus* (Amphibia, Gymnophiona). *Rev Bras Biol* **60**, 167–172.

Lafortune M, Göbel T, Jacobson E, et al. (2005) Respiratory bronchoscopy of subadult American alligators (*Alligator mississippiensis*) and tracheal wash evaluation. *J Zoo Wildl Med* **36**, 12–20.

Magnusson WE, Taylor JA (1980) A description of developmental stages in *Crocodylus porosus*, for use in aging eggs in the field. *Aust Wildlife Res* **7**, 479–485.

Meek A (1893) On the occurrence of a Jacobson's organ, with notes on development of nasal cavity, lachrymal duct, and harderian gland in *Crocodilus porosus*. *J Anat Physiol* **27**, 151–160.

Meek A (1911) On the morphogenesis of the head of the crocodile (*Crocodilus porosus*). *J Anat Physiol* **45**, 357–377.

Miall LC (1878) *The Skull of the Crocodile. A Manual for Students. Studies in Comparative Anatomy I*, p. 50. London: Macmillan.

Müller F (1965) Zur Morphogenese des Ductus nasopharyngeus und des sekundaren Gaumendaches bei den Crocodilia. *Rev Suisse Zool* **72**, 647–652.

Müller F (1967) Zur embryonalen Kopfentwicklung von *Crocodylus cataphractus* Cuvier. *Rev Suisse Zool* **74**, 189–294.

Parker WK (1882) On the structure and development of the skull in the Crocodilia. *Trans Zool Soc Lond* **11**, 263–310.

Peterka M, Sire JY, Hovorakova M, et al. (2010) Prenatal development of *Crocodylus niloticus niloticus* Laurenti, 1768. *J Exp Zool Part B* **314**, 353–368.

Pol D, Leardi JM, Lecuona A, et al. (2012) Postcranial anatomy of *Sebecus icaeorhinus* (Crocodyliformes, Sebecidae) from the Eocene of Patagonia. *J Vertebr Paleontol* **32**, 328–354.

Reese AM (1915) *The Alligator and its Allies*, p. 358. New York: GP Putnam and Sons.

Rieppel O, Zaher H (2001) The development of the skull in *Acrochordus granulatus* (Schneider) (Reptilia: Serpentes), with special consideration of the otico-occipital complex. *J Morphol* **249**, 252–266.

Romer AS (1956) *Osteology of the Reptiles*, p. 772. Chicago: The University of Chicago Press.

Salas-Gismondi R, Flynn J, Baby P, et al. (2015) A Miocene hyperdiverse crocodylian community reveals peculiar trophic dynamics in proto-Amazonian mega-wetlands. *Proc R Soc B* **282**, 20142490.

Salas-Gismondi R, Flynn J, Baby P, et al. (2016) A new 13 Million year old gavialoid crocodylian from proto-Amazonian mega-wetlands reveals parallel evolutionary trends in skull shape linked to longirostry. *PLoS One* **11**, e0152453.

Santos CM, Abidu-Figueiredo M, Teixeira MJ, et al. (2011) Light microscopic and immunohistochemical study of the trachea of the broad-snouted caiman (*Caiman latirostris*). *Vet Med* **56**, 48–54.

Schneider JG (1801) *Historiae Amphibiorun Naturalis et Literariae. Fasciculis Secundus*: Continens Crococodilos, Scincos, Chamaesauras, Boas, Pseudoboas, Elapes, Angues, Arnphisbaenas et Caecilias, p. 374. Jena: Friedrich Frommann.

Schumacher GH (1973) The head muscles and hyolaryngeal skeleton of turtles and crocodilians. In: *Biology of the Reptilia*. (eds Gans C, Parsons TS), pp. 101–200. London: Academic Press.

Shiino K (1914) Studien zur Kenntnis des Wirbeltierkopfes. *Anat Embryol* **50**, 253–382.

Spix JB (1825) *Animalia Nova Sive Species Novae Lacertarum Quas in Itinere per Brasiliam Annis MDCCCXVII–MDCCCXX Jussu et Auspiciis Maximiliani Josephi I. Bavariae Regis Suscepto Collegit et Descripsit Dr. J. B. de Spix*, p. 26. Monachii: Typis Franc. Seraph. Hübschmanni.

Taylor WR, Van Dyke GC (1985) Revised procedures for staining and clearing small fishes and other vertebrates for bone and cartilage study. *Cybium* **9**, 107–120.

Vieira LG, Santos ALQ, Hirano LQL, et al. (2018) Ontogeny of the skull of the Black Caiman (Melanosuchus niger) (Crocodylia: Alligatoridae). *Can J Zool* **97**, 142–155.

Voeltzkow A (1899) Beitrage zur Entwicklungsgeschichte der Reptilien. 1. Biologie und Entwicklung der ausseren Korperform von *Crocodilus madagascariensis*. *Abhandl Senckenb Naturf Ges* **26**, 1–150.

Werneburg I, Yaryhin O (2018) Character definition and tempus optimum in comparative chondrocranial research. *Acta Zool* 1–13. https://doi.org/10.1111/azo.12260.

Witmer LM (1995) Homology of facial structures in extant archosaurs (birds and crocodilians), with special reference to paranasal pneumaticity and nasal conchae. *J Morphol* **225**, 269–327.

Yaryhin O, Werneburg I (2017) Chondrification and character identification in the skull exemplified for the basicranial anatomy of early squamate embryos. *J Exp Zool Part B* **328**, 476–488.