



Comparative Anatomy of the Forearm and Hand of Wildcat (*Leopardus geoffroyi*), Ocelot (*Leopardus pardalis*) and Jaguar (*Panthera onca*)

H. L. Sánchez¹ M. E. Rafasquino¹ E. L. Portiansky²

¹Institute of Anatomy, Facultad de Ciencias Veterinarias, Universidad Nacional de la Plata, La Plata, Argentina

²Image Analysis Laboratory, Facultad de Ciencias Veterinarias, Universidad Nacional de la Plata, La Plata, Argentina

Address for correspondence Mg. HL. Sánchez, Instituto de Anatomía, Facultad de Ciencias Veterinarias, Universidad Nacional de la Plata, Calle 60 y 118, s/n°, CP 1900, CC296, La Plata, Argentina (e-mail: lilianasanchez@fcv.unlp.edu.ar).

J Morphol Sci 2019;36:7–13.

Abstract

Introduction The thoracic limbs of cats facilitate jumping and represent one of their main ways for pursuing and capturing prey. The main muscles and nerves involved in these activities are present in the region of the forearm and of the hand. The scant anatomical reference available on South American cats species justifies the present comparative study.

Materials and Methods The forelimbs of wildcat, ocelot and jaguar wild felines were fixed. Images of the dissected limbs were captured using a digital camera. Measurements were made using a caliper.

Results The long and short heads of the extensor carpi radialis muscle of the ocelot and of the jaguar showed a great development in comparison with those of the wildcat. The flexor digitorum profundus muscle in the three felines is formed by five heads. In the jaguar, the radial or deep head presented two sesamoid bones. The brachioradialis muscle of the jaguar and of the ocelot is inserted medially at the distal end of the radius and at the proximal row of the carpus by a thick and flattened tendon. The pronator teres muscle of the jaguar extended to the carpal region. In the wildcat and in the ocelot, this muscle was less developed.

Conclusions The main variations observed between the forearms and the hands of these South American cats were found between the supinator and the pronator muscles, presenting a variation in the size of their bellies and tendons. Our study of the muscular characteristics represents a contribution to the homologies and differences of the forearm and hand muscles of each of these species of felines.

Keywords

- ▶ South American felines
- ▶ felines
- ▶ forearm muscles
- ▶ hand muscles
- ▶ jaguar
- ▶ ocelot
- ▶ wildcat

Introduction

Argentina is the only country in the American continent that has all the species of felines present in South America. With the exception of the red lynx (*Lynx rufus*) and of the Canada lynx (*Lynx canadensis*), which only inhabit North America, the remaining 10 species that inhabit the continent have part of their distribution in Argentina. However, very little is

known about most of these autochthonous species. From the jaguar (*Panthera onca*) to the wildcat (*Leopardus geoffroyi*), the largest and the smallest of the American felines, respectively, all of the South American wild cats are almost unknown to science.¹ Currently, most of these native felines are protected in Argentina. However, the deep ignorance that exists about their anatomy could hinder actions tending to

received
August 30, 2018
accepted
January 6, 2019
published online
March 7, 2019

DOI <https://doi.org/10.1055/s-0039-1681016>.
ISSN 2177-0298.

Copyright © 2019 by Thieme Revinter Publicações Ltda, Rio de Janeiro, Brazil

License terms



their effective preservation and management in the areas destined to their preservation.²

For a long time, the domestic cat has been the biological model used for the study of different feline species, mainly due to the greater availability of specimens. The lower availability of material from the other species significantly limits their study.³ From the agreement of collaboration maintained by the Facultad de Ciencias Veterinarias of the Universidad Nacional de la Plata with the zoo of the municipality of La Plata, which cedes the dead specimens to our Instituto de Anatomía, we began to study the locomotor apparatus and the peripheral nervous system of the jaguar and of the puma.^{4,5}

Although some aspects related to ecology, reproduction and nutrition are known, there is not much information related to the anatomy of these autochthonous species, especially to their locomotor system. The description of the muscles of these feline species is particularly useful for phylogenetic studies.⁶ Comparative studies of these taxa and homologies show the evolution of their muscles, as well as a very careful review and clarification of the nomenclature used based on the *Nomina Anatomica Veterinaria*.^{7,8}

Knowledge about the anatomical region of the forearm and of the hand is of high importance to understand the hunting and movement habits of these animals.⁹ Thus, some species of felines, such as the serval (*Leptailurus serval*), have developed long and thin thoracic limbs, to which is added the great development of auricular pavilions, which they use to detect the prey in tall grass.^{5,10} In contrast, other species of felines, such as the jaguar, have developed shorter thoracic limbs, with well-developed arms and forearms that allow them to grab the prey strongly.¹¹

The lack of knowledge about the muscles of the forearm and of the hand of these felines poses difficulties for the discussion not only of their morphology, but also of their function and of the evolution of these native felines. The objective of the present study was to carry out a descriptive analysis of the forearm and hand muscles of wildcats, ocelots and jaguars and to compare them with the data recorded for the domestic cat. Likewise, the accuracy of the homologies, as well as of the nomenclature used among these feline species for the description of the muscles, was critically examined and discussed.

Materials and Methods

Muscles of the right and left thoracic limbs of 1 adult male jaguar (body weight [BW]: 78 kg) and of 1 young female ocelot (BW: 7 kg) that died of natural causes in the zoo of the municipality of La Plata were dissected. A total of 3 wildcats, 1 young female (BW: 3 kg) and 2 adult males (BWs between 3.6 and 4 Kg), found dead in the field or on the route of Mount Berisso, in the province of Buenos Aires, were also used.

The animals were frozen and stored in the Instituto de Anatomía of the Facultad de Ciencias Veterinarias of the Universidad Nacional de la Plata. They were then fixed with a fixing solution composed of 10% formaldehyde, 1 L of carbolic acid, 1 L of glycerin, and 5 g of thymol. The common

carotid arteries were channeled, and an amount of fixative liquid equivalent to 10% of the BW of each animal was injected. At each stage of the dissection, the muscles were photographed with a Sony Cyber-Shot DSC-P10 digital camera (Sony Corporation, Tokyo, Japan). The Adobe Photoshop CS6 software (Adobe Inc., San Jose, CA, USA) was used to process the images.

The following variables were analyzed: presence of muscles, length of the muscles, length of the muscular bellies, length of the tendons from their origin to their insertion, and some morphological variations of the muscles were compared between the three studied feline species. The measurements were made using a 300 mm Vernier caliper (200 mm, Isard, China).

Results

The extensor carpi radialis muscle of the ocelot and of the jaguar showed a great development of the long and short heads, compared with that of the wildcat. Both muscular bellies originated in the lateral supracondylar ridge, distal to the humerus bone. The long head was inserted into the dorsal surface of the second metacarpal, and the short head at the base of the third metacarpal (►Fig. 1A, 2A). The extensor digitorum communis muscle of the three species was formed by two bellies: medial and lateral. However, the lateral digital extensor muscle of the jaguar had only one belly, whereas in the wildcat and in the ocelot, it was clearly divided into two bellies, of which the medial belly was divided again into two tendons (►Fig. 3A, C). The abductor digiti longus muscle of the first finger showed a more proximal origin in the jaguar and in the ocelot than in the wildcat. It originated along the entire length of the lateral edge of the ulna, in the proximal two thirds of the radius and in the interosseous membrane of the forearm. In the jaguar and in the ocelot, the extensor digiti I and the extensor digiti II muscles originated in the proximal third of the diaphysis of the ulna and were divided into two bellies. The belly of finger I was continued with two tendons, which then fused, forming an expansion in its insertion in the distal phalanx. The belly of finger II had a single tendon, which fused with the tendon of the extensor digitorum lateralis muscle of finger II (►Fig. 2B).

The flexor muscles showed no relevant differences between the felines studied. The palmaris longus muscle of the ocelot and of the jaguar, located medial to the forearm, ended in five tendons, while in the wildcat it was divided into four tendons (►Fig. 1B, 3B). In the three wild species, they ended up attached to the tendons of the flexor digitorum superficialis muscle in the proximal extremity of the middle phalanx.

In the three South American felines, the flexor digitorum superficialis muscle was formed by two heads: one ulnar and one radial, which united to form a common belly. Particularly in the jaguar, this muscle formed a thick and flattened muscular belly that later became divided into four tendons, one for each finger (►Fig. 1B).

In felines, the flexor digitorum profundus muscle has five heads (►Fig. 1B, 3B); the first head, or superficial head, is the ulnar. The second, third and fourth heads originate from the

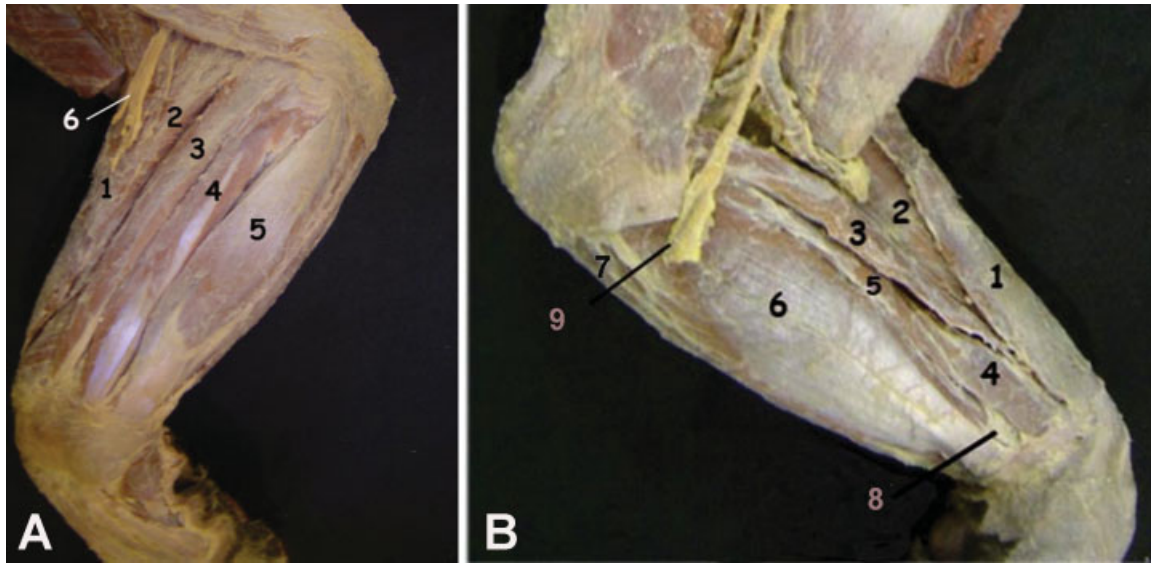


Fig. 1 (A) Lateral view of the forearm and of the hand of the jaguar. 1. Brachioradialis muscle. 2. Extensor carpi radialis muscle. 3. Extensor digitorum communis muscle. 4. Extensor digitorum lateralis. 5. Extensor carpi ulnaris muscle. 6. Radial nerve. (B) Medial view of the forearm and of the hand of the jaguar. 1. Brachioradialis muscle. 2. Extensor carpi radialis muscle. 3. Pronator teres muscle. 4. Flexor carpi radialis muscle. 5. Palmaris longus muscle. 6. Flexor digitorum superficialis muscle. 7. Flexor carpi ulnaris muscle. 8. Median nerve.

humerus, completely separated and located in a median plane. Finally, the radial or deep head originates from the distal middle third of the radius and of the ulna. In the jaguar, this muscular belly had two sesamoid bones. The second head (humeral) formed the tendon of finger I, while the remaining four heads formed the tendons of fingers II to V. Each tendon descended through the proximal annular ligament. The tendons of fingers II to V continued distally through the distal annular ligament to insert on the palmar side of the distal phalanx (►Fig. 2B, 3A).

In the jaguar, a great development of the supinator and pronator muscles was observed (►Table 1) (►Fig. 1A). However, they were less bulky in the ocelot and in the wildcat (►Table 1). The brachioradialis muscle, located under the superficial fascia of the forearm, showed a very developed fleshy belly in the jaguar and in the ocelot, in comparison with that of the wildcat (►Fig. 2A, 3A). This muscle had an origin in the proximal third of the caudal surface of the humerus and covered the cranial muscles of the forearm, and then inserted medially at the distal end of the radius and at the proximal row of the carpus by a thick and flattened tendon (►Fig. 1A).

Beneath the extensor muscles, the supinator muscle was located. In the jaguar, this muscle was formed by a flat muscular belly that spiraled around the proximal end of the radius. At its origin, it presented a short tendon starting from the lateral side of the annular ligament of the radius and from the radial collateral ligament to insert on the cranial surface of the distal third of the radius. In the ocelot and in the wildcat, this muscle was less bulky and ended with a tendon on the cranial surface of the middle third of the radius (►Fig. 4A).

The pronator teres muscle of the jaguar originated through a thick tendon starting from the medial epicondyle of the humerus, to end up being inserted in the cranial face of

the distal end of the radius. Then, it extended to the carpal region, where it fused with the flexor retinaculum (►Fig. 1B, 4B) muscle. In the wildcat and in the ocelot, this muscle was less developed (►Table 1) and inserted into the medial border of the proximal third of the radius (►Fig. 2A, 3D, 4B).

The pronator quadratus muscle was in a deeper plane. It originated at the flexor surface of the ulna and in the interosseous membrane. Its very fleshy fibers passed obliquely and distally to be inserted in the caudal surface of the radius. In the jaguar and in the ocelot, this muscle was covered by a thick tendon blade.

Discussion

The myology of the forearm and of the hand of felines was described only for the domestic cat (*Felis catus*) and for the lion (*Panthera leo*).¹² There are some studies performed on the cheetah (*Acinonyx jubatus*) and on the puma (*Puma concolor*), but the descriptions are brief and lack morphological details.^{9,13} On the other hand, the description of the muscles of the domestic cat and of the lion are much more extensive, with many well-illustrated and detailed dissections.^{12,14,15}

During the evolution of mammals, the supinator and pronator muscles became vestigial or disappeared, as their movement capacity was reduced or lost. Among cats, however, these movements are feasible and very broad, with a pronation of 40° and a supination of 50°.¹⁶ These movements are possible due to the great development of the brachioradialis muscle, which performs the external rotation and the supination of the forearm and of the hand.¹⁷⁻¹⁹ In felines, the movement of supination is necessary to capture, manipulate and exhaust the prey.²⁰ The muscles of the forearm are better developed in wild cats compared with what is described for

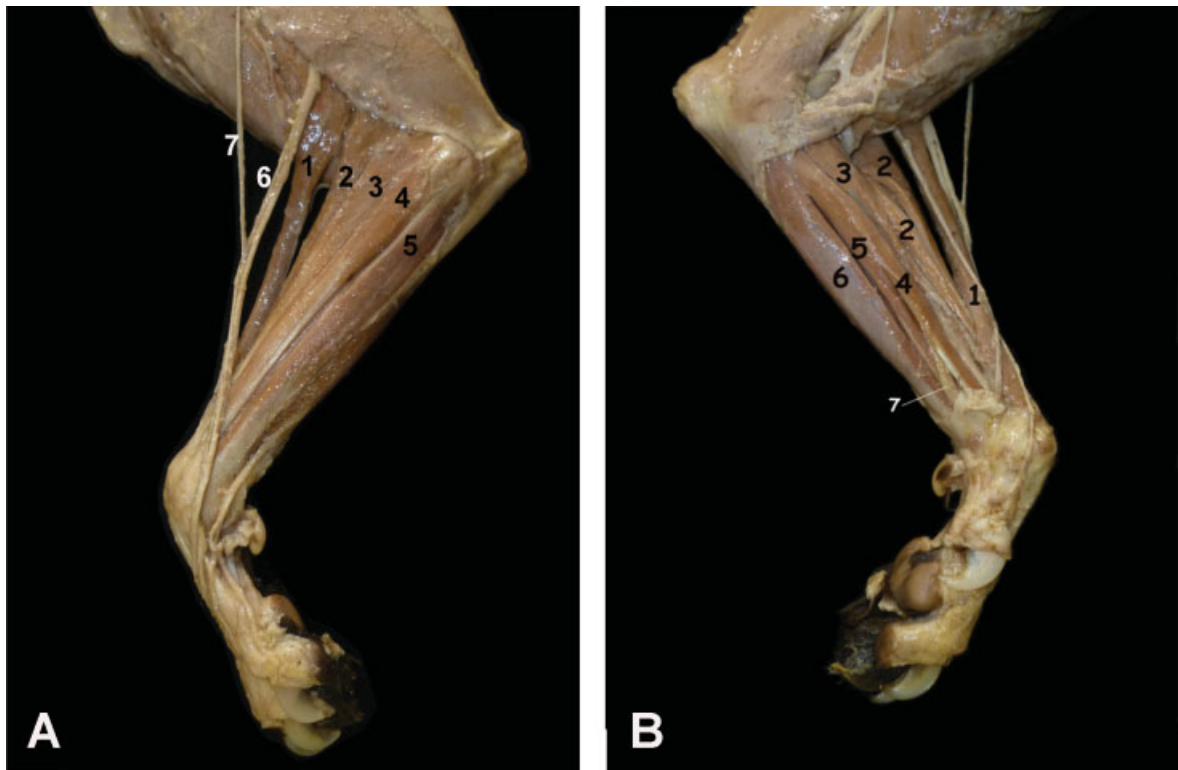


Fig. 2 (A) Lateral view of the forearm and of the hand of the ocelot. 1. Brachioradialis muscle. 2. Extensor carpi radialis muscle. 3. Extensor digitorum communis muscle. 4. Extensor digitorum lateralis muscle. 5. Extensor carpi ulnaris muscle. 6. Surface branch of the radial nerve. 7. Lateral and medial branches of the superficial branch of the radial nerve. 8. Cephalic vein. (B) Medial view of the forearm and of the hand of the ocelot. 1. Brachioradialis muscle. 2. Extensor carpi radialis muscle. 3. Pronator teres muscle. 4. Flexor carpi radialis muscle. 5. Palmaris longus muscle. 6. Flexor digitorum superficialis muscle. 7. Median nerve.

the domestic cat.^{4,14} This seems to be related to the size of the prey and to the adaptation these cats have to hunt in the water or in heights and alone, not in a herd.

The greatest differences were found in the extensor muscles of the carpus and of the fingers, probably because with the distal portion of the thoracic limb rotation, supination and pronation movements are performed with greater amplitude.²¹ However, this observation is unlikely to explain the variation in the number of bellies or tendons of the forearm and hand muscles.

It has been described that the extensor digitorum lateralis muscle of the ocelot has three muscular bellies, while the extensor digitorum communis muscle is formed by four muscular bellies.²² This differs from what we have described in our dissections, in which a division of two muscular bellies in both muscles was observed. The same authors described that, in the ocelot, the long palmar muscle terminated in four

tendons.²² Nevertheless, according to our observations, the termination of the palmaris longus muscle is divided into five tendons in the ocelot and in the jaguar, and into four tendons in the wildcat.

The division of the number of tendons to the fingers is related to the degree of movement of the digits.²³ These muscular characteristics are consistent with the behavior of each species during the hunting of its prey,²⁴ both in the distances they travel and in the size of the different preys.

For authors describe the palmaris longus muscle is not present in the puma, but it is part of the flexor digitorum superficialis.⁹ However, had already described this muscle for the domestic cat separated from the flexor digitorum superficialis,¹⁴ as we have observed in our dissections in the three feline species studied. However, their tendons in the distal extremity of the middle phalanx ended up attached to the tendons of the flexor digitorum superficialis muscle.

Table 1 Comparative measurements of the brachioradialis, supinator, and pronator muscles

Species	Brachioradialis muscle			Supinator muscle			Pronator teres muscle		
	L	W	T	L	W	T	L	W	T
Jaguar	21	0.5	0.4	14	1.5	1.2	14.5	1.8	2.5
Ocelot	10	1	0.2	8	0.8	0.5	7	1.2	0.5
Wildcat	8	1	0.2	5	0.5	0.2	6	1	0.5

Measurements are expressed in cm.
Abbreviations: L, Length; W, Width; T, Thickness.

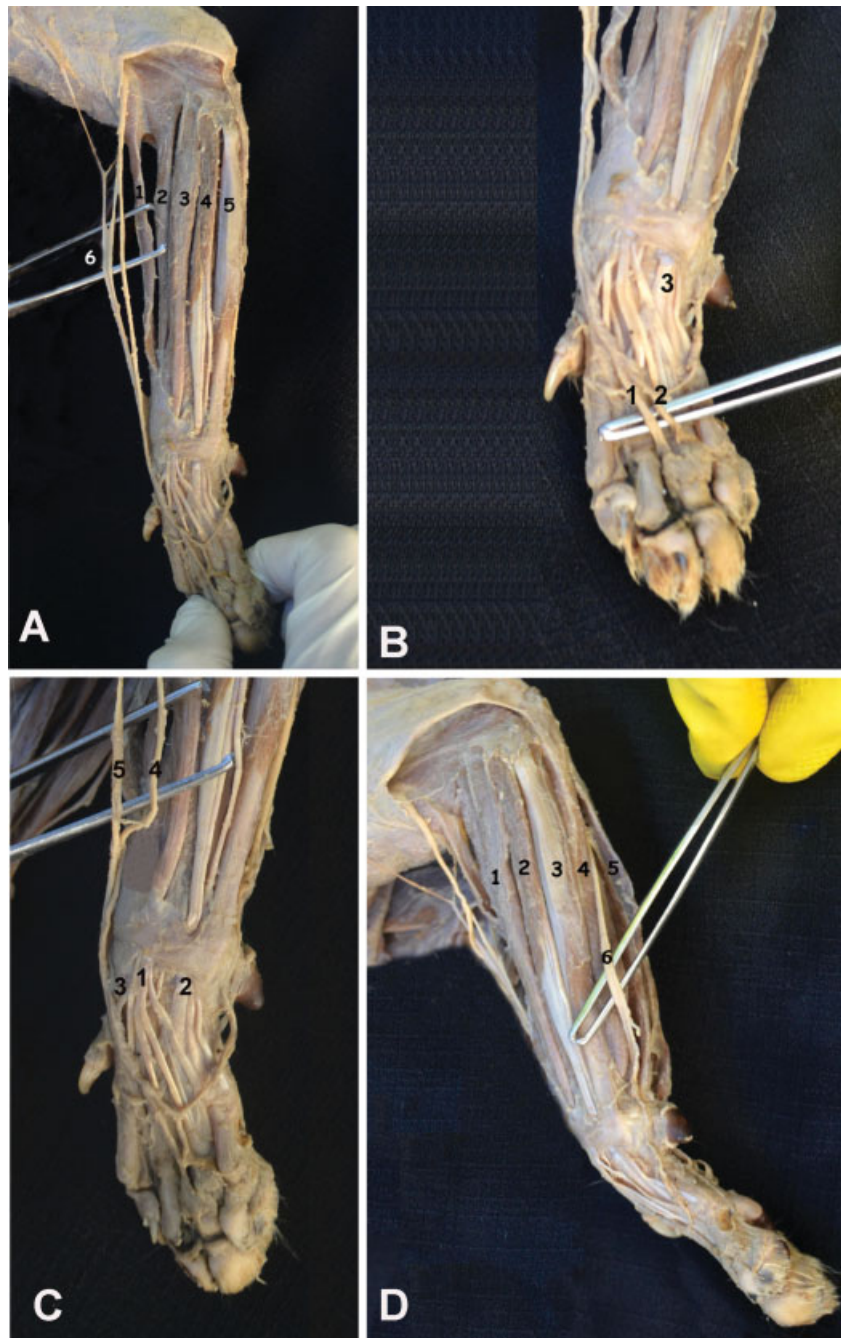


Fig. 3 (A) Side view of the forearm and of the hand of the wildcat. 1. Brachioradialis muscle. 2. Extensor carpi radialis muscle. 3. Extensor digitorum communis muscle. 4. Extensor digitorum lateralis muscle. 5. Extensor carpi ulnaris muscle. 6. Radial nerve. (B) Palmar view of the hand of the wildcat. 1. Palmar lateral branch 2. Medial palmar branch of the median nerve. 3. Tendons of the flexor digitorum profundus muscle. (C) Lateral view of the forearm and of the hand of the wildcat. 1. Extensor carpi radialis muscle. 2. Extensor digitorum communis muscle. 3. Extensor digitorum lateralis muscle. 4. Extensor carpi ulnaris muscle. 5. Flexor carpi ulnaris muscle. 6. Dorsal and palmar branches of the ulnar nerve. (D) Dorsal view of the hand of the wildcat. 1. Tendons of the Extensor digitorum communis muscle 2. Tendons of the extensor digitorum lateralis muscle 3. Tendons of the abductor pollicis 4. Lateral branches of the radial nerve 5. Medial branches of the radial nerve.

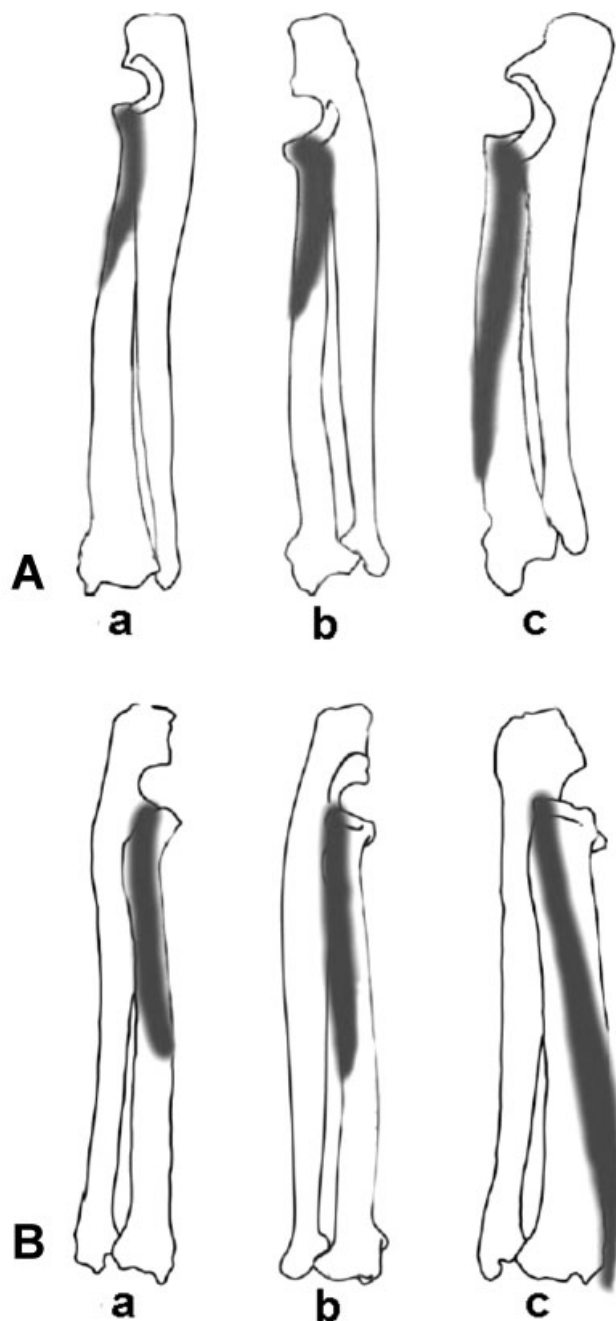


Fig. 4 A. Drawings of the radii and ulnae of the wildcat (a), ocelot (b), and jaguar (c) showing the variation in size and insertions of the supinator muscle. B. Outlines of the radii and ulnae of the wildcat (a), ocelot (b) and jaguar (c) showing the variation in size and insertions of the pronator teres muscle.

Conclusion

The most distinctive morphological adaptations that we have found between the jaguar, the ocelot, and the wildcat are the powerful supinator and pronator muscles, presenting a variation in the size of their bellies and tendons. These variations among the three species studied are related to ecomorphological variables, such as the size of their prey and their habitat.

The studies of the muscular characteristics of each species of felines and their differences will be particularly useful for future phylogenetic reconstructions. These South American

cats have been little studied, and our work represents a contribution on the homologies and differences of the forearm and hand muscles.

Conflicts of interest

The authors have no conflicts of interest to declare.

References

- Bart JH, Rebecca JF, Said M, Gutierrez Silverio YM, Doncaster CP. Scrape-marking behavior of jaguars (*Panthera onca*) and pumas (*Puma concolor*). *J Mammal* 2010;91(05):1225–1234
- Ceballos G, García A, Ehrlich PR. The sixth extinction crisis: Loss of animal populations and species. *Journal Cosmology* 2010; 8:1821–1831
- Ledesma MA, Ledesma CO, Schiaffino K, et al. Cytogenetic analysis of *Panthera Onca* (Felidae: Pantetherinae) from the province of Misiones, Argentina. *Mastozoología neotropical* 2004;11(01):85–90. Available at: http://www.scielo.org.ar/scielo.php?script=sci_arttext&pid=S0327-93832004000100009&lng=es
- Sánchez HL, Silva LB, Rafasquino ME, et al. Anatomical study of the forearm and hand nerves of the domestic cat (*Felis catus*), puma (*Puma concolor*) and jaguar (*Panthera onca*). *Anat Histol Embryol* 2013;42(02):99–104
- Silva LB, Sánchez HL. La inervación del miembro torácico en felinos. *Analecta Vet* 2013;33(01):10–17
- Diogo R, Pastor F, De Paz F, et al. The head and neck muscles of the serval and tiger: homologies, evolution, and proposal of a mammalian and a veterinary muscle ontology. *Anat Rec (Hoboken)* 2012;295(12):2157–2178
- Schaller O. *Nomenclatura Anatómica Veterinaria Ilustrada*. Acribia 1996 Zaragoza
- Nomina Anatomica Veterinaria. (NAV). International Committee on Veterinary Gross Anatomical Nomenclature. 5th ed. Hannover, Columbia, Gent, Sapporo: Editorial Committee; 2012:18–23
- Concha I, Adaro L, Borroni C, Altamirano C. Consideraciones Anatómicas sobre la Musculatura Intrínseca del Miembro Torácico del Puma (*Puma concolor*). *Int J Morphol* 2004;22(02):121–125
- Geertsema A. Impressions and observations on serval behaviour in Tanzania, East Africa. *Mammalia* 1976;40:13–19
- Seymour KL. *Panthera onca*. *Mamm Species* 1989;340:1–9
- Barone R. La myologie du lion (*Panthera leo*). *Mammalia* 1967;31(03):459–514
- Ross FO. Myology of the cheetah, or hunting leopard of India (*Felis jubata*). *Proc R Ir Acad* 1876;2(03):23–32
- Reighard J, Jennings HS. *Anatomy of the cat*. New York: Rinehart & Winston; 1966:582–592
- Medina Puentes R, Morales Muñoz P, Concha Albornoz and Borroni Gonzalez. Descripción Anatómica de la Inervación del Miembro Pélvico de León Africano (*Panthera leo*). *Int J Morphol* 2014;32(03):889–894
- Dyce KM. Thoracic member. In: Dyce KM, Sack WO, Wensing CJG eds. *Veterinary Anatomy Treaty*. 4th ed. México: El Manual Moderno S. A. de C. V; 2010:476–489
- Níkel R, Schummer A, Seiferle E, Frewein J, Wilkens H, Wille K. The Locomotor System of Domestic Mammals. Berlin: Verlag Paul Parey; 1986:515
- Liebich HG, Maierl J, König HE. Thoracic member. In: König HE, Liebich HG eds. *Veterinary Anatomy of Domestic Mammals: Textbook and Colour Atlas*. Porto Alegre: Artmed; 2016: 165–234
- De Souza PJ, Dos Santos LMPR, Nogueira DMP, Abidu-Figueiredo M, Santos ALQ. Occurrence and morphometrics of the brachioradialis muscle in wild carnivorans (Carnivora: Caniformia, Feliformia). *Zoologia* 2015;32(01):23–32
- Hudson PE, Corr SA, Payne-Davis RC, Clancy SN, Lane E, Wilson AM. Functional anatomy of the cheetah (*Acinonyx jubatus*) forelimb. *J Anat* 2011;218(04):375–385

- 21 Crouch J. Text-Atlas of Cat Anatomy. Philadelphia: Lea and Febiger; 1969:101–108
- 22 Julik E, Zack S, Adrian B, et al. Functional Anatomy of the Forelimb Muscles of the Ocelot (*Leopardus pardalis*). *J Mamm Evol* 2012;19 (04):277–304
- 23 Ruberte J, Sautet J, Navarro, M, et al. Thorax and thoracic limb. In: DoneS H, Goody PC, Evans SA, Strickland NC eds. Color Atlas of Veterinary Anatomy: the dog and the cat. España: Elsevier Mosby; 2010:171–193
- 24 El-Ghazali HM, El-behery El. Comparative Macro-Anatomical Observations of the Appendicular Skeleton of New Zealand Rabbit (*Oryctolagus cuniculus*) and Domestic Cat (*Felis domestica*) Thoracic Limb. *Inter J Vet Sci* 2018; 7:127–133