

Lung India

Official Publication of Indian Chest Society



www.lungindia.com

Editorial

Remodeling in asthma and COPD—recent concepts
Surinder Kumar Jindal ...1

Original Articles

Long-term outcomes of the bronchial artery embolization are diagnosis dependent

Vikas Pathak, Joseph M Stavas, Hubert J Ford, Charles A Austin, Robert M Aris ...3

Surgical treatment of pulmonary aspergillosis: A single center experience

Biswajeet Mohapatra, Poornima Sivakumar, Subhankar Bhattacharya, Santanu Dutta ...9

A new approach for the assessment of sleepiness and predictivity of obstructive sleep apnea in drivers: A pilot study

Vitaliano Nicola Quaranta, Silvano Dragonieri, Pierluigi Carratù, Vito Antonio Falcone, Elisa Carucci, Teresa Ranieri, Valentina Ventura, Onofrio Resta ...14

Antisynthetase syndrome: An under-recognized cause of interstitial lung disease

Venkata Nagarjuna Maturu, Arjun Lakshman, Amanjit Bal, Varun Dhir, Aman Sharma, Mandeep Garg, Biman Saikia, Ritesh Agarwal ...20

Drug resistance pattern of mycobacterial isolates in HIV and non-HIV population in South India

Umamaheshwari Shivaswamy, Sumana M Neelambike ...27

Resurvey of symptomatics of the Jaipur district population and suggestion for alternative diagnostic criteria of asthma for epidemiological surveys

Prahlad Rai Gupta, Ankit Bansal, Anupam Singh ...32

Incremental shuttle walk test: Reference values and predictive equation for healthy Indian adults

Bela Agarwal, Monal Shah, Nilesh Andhare, Rajani Mullerpatan ...36

And More....

ISSN : 0970-2113

Case Report

Pulmonary toxoplasmosis in human immunodeficiency virus-infected patients in the era of antiretroviral therapy

Jorge N Velásquez, Bibiana A Ledesma¹, Monica G Nigro¹, Natalia Vittar, Nestor Rueda, Luis De Carolis, Olga Figueiras, Silvana Carnevale¹, Marcelo Corti

Department of HIV/AIDS, Francisco Javier Muñiz Infectious Diseases Hospital, ¹Department of Parasitology, National Institute of Infectious Diseases- National Administration of Health Laboratories and Institutes (INEI-ANLIS) "Dr. Carlos G. Malbrán", Buenos Aires, Argentina

ABSTRACT

Toxoplasmosis is a severe opportunistic infection in patients infected with the human immunodeficiency virus (HIV). The lung is a major site of infection after the central nervous system. In this report we described two cases of pneumonia due to *Toxoplasma gondii* infection in HIV patients with antiretroviral therapy. Clinical and radiological abnormalities are not specific. Pulmonary toxoplasmosis should be considered in HIV-infected patients with late stage of HIV, CD4 count less than 100 cells/ μ l and a poor adherence to HAART.

KEY WORDS: AIDS, human immunodeficiency virus, polymerase chain reaction, pulmonary toxoplasmosis

Address for correspondence: Dr. Jorge N Velásquez, Francisco Javier Muñiz Infectious Diseases Hospital, Uspallata 2272, (CP 1282), Buenos Aires, Argentina. E-mail: jorgeysilvana@speedy.com.ar

INTRODUCTION

Infections are the most common pulmonary complications in human immunodeficiency virus (HIV)-infected patients.^[1,2] The introduction of highly active antiretroviral therapy (HAART) and antibiotic prophylaxis against pulmonary opportunistic infections have resulted in considerable reduction of morbidity and mortality of this kind of patients.^[3,4]

Some of HIV-infected patients have pulmonary opportunistic infections in the HAART era associated with different causes including patients who are unaware of their HIV serostatus and do not initiate HAART, late stage of HIV infection, CD4 count less than 100 cells/ μ l, HAART non-adherence or failure to respond, injection drug use and failure to provide prophylaxis against opportunistic pathogens.^[2-4]

Pulmonary toxoplasmosis is the second location of extracerebral toxoplasmosis after the ocular form, with 40% of mortality without early diagnosis and specific treatment. The diagnosis is difficult because clinical and radiological abnormalities are not specific.^[5,6]

Pulmonary toxoplasmosis accounts for 4% of all cases of pneumonia in HIV-infected patients in the pre-HAART era and is not considered commonly during the HAART era.^[6-8]

We described two cases of *Toxoplasma gondii* pneumonia in HIV patients in the HAART era.

CASE REPORTS

Case 1

A 41-year-old HIV-positive man was admitted to our hospital because of fever and cough since 5 days. His

This is an open access article distributed under the terms of the Creative Commons Attribution-NonCommercial-ShareAlike 3.0 License, which allows others to remix, tweak, and build upon the work non-commercially, as long as the author is credited and the new creations are licensed under the identical terms.

For reprints contact: reprints@medknow.com

How to cite this article: Velásquez JN, Ledesma BA, Nigro MG, Vittar N, Rueda N, De Carolis L, *et al.* Pulmonary toxoplasmosis in human immunodeficiency virus-infected patients in the era of antiretroviral therapy. Lung India 2016;33:88-91.

Access this article online	
Quick Response Code: 	Website: www.lungindia.com
	DOI: 10.4103/0970-2113.173063

medical history revealed intravenous drugs addiction, chronic renal failure and hepatitis C infection. He was started on HAART based on abacavir, lamivudine and efavirenz during the last year. On examination the patient was oriented. His temperature was 37°C, pulse rate of 100 beats per minute and 20 breaths per minute. Chest examination did not reveal rhonchi or crackles. No focal neurological deficit was evident. Relevant laboratory findings showed an hemoglobin level of 7 g/dl, total white cell count of 3,700 cells/mm³ and a normal platelet count. Renal dysfunction was evidenced by serum urea of 47 mg/dl and creatinine of 1.8 mg/dl. Ocular fundus examination was normal. The liver function test and lactate dehydrogenase level (LDH) were normal. A chest radiograph showed bilateral interstitial infiltrates [Figure 1]. Staining and culture of sputum samples were negative for bacteria, mycobacteria and fungi. Blood cultures for the same microorganisms were also negative. The CD4 T-cell count was 35 cells/μl and the plasma viral load was 203,906 copies/ml. Serologic testing revealed the presence of *T. gondii* IgG antibodies with a positive titer of 1:1024 and IgM negative by indirect immunofluorescence.

Fever and cough continued 7 days after admission to the hospital. On the eighth day a bronchoalveolar lavage (BAL) was performed. Cytological and microbiological examinations of the BAL were negative for bacteria, fungi, *Pneumocystis jirovecii* and *Mycobacterium tuberculosis*. Giemsa-stained smears of the BAL were negative for tachyzoite forms of *T. gondii*. An aliquote of the BAL fluid was assayed for *T. gondii* using the PCR technique for amplification of a fragment corresponding to the B1 gene. BAL specimens were positive by PCR for *T. gondii*. Treatment for *T. gondii* infection was initiated with sulfadiazine, pyrimethamine and folinic acid. Computed tomography (CT) scan of the brain showed marked cerebral atrophy without evidence of focal lesions.

He showed a marked improvement in clinical, radiological, and laboratory findings after the seventh day of therapy for

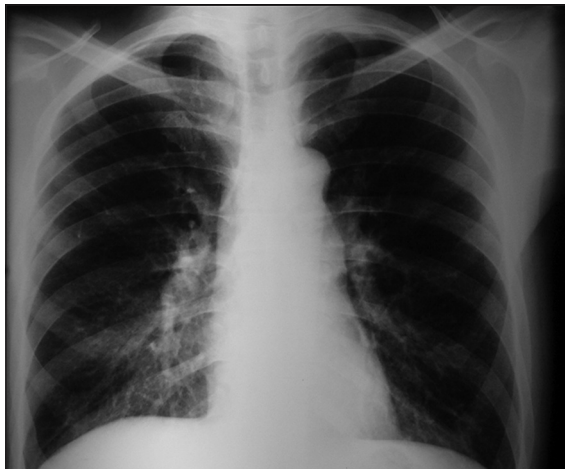


Figure 1: Chest radiograph showing bilateral interstitial infiltrates

T. gondii. He was discharged from the hospital after 15 days of admission in a good clinical condition.

Case 2

A 33-year-old male was admitted with fever and cough since 7 days. He was intravenous drug user and had been diagnosed as HIV seropositive 10 years before. He had history of cerebral toxoplasmosis 6 months before. He was discharged from the hospital with improvement in clinical and radiological finding after treatment. The patient was not adhering to treatment with HAART and secondary prophylaxis for *T. gondii* infection. On admission, he was febrile (38°C), pulse rate of 100 beats per minute and 18 breaths per minute. Chest examination reveals rales in the right lower lobe of the lung. No signs or focal neurological deficit was evident. Laboratory results showed a white blood cell count of 8,600 cell/mm³, an hemoglobin level of 12 g/dl and a normal platelet count. The liver and renal function tests were normal. The LDH level and the ocular fundus examination were also normal. A chest radiograph showed pleural effusion in right pulmonary lobe [Figure 2a]. CT scan of the chest showed pleural effusion in the right lung [Figure 2b]. Staining and culture of sputum sample were negative for bacteria, mycobacteria and fungi. Blood cultures for the same microorganisms were also negative. The CD4 T cell count was 62 cells/μl. Serologic testing revealed the presence of *T. gondii* IgG antibodies with a positive titer of 1:1024 and IgM negative by indirect immunofluorescence. Empiric treatment was initiated with Ampicillin plus sulbactam. On the fifth day fever and cough continued. A BAL was performed. Cytological and microbiological examinations were negative for bacteria, fungi, *P. jirovecii* and *M. tuberculosis*. Giemsa-stained smears of the BAL were negative for tachyzoite forms of *T. gondii*. A BAL fluid sample was assayed for *T. gondii* using the PCR technique for amplification of a fragment corresponding to the B1 gene. BAL specimens were positive for *T. gondii*. Samples from blood were also positive for *T. gondii* by the PCR technique. CT studies of the brain showed a left temporoparietal periventricular lesion with mass effect on the middle-line structures [Figure 3].

Treatment for *T. gondii* infection was initiated with sulfadiazine plus pyrimethamine and folinic acid. In the

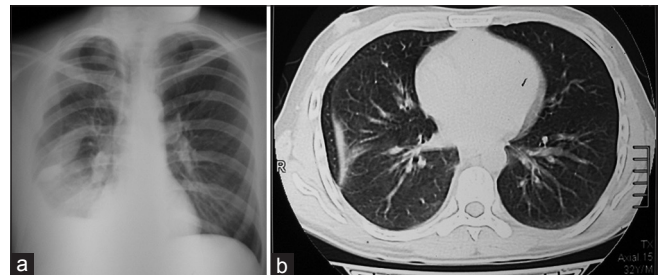


Figure 2: (a) Chest radiograph showing pleural effusion in right pulmonary lobe (b) Computerized tomography showing pleural effusion in right pulmonary lobe

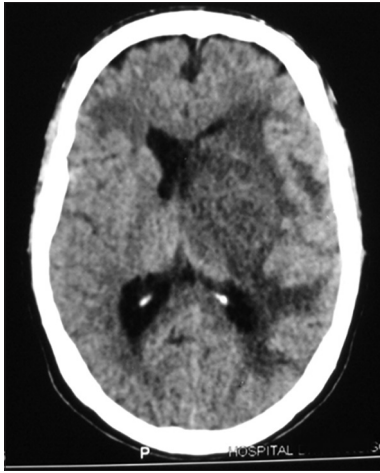

Figure 3: Computerized tomographic studies of the brain showing evidence of a focal lesion

following days the clinical condition improved. He was discharged from the hospital after 30 days in a good clinical and neurological condition.

DISCUSSION

Spectrum of HIV-related pulmonary complications that can be seen in the HAART era include *P. jirovecii* pneumonia, bacterial pneumonia and interstitial pneumonitis with unknown etiology but not pulmonary toxoplasmosis.^[7] *T. gondii* pulmonary involvement in HIV-infected patients was first described in 1984.^[8] Clinical manifestations include febrile illness associated with unspecific respiratory symptoms such as cough and dyspnea.^[4-8]

Here, we described two HIV-infected patients with poor adherence to HAART and antibiotic prophylaxis, with fever and cough but not with dyspnea or adult respiratory distress syndrome (ARDS). Kovari and colleagues published two cases in 2010 with unknown HIV status and pulmonary toxoplasmosis in Switzerland, one patients with ARDS and the second with productive cough.^[9]

The most common findings on chest radiographs are bilateral diffuse interstitial infiltrates. Other findings include nodular solitary lesions and pneumothorax.^[10] In the first case that we described, chest radiograph showed bilateral interstitial infiltrates and, in the second, pleural effusion was present. Pleural effusion was described in a previous report.^[10] In the Swiss cases chest radiographs showed bilateral diffuse interstitial infiltrates, one of them associated with *P. jirovecii*.^[9]

Pulmonary toxoplasmosis occurred in patients with advanced immunodeficiency with CD4 T-cell count less than 100 cells/ μ l.^[6] Both of our patients have CD4 lymphocyte counts less than 100 cells/ μ l. Serological data for the patients showed a rise in IgG levels but were

negative for IgM during the acute episode of pulmonary toxoplasmosis. Negative IgM antibody in pulmonary toxoplasmosis has been described by others authors.^[6]

Diagnosis of pulmonary toxoplasmosis is based on the identification of tachyzoites or DNA of *T. gondii* in samples of BAL, biopsy specimens or necropsy. BAL samples should be processed by several methods such as Giemsa staining, tissue culture, intraperitoneal inoculation of mice, immunoperoxidase assay and detection of parasite DNA by molecular techniques.^[11-13]

Giemsa-stained smears of BAL fluids from the two patients were negative for tachyzoite forms of *T. gondii*. Visualization of tachyzoites in BAL fluid by Giemsa is difficult because of their small size or their small number.^[13,14] *T. gondii* DNA is detected in BAL specimens with the use of primers targeting the B1 gene. The B1 gene is highly specific for *T. gondii* and can detect as few as 10 organisms.^[15,16] Diagnosis of pulmonary toxoplasmosis was established in the two cases with the use of primers targeting the B1 gene in BAL and blood samples. Antiparasitic therapy based on sulfadiazine and pyrimethamine was associated with a marked improvement in clinical, radiological, and laboratory findings in our cases.

CONCLUSIONS

In conclusion, pulmonary toxoplasmosis should be included in the differential diagnosis of HIV positive patients with late stage of HIV infection, CD4 T cell counts less than 100 cells/ μ l, a poor adherence or failure to HAART and with fever, cough and pulmonary radiological infiltrates.

Financial support and sponsorship

Infectious Diseases F.J. Muñiz Hospital, INEI-ANLIS “Dr. Carlos Malbrán”, Buenos Aires, Argentina.

Conflicts of interest

There are no conflicts of interest.

REFERENCES

1. Wolff AJ, O'Donnell AE. Pulmonary manifestations of HIV infection in the era of highly active antiretroviral therapy. *Chest* 2001;120:1888-93.
2. Sabin CA, Smith CJ, Gumley H, Murphy G, Lampe FC, Phillips AN, et al. Late presenters in the era of highly active antiretroviral therapy: Uptake of and responses to antiretroviral therapy. *AIDS* 2004;18:2145-51.
3. Sullivan JH, Moore RD, Keruly JC, Chaisson RE. Effect of antiretroviral therapy on the incidence of bacterial pneumonia in patients with advanced HIV infection. *Am J Respir Crit Care Med* 2000;162:64-7.
4. Kaplan JE, Hanson D, Dworkin MS, Frederick T, Bertolli J, Lindegren ML, et al. Epidemiology of human immunodeficiency virus-associated opportunistic infections in the United States in the era of highly active antiretroviral therapy. *Clin Infect Dis* 2000;30(Suppl 1):S5-14.
5. Derouin F, Sarfati C, Beauvais B, Garin YJ, Larivière M. Prevalence of pulmonary toxoplasmosis in HIV-infected patients. *AIDS* 1990;4:1036.
6. Pomeroy C, Filice GA. Pulmonary toxoplasmosis: A review. *Clin Infect*

- Dis 1992;14:863-70.
7. Chiang HH, Hung CC, Lee CM, Chen HY, Chen MY, Sheng WH, *et al.* Admissions to intensive care unit of HIV-infected patients in the era of highly active antiretroviral therapy: Etiology and prognostic factors. *Crit Care* 2011;15:R202.
 8. Murray JF, Felton CP, Garay SM, Gottlieb MS, Hopewell PC, Stover DE, *et al.* Pulmonary complications of the acquired immunodeficiency syndrome. Report of a National Heart, Lung and Blood Institute Workshop. *N Engl J Med* 1984;310:1682-8.
 9. Kovari H, Ebnöther C, Schweiger A, Berther N, Kuster H, Günthard HF. Pulmonary toxoplasmosis, a rare but severe manifestation of a common opportunistic infection in late HIV presenters: Report of two cases. *Infection* 2010;38:141-4.
 10. Goodman PC, Schnapp LM. Pulmonary toxoplasmosis in AIDS. *Radiology* 1992;184:791-3.
 11. Derouin F, Sarfati C, Beauvais B, Iliou MC, Dehen L, Larivière M. Laboratory diagnosis of pulmonary toxoplasmosis in patients with acquired immunodeficiency syndrome. *J Clin Microbiol* 1989;27:1661-3.
 12. Rabaud C, May T, Lucet JC, Leport C, Ambroise-Thomas P, Canton P. Pulmonary toxoplasmosis in patients infected with human immunodeficiency virus: A French National Survey. *Clin Infect Dis* 1996;23:1249-54.
 13. Maguire GP, Tatz J, Giosa R, Ahmed T. Diagnosis of pulmonary toxoplasmosis by bronchoalveolar lavage. *NY State J Med* 1986;86:204-5.
 14. Catterall JR, Hofflin JM, Reminton JS. Pulmonary toxoplasmosis. *Am Rev Respir Dis* 1986;133:704-5.
 15. Bretagne S, Costa JM, Vidaud M, Tran J, Nhieu V, Fleury-Feith J. Detection of *Toxoplasma gondii* by competitive DNA amplification of bronchoalveolar lavage samples. *J Infect Dis* 1993;168:1585-8.
 16. Burg JL, Grover CM, Pouletty P, Boothroyd JC. Direct and sensitive detection of a pathogenic protozoan, *Toxoplasma gondii*, by polymerase chain reaction. *J Clin Microbiol* 1989;27:1787-92.