

Sarcocystis masoni, n. sp. (Apicomplexa: Sarcocystidae), and redescription of *Sarcocystis aucheniae* from llama (*Lama glama*), guanaco (*Lama guanicoe*) and alpaca (*Vicugna pacos*)

GASTÓN MORÉ^{1,2*}, CRISTIAN REGENSBURGER³, M. LAURA GOS^{1,2}, LAIS PARDINI^{1,2}, SHIV K. VERMA⁴, JULIANA CTIBOR³, MARCOS ENRIQUE SERRANO-MARTÍNEZ⁵, JITENDER P. DUBEY⁴ and M. CECILIA VENTURINI¹

¹ Laboratorio de Immunoparasitología, Facultad de Ciencias Veterinarias, Universidad Nacional de La Plata, La Plata, Argentina

² Consejo Nacional de Investigaciones Científicas y Técnicas (CONICET), Buenos Aires, Argentina

³ Unidad Académica Caleta Olivia, Universidad Nacional de la Patagonia Austral, Santa Cruz, Argentina

⁴ United States Department of Agriculture, Agricultural Research Service, Beltsville Agricultural Research Center, Animal Parasitic Diseases Laboratory, Beltsville, Maryland 20705-2350, USA

⁵ Facultad de Medicina Veterinaria y Zootecnia, Universidad Peruana Cayetano Heredia, Lima, Perú

(Received 4 November 2015; revised 15 December 2015; accepted 29 December 2015)

SUMMARY

There is considerable confusion concerning the species of *Sarcocystis* in South American camelids (SAC). Several species names have been used; however, proper descriptions are lacking. In the present paper, we redescribe the macroscopic sarcocyst forming *Sarcocystis aucheniae* and describe and propose a new name, *Sarcocystis masoni* for the microscopic sarcocyst forming species. Muscles samples were obtained from llamas (*Lama glama*) and guanacos (*Lama guanicoe*) from Argentina and from alpacas (*Vicugna pacos*) and llamas from Peru. Individual sarcocysts were processed by optical and electron microscopy, and molecular studies. Microscopic sarcocysts of *S. masoni* were up to 800 µm long and 35–95 µm wide, the sarcocyst wall was 2.5–3.5 µm thick, and had conical to cylindrical villar protrusions (vp) with several microtubules. Each vp had 11 or more rows of knob-like projections. Seven 18S rRNA gene sequences obtained from sarcocysts revealed 95–96% identity with other *Sarcocystis* spp. sequences reported in the GenBank. Sarcocysts of *S. aucheniae* were macroscopic, up to 1.2 cm long and surrounded by a dense and laminar 50 µm thick secondary cyst wall. The sarcocyst wall was up to 10 µm thick, and had branched vp, appearing like cauliflower. Comparison of the 11 sequences obtained from individual macroscopic cysts evidenced a 98–99% of sequence homology with other *S. aucheniae* sequences. In conclusion, 2 morphologically and molecularly different *Sarcocystis* species, *S. masoni* (microscopic cysts) and *S. aucheniae* (macroscopic cysts), were identified affecting different SAC from Argentina and Peru.

Key words: *Sarcocystis* spp. South American camelids, PCR, sequencing, electron microscopy, Argentina, Peru.

INTRODUCTION

There is considerable confusion concerning the species of *Sarcocystis* in camelids (Dubey *et al.* 2015a). Historically, a macroscopic sarcocyst observed in a llama (*Lama glama*) was named *Sarcocystis aucheniae* by Brumpt (1913) in his book but no other detail was provided. Sarcocysts were found in a guanaco (*Lama guanicoe*) and named *Sarcocystis tilopodi* by Quiroga *et al.* (1969), based on finding it in a different species of *Lama*. In Chile, Gorman *et al.* (1984) found macroscopic and microscopic sarcocysts in *L. guanicoe* and the authors suggested that the parasite in *L. glama* should be named *Sarcocystis lamacanis* and the parasite in the species *L. guanicoe* should be called *S. guanicoecanis*. In a review paper, Leguía recognized 2 species and called the parasite, *S.*

aucheniae (macroscopic cysts) and *S. lamacenis* (microscopic cysts); the author probably misspelled *S. lamacanis* as *lamacenis* and this name was copied by Taylor *et al.* (2007) and by Rooney *et al.* (2014). Microscopic cysts detected in heart muscle from llamas and alpacas were named as *S. lamacanis* (Leguía and Casas, 1999). In Germany, Schnieder *et al.* (1984) found both microscopic and macroscopic sarcocysts in *L. glama* from Bolivia; dogs but not cats fed both types of sarcocysts excreted sporocysts. They thought that microscopic sarcocysts could either be developmental stages of *S. auchenie* or sarcocysts of a separate species. A history of sarcocysts detection in South American camelids (SAC) is summarized in Table 1.

A critical examination of the taxonomy of *Sarcocystis* species (Dubey *et al.* 2015a), led to the conclusion that there is only 1 valid name, *S. aucheniae*, and that there is no valid reason separating species infecting llamas and alpacas (*Vicugna pacos*). Therefore, the names *S. guanicoecanis*, *S. lamacanis*, *S. lamacenis* should be *nomen nudum/dubia*; as well as the names with hyphen since taxonomically are not permitted. Because the sarcocyst

* Corresponding author. Universidad Nacional de La Plata, Facultad de Ciencias Veterinarias, Calle 60 y 118 (Zip code: 1900) La Plata, Argentina. Tel: +54 221 4249621. Fax: +54 221 4257980. E-mail: gastonmore@fcv.unlp.edu.ar

Table 1. Detection of *Sarcocystis* spp. sarcocysts in SAC

Reference	Country	Host	Samples		Sarcocysts			Bioassay in DH
			<i>n</i>	Prevalence (%) M/m ^a	LM/TEM	Molecular	Name used	
Guerrero <i>et al.</i> (1967)	Peru	Alpaca	200	–/100 –/99·5	Yes/no	No	<i>Sarcocystis</i> sp.	No
Quiroga <i>et al.</i> (1969)	Argentina	Guanaco	119	40/–	Yes/no	No	<i>S. tilopodi</i>	No
Castro, (1974)	Peru	Llama	131	0/98·4 74/90·1 98·4/0	Yes/no	No	<i>S. aucheniae</i>	No
Schnieder <i>et al.</i> (1984)	Bolivia	Llama	–	Yes/yes	Yes/yes	No	<i>S. aucheniae</i>	Yes*
Gorman <i>et al.</i> (1984)	Chile	Guanaco	–	Yes/yes	Yes/no	No	<i>S. guanicocanis</i>	Yes*
Leguía <i>et al.</i> (1989)	Peru	Alpaca	–	Yes/yes	No/no	No	<i>S. aucheniae</i> (M), <i>S. lama-</i> <i>canis</i> (m)	Yes*
Ayala (1999)	Bolivia	SAC	1023	24·64/–	No/no	No	<i>Sarcocystis</i> sp.	No
La Perle <i>et al.</i> (1999)	USA	Alpaca	1	Yes/–	Yes/yes	No	<i>S. aucheniae</i>	No
Holmdahl <i>et al.</i> (1999)	Australia	Alpaca	1	Yes/–	No/no	Yes (a)	<i>S. aucheniae</i>	No
Beldomenico <i>et al.</i> (2003)	Argentina	Guanaco	12	66·6/66·6	Yes/no	No	<i>Sarcocystis</i> sp.	No
Cornejo <i>et al.</i> (2007)	Peru	Alpaca Llama	–	Yes/–	No/no	No	<i>S. aucheniae</i>	Yes*
Gabor <i>et al.</i> (2010)	Australia	Alpaca	1	Yes	Yes/yes	No	<i>Sarcocystis</i> sp.	No
Carletti <i>et al.</i> (2013)	Argentina	Llama	3	100/–	No/no	Yes (b)	<i>S. aucheniae</i>	No
Zacarias <i>et al.</i> (2013)	Peru	Alpaca	–	Yes/–	No/no	No	<i>S. aucheniae</i>	Yes*
Rooney <i>et al.</i> (2014)	Bolivia	Llama	1196	34·1/–	No/no	No	<i>S. lamacenis</i>	No
Regensburger <i>et al.</i> (2015)	Argentina	Guanaco	2	100/–	Yes/yes	Yes (c)	<i>S. aucheniae</i>	No

^a M, Macroscopic cysts; m, microscopic cysts; (–), not informed. 18S rRNA gene sequence reported in the GenBank as (a) = AF017123; (b) = JX110660– JX110668; (c) = KT382799. DH: definitive hosts/ (*), dogs shed sporocysts after experimental infection.

Table 2. Details of camelids muscle samples and sarcocysts examined by LM and TEM

Country/region	No. of samples/animal species	No. of macroscopic cysts examined by LM/TEM	No. of microscopic cysts examined by LM/TEM
Argentina/Jujuy	5/ <i>Lama glama</i>	10/5	14/4
Argentina/Santa Cruz	10/ <i>Lama guanicoe</i>	15/6	23/8
Peru/Huancavelica	7/ <i>Lama pacos</i>	20/7	15/5
	3/ <i>Lama glama</i>	10/3	9/4
Total	25	55/21	61/21

that Brumpt (1913) first recognized was macroscopic it seems reasonable to designate macroscopic species as *S. aucheniae* (Dubey *et al.* 2015a).

In the present paper, we redescribe the macroscopic sarcocyst forming *S. aucheniae* and describe and name the microscopic sarcocyst forming species, as *S. masoni*, after Dr Eugene Mason who first recognized sarcocystosis in a camel.

MATERIALS AND METHODS

Samples collection and microscopy

Samples (50 g) of muscles from the neck and lumbar region were collected from different camelids from Argentina and Peru (Table 2). Muscles were

transported refrigerated at 4 °C and processed immediately by the direct observation and fresh microscopic examination.

The muscle samples were cut with a scalpel and examined for the presence of macroscopic sarcocysts. Sarcocysts were separated from muscle and individual cysts samples were observed by light microscopy (LM), fixed in 2% glutaraldehyde for transmission electron microscopy (TEM) and conserved at –20 °C for molecular studies. The muscles were further processed by homogenization and examined by LM essentially as previously described (Moré *et al.* 2011). Microscopic cysts observed were collected with a micropipette and a sterile tip and processed as for macroscopic cysts. TEM studies were conducted as previously for sarcocysts obtained from cattle samples

(Moré *et al.* 2011). Additionally, glutaraldehyde-fixed macroscopic cysts from a llama sample were processed for scanning electron microscopy (SEM).

All the morphological descriptions were performed with the average of at least 20 measurements.

Molecular analysis

DNA was extracted from intact or broken cysts with commercial kit (Wizard genomics, Promega, USA) according to manufacturer instructions. Samples of DNA were amplified by PCR using primers SarcoFext and SarcoRext proceeding as previously (Moré *et al.* 2013). Amplicons obtained which reach a gel-estimated concentration of about $40 \text{ ng } \mu\text{L}^{-1}$, were purified using a commercial kit (Wizard SV clean up system, Promega) according to manufacturer instructions, and submitted for sequencing to the Genomic Unit, Biotechnology Institute CICVyA – CNIA – INTA, Argentina. Samples of DNA from microscopic cysts were amplified with primers ERIB1 – PrimerB and purified as previously, and submitted for sequencing with primers 3H, 4H, S3 and S5 (Moré *et al.* 2013). Additionally, DNA from a macroscopic cyst from Argentinean llama was amplified to reach the full length of the 18S rRNA gene, purified, cloned into plasmids and sequenced as previously (Moré *et al.* 2013). Sequences obtained were aligned and analysed with the GENEIOUS software (7.1 version available at <http://www.geneious.com>), and analysed and compared by BLASTn function from NCBI (<http://blast.ncbi.nlm.nih.gov/>).

Consensus sequences obtained were phylogenetically analysed based on a ClustalW multi-alignment using 18S rRNA gene sequences from several *Sarcocystis* spp. with the 18S rRNA gene sequence of *Toxoplasma gondii* (GenBank M97703) as an out-group (tree function of the GENEIOUS program). A neighbour-joining method was applied with a Tamura–Nei-model genetic distance calculation and with 1000 bootstrap replicates using 50% of support threshold.

RESULTS

Description of *S. masoni*, n. sp.

Sarcocysts were up to $800 \mu\text{m}$ long and $35\text{--}95 \mu\text{m}$ wide. The sarcocyst wall in isolated unstained cysts appeared striated with radial projections which were not always visible (Fig. 1A, B). In Toluidine blue stained sections the sarcocyst wall was $2.5\text{--}3.5 \mu\text{m}$ thick, and had small protrusions (Fig. 1C). By TEM, the sarcocyst wall had conical to cylindrical villar protrusions (vp), $2\text{--}2.8 \mu\text{m}$ long and $0.5\text{--}0.7 \mu\text{m}$ wide (Fig. 2A–D). Some vp appeared wider at the base (Fig. 2C, D). They were lined by a 25–45 nm thick electron dense parasitophorous vacuolar membrane (pvm). The vp were at irregular distances and

the host myocyte was often degenerated along the vp giving the impression that vp were apart (Fig. 2A). Each vp had several microtubules (mt) from the tip of the villus to the middle of the ground substance (gs) layer. The mt were smooth, without granules. Several rows (11 or more) of knob-like protrusions (pr) out-pocketed from pvm and they appeared to be interconnected. Evenly distributed hair-like electron dense, structures were seen on vp tips (Fig. 2B). The gs layer was $0.5\text{--}1.0 \mu\text{m}$ thick (Fig. 2A). The deeper part (juxtaposed with bradyzoites) of the gs was smooth and more electron dense than the outer part towards the vp (Fig. 2C), but this distinction was not always apparent. The total thickness of the sarcocyst wall (from the base of gs to vp tip) was $2.5\text{--}3.5 \mu\text{m}$. Bradyzoites were $11\text{--}14 \times 2\text{--}3.5 \mu\text{m}$ in size. Bradyzoites contained numerous micronemes located in the anterior half and amylopectin granules located in the posterior half (Fig. 2E).

Full-length 18S rRNA gene amplicons evidenced sequencing results only with primers 3H, 4H, S3 and S5 and consensus sequences of 1125 and 1134 bp from an Argentinean llama and guanaco sample were obtained, respectively (GenBank accession numbers KU527109 and KU527111). For the remaining 5 amplicons (partial sequences), consensus sequences obtained ranged from 755 to 805 bp and correspond to cyst samples from Argentinean guanaco ($n=2$) and llama ($n=1$), and from Peruvian alpacas ($n=2$) (GenBank KU527107, KU527108, KU527110, KU527112 and KU527113). The 7 sequences obtained showed a sequence identity ranging 98.6–99.8% among them. BLAST analysis revealed the higher sequence identity (only 95–96%) with other *Sarcocystis* spp. sequences such as *S. silva* (JN226124) and *S. tarandi* (GQ250971 and GQ250968). All sequences obtained from microscopic cysts from different SAC species positioned together in a unique branch closely related with other sequences of *Sarcocystis* spp. which used canids as definitive hosts (Fig. 3).

Taxonomic summary of S. masoni, n. sp. (Figs 1, 2, 7A).

Diagnosis. Sarcocysts microscopic (up to $800 \mu\text{m}$ long and $35\text{--}95 \mu\text{m}$ wide). The sarcocyst wall was $2.5\text{--}3.5 \mu\text{m}$ had conical to cylindrical vp ($2\text{--}2.8 \mu\text{m}$ long and $0.5\text{--}0.7 \mu\text{m}$ wide) with mt and knob-like projections.

Type intermediate host. Llama (*L. glama*).

Other intermediate hosts. Guanaco (*L. guanicoe*), Alpaca (*V. pacos*).

Distribution. South America. Probably follow the intermediate host distribution.

Definitive host. Unknown (dog and other canids are the most likely DH).

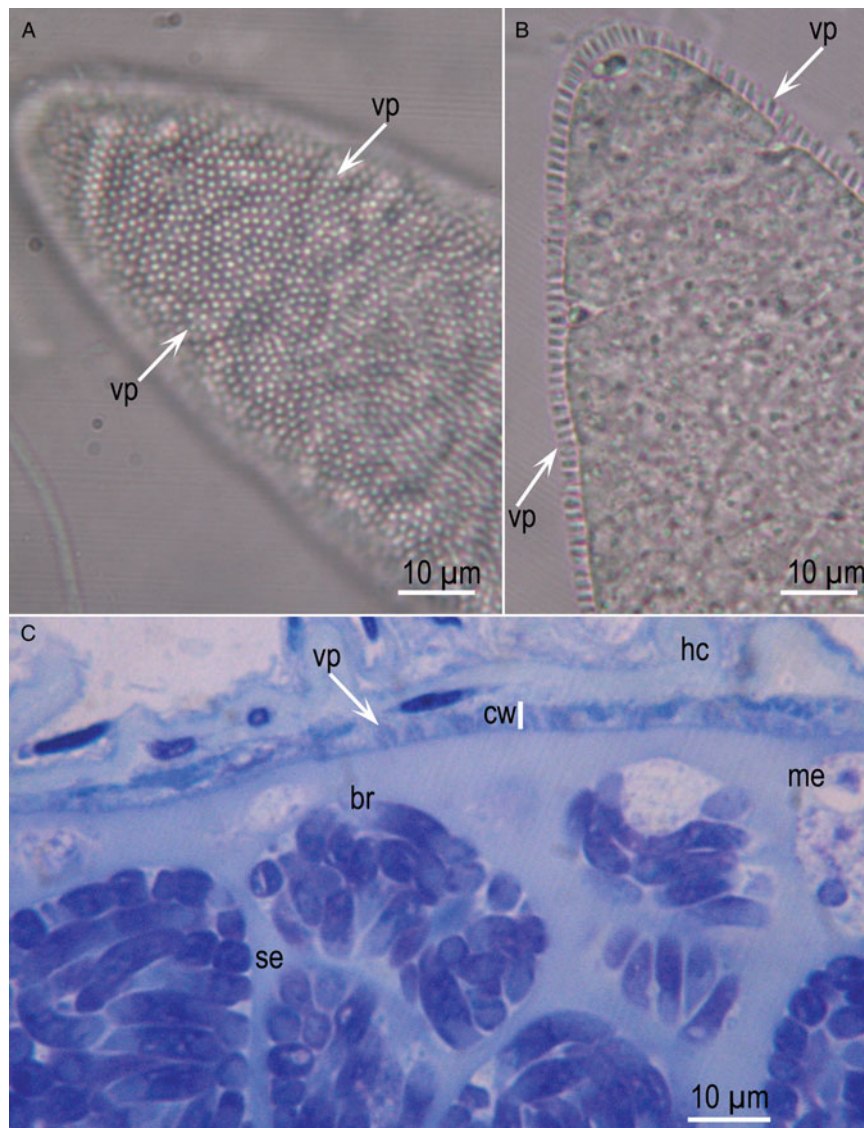


Fig. 1. *Sarcocystis masoni* sarcocysts from *Lama glama* from Argentina. (A) Surface view showing tips of vp. Unstained. (B) Flattened sarcocyst showing striations on the cyst wall. Unstained. (C) Section (1 µm) stained with Toluidine blue. Note relatively thin cyst wall (cw), conical vp and elongated bradyzoites (br).

Etymology. Species named after Dr Eugene Mason who was the first to describe sarcocysts in camelids in a report in 1910.

Specimens deposited. Sections of Syntypes of toluidine blue stained cyst sections deposited in the United States National Parasite Collection in the Division of Invertebrate Zoology and National Museum of Natural History, Smithsonian Institution, Washington, D.C.

Sequences were deposited in NCBI GenBank (accession numbers KU527107–KU527113).

Redescription of *S. aucheniae*

Sarcocysts were macroscopic up to 1.2 cm long; most cysts were 2–7 mm (Fig. 4). They were pale yellow in colour. Some cysts were embedded deep in muscles while some were superficial. Cysts were

frequently surrounded by a dense and laminar secondary cyst wall (scw), approximately 50 µm thick (Figs 5B, C). In Toluidine blue stained sections, the sarcocyst wall was 8–10 µm thick (Fig. 5A), and the centre of the cysts contained fluid material, often without viable bradyzoites. By TEM, the cyst wall was up to 10 µm thick, including the gs layer and the scw consisted of degenerated host cells, often appearing laminated structures (Fig. 5C). The proper sarcocyst wall had branched vp, appearing like cauliflower. The vp were difficult to measure because of branching; they were approximately 3–4.5 µm high by 2.5–3.5 µm wide. The gs was 3–5 µm and appeared homogenous without granules. In some sections, the vp had a conical cap (Figs 6B and 7B) with criss-crossing mt, without granules. Hair-like structures were visible on the tip of the villar cap. Oval to elongated bradyzoites were packed in sacs separated by septa

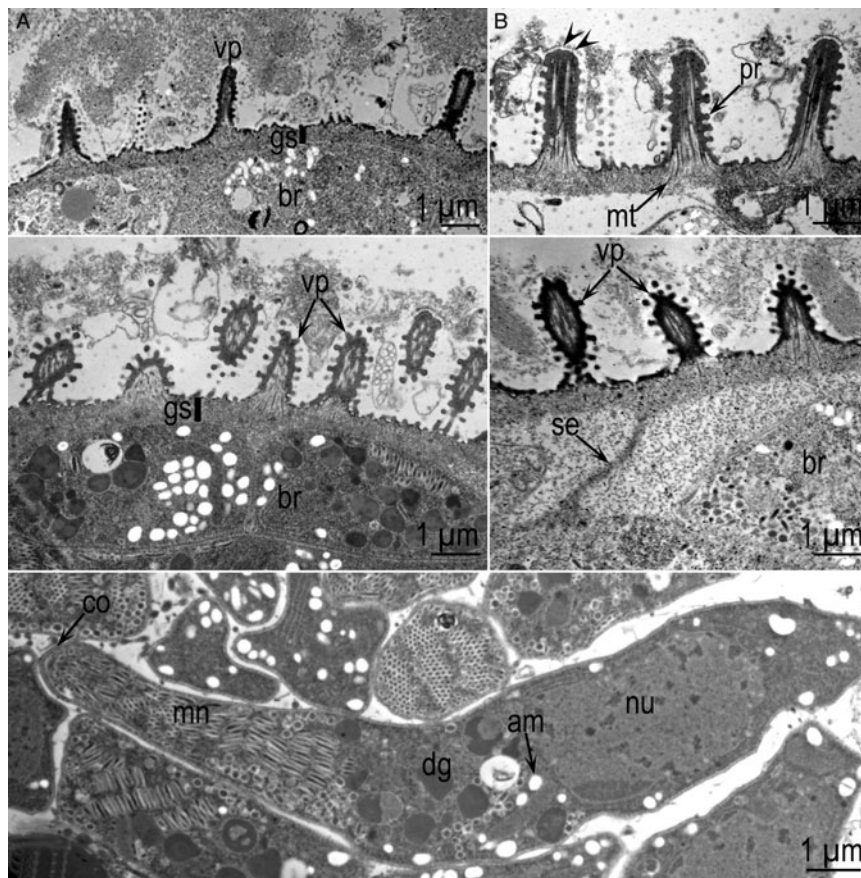


Fig. 2. TEM of *Sarcocystis masoni* sarcocysts. Note villar protrusions (vp), ground substance layer (gs), microtubules (mt), bradyzoites (br), septum (se). (A–D) Cyst wall of 4 sarcocysts. Note variability of vp shapes and sizes. A from *Lama glama*, Argentina, B from *Lama guanicoe*, Argentina, C from *L. guanicoe*, Argentina, D from *L. glama*, Peru. (E) Longitudinally cut bradyzoite. Note conoid (co), amylopectin granules (am), dense granules (dg) and nucleus (nu). From *L. glama*, Peru.

(Fig. 6C). By TEM, the bradyzoites were $13\text{--}18\ \mu\text{m} \times 3\text{--}5\ \mu\text{m}$ in size. Each bradyzoite contained numerous micronemes in conoidal third of the bradyzoite, several dense granules, 2 rhoptries and numerous amylopectin granules (Fig. 6D).

Full-length 18S rRNA gene sequence of 1879 bp was obtained after cloning in plasmids from an Argentinean llama cyst sample (accession number KU527117). A total of 2 clones were sequenced and consensus sequences were identical. The sequence revealed the highest identity ($\geq 99\%$) with sequences of *S. aucheniae* reported in GenBank (KF383266–KF3832668 and KT382799). A total of 13 amplicons from macroscopic cysts samples were submitted for sequencing and in 3 samples the results were inconclusive. From the remaining 10 samples, consensus sequences ranging from 511 to 794 bp were obtained from Argentinean llamas ($n=2$) and guanacos ($n=4$) and from alpacas ($n=3$) and llamas ($n=1$) from Peru. All sequences were registered on the GenBank (accession numbers KU527114–KU527124) and evidenced a 98–99% of sequence homology with *S. aucheniae* sequences (KT382799, KF383266, KF3832667, KF3832668 and AF017123) by the BLASTn analysis. Comparison of the 11

sequences obtained from macroscopic cysts evidenced a sequence identity ranging 99.4–100% among them.

The phylogenetic tree performed positioned all the obtained *S. aucheniae* sequences in the same branch with other *S. aucheniae* previously reported sequences. The *S. aucheniae* branch positioned separated from other sequences of *Sarcocystis* spp. which used canids as definitive host (Fig. 3).

Taxonomic summary of S. aucheniae (Brumpt, 1913)

Diagnosis: Sarcocysts macroscopic (up to 1.2 cm). The sarcocyst wall is $10\ \mu\text{m}$ thick and frequently surrounded by a $50\ \mu\text{m}$ thick secondary cyst wall. The branched vp with ‘cauliflower-like’ shape measured $3\text{--}4.5\ \mu\text{m}$ high by $2.5\text{--}3.5\ \mu\text{m}$ width, mt in vp are smooth. Mature sarcocysts evidenced a solid package of bradyzoites within septa in the peripheral area and fluid material without viable bradyzoites in the centre. Bradyzoites measured $13\text{--}18 \times 3\text{--}5\ \mu\text{m}$.

Intermediate host. South American Camelids (SAC).

Distribution. South America. Probably follow the intermediate host distribution.

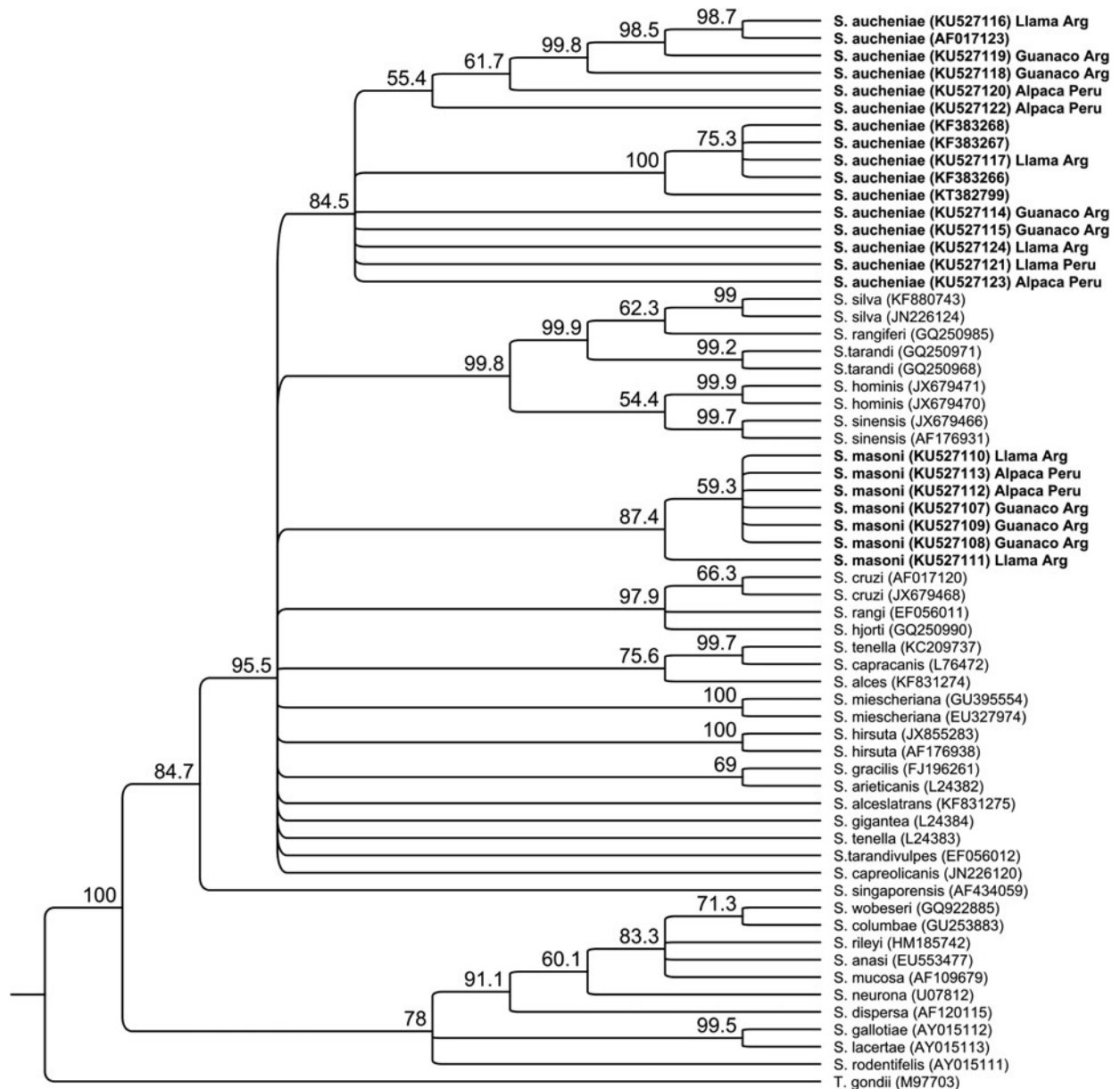


Fig. 3. Phylogenetic tree. Neighbour-Joining consensus tree from a multiple *Sarcocystis* spp. 18S rRNA gene sequence alignment. A *Toxoplasma gondii* sequence (GenBank M97703) was used as an out-group. Branch support is represented as percentage from 1000 bootstraps. Sequences obtained from South American Camelids are in bold and the sequences obtained in the present study include the host name and country (Arg = Argentina).

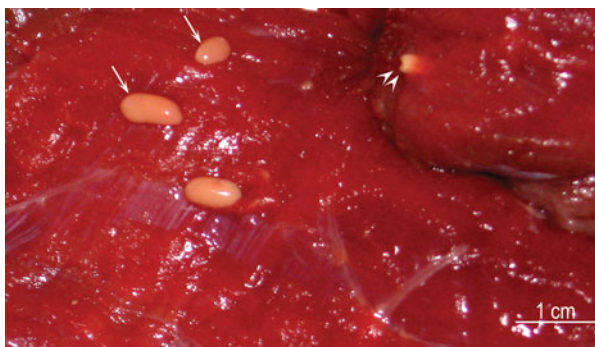

Fig. 4. Macroscopic sarcocysts of *Sarcocystis aucheniae* from *Lama glama*, Argentina. Unstained. Note sarcocysts on the surface (arrow) and embedded (arrow heads).

Definitive host. Dog (according experimental infection results).

DISCUSSION

The sarcocysts found in the present study were clearly distinguished as 2 species based on morphological and molecular data. Until now, sarcocysts in camelids were recognized as microscopic and macroscopic, sometimes regarded the same species. This is the first full morphological description of the microscopic cyst.

The structure of sarcocyst wall is a useful criterion to distinguish *Sarcocystis* spp. within a given host. A

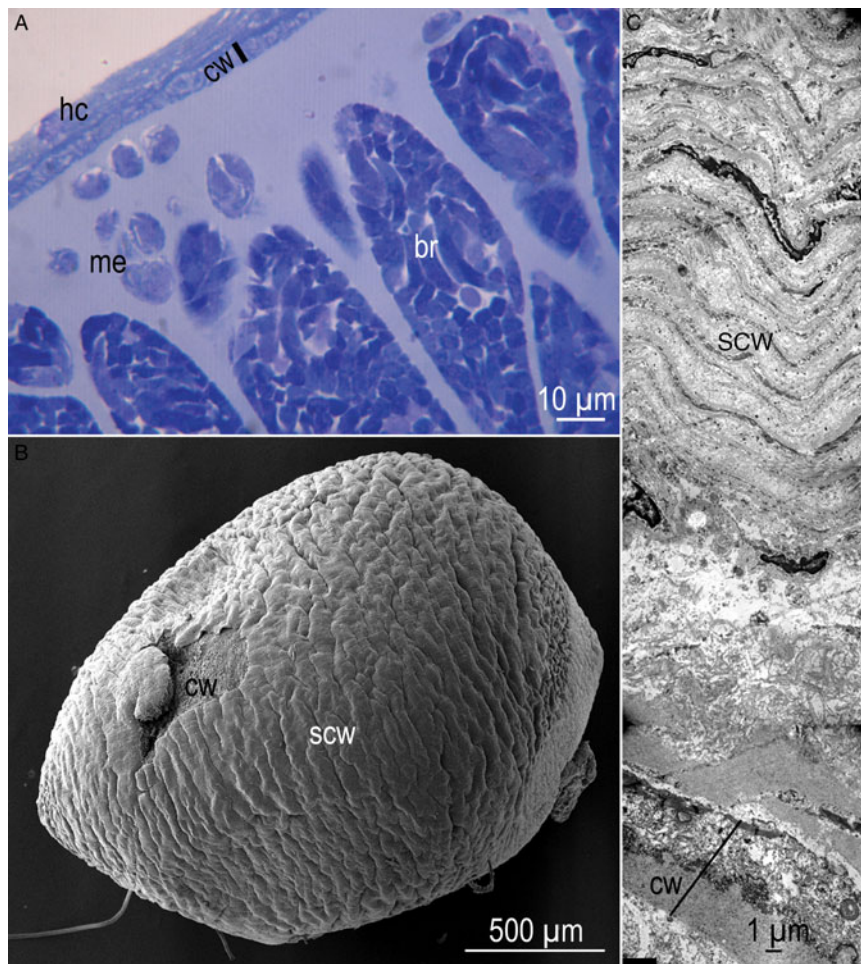


Fig. 5. Sarcocyst of *Sarcocystis aucheniae*. (A) Toluidine blue stained section ($10\ \mu\text{m}$) from *Lama glama*, Peru. Note host cell (hc), cyst wall (cw) and bradyzoites (br). (B) SEM of a sarcocyst enclosed in capsule from *Lama glama*, Argentina. Part of the secondary cyst wall (SCW) is broken and the cw proper is visible. (C) TEM of sarcocyst from *L. glama*, Argentina. The cw is relatively thin compared with thickness of the secondary cyst wall.

recent review indicated that there were more than 200 *Sarcocystis* species with at least 42 types and several subtypes of sarcocyst wall (Dubey *et al.* 2015a). Among all species of *Sarcocystis*, *S. cameli* from the domestic camel has a distinctive cyst wall, classified as 'type 9j'. Sarcocyst wall of *S. masoni*, described here is similar to cyst wall of *S. cameli* (Dubey *et al.* 2015b).

Although the macroscopic *S. aucheniae* sarcocysts were recognized for decades, this is the first complete description of the sarcocyst. Schnieder *et al.* (1984) described the ultrastructure of *S. aucheniae* cysts; however, their focus was on transmission of the parasite. They found that of dogs and cats fed individual macroscopic sarcocysts, only the dog shed sporocysts. This is an unusual finding because most macroscopic sarcocysts of other animals are transmitted by cats and not dogs (Dubey *et al.* 2015a). The structure of macroscopic *S. aucheniae* sarcocysts in the present study is essentially similar to sarcocysts of *Sarcocystis gigantea* of sheep described in detail from the oesophagus of sheep (Mehlhorn and Scholtz, 1973). In the present

study, we provided the description of the scw of *S. aucheniae*, including the surface view by SEM. The proper cyst wall had vp that were highly branched, like a cauliflower. Other species producing macroscopic cysts like *S. gigantea* of sheep, *Sarcocystis fusiformis* of the water buffalo (Dubey *et al.* 2015c), *Sarcocystis cafferi* of the African buffalo (Dubey *et al.* 2014) and *Sarcocystis rileyi* of ducks (Dubey *et al.* 2003) have been described to have cauliflower-like branching of vp. However, these sarcocysts are structurally distinct. For example, the vp in *S. fusiformis* have dumbbell-like protrusions that were not seen in *S. aucheniae*. Also, the conical villar tips with prominent mt found in the present study were not reported previously for other macroscopic cysts. Whether some of these differences are related to techniques and fixatives used needs further investigation.

Sarcocystis spp. mixed infections are frequently observed in herbivore muscles (Moré *et al.* 2014a; Dubey *et al.* 2015a). In the present study, most of the samples contained sarcocysts from 2 species. Because in some transmission studies,

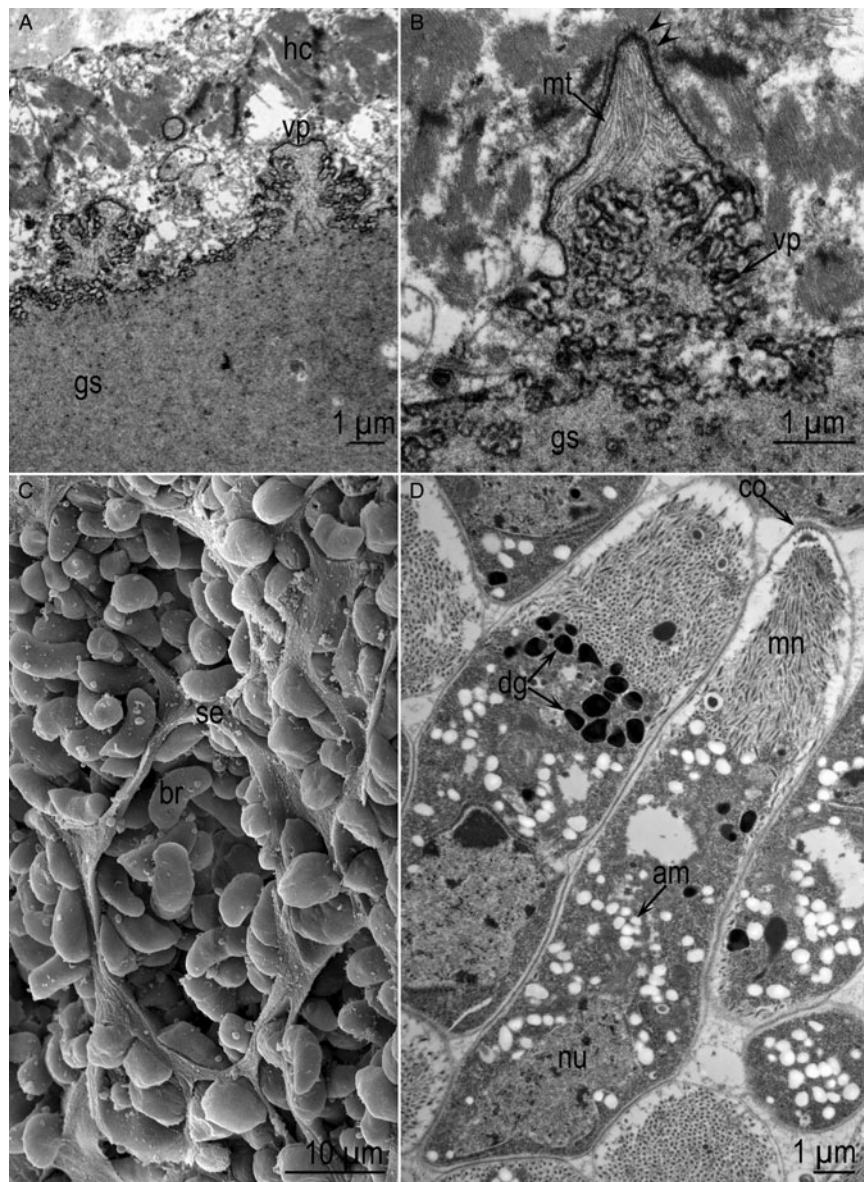


Fig. 6. TEM and SEM of *Sarcocystis aucheniae* sarcocyst from *Lama glama*, Argentina. (A) Low magnification of the cyst wall showing branched protrusions (vp). (B) Higher magnification of vp showing villar tip containing microtubules (mt) and hair-like projections (arrow heads). (C) SEM of cyst showing bradyzoites (br) and septa (se). (D) TEM of bradyzoites. Note amylopectin granules (am), dense granules (dg), a conoid (co) and nucleus (nu).

dogs that excreted sporocysts had been fed naturally infected camelid muscles (Gorman *et al.* 1984; Leguía and Casas, 1999), the definitive host for *Sarcocystis masoni* is uncertain. Therefore, there is a need to perform experimental studies using individual sarcocysts as we did for the present molecular studies.

From the literature it appears that sarcocysts in domestic camel are different than from sarcocysts in SAC. Camels are native to Asia and the Middle Eastern countries and not present in South America. The macroscopic sarcocyst of *S. aucheniae* has not been recorded in domestic camel and *Sarcocystis ippeni* of camel has not been found in the SAC. Additionally, *S. ippeni* has characteristic

sarcocyst wall structure, 'type 32' not found in other species of *Sarcocystis* (Dubey *et al.* 2015b).

In the present study, we provided additional molecular data on *Sarcocystis* species in camelids and supporting morphological findings. While reviewing literature on *Sarcocystis* infections in SAC, we encountered that several publications were conference proceedings or in local journals (Table 1), a fact which complicate proper comparisons.

The 18S rRNA gene fragments sequences from *S. masoni* were almost identical among different sampled SAC, but showed only 96% of sequence identity with *S. aucheniae* and other *Sarcocystis* spp. gene sequences reported on the GenBank. Previous reported sequences of *S. lamacanis*

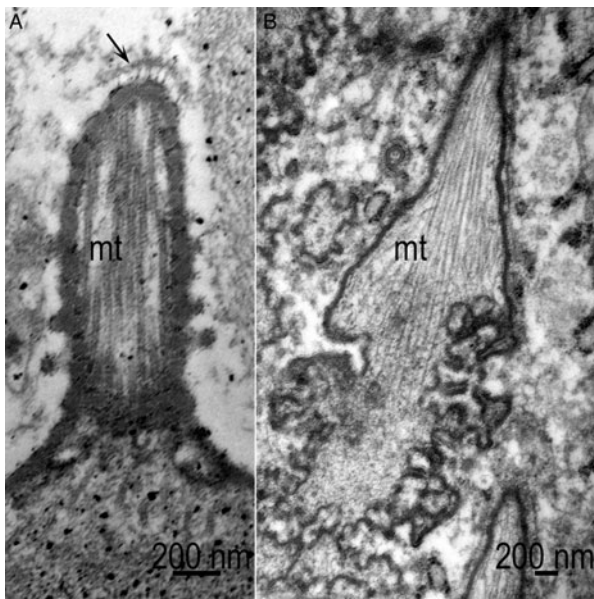


Fig. 7. Comparison of villar protrusions (vp) of *Sarcocystis masoni* and *Sarcocystis aucheniae*. Note smooth microtubules (mt). (A) Cylindrical vp of *S. masoni*. Arrow points to hair-like projections on villar tip. (B) Conical vp of *S. aucheniae*.

DQ100056 and AY840990 (Medrano *et al.* 2006) as well as EF640651 and EF640652 (Arias and Hung unpublished) did not show higher homology and/or did not show a high coverage with our sequences. Probably all previous short 18S rRNA gene sequences (ranging 280–343 bp) were obtained from a different gene region as we amplified, which did not include hyper-variable regions. In addition, if these previously reported sequences (for example DQ100056 and EF640652) are analysed by BLASTn, they have 99% identity with many other *Sarcocystis* spp. sequences (including *S. cruzi*, *S. tenella*, *S. gracilis*, *S. silva*, *S. hjorti*, etc.). Moreover, any of the previous studies have performed a morphological characterization of the *Sarcocystis* sp. prior amplification and sequencing. The present sequences from the microscopic *S. masoni* sarcocysts should serve as reference for future molecular studies. Phylogenetical analysis positioned *S. masoni* sequences in the same branch as other *Sarcocystis* spp. using canids as definitive hosts. Therefore, based on this molecular finding and the results of dog infection with heart muscles containing ‘microscopic’ sarcocysts (Leguía *et al.* 1989), it is possible to suggest that *S. masoni* used canids as definitive hosts.

With respect to molecular characterization and comparison of different 18S rRNA gene fragment sequences from macroscopic cysts a high-sequence identity ($\geq 99\%$) was observed among the obtained from different SAC samples as well as with the sequences reported on the GenBank as *S. aucheniae*

from llamas and guanaco from Argentina (KF383266, KF383267, KF3832668 and KT382799) and an alpaca in Australia (AF017123) (Holmdahl *et al.* 1999; Carletti *et al.* 2013; Regensburger *et al.* 2015). Interestingly, when analysed phylogenetically, *S. aucheniae* sequences aligned in a separated branch from other *Sarcocystis* spp. which used canids as definitive host. A similar phylogenetical construction and observation was previously achieved (Holmdahl *et al.* 1999; Carletti *et al.* 2013; Moré *et al.* 2014b).

In conclusion, 2 morphologically and molecularly different *Sarcocystis* species, *S. masoni* (microscopic cysts) and *S. aucheniae* (macroscopic cysts), were identified affecting different SAC from Argentina and Peru. Further studies are needed in order to identify natural infected definitive hosts for *S. masoni* and *S. aucheniae*.

ACKNOWLEDGEMENTS

We would like to thank Isidoro Ercoli, Marco Quispe Huacho and Roxana Peralta for their excellent technical assistance.

FINANCIAL SUPPORT

Financial support was partially obtained through *Agencia Nacional de Promoción Científica y Tecnológica* (PICT2012-0506), Argentina (GM); and by a researcher exchange program PE13-05 MINCYT-CONCYTEC (Argentina-Peru, GM and MESM).

CONFLICT OF INTEREST

The authors declare that they have no conflict of interest.

REFERENCES

- Ayala, C. (1999). Estudio detallado de la ocurrencia de *Sarcocystis* en el altiplano Boliviano. In *3rd European Symposium and Supreme European Seminar* pp. 181–185. EAAP Publication, Göttingen, Germany.
- Beldomenico, P. M., Uhart, M., Bono, M. F., Marull, C., Baldi, R. and Peralta, J. L. (2003). Internal parasites of free-ranging guanacos from Patagonia. *Veterinary Parasitology* **118**, 71–77.
- Brumpt, E. (1913). *Precis de Parasitologie*, 2nd Edn. Masson et cie, Paris, France.
- Carletti, T., Martin, M., Romero, S., Morrison, D. A., Marcoppido, G., Florin-Christensen, M. and Schnittger, L. (2013). Molecular identification of *Sarcocystis aucheniae* as the macrocyst-forming parasite of llamas. *Veterinary Parasitology* **198**, 396–400.
- Castro, J. (1974). *Sarcocystis aucheniae* en Llamas. *Revista Investigaciones Pecuarias IVITA (Perú)*, **3**, 91–92.
- Cornejo, R. B., Chavez, V. A., Leyva, V. V., Falcón, N. P., Panez, S. P. and Ticona, D. S. (2007). Relación entre el tamaño de los macroquistes de *Sarcocystis aucheniae* y su viabilidad en *Canis familiaris*. *Revista de Investigaciones Veterinarias del Perú* **18**, 76–83.
- Dubey, J. P., Cawthorn, R. J., Speer, C. A. and Wobeser, G. A. (2003). Redescription of the sarcocysts of *Sarcocystis rileyi* (Apicomplexa: Sarcocystidae). *Journal Eukaryotic Microbiology* **50**, 476–482.
- Dubey, J. P., Lane, E. P., van Wilpe, E., Suleman, E., Reininghaus, B., Verma, S. K., Rosenthal, B. M. and Mtshali, M. S. (2014). *Sarcocystis cafferi* n. sp. (Protozoa: Apicomplexa) from the African buffalo (*Syncerus caffer*). *Journal of Parasitology* **100**, 817–827.
- Dubey, J. P., Calero-Bernal, R., Rosenthal, B. M., Speer, C. A. and Fayer, R. (2015a). *Sarcocystosis of Animals and Humans*, 2nd Edn. CRC Press, Boca Raton, FL, USA.

- Dubey, J. P., Hilali, M., Van Wilpe, E., Calero-Bernal, R., Verma, S. K. and Abbas, I. E. (2015b). A review of sarcocystosis in camels and redescription of *Sarcocystis cameli* and *Sarcocystis ippeni* sarcocysts from the one-humped camel (*Camelus dromedarius*). *Parasitology* **142**, 1481–1492.
- Dubey, J. P., Hilali, M., Van Wilpe, E., Verma, S. K., Calero-Bernal, R. and Abdel-Wahab, A. (2015c). Redescription of *Sarcocystis fusiformis* sarcocysts from the water buffalo (*Bubalus bubalis*). *Parasitology* **142**, 385–394.
- Gabor, M., Gabor, L. J., Srivastava, M., Booth, M. and Reece, R. (2010). Chronic myositis in an Australian alpaca (*Lama pacos*) associated with *Sarcocystis* spp. *Journal of Veterinary Diagnostic Investigation* **22**, 966–969.
- Gorman, T. R., Alcaïno, H. A., Munoz, H. and Cunazza, C. (1984). *Sarcocystis* sp. in guanaco (*Lama guanicoe*) and effect of temperature on its viability. *Veterinary Parasitology* **15**, 95–101.
- Guerrero, C., Hernández, J. and Alva, J. (1967). *Sarcocystis* en Alpacas. *Revista Facultad de Medicina Veterinaria Universidad Nacional Mayor San Marcos (Peru)* **21**, 69–76.
- Holmdahl, O. J., Morrison, D. A., Ellis, J. T. and Huong, L. T. (1999). Evolution of ruminant *Sarcocystis* (Sporozoa) parasites based on small subunit rDNA sequences. *Molecular Phylogenetics and Evolution* **11**, 27–37.
- La Perle, K. M., Silveria, F., Anderson, D. E. and Blomme, E. A. (1999). Dalmeny disease in an alpaca (*Lama pacos*): sarcocystosis, eosinophilic myositis and abortion. *Journal of Comparative Pathology* **121**, 287–293.
- Leguía, G. and Casas, E. (1999). *Enfermedades parasitarias y atlas parasitológico de camélidos sudamericanos*, Primera edn. De Mar, Lima, Perú.
- Leguía, G., Guerrero, C., Sam, R. and Chavez, A. (1989). Infección experimental de perros y gatos con micro y macroquistes de *Sarcocystis* de alpacas. *Revista de Investigaciones Veterinarias del Perú* **5**, 10–13.
- Medrano, G., Hung, A. and Rubio, N. (2006). Detección molecular temprana de *Sarcocystis* en el animal vivo y su estudio filogenético basado en el análisis del gen SSU rRNA en alpacas en Perú. *Mosaico científico* **3**, 5–9.
- Mehlhorn, H. and Scholtyseck, E. (1973). [The fine structure of the cyst stages of *Sarcocystis tenella* (authors transl.)]. *Zeitschrift für Parasitenkunde* **41**, 291–310.
- Moré, G., Abrahamovich, P., Jurado, S., Bacigalupe, D., Marin, J. C., Rambeaud, M., Venturini, L. and Venturini, M. C. (2011). Prevalence of *Sarcocystis* spp. in Argentinean cattle. *Veterinary Parasitology* **177**, 162–165.
- Moré, G., Schares, S., Maksimov, A., Conraths, F. J., Venturini, M. C. and Schares, G. (2013). Development of a multiplex real time PCR to differentiate *Sarcocystis* spp. affecting cattle. *Veterinary Parasitology* **197**, 85–94.
- Moré, G., Pantchev, A., Skuballa, J., Langenmayer, M. C., Maksimov, P., Conraths, F. J., Venturini, M. C. and Schares, G. (2014a). *Sarcocystis sinensis* is the most prevalent thick-walled *Sarcocystis* species in beef on sale for consumers in Germany. *Parasitology Research* **113**, 2223–2230.
- Moré, G., Pantchev, N., Herrmann, D. C., Vrhovec, M. G., Ofner, S., Conraths, F. J. and Schares, G. (2014b). Molecular identification of *Sarcocystis* spp. helped to define the origin of green pythons (*Morelia viridis*) confiscated in Germany. *Parasitology* **141**, 646–651.
- Quiroga, D., Lombardero, O. and Zorrilla, R. (1969). *Sarcocystis tilopodi* n. sp. en guanacos (*Lama guanicoe*) de la Republica Argentina. *Gaceta Veterinaria* **31**, 67–70.
- Regensburger, C., Gos, M. L., Ctibor, J. and Moré, G. (2015). Morphological and molecular characteristics of *Sarcocystis aucheniae* isolated from meat of Guanaco (*Lama guanicoe*). *Journal of Food Quality and Hazards Control* **2**, 118–121.
- Rooney, A. L., Limon, G., Vides, H., Cortez, A. and Guitian, J. (2014). *Sarcocystis* spp. in llamas (*Lama glama*) in Southern Bolivia: a cross sectional study of the prevalence, risk factors and loss in income caused by carcass downgrades. *Preventive Veterinary Medicine* **116**, 296–304.
- Schnieder, T., Kaup, F. J., Drommer, W., Thiel, W. and Rommel, M. (1984). [Fine structure and development of *Sarcocystis aucheniae* in llamas]. *Zeitschrift für Parasitenkunde* **70**, 451–458.
- Taylor, M. A., Coop, R. L. and Wall, R. L. (2007). *Veterinary Parasitology*. Blackwell Publishing, Oxford, UK, Ames, Iowa.
- Zacarias, F. S., Sam, R. T., Ramos, D. D., Lucas, O. A. and Lucas, J. L. (2013). Técnicas de aislamiento y purificación de oocistos de *Sarcocystis aucheniae* a partir de intestino delgado de perros experimentalmente infectados. *Revista Investigaciones Veterinarias del Perú* **24**, 396–403.