Journal of Fish Diseases 2013, **36**, 853–859 doi:10.1111/jfd.12083

Morphological aspects and histological effects of the attachment organ of *Parabrachiella* sp. (Copepoda: Lernaeopodidae) on the grey mullet, *Mugil liza* Valenciennes

S E Plaul[1], M M Montes[2], C G Barbeito[1] and S R Martorelli[2]

1 Facultad de Ciencias Veterinarias, Cátedra de Histología y Embriología, UNLP. La Plata, Bs. As., Argentina
2 CEPAVE (Centro de Estudios Parasitológicos y de Vectores), UNLP. La Plata, Bs. As., Argentina

Abstract

The genus *Parabrachiella* Wilson, 1915 (Lernaeopodidae) is represented by copepods that are highly adapted to a parasitic way of life. In Argentina, only *P. insidiosa var. lageniformis* Heller, 1865, *P. chevreuxii* Van Beneden, 1891 and *P. spinicephala* Ringuelet, 1945 have been cited, but none of these have been reported on mugilids. Recently, other species of this genus were found attached to the nasal cavities of juvenile grey mullets, *Mugil liza* Valenciennes, from Samborombón bay, Buenos Aires province. In this study, the prevalence and mean intensity of the *Parabrachiella* sp. on grey mullet is investigated. In addition, the damage the parasite imposes on its hosts is examined through evaluation of histological sections and immunostaining for proliferative cell nuclear antigen (PCNA). The morphology of the parasite's bulla is described from light and scanning electron micrographs.

Keywords: bulla, *Mugil liza*, nasal cavity, *Parabrachiella* sp., proliferative cell nuclear antigen (PCNA).

Introduction

Copepods of the family Lernaeopodidae are a successful group of parasites that are found mainly on marine fish (Benkirane, Coste & Raibaut 1999; Öktener & Trilles 2009) but have also been reported from certain freshwater species (Kabata 1992; Piasecki, Mlynarczyk & Hayward 2010). Only the adult females are parasitic (Schäperclaus 1991) and can be easily recognised by their morphology and mode of attachment. This involves the second maxillae which are modified and fused to a mushroom-shaped-anchoring structure known as the bulla (Benkirane *et al.* 1999; Piasecki *et al.* 2004). The morphology of the bulla shows great variability within the lernopodids. It is produced by the frontal gland of the cephalothorax during the larval stage and, once inserted into the tissue of the host, it fuses with the second maxillae and becomes a permanent attachment organ which allows the lernaeopodid to obtain its food (Kabata 1992; Castro & González 2005; Piasecki, Sękowska-Jakubowska & Sobecka 2006).

The genus *Parabrachiella* Wilson, 1915 includes 67 species (Piasecki *et al.* 2010). In Argentina, only three members of the genus *Parabrachiella* have been recorded as parasites of marine and brackish water species; *Neobrachiella chevreuxii* Van Beneden, 1891 (= *P. chevreuxii*) in *Micropogonias furnieri*, Scianidae (see Sardella, Etchegoin & Martorelli 1995; Alarcos & Etchegoin 2010), *N. insidiosa var. lageniformis* Heller, 1865 (= *P. insidiosa var. lageniformis*) in *Merluccius hubbsi*, Merlucidae (see Sardella & Timi, 1996) and *N. spinicephala* Ringuelet, 1945 (= *P. spinicephala*) in *Pinguipes brasilianus*, Pinguipidae (see Etchegoin, Timi & Lanfranchi 2006).

At present, there are few reports of histopathology associated with *Parabrachiella* attachment and feeding, and the aim of this study was to analyse

Correspondence *S E Plaul, Facultad de Ciencias Veterinarias, Cátedra de Histología y Embriología, UNLP. La Plata, Buenos Aires, Argentina (e-mail: splaul@museo.fcnym.unlp.edu.ar)*

Journal of Fish Diseases

the pathogenicity of these parasites and the morphological characteristics of the attachment organ. To investigate possible parasite induced damage to the host, histological sections through tissues at the site of parasite attachment were taken and immunohistochemistry was performed to evaluate proliferative cells. The study looks at the number of proliferating cells seen in the immediate vicinity of a parasite attaching and compares them with the number observed away from the point of parasite attachment and in uninfected co-specifics (Dezfuli *et al.* 2012). Furthermore, morphological characteristics of the bulla were observed under light microscopy and scanning electron microscopy (SEM).

Materials and methods

A total of one hundred and sixty-one juvenile specimens of juvenile grey mullet, *Mugil liza* Valenciennes (Mugilidae), were captured from two areas in the Samborombón Bay, Buenos Aires province, Argentina during 2009. Of these, sixty-five specimens were collected in the Salado river (35º50′S, 57º25′W) and ninety-six specimens in the Ajó river (36º 20′S, 56º 54′W) (Fig. 1). Limnological parameters such as water temperature, salinity, dissolved oxygen and pH were taken (Fig. 2).

In both cases, fish were collected using a modified Garlito/Bituron fixed net (Colautti 1998) and a haul net (10 m length with 5 mm stretched mesh in the wings and 2.5 mm stretched mesh in the cod ends). Fish were weighed, and the total length of each fish was recorded. Nasal, oral-branchial cavities and the external body surface of each mullet were examined for parasitic copepods. Parasites were counted, dissected from the host tissue with needles, fixed in a 3% glutaraldehyde in 0.1 M cacodylate buffer (pH 7.0) for 4 h at 4 °C, post-fixed for 1 h in 1% osmium tetroxide in 0.1 M cacodylate buffer and then dehydrated in a graded series of ethanol. Thereafter, specimens for the

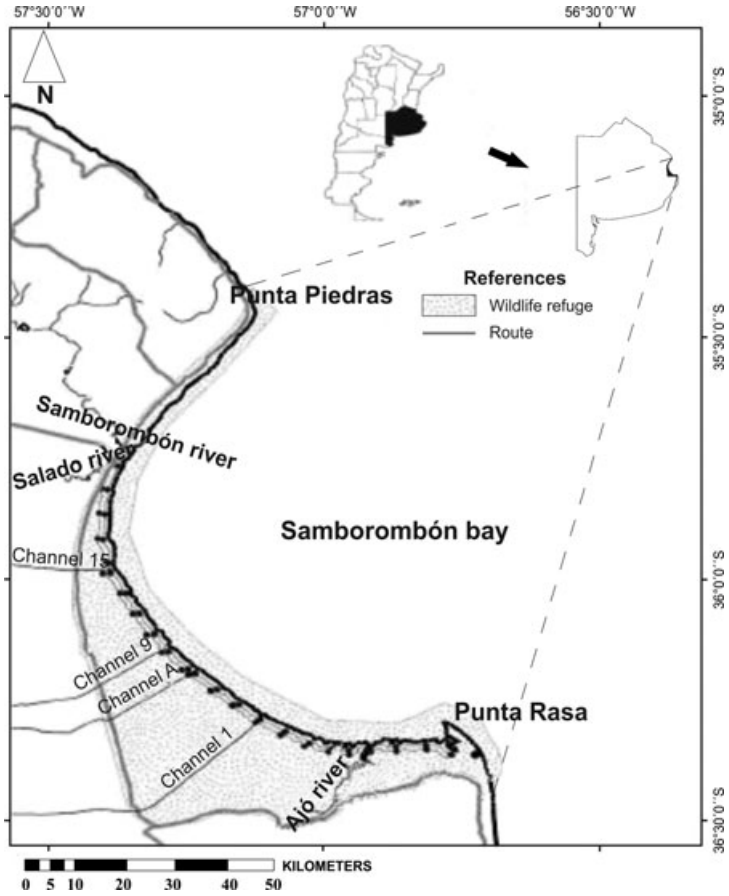

Figure 1 Position of the Salado and Ajó rivers within Samborombón Bay, Buenos Aires province.

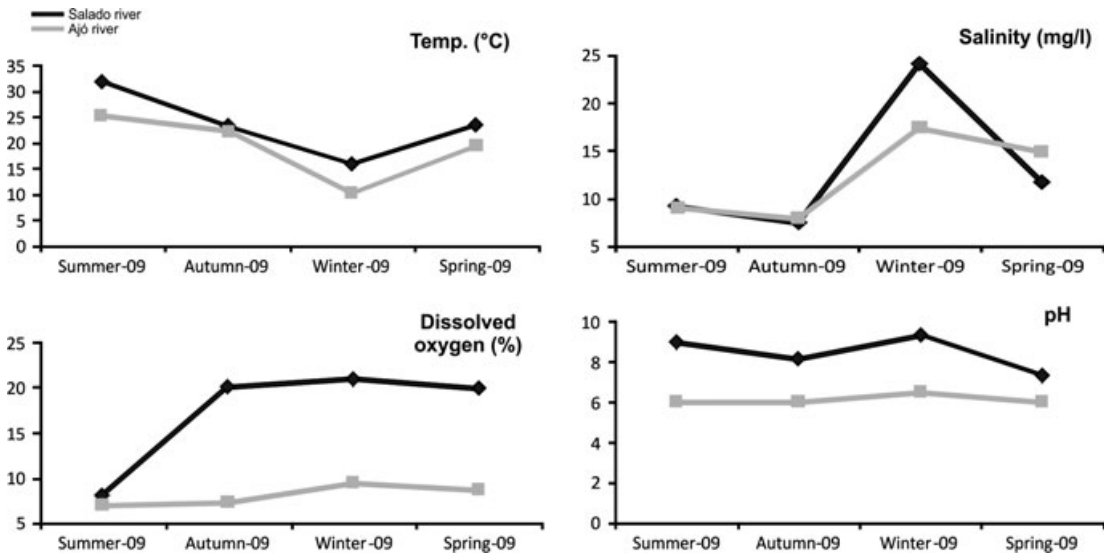

Figure 2 Environmental parameters of water in the Salado and Ajó rivers during 2009.

SEM study were critical point-dried and sputter-coated with gold. Specimens were viewed and photographed using Philips SEM 505 and Soft Imaging System ADDA II (SIS) software. Taxonomic identification of the collected specimens to the generic level was made using the keys of Kabata (1979) and Piasecki *et al.* (2010).

Additional infected specimens of grey mullet were fixed in 10% buffered formalin, and representative material was selected and processed for histological examination. Copepods collected from the nasal cavity were prepared for wax embedding and histology following standard methods. Histological sections were stained with haematoxylin and eosin and PAS technique. Cell proliferation within the sections was evaluated by immunohistochemistry using a monoclonal PCNA antibody (19F4, Boehringer) following the procedure of Ortego *et al.* (1994). Afterwards, the sections were counter-stained with haematoxylin.

The prevalence and intensity of infection (Margolis *et al.* 1981) were calculated for each parasite species in relation to the number of fish infected $\times$100/total number of fish and the total number of parasites/total number of infected fish, respectively (Table 1).

Results

A total of 228 adult females of the family Lernaeopodidae were found attached to the nasal cavity wall of the grey mullet, *M. liza*. According to the morphology of the second maxilla and the presence of posterior processes, these specimens were assigned to the genus *Parabrachiella*. Similarities between species make it extremely difficult to distinguish one species from another, but a high-resolution analysis of the posterior margin of the trunk revealed significant differences in the anal region.

All parasitized fish were found in March, prevalence and intensity in both rivers are shown in Table 1. The limnological parameters (Fig. 2) indicated that during the summer, both rivers have high temperature and low salinity levels. Unlike the Salado river, the Ajó river has a low concentration of dissolved oxygen and a slightly acidic pH, which may explain the higher observed prevalence of the parasite (49%).

Table 1 Prevalence and intensity of *Parabrachiella* sp. from *Mugil liza*

	Number of mullet examined	Size range, cm	Weight, g	Prevalence	Intensity
Salado river	65	2.13–19.17	0.22–67.53	1.53%	6.00
Ajó river	96	3.64–23.40	1.05–398.61	49.00%	2.31

Pathology

Pathogenicity of the parasite was low; the infected fish showed no macroscopic signs of damage at the attachment sites, where no haemorrhage was observed. Evaluation of histological sections by light microscopy showed that alterations in the tissue were consistent with a chronic process. Histological examination revealed local hyperplasia due to irritation caused by the parasite in the attachment site. The bulla of the parasite crosses the epidermis and fixes to the surface of the dermis. Opposed to this site, where the parasite is supported, atrophy in the epithelium of the nasal cavity wall was observed (Fig. 3). Near the point of attachment, cellular infiltration of lymphocytes, eosinophilic granule cells and rodlet cells were detected as part of the host's inflammatory response (Fig. 4). Although mucous cells were present in the epidermis, their number and size were not affected. The immunohistochemical technique showed that there were numerous PCNA-positive nuclei in both the basal/germinal and middle stratum of the epidermis as compared to the levels seen in uninfected (control) hosts (Fig. 5).

Structure of the parasite's attachment organ

SEM microphotographs show that the elongated second maxillae remain separate except for the distal end where they fuse forming a ring around the bulla, in which marks of the maxillary suture can be seen (Fig. 6). Light microscopy showed that the bulla, the attachment organ, penetrates the nasal cavity tissue where it is deeply embedded (Fig. 7a). This organ is composed mainly of two parts, a manubrium and an anchor. The manubrium, long and cylindrical, is connected posteriorly to the tips of the second maxillae and, anteriorly, it is expanded forming the anchor which has the shape of a thin cup excavated in the centre and flattened along its whole surface (Fig. 7b). The matrix of the bulla, in longitudinal section, showed the presence of canals crossing the manubrium that opens at the anchor in several pores displayed in a regular circle (Fig. 7 inset). The presence of fibres that stain intensely with eosin and PAS was also detected.

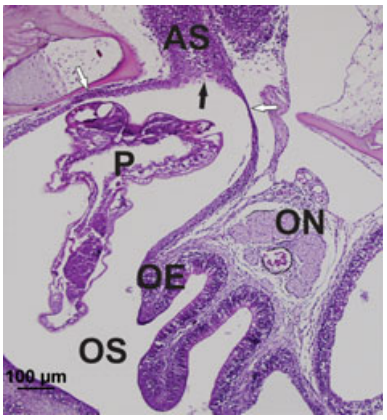

Figure 3 Position of *Parabrachiella* sp. within the nasal cavity of its host *Mugil liza*. Areas of hyperplasia (black arrow) are evident close to the point of parasite attachment (AS). The area where the parasite is attached shows signs of atrophy in the epithelium (white arrows). AS, attachment site; OE, olfactory epithelium; ON, olfactory nerve; OS, olfactory sac; P, parasite.

Discussion

In mugilids, only two species of *Parabrachiella* have been reported: *P. mugilis* Kabata, Raibaut & Ben Hassine, 1971 from *Liza aurata* and *L. saliens* (see Kabata, Raibaut & Ben Hassine 1971; Benkirane *et al.* 1999) in the Palearctic region and *N. exilis* Shiino, 1956 (= *P. exilis*) from *M. platanus* (= *M. liza*) (see Knoff, Luque & Takemoto 1994; Knoff, Luque & Amato 1997) and *M. cephalus* (Castro Romero & Baeza Kuroki 1986) from Brazil and Chile, respectively, in the Neotropical region. *Parabrachiella* sp. from the grey mullet is the first species of the genus reported parasitizing the nasal cavities. This microhabitat is remarkable because *P. mugilis* and *P. exilis* were reported parasitizing the gills and fins. Members of the genus have, however, been recorded as parasites of the branchial and oral cavities in some marine fish such as *Paralichthys californicus* (see Piasecki 1993), *M. furnieri* (see Sardella *et al.* 1995; Alarcos & Etchegoin 2010), and *Trigla lucerna* (see Benkirane *et al.* 1999).The implications of this parasitosis for farmed, ornamental and wild fish in Argentina are unknown.

The morphology of the bulla varies markedly within lernaeopodids, but this morphology is quite stable among the species of a genus. Kabata & Cousens (1972) concluded that the morphology is linked with the type of host and distinguished three types of bullae which correspond to three types of hosts: freshwater teleosts, marine teleosts and Elasmobranchii. The bulla of *Parabrachiella* sp. is included within type II found in

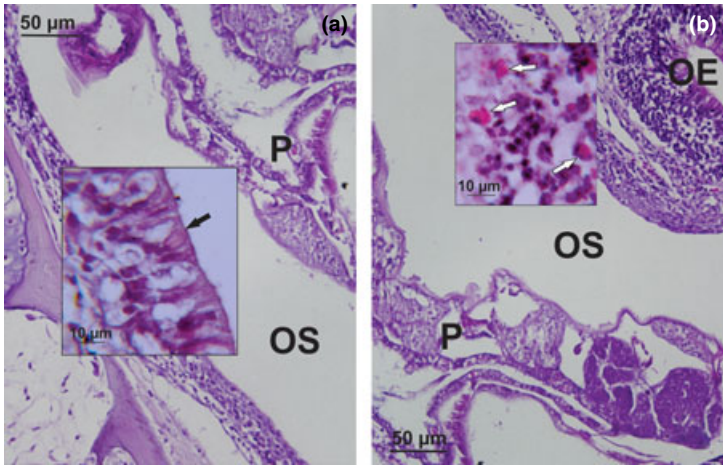

Figure 4 Cellular infiltration found in the epithelium as part of the inflammatory response of the host. (a) Rodlet cells (black arrow). (b) Eosinophilic granule cells (white arrows). In both images, an infiltration of lymphocytes can be seen. OE, olfactory epithelium; OS, olfactory sac; P, parasite.

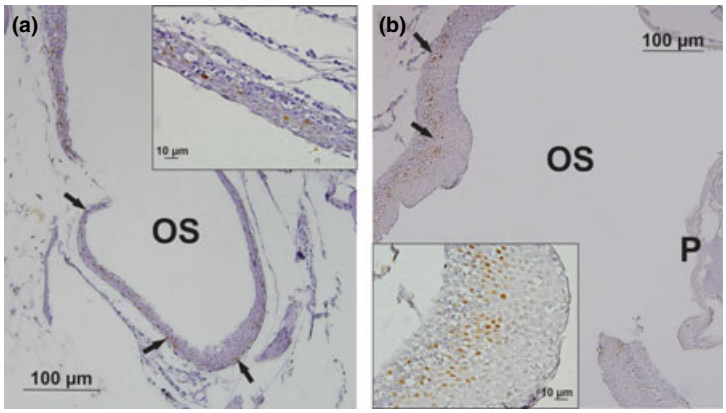

Figure 5 Immunohistochemical characterization of PCNA labelled nuclei in the nasal cavity of *Mugil liza*. (a) In the control group, proliferating nuclei (PCNA-positive) can be seen in a few cells in the basal area of the olfactory sac epithelium (arrows). Inset: detail of epithelium at higher magnification. (b) In the treated group, PCNA-positive cells can be seen in both the basal and middle stratum of the epidermis (arrows). Inset: detail of epithelium at higher magnification. OS, olfactory sac; P, parasite.

marine fish. These bullae are consistent with species attached to the tegument and are characterized by large-diameter cups flattened on the host tissues (Benkirane *et al.* 1999).

The pathogenicity of the parasite is low, but lesions that are consistent with a chronic process can be seen. This group is characterized by their relatively large size, and their attachment mechanism, however, its species seem to inflict less damage than other parasitic copepods like *Lernaea* or *Ergasilus*. Disturbances in the environment, as well as differentiation and degeneration, are the main factors affecting the cellular components of the epidermis (Kang *et al.* 1998; Nolan *et al.* 2000). The skin is the first barrier of protection of the body against pathogens; however, few studies have been performed in this organ associated with cell proliferation. The light-microscopical lesions described in the current study resulted in local hyperplasia due to irritation caused by the parasite in the attachment site. Coinciding with these results, the immunohistochemical technique marking PCNA was intense mainly in the middle stratum of the mullet's nasal cavity epithelium. Changes in the expression of PCNA can provide an early indication of deviations to normal functioning. Dezfuli *et al.* (2012) have observed that the number of PCNA-positive cells in regions close to the point

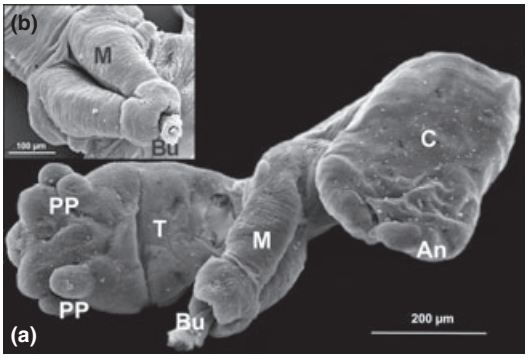

Figure 6 (a) A scanning electron micrograph of a female *Parabrachiella* sp. ×130. (b) Extremity of second maxillae with bulla, ×250. Note that the elongated second maxillae (M) remain separated and unite only at their distal end around the bulla (Bu). An, antenna; Bu, bulla; C, cephalosome; M, maxillae; PP, posterior processes; T, trunk.

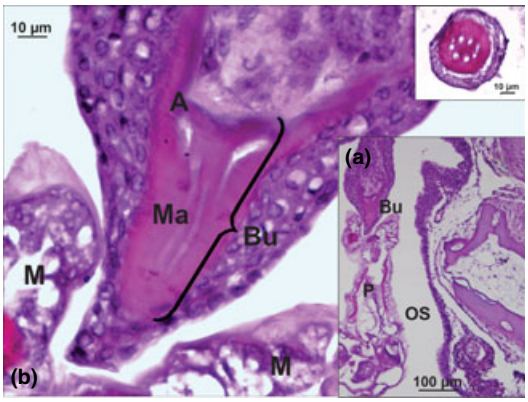

Figure 7 (a) Insertion of *Parabrachiella* sp. into the tegument of the olfactory sac of its host *Mugil liza*. (b) Bulla composed of two parts, manubrium and anchor. Inset: detail of the anchor, the latter is crossed by several canals displayed in a regular circle. A, anchor; Bu, bulla; M, maxillae; Ma, manubrium; OS, olfactory sac; P, parasite.

of parasite attachment was significantly higher than the number observed in uninfected individuals. The present work as well as the previous study mentioned demonstrated that increased cell proliferation is a general reaction produced by parasite attachment. The general condition of the fish sampled in this study was not evaluated but because other lernaeopodids have been documented to reduce the egg production of hatchery rainbow trout (Gall, McClendon & Schafer 1972), it is desirable to assess the impact of this parasite on the growth, maturation, and physiology of the host (Nagasawa & Urawa 2002).

The final effects depend, however, on more than one factor and are influenced by the intensity of infection, the site affected and often by environmental parameters such as temperature, oxygen and salinity level (Kabata 1992). According to Johnson *et al.* (2004), temperature is the most important environmental factor controlling the developmental time of parasitic copepods and the rate at which their population size increases in the absence of treatments. We observed that these three factors together with the pH are related to prevalence of the parasite. In the case of the Ajo river, low concentrations of dissolved oxygen together with high temperatures and low salinity seem to make fish more prone to parasitic infections. The prevalence and intensity of infection in the current study significantly declined in late autumn, which coincides with the decreasing water temperature and the observations made in other similar studies (Plaul, García Romero & Barbeito 2010).

The present study is the first report of the effects of the *Parabrachiella* sp. penetration in the catadromous fish *M. liza.* The results may contribute to the implementation of appropriate treatments for different types of physiological changes and the development of preventive techniques in fish farming. This is very important due to the development of aquaculture in many South American countries (Poquet 1979).

Acknowledgements

We would to thank to Lic. Agustin Solari for providing samples of juveniles *M. liza* and Felicia Cardillo for helping in *Parabrachiella* collection. We also thank Drs Federico Lozano and Pablo Marino for reading the MS.

References

Alarcos A.A. & Etchegoin J.A. (2010) Parasite assemblages of estuarine-dependent marine fishes from Mar Chiquita coastal lagoon (Buenos Aires Province, Argentina). *Parasitology Research* **107**, 1083–1091.

Benkirane O., Coste F. & Raibaut A. (1999) On the morphological variability of the attachment organ of Lernaeopodidae (Copepoda: Siphonostomatoida). *Folia Parasitologica* **46**, 67–75.

Castro R. & González M.T. (2005) *Clavellotis sebastidis* sp. nov. (Copepoda, Lernaeopodidae) parasitic on *Sebastes oculatus* Valenciennes, 1833 from Argentina. *Acta Parasitologica* **50**, 74–79.

Castro Romero R. & Baeza Kuroki H. (1986) Some species of *Neobrachiella* Kabata, 1979 (Copepoda: Lernaopodidae) parasitic on Chilean fishes, with description of *Neobrachiella paralichthyos* sp. nov. from *Paralichthys adspersus* (Syteindachner). *Crustaceana* **51**, 245–253.

Colautti D. (1998) Sobre la utilización de trampas para peces en las lagunas pampásicas. *Revista de Ictiología* **6**, 17–23.

Dezfuli B.S., Giari L., Lui A., Squerzanti S., Castaldelli G., Shinn A.P., Manera M. & Lorenzoni M. (2012) Proliferative cell nuclear antigen (PCNA) expression in the intestine of *Salmo trutta trutta* naturally infected with an acanthocephalan. *Parasites & Vectors* **5**, 198. doi: 10.1186/1756-3305-5-198

Etchegoin J.A., Timi J.T. & Lanfranchi A.L. (2006) Redescription of *Neobrachiella spinicephala* (Ringuelet, 1945) parasitic on *Pinguipes brasilianus* Cuvier. *Acta Parasitologica* **51**, 290–293.

Gall G.A.E., McClendon E.L. & Schafer W.E. (1972) Evidence on the influence of the copepod (*Salmincola californiensis*) on the reproductive performance of a domestical strain of rainbow trout (*Salmo gairdneri*). *Transactions of the American Fisheries Society* **101**, 345–346.

Johnson S.C., Treasurer J.W., Bravo S., Nagasawa K. & Kabata Z. (2004) A review of the impact of parasitic copepods on marine aquaculture. *Zoological Studies* **43**, 229–243.

Kabata Z. (1979) *Parasitic Copepoda of British Fishes*. pp. 468, The Ray Society, The British Museum, London.

Kabata Z. (1992) Copepods parasitic on fishes: keys and notes for identification of the species. In: *Synopses of the British Fauna (New Series) N° 47*. (ed. by D.M. Kermack, R.S.K. Barnes & J.H. Crothers Editors), pp.264. The Linnean Society of London and the Estuarine and Coastal Sciences Association, Oegstgeest, Netherlands.

Kabata Z. & Cousens B. (1972) The structure of the attachment organ of Lernaeopodidae (Crustacea: Copepoda). *Journal of the Fisheries Research Board of Canada* **29**, 1015–1023.

Kabata Z., Raibaut A. & Ben Hassine O.K. (1971) *Eubrachiella mugilis* n. sp., un copepode parasite de muges de Tunisie. *Bulletin de l'Institut National Scientifique et Technique d'Oceanographie et de Peche de Salammbo* **2**, 87–93.

Kang W.S., Moon Y.W., Han J.W., Park N.G. & Kim H.H. (1998) Induced epidermal cell turnover in the seawater-adapted guppy, *Poecilia reticulata*. *Korean Journal of Biological Sciences* **2**, 521–527.

Knoff M., Luque J.L. & Takemoto R.M. (1994) Parasitic copepods on *Mugil platanus* Günther (Osteichthyes: Mugilidae) from the coast of the State of Rio de Janeiro, Brazil. *Revista Brasileira de Parasitologia Veterinária* **3**, 45–56.

Knoff M., Luque J.L. & Amato J.F.R. (1997) Community ecology of the metazoan parasites of grey mullets, *Mugil platanus* (Osteichthyes: Mugilidae) from the littoral of the State of Rio de Janeiro, Brazil. *Revista Brasileira de Biologia* **57**, 441–454.

Margolis L., Esch G.W., Colmes J.C., Curie A.M. & Schad G.A. (1981) The use of ecological terms in parasitology. *The Journal of Parasitology* **68**, 133.

Nagasawa K. & Urawa S. (2002) Infection of *Salmincola californiensis* (Copepoda: Lernaeopodidae) on juvenile masu salmon (*Oncorhynchus masou*) from a stream in Hokkaido. *Bulletin of the National Salmon Resources Center* **5**, 7–12.

Nolan D.T., Hadderingh R.H., Spanings F.A.T., Jenner H.A. & Wendelaar Bonga S.E. (2000) Effects of short-term acute temperature elevation on sea trout smolts (*Salmo trutta* L.) in tap water and in Rhine water: effects on skin and gill epithelia, hydromineral balance and gill specific Na^+K^+-ATPase activity. *Canadian Journal of Fisheries and Aquatic Sciences* **57**, 708–718.

Öktener A. & Trilles J.P. (2009) Four parasitic copepods on marine fish (Teleostei and Condrichthyes) from Turkey. *Acta Adriatica* **50**, 121–128.

Ortego L.S., Hawkins W.E., Walker W.W., Krol R.M. & Benson W.H. (1994) Detection of proliferating cell nuclear antigen in tissue of three small fish species. *Biotechnic and Histochemistry* **69**, 317–323.

Piasecki W. (1993) Description of *Neobrachiella* sp. (Copepoda, Siphonostomatoida, Lernaeopodidae) parasitic in the buccal cavity of California halibut (*Paralichthys californicus*). *Wiadomos'ci Parazytologiczne* **39**, 149–153.

Piasecki W., Goddwin A.E., Eiras J.C. & Nowak B.F. (2004) Importance of Copepoda in freshwater aquaculture. *Zoological Studies* **43**, 193–205.

Piasecki W., Sękowska-Jakubowska A. & Sobecka E. (2006) Comparative description of males of two species of *Achtheres* von Nordmann, 1832 (Copepoda: Siphonostomatoida: Lernaeopodidae) infecting zander and European perch. *Folia Parasitologica* **53**, 211–216.

Piasecki W., Mlynarczyk M. & Hayward C.J. (2010) *Parabrachiella jarai* sp. nov. (Crustacea: Copepoda: Siphonostomatida) parasitic on *Sillago sihama* (Actinopterygii: Persiformes: Sillaginidae). *Experimental Parasitology* **125**, 55–62.

Plaul S.E., García Romero N. & Barbeito C.G. (2010) Distribution of the exotic parasite, *Lernaea cyprinacea* (Copepoda, Lernaeidae) in Argentina. *Bulletin of the European Association of Fish Pathologists* **30**, 65–73.

Poquet M. (1979) Aportaciones al estudio morfológico de algunas especies de copépodos de peces del litoral mediterráneo. *Miscelanea Zoologica* **5**, 161–171.

Sardella N.H. & Timi J.T. (1996) Parasite communities of *Merluccius hubbsi* from the Argentinian-Uruguayan common fishing zone. *Fisheries Research* **27**, 381–388.

Sardella N.H., Etchegoin J.A. & Martorelli S.R. (1995) Parasite community of *Micropogonias furnieri* (whitemouth croaker) in Argentina. *Boletim del Instituto Oceanografico de Venezuela* **34**, 41–47.

Schäperclaus W.(1991) Diseases caused by copepods. In: *Fish Diseases Vol.2* (ed. by W. Schäperclaus, H. Kulow & K. Schreckenbach), pp. 908–913. Published for the U.S. Department of the Interior and the National Science Foundation, Washington, DC. Amerind, New Delhi.

Received: 27 September 2012
Revision received: 7 December 2012
Accepted: 7 December 2012

