




ELSEVIER

Contents lists available at ScienceDirect

IJP: Parasites and Wildlife

journal homepage: [www.elsevier.com/locate/ijppaw](http://www.elsevier.com/locate/ijppaw)

# Pathology associated with larval *Eustrongylides* sp. (Nematoda: Dioctophymatoidea) infection in *Galaxias maculatus* (Actinopterygii: Galaxiidae) from Patagonia, Argentina

Silvia Guagliardo<sup>a</sup>, Gustavo Viozzi<sup>b,\*</sup>, Norma Brugni<sup>b</sup>

<sup>a</sup> Laboratorio de Patología de Organismos Acuáticos- Dep. Biología, Bioquímica y Farmacia, Universidad Nacional del Sur, San Juan, 670, 8000, Bahía Blanca, Argentina

<sup>b</sup> Laboratorio de Parasitología, INIBIOMA (Universidad Nacional del Comahue-CONICET), Quintral 1250, 8400, Bariloche, Argentina

## ARTICLE INFO

### Keywords:

Nematoda  
*Eustrongylides* sp.  
*Galaxias maculatus*  
Histopathology

## ABSTRACT

Helminth infections within tissues tend to be subjected to a host response that can include encapsulation and melanization to isolate the parasite. The effectiveness of this response depends on the host species. During a survey of parasites of the native fish, *Galaxias maculatus*, we found conspicuous, strongly melanized exterior cysts located in the caudal peduncle of the fish. Dissection of these cysts exposed larval nematodes whose morphometrical features allowed their identification as *Eustrongylides* sp. Species of this genus are distributed worldwide. *Galaxias maculatus* was previously reported as second intermediate host to *Eustrongylides* sp. larvae, and the aquatic bird *Podiceps major* was cited as definitive host of *Eustrongylides tubifex* in Andean Patagonian lakes. The site of infection in the fish, and the host's response are unique among infections by larvae of *Eustrongylides* sp. in fishes, so the objective of this study was to describe the histological injury caused by larvae of the genus *Eustrongylides* parasitizing *G. maculatus*. Samples of fish were taken near the shore of Gutiérrez lake, in northwestern Patagonia. Some larval morphometric features were described to confirm the identity of larvae to generic level. Histopathological analysis (tissues sectioned at 5–7 μm, stained with Hematoxylin and Eosin, and Masson's Trichrome) of the caudal peduncle revealed almost complete disappearance of the epaxial musculature due to compressive atrophy and a chronic inflammatory response, associated mainly with a dense fibrotic capsule and an intense melanin deposit. This is the first description of the histopathology of an external cyst caused by *Eustrongylides* sp. larvae in fishes.

## 1. Introduction

Parasitic infections in fish can cause changes in behavior, vulnerability to predators, and a reduced capacity to resist stress (Coyner et al., 2001; Moore, 2002; Poulin, 2010; Hammond-Tooke et al., 2012). The presence of a parasite generates a host strategy of inactivation or elimination through cellular and humoral responses, which range from acute or chronic inflammation to severe necrosis (Feist and Longshaw, 2008; Mitchell et al., 2009). Helminth infections within tissues tend to be subjected to a host response that can include encapsulation and melanization to isolate the parasite; the effectiveness of this response depends on the fish species (Feist and Longshaw, 2008).

*Galaxias maculatus* (Jenyns, 1842) is a small prey fish with an exceptionally disjunct distribution, occurring in Australia, Tasmania, Lord Howe Island, New Zealand, Chatham Island, and the south of Chile and Argentina (McDowall, 2006). This fish was reported as host to

*Eustrongylides* spp. in New Zealand (Hine, 1978), Australia (Pollard, 1974; Chapman et al., 2006), and Argentinean Patagonia (Brugni and Viozzi, 1999, 2003). Since the larval forms cannot be identified at species level, they are usually designated as *Eustrongylides* sp. Brugni and Viozzi (1999, 2003) found larvae of *Eustrongylides* sp. in the caudal peduncle musculature of *Galaxias maculatus* from Lake Gutiérrez and Lake Moreno, both located in Nahuel Huapi National Park. These larvae were used to perform experimental infections in chicks, obtaining immature adults which showed morphological characteristics similar to *E. tubifex* (Nitzsch, 1819) (Brugni and Viozzi, 1999), in accordance with the finding of an ovigerous female of *E. tubifex* in the proventriculus of *Podiceps major* from Moreno lake (Brugni and Viozzi, 2003).

The life cycle of *Eustrongylides* spp. involve an aquatic oligochaete, a fish, and a piscivorous bird. The larvae migrate from the digestive tract of the fish to the cavity or the musculature of the body wall, and have mostly been reported encysted in thin, white or yellowish-pink fibrous

\* Corresponding author. Universidad Nacional del Comahue, Quintral 1250, 8400, Bariloche, Río Negro, Argentina.

E-mail addresses: [sguaglia@criba.edu.ar](mailto:sguaglia@criba.edu.ar) (S. Guagliardo), [gviozzi@gmail.com](mailto:gviozzi@gmail.com) (G. Viozzi), [normabrugni@gmail.com](mailto:normabrugni@gmail.com) (N. Brugni).

<https://doi.org/10.1016/j.ijppaw.2019.08.004>

Received 5 July 2019; Received in revised form 7 August 2019; Accepted 8 August 2019

2213-2244/ © 2019 The Authors. Published by Elsevier Ltd on behalf of Australian Society for Parasitology. This is an open access article under the CC BY-NC-ND license (<http://creativecommons.org/licenses/by-nc-nd/4.0/>).

collagenous cysts located in mesenteries, fatty tissues, the coelomic cavity, liver, spleen, stomach wall, gonads, around the intestinal tract, and musculature (Paperna, 1974; Cooper et al., 1978; Measures, 1988; Kristmundsson and Helgason, 2007; Mitchell et al., 2009; Mir et al., 2012). In *G. maculatus* from Australia, *Eustrongylides* sp. larvae were reported encysted on the outer surface of the stomach, ovaries, and in the abdominal cavity (Pollard, 1974, Chapman et al., 2006). In Patagonia, the larvae have always been found in conspicuous, external, and strongly melanized cysts on the caudal peduncle of *G. maculatus* (Brugni and Viozzi, 1999, 2003; Viozzi et al., 2009), which is an atypical localization and fish reaction. Previous studies on the histopathology of infection by *Eustrongylides* species in different fish species were carried out mainly on larvae localized in the abdominal cavity (Paperna, 1974; Kennedy and Lie, 1976; Eiras and Rego, 1988; Measures, 1988; Mir et al., 2012; Kaur et al., 2012).

Since the site of infection and the host's response are unique among infections by larvae of *Eustrongylides* sp. in fishes, the objective of this study was to describe the histological injury caused by larvae located in the caudal peduncle of *G. maculatus*.

## 2. Materials and methods

Specimens of *G. maculatus* were collected near the shore of Gutiérrez lake (41°10'S–71°24'W), northwestern Patagonia, in January and March 2018. Some fish were examined and the melanized cysts were dissected to observe the larvae. The larvae were fixed in 5% formal and cleared in Aman's Lactophenol. Morphometric characteristics were registered for third and fourth-stage larvae in order to confirm the generic identification (sensu Lichtenfels and Pilitt, 1986 and Measures, 1988). All measurements are expressed in micrometers ( $\mu\text{m}$ ) unless otherwise stated.

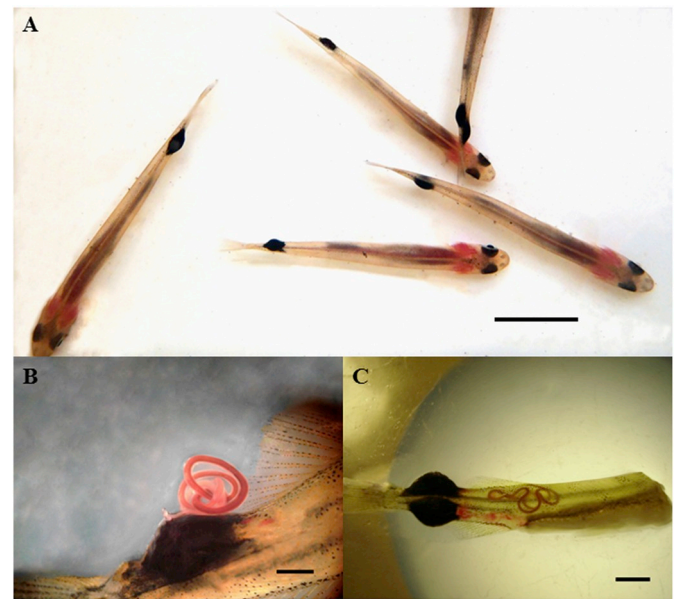
Two types of fish from the March sample were selected for histological purposes: 1) specimens without cyst, 2) specimens with cyst. The caudal peduncles of infected and uninfected fish were fixed immediately postmortem in 10% buffered formalin, dehydrated in a graded series of alcohols, embedded in paraffin, sectioned at 5–7  $\mu\text{m}$ , and stained with Hematoxylin and Eosin, and Masson's Trichrome. Microphotographs were obtained with a Motic BA200 microscope.

## 3. Results

A total of 600 fish were collected (42–59 mm long), twelve of which were infected in the caudal peduncle by encysted larvae of *Eustrongylides* sp. (prevalence = 2%). Ten fish showed one conspicuous, strongly melanized cyst, while the remaining infected fish had two cysts with only a single larva in each (mean intensity = 1.2) (Fig. 1 A). The cysts measured up to 5 mm in length and up to 3.9 mm in height, representing about 8% of the fish's total length. The cyst harbored 1 live, reddish larva of the third or fourth stage (Fig. 1 B). Cysts were not found in any other site on the body; however, when the host dies, the larva sometimes leaves the cyst and migrates through the musculature (Fig. 1 C).

All the larvae dissected from the January samples (4) were in the third stage of development, while the larvae dissected from the March sample (6) were in the fourth stage. The longest fourth-stage larva found measured 38 mm (Table 1). The remaining measurements of the third- and fourth-stage larvae are shown in Table 1. The body is dark red; the anterior end is conical and has two circles of labial papillae, with 6 papillae in each circle. The papillae of the exterior circle are larger than those of the inner circle and have wide bases with nipplelike apices, while the papillae of the inner circle have spinelike apices (Fig. 2 A). The posterior extremity is rounded and the anus and genital primordia are located terminally. Three cuticle layers are visible at the posterior extremity of the fourth-stage larvae (Fig. 2B).

The cross sections of a non-parasitized fish show the hypaxial and epaxial striated musculature intact around the spinal cord (Fig. 3A). In

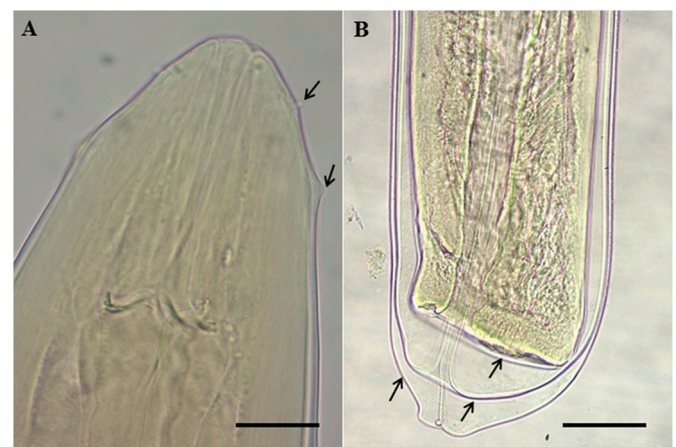


**Fig. 1.** A. specimens of *Galaxias maculatus* showing melanized cysts located in the caudal peduncle. Bar = 15 mm; B. larva of *Eustrongylides* sp. emerging from the cyst. Bar = 1.5 mm  $\mu\text{m}$ ; C. caudal peduncle of *Galaxias maculatus* showing 2 cysts, and a larva migrating through the musculature. Bar = 2.5 mm.

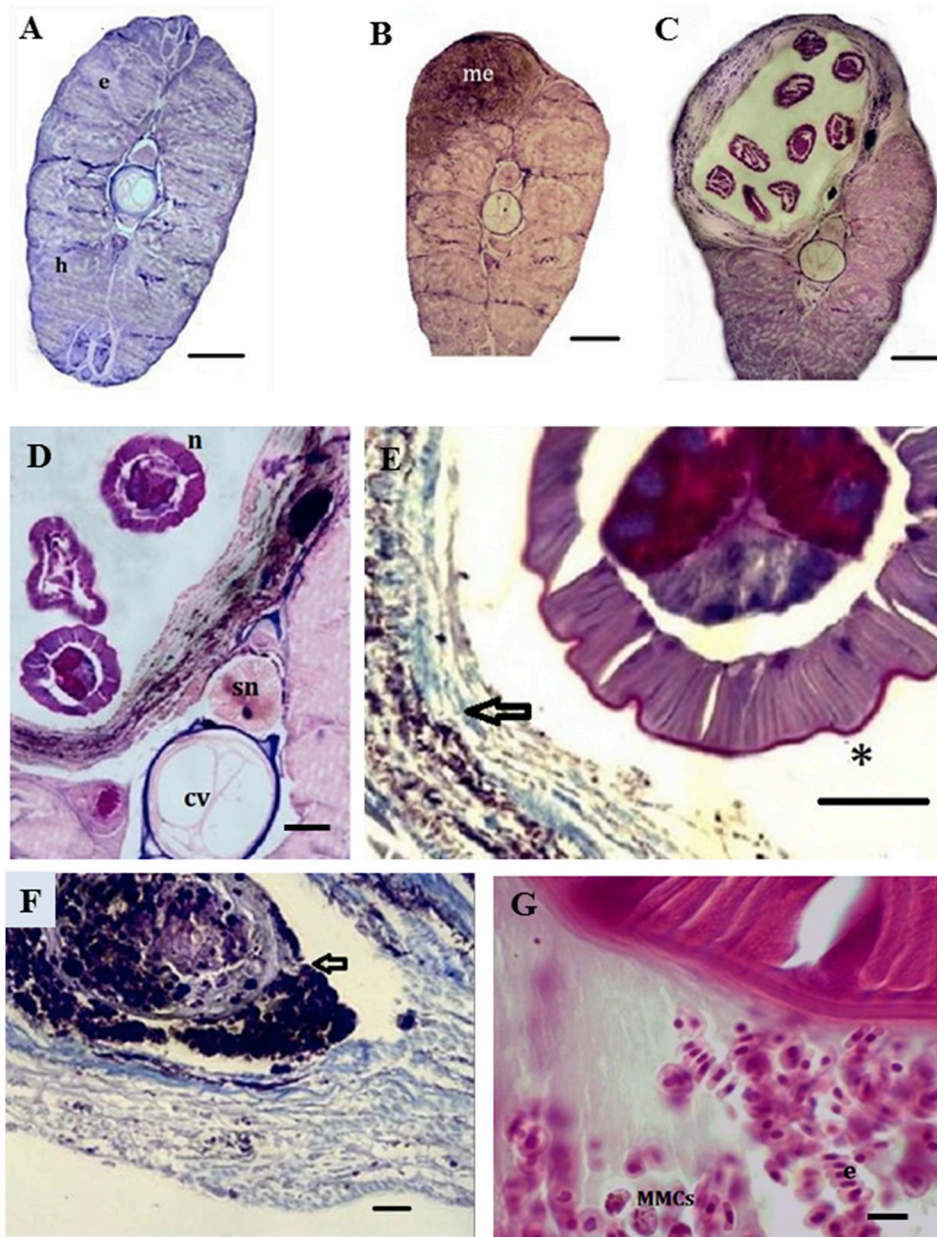
**Table 1**

Morphometrics of third- and fourth-stage larval *Eustrongylides* sp. from *Galaxias maculatus* from Gutiérrez Lake.

	Third-stage larvae				Fourth-stage larvae			
	mean	sd	min	max	mean	sd	min	max
Total length (mm)	16.3	1.5	15	18	34.4	3.4	30	38
Width at never ring	144.0	17.9	125	168	171.2	9.5	156	182
Papillae of external circle from anterior end	37.3	6.2	29	43	70.5	8.7	58	84
Nerve ring from anterior end	121.3	11.9	108	137	204.5	13.0	180	216
Buccal cavity length	72.5	9.0	60	79	142.8	19.8	120	175
Oesophagus length (mm)	5.2	0.7	5	6	12.7	2.0	10	15



**Fig. 2.** Fourth-stage larva of *Eustrongylides* sp. from *Galaxias maculatus*. A. anterior end. Bar = 40  $\mu\text{m}$ . Internal and external labial papillae (arrows); B. caudal extremity of male. Bar = 100  $\mu\text{m}$ . Note three cuticles, outer second stage, middle third stage, and inner fourth stage (arrows).



**Fig. 3.** A. cross section of non-parasitized fish: striated hypaxial (h) and epaxial (e) musculature, Masson's trichrome. Bar = 350  $\mu$ m; B. melanization (me) at one end of a cyst. Hematoxylin and Eosin. Bar = 350  $\mu$ m; C. fibrotic capsule around larvae and complete disappearance of the epaxial musculature Hematoxylin and Eosin. Bar = 200  $\mu$ m; D. compressive atrophy and fibrotic capsule around the parasites. cv: vertebral body, n: nematode, ns: neural spine, T. Masson. Bar = 90  $\mu$ m; E. dense collagenous fibrotic capsule (arrow), parasitic cuticle (asterisk). Bar = 50  $\mu$ m, F. melanin deposit (arrow). Masson's trichrome. Bar = 50  $\mu$ m, G. erythrocytes (e) and melanomacrophagic centers (MMCs) around the nematode. Bar = 8  $\mu$ m.

transverse sections at one end of the cyst, it can be seen that the injury extends through the epaxial muscles (Fig. 3B). The dorsal portion of the vertical septum is deviated from the normal position due to displacement caused by the cyst, which takes the place of the musculature. The melanic zone is distinguishable from normal muscle (Fig. 3B).

The section in the middle of the cyst shows several portions of the worm immersed in liquid, and surrounded by a fibrous cyst larger than the original muscular mass. In addition an almost total disappearance of the epaxial musculature, due to compressive atrophy, is observed (Fig. 3 C). High magnification shows a predominant collagenous cyst surrounding the parasite (Masson's Trichrome stain), with few inflammatory cells (Fig. 3D). Although the cross sections show a chronic response, the parasites were not affected (Fig. 3E). Within the fibrosis, melanic deposits are observed around necrotic tissue (Fig. 3F). Encapsulation is associated with hemorrhage immediately surrounding the encapsulated parasites. The presence of erythrocytes and melanomacrophagic centers (MMCs) can be observed (Fig. 3G).

#### 4. Discussion

The presence of 2 rings of 6 labial papillae and the rounded posterior extremity with terminal anus and genital primordium, along with the morphometrical features allowed us to assign the larvae to the genus *Eustrongylides* (Lichtenfels and Pilitt, 1986; Measures, 1988). The infection site, shape and measurements of these larvae are similar to those found in previous reports for the same host and environment (Brugni and Viozzi, 1999, 2003).

In *G. maculatus* from Victoria, Australia, Pollard (1974) registered a maximum number of 44 larval *Eustrongylides* sp. (sensu the author, probably *E. gadopsis*) per fish, and indicated inhibition or prevention of egg laying by female fish due to larvae encysted either in the vent region or within the ovary itself. These larvae have usually been observed coiled in somewhat flattened, thin-walled, fibrous connective-tissue cysts attached to various organs within the body cavity of the fish, but most frequently attached to the outer surface of the stomach (Pollard, 1974). In *G. maculatus* from southwestern Australia, Chapman et al. (2006) reported larval *Eustrongylides gadopsis* encysted in the inner body

wall. In the present study, the site of infection of *G. maculatus* with *Eustrongylides* sp. was invariably the skeletal musculature of the caudal peduncle, with complete commitment of muscle tissues, and low values of prevalence and intensity. Although the general appearance and structure of the cysts resembles the description given by Paperna (1974), Measures (1988), Dezfuli et al. (2015) and Branciarri et al. (2016) for inner cysts in the body wall muscles of other fish species, in the small galaxiid fish, *G. maculatus*, the parasite generates a conspicuous, strongly melanized cyst exposed to the exterior and complete disappearance of the musculature through compressive atrophy and a chronic inflammatory response, associated mainly with a dense fibrotic capsule and an intense melanic deposit. This response to the infection could lead to the fish becoming more easily recognizable prey for fish-eating birds, as found for *Eustrongylides ignotus* infecting mosquitofish (Coyner et al., 2001). These authors pointed out that the larvae of *E. ignotus* are large in size relative to the mosquitofish body size, and probably produce a physical and metabolic burden that may reduce and inhibit the fish's ability to avoid capture. The same kind of effect may occur in the case of *G. maculatus*, given the size ratio between the small fish and the larvae of *Eustrongylides* sp. In a small fish such as *G. maculatus*, the infection affects the muscle mass of the caudal peduncle, causing compression in the dorsal column, which could compromise the swimming ability of the fish.

Although the cross sections showed a chronic response, the parasites were not affected. The good condition of the microanatomy of the parasites inside the cysts shows that *G. maculatus* is a good intermediate host, where the strong encapsulation does not alter the viability of the parasite. The worms can sometimes emerge from the encapsulation and migrate to the musculature, causing hemorrhage in the muscles, as observed by Cooper et al. (1978) in high temperature conditions. In *Bagrus docmac*, Paperna (1974) observed extensive lysis around unencysted worms which had penetrated the body wall muscles and their sheaths of connective tissue.

Infections within tissues tend to be subjected to a host response that includes a granulomatous inflammatory reaction that encapsulates the parasite, irrespective of the organs infected, and can include melanization (Feist and Longshaw, 2008). In the present study we found that encapsulation is associated with hemorrhage and the presence of MMCs, leading to compressive atrophy and a chronic inflammatory response with an intense melanic deposit. The histopathology of an external cyst is described for the first time in response to larval infection of *Eustrongylides* sp in the muscles of fish.

#### Declarations of interest

None.

#### Acknowledgements

This study was funded by the following projects: 1) Parasitismo en ecosistemas patagónicos: invasiones y zoonosis, Universidad Nacional del Comahue, Argentina. UNCo B/225, 2) Invasiones ocultas: Los parásitos y la introducción de peces en la cuenca del Río Negro,

Argentina. CONICET. PIP GI.

#### References

- Branciarri, R., Ranucci, D., Miraglia, D., Valiani, A., Veronesi, F., Urbani, E., Franceschini, R., 2016. Occurrence of parasites of the genus *Eustrongylides* spp. (Nematoda: dioctophymatidae) in fish caught in Trasimeno lake. *Ital. J. Food Saf.* 5, 206–209.
- Brugni, N., Viozzi, G., 1999. Presence of *Eustrongylides* sp. (jagerskiöl, 1909) (nematoda: dioctophymatoidea) in *Galaxias maculatus* (Jenyns, 1842) (pisces: galaxiidae) from Patagonia, Argentina. *J. Helminthol. Soc. Wash.* 66, 92–94.
- Brugni, N., Viozzi, G., 2003. Presencia de *Eustrongylides tubifex* (Nematoda: dioctophymatoidea) en la Patagonia, Argentina. *Parasitol. Latinoam.* 58, 83–85.
- Chapman, A., Hobbs, R.P., Morgan, D.L., Gill, H.S., 2006. Helminth parasitism of *Galaxias maculatus* (Jenyns 1842) in southwestern Australia. *Ecol. Freshw. Fish* 15, 559–564.
- Cooper, C., Crites, J., Sprinkle Fastkie, D., 1978. Population biology and behavior of larval *Eustrongylides tubifex* (Nematoda: dioctophymatida) in Poikilothermous hosts. *J. Parasitol.* 64, 102–107.
- Coyner, D., Schaack, S., Spalding, M., Forrester, D., 2001. Altered predation susceptibility of mosquitofish infected with *Eustrongylides ignotus*. *J. Wildl. Dis.* 37, 556–560.
- Dezfuli, B.S., Manera, M., Lorenzoni, M., Pironi, F., Shinn, A.P., Giari, L., 2015. Histopathology and the inflammatory response of European perch, *Perca fluviatilis* muscle infected with *Eustrongylides* sp. (Nematoda). *Parasites Vectors* 8, 227.
- Eiras, J., Rego, A., 1988. Histopatología da parasitose de peixes do Rio Cuiabá (Mato Grosso) por larvas de *Eustrongylides* sp. (Nematoda, Dioctophymidae). *Rev. Bras. Biol.* 48, 273–280.
- Feist, S.W., Longshaw, M., 2008. Histopathology of fish parasite infections – importance. *J. Fish Biol.* 73, 2143–2160.
- Hammond-Tooke, C., Nakagawa, S., Poulin, R., 2012. Parasitism and behavioural syndromes in the fish *Gobiomorphus cotidianus*. *Behaviour* 149, 601–622.
- Hine, P.M., 1978. Distribution of some parasites of freshwater eels in New Zealand. *N. Z. J. Mar. Freshw. Res.* 12, 179–187.
- Kaur, P., Shrivastav, R., Qureshi, T., 2012. Pathological effects of *Eustrongylides* sp. larvae (Dioctophymatidae) infection in freshwater fish, *Glossogobius giuris* (Ham.) with special reference to ovaries. *J. Parasit. Dis.* 37 245–25.
- Kennedy, C., Lie, S., 1976. The distribution and pathogenicity of larvae of *Eustrongylides* (Nematoda) in brown trout *Salmo trutta* L. in Fernworthy Reservoir, Devon. *J. Fish Biol.* 8, 293–302.
- Kristmundsson, A., Helgason, S., 2007. Parasite communities of eels *Anguilla anguilla* in freshwater and marine habitats in Iceland in comparison with other parasite communities of eels in Europe. *Folia Parasitol.* 54, 141–153.
- Lichtenfels, J., Pilit, P., 1986. *Eustrongylides* sp. (nematoda: dioctophymatoidea): differentiation of third and fourth-stage larvae from killifish, *Fundulus* sp. collected in Chesapeake bay area. *U.S.A. Proc. Helminthol. Soc. Wash.* 53, 144–148.
- McDowall, R., 2006. Crying wolf, crying foul, or crying shame: alien salmonids and a biodiversity crisis in the southern cool-temperate galaxioid fishes? *Rev. Fish Biol.* 16, 233–422.
- Measures, L., 1988. Epizootiology, pathology, and description of *Eustrongylides tubifex* (Nematoda: dioctophymatoidea) in fish. *Can. J. Zool.* 66, 2212–2222.
- Mir, T., Kaur, P., Manohar, S., 2012. Pathogenic effects of nematode parasite *Eustrongylides* sp. larvae on serum LH level and histology of gonads of freshwater fish, *Clarias gariepinus*. *Recent Res. Sci. Technol.* 4, 24–26.
- Mitchell, A., Overstreet, R.M., Goodwin, A.E., 2009. *Eustrongylides ignotus* infecting commercial bass, *Morone chrysops* female X *Morone saxatilis* male, and other fish in the southeastern USA. *J. Fish Dis.* 32, 795–799.
- Moore, J., 2002. *Parasites and the Behavior of Animals*. Oxford University Press, Oxford, UK, pp. 338.
- Paperna, I., 1974. Host distribution and pathology of infections with larvae of *Eustrongylides* (Dioctophymidae, Nematoda) in fishes from East African lakes. *J. Fish Biol.* 6, 67–76.
- Pollard, D., 1974. The biology of a landlocked form of the normally catadromous salmoniform fish *Galaxias maculatus* (Jenyns). VI. Effects of Cestode and Nematode parasites. *Aust. J. Mar. Freshw. Res.* 25, 105–120.
- Poulin, R., 2010. Parasite manipulation of host behaviour: an update and frequently asked questions. *Adv. Stud. Behav.* 41, 151–186.
- Viozzi, G., Semenas, L., Brugni, N., Flores, V., 2009. Metazoan parasites of *Galaxias maculatus* (osmeriformes: galaxiidae) from argentinean Patagonia. *Comp. Parasitol.* 76, 229–239.