



# ARCHIVOS DE LA SOCIEDAD ESPAÑOLA DE OFTALMOLOGÍA

www.elsevier.es/ofthalmologia



## Original article

# Treatment of corneal ulcers with platelet rich plasma<sup>☆</sup>

L. Acosta<sup>a</sup>, M. Castro<sup>a</sup>, M. Fernandez<sup>a</sup>, E. Oliveres<sup>a</sup>, E. Gomez-Demmel<sup>a</sup>, L. Tartara<sup>b,\*</sup>

<sup>a</sup> Servicio de Oftalmología, Hospital Privado, Córdoba, Argentina

<sup>b</sup> Departamento de Farmacia, Facultad de Ciencias Químicas, Universidad Nacional de Córdoba, Córdoba, Argentina

### ARTICLE INFO

#### Article history:

Received 29 May 2013

Accepted 17 September 2013

Available online 24 May 2014

#### Keywords:

Corneal ulcers

Treatment

Platelet-rich plasma

Autologous serum

Rabbits

### ABSTRACT

**Objective:** To assess the efficacy of platelet rich plasma (PRP) in the treatment of extensive corneal ulcers in albino rabbits.

**Methods:** New Zealand rabbits, divided into three groups, were used for the study. Corneal ulcers of 10 mm diameter were made. Rabbits blood was extracted for the preparation of the PRP of the corresponding group. The blood was processed by differential centrifugation. The first group, named control, was treated with sterile saline every 8 h. The second group, named gel, was treated with deproteinized extract gel beef fat every 8 h, and the third group, named PRP received one PRP drop on the first and third day of monitoring. The rabbits were monitored, by taking photographs, each day for the 7 days that the study lasted.

**Results:** A better outcome was observed in the group with deproteinized extract gel beef fat (GE group), and the PRP group (PL group), in comparison with the control group (CO group) ( $P < 0.05$ ).

**Conclusion:** The PRP showed to be just as effective as the commercial product (Solcoseryl<sup>®</sup>), for the regeneration of the extensive and deep corneal ulcers. Besides, it stands out as there is no surgical procedure is required, and there is easy access, low cost and reduced doses.

© 2013 Sociedad Española de Oftalmología. Published by Elsevier España, S.L. All rights reserved.

## Tratamiento de úlceras corneales con plasma rico en plaquetas

### RESUMEN

**Objetivo:** Evaluar la eficacia del plasma rico en plaquetas (PRP) en el tratamiento de úlceras corneales no infecciosas extensas en conejos albinos.

**Métodos:** Para el estudio se utilizaron conejos New Zealand, divididos en 3 grupos. Se realizaron úlceras corneales de 10 mm de diámetro. Se extrajo sangre de los conejos para la preparación del PRP del grupo correspondiente. La misma fue procesada mediante centrifugación diferencial. El primer grupo, llamado control, fue tratado con solución salina estéril cada 8 h durante 7 días; el segundo grupo, llamado gel, fue tratado con un gel extracto desproteinizado de sangre de ternera (Solcoseryl<sup>®</sup>) cada 8 h durante 7 días y el tercer grupo,

#### Palabras clave:

Úlcera corneal

Tratamiento

Plasma rico en plaqueta

Suero autólogo

Conejos

<sup>☆</sup> Please cite this article as: Acosta L, Castro M, Fernandez M, Oliveres E, Gomez-Demmel E, Tartara L. Tratamiento de úlceras corneales con plasma rico en plaquetas. Arch Soc Esp Ophthalmol. 2014;89:48-52.

\* Corresponding author.

E-mail address: i.tartara@gmail.com (L. Tartara).

llamado PRP, recibió una gota del PRP el día 1 y el día 3 de seguimiento. Los controles fueron realizados diariamente durante los 7 días que duró el tratamiento. Se llevó a cabo un registro de los mismos a través de muestras fotográficas.

**Resultado:** Se observó una mejor evolución en el grupo del gel extracto desproteinizado de sangre de ternera (grupo GE) y en el grupo de PRP (grupo PL), en comparación con el grupo control (grupo CO) ( $P < 0,05$ ).

**Conclusión:** El PRP demostró ser tan efectivo como la muestra comercial (Solcoseryl®), para la regeneración de úlceras corneales profundas y extensas. Además se destaca su fácil acceso, costo y reducida posología.

© 2013 Sociedad Española de Oftalmología. Publicado por Elsevier España, S.L. Todos los derechos reservados.

## Introduction

A corneal ulcer is an epithelial defect, loss of stroma, stromal inflammation or a combination thereof.<sup>1</sup> The causes can be neurotrophic, chemical, self-immune or due to connective tissue disorders, traumatism or bacterial infection (more frequently found in contact lens users), virus, fungi and parasites, etc.<sup>2-8</sup>

Said entity is treated with occlusion, lubricants (gel and eyedrops), antibiotics, surgical techniques such as conjunctival covering or with amniotic membrane, including tharsorrhaphy.<sup>9-12</sup> Solcoseryl® is an ophthalmic gel that contains a deproteinized extract of veal blood, which is utilized to rebuild and re-epithelize corneal tissue due to its properties as aerobic metabolism and oxidative phosphorylation activator. This medication: (1) increases oxygen consumption and glucose transport to tissues and cells in hypoxia and metabolically weakened; (2) increases collagen synthesis, stimulates cell proliferation and migration, and (3) accelerates and qualitatively improves cicatrization of lesions.<sup>12</sup> Platelet-rich plasma (PRP) has been used as adjuvant for tissue regeneration in oral, maxillofacial, reconstructive, cardiovascular and plastic surgery and in corneal lesions that progress toward stromal ulceration.<sup>13,14</sup> It is obtained through centrifugation of non-coagulated complete blood. Its biochemical composition is serum, leukocytes, platelets and growth factors although the crucial elements are platelet-derived growth factors (PDGF), transformation growth factor-beta (TGF-BETA), insulin-like growth factor (IGF), fibroblastic growth factor (FGF), vascular endothelial growth factor (VEGF) and epidermic growth factor (EGF) which carry out to the function of regenerating the substrate.<sup>13-15</sup>

In contrast with the other treatments mentioned above, PRP began to be utilized because in addition to repairing injury it regenerates lost tissue. Tissue repair is defined as the restoration thereof without retaining its original architecture or function, which produces cicatrization. On the other hand, regeneration takes place when the restoration of said tissue features properties indistinguishable from the original ones. Scar tissue does not recover the mechanical properties of the physiological function of the damaged tissue or organ, and PRP is of interest precisely because it is able to regenerate and rebuild the form as well as restoring function.<sup>14</sup> Accordingly, therapy strategies utilizing PRP are based on the modulation and acceleration of regenerative processes by means of the growth factors present in the platelets, which are known as

universal activators of nearly all regeneration processes. It has been demonstrated that EGF is present in the basal as well as reflex lacrimal secretion in somewhat lower concentrations to those found in serum.<sup>16</sup> Its function is to enhance the migration process of epithelial cells.<sup>17,18</sup> An additional factor of significance is TGF-BETA, involved in epithelial and stromal repair processes. Its concentration in serum is nearly three times higher than that found in tears.<sup>19-22</sup> Fibronectin is an important factor in cell migration and is present in lower concentrations with respect to serum.<sup>23,24</sup>

## Objective

To assess the efficacy of PRP in the treatment of noninfectious extended corneal ulcers in New Zealand albino rabbits.

## Materials and methods

### Solcoseryl®

Gel, by RAYMOS laboratory, made up by 200 mg of deproteinized extract of veal blood, 13 mg carboxy methylcellulose, 50 mg of 70% sorbitol, 50 µg thimerosal and 1 g distilled water csp.

### Platelet rich plasma

Platelet-rich plasma was obtained by extracting blood (2.5 ml) from the marginal ear vein which was placed in 1 ml microvials containing 3.2% sodium citrate in a ratio of 9:1. Subsequently it was centrifuged at 1000 RPM during 5 min. After this procedure the plasma fraction close to red and white blood cells was withdrawn with a Pasteur pipette. This PRP aliquot (approximately 300 µl) was kept in a sterile container at ambient temperature up to application.

### Utilized population

The population utilized for this 7-day prospective experimental study were New Zealand albino rabbits weighing 2-2.5 kg ( $n = 9$ ; 18 eyes), divided into 3 groups of 3 rabbits (6 eyes) each. The animals were given food and water ad libitum in a room with controlled temperature ( $21 \pm 5^\circ\text{C}$ ). The rabbits were exposed to cycles of 12 h light and 12 h darkness. The handling procedure was in accordance with the standards of the

Association for Research in Vision and Ophthalmology (ARVO norms) related to the use of animals for research purposes.

### Corneal lesion generation

The animals were previously anesthetized with an intramuscular injection (21 G) of ketamine (25 mg/kg) and xylazine (1 mg/kg) and with topical anesthesia with 0.5% proparacaine chlorhydrate (Anestalcon®). 10 mm diameter corneal ulcers were made with 50% alcohol during 45 seconds, followed by washing with physiological solution and corneal epithelium scraping with rounded spatula. Photographs were taken to record the injuries for subsequent comparison.

### Establishment of treatment and efficacy evaluation

The first group, named "CO", was treated with physiological solution at 8-h intervals during 7 days. The second group, named "GE", was treated with veal blood deproteinized extract in gel form (Solcoseryl®) at 8-h intervals during 7 days, while the third group, named "PL", was administered one drop of PRP on follow-up days 1 and 3, and was controlled up to completing day 7.

Controls were carried out once a day, always at the same time, taking photographs with a Sony digital camera (12.2 megapixel, full HD 1080, Optical zoom 4×, Wide angle lens 30 mm, Optical steadycam, DSC-w220) (Minato, Tokyo, Japan) after instilling topical anesthesia, 0.25% sodium fluorescein (Grant® Solution) under cobalt blue light filter. For assessing results and statistical analysis the photographs taken on days 1, 3, 5 and 7 were utilized. The corneal and ulcer areas were measured with a surface measurement computer program (Klonk Image Measurement). The evolution index was determined by means of the u/c ratio, where "u" is the ulcer area and "c" the cornea area, measured in mm.<sup>2</sup>

### Statistical analysis

The main variable was the quotient between the ulcer and corneal areas (U/C). Hypothesis tests were performed to compare the average is of each treatment (control, Solcoseryl® and plasma), at each point in time (1, 3, 5 and 7 days). The applied test was the T for independent samples, comparison of pairs.

Description: the test enabled paired comparison of equal population mean values. Each comparison considers the following:

Null hypothesis :  $E(X1)$

=  $E(X2)$ ; random variable expectations are equal

Alternative hypothesis :  $E(X1)$

< >  $E(X2)$ ; random variable expectations are different

where  $E(X1)$  and  $E(X2)$  are being the expectation of distribution 1 and 2 respectively of the groups being compared.

Due to the design of the experiment, the assumption of "independent random samples" was verified. On the other hand, the "normal distributions" assumption was verified for

each case by means of Shapiro–Wilk goodness of fit test (modified).

As regards the variance homogeneity assumption, in the cases in which it was not possible to assume variance equality, the Satterwait non-homogeneous variance correction was utilized (at a significance level of 5%). INFOSTAT version 2013 statistical software (Group InfoStat, FCA, Argentina) was used.

## Results

In daily controls it was noticed that the "CO" group exhibited poor evolution in comparison with the "GE" group ( $p=0.0307$  [seventh day]) and with the "PL" group ( $p=0.0212$  [seventh day]), with more irritable behavior and subjectively in more pain and discomfort. In these cases the palpebral slit was more difficult to open due to larger amounts of secretion. As regards the "GE" and "PL", groups, they exhibited a similar evolution ( $p=0.2898$ ). The rabbits exhibited more activity and the examination could be carried out with greater ease. In the first days (day 3), the "GL" group exhibited a lower re-epithelization rate ( $0.23 \pm 0.22 \text{ mm}^2$ ) than the "PL" group ( $0.12 \pm 0.05 \text{ mm}^2$ ), although in the last days the evolution was equal, exhibiting a similar regeneration rate by day 7 (Table 1 and Fig. 1).

## Discussion

Corneal ulcers are frequently found in ophthalmological practice. In general, small defects are easy to treat with artificial tears, ophthalmological cream and topical antibiotics. The difficulties lie in deep and large ulcers which can progress to perforation affecting vision and even the integrity of the ocular globe. When standard therapy fails, surgical techniques can be carried out, including tarsorrhaphy,<sup>25</sup> conjunctival covering, amniotic membrane.<sup>26,27</sup>

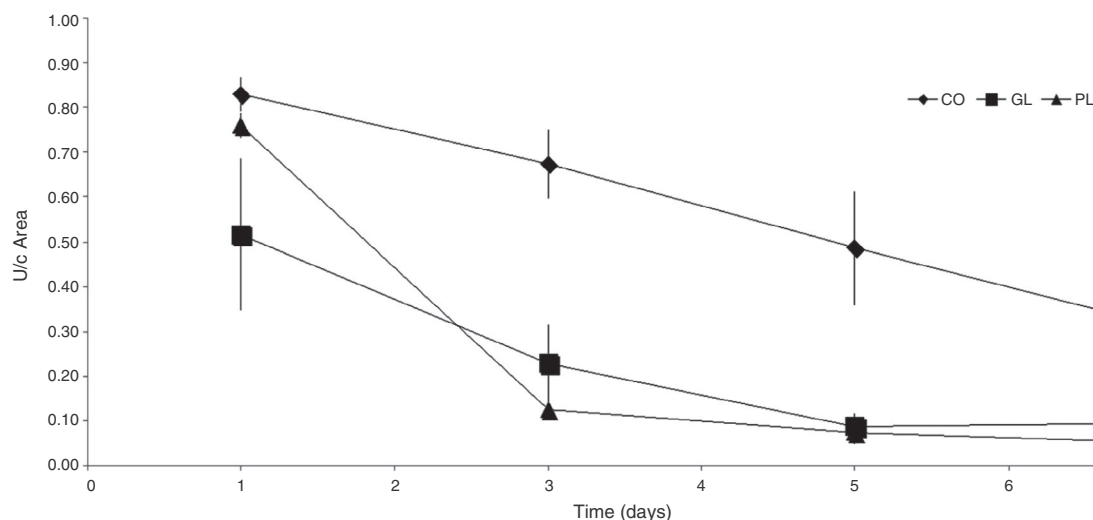
Tarsorrhaphy is a simple, short and reversible surgical procedure once the injury is healed. However, it is not easily accepted by patients because it is an uncomfortable and anti-esthetic procedure.<sup>27</sup> Conjunctival and amniotic membrane covering are usually utilized for treating infectious ulcers (bacterial and mycotic) which are difficult to treat otherwise. In addition, some authors have observed greater efficacy of the latter for treating chemical (alkaline) ulcers in animal models as compared to autologous serum.<sup>28</sup> Its advantage is due to the presence of blood vessels in the substrate of the injury which facilitate the elimination of pathogen agents and prevent perforation. Its drawbacks include difficulty in visualizing anterior and posterior segments, impossibility of controlling intraocular pressure and lower effect of antibiotic eyedrops due to the poor penetration rate thereof. In addition, more than one surgery is required for reestablishing visual acuity.<sup>26</sup>

An additional alternative for treatment is the use of autologous serum, which has demonstrated objective and subjective efficacy for treating severe dry eye (Sjögren syndrome, keratoconjunctivitis sicca),<sup>29,30</sup> persistent epithelial defects<sup>31</sup> and neurotrophic keratopathy.<sup>32-34</sup>

However, other studies carried out in patients with dry eye did not demonstrate symptom improvement with the use of autologous serum in comparison with the use of artificial tears.<sup>35</sup> Malavazzi et al.<sup>36</sup> were not able to demonstrate that

**Table 1 – Median comparison between groups and corresponding p value.**

| Time | Variable | G1      | G2         | Median (1) | Median (2) | p      |
|------|----------|---------|------------|------------|------------|--------|
| 1    | U/c      | Control | Plasma     | 0.83       | 0.76       | 0.1895 |
| 1    | U/c      | Control | Solcoseryl | 0.83       | 0.52       | 0.1342 |
| 1    | U/c      | Plasma  | Solcoseryl | 0.76       | 0.52       | 0.2188 |
| 3    | U/c      | Control | Plasma     | 0.67       | 0.12       | 0.0011 |
| 3    | U/c      | Control | Solcoseryl | 0.67       | 0.23       | 0.0036 |
| 3    | U/c      | Plasma  | Solcoseryl | 0.12       | 0.23       | 0.3054 |
| 5    | U/c      | Control | Plasma     | 0.49       | 0.07       | 0.0250 |
| 5    | U/c      | Control | Solcoseryl | 0.49       | 0.09       | 0.0284 |
| 5    | U/c      | Plasma  | Solcoseryl | 0.07       | 0.09       | 0.7191 |
| 7    | U/c      | Control | Plasma     | 0.31       | 0.05       | 0.0212 |
| 7    | U/c      | Control | Solcoseryl | 0.31       | 0.10       | 0.0307 |
| 7    | U/c      | Plasma  | Solcoseryl | 0.05       | 0.10       | 0.2898 |

**Fig. 1 – Daily corneal ulcer evolution rate.**

autologous serum is more effective than treatment with physiological solution in rabbit ulcers.

In the research reported herein, ulcer regeneration in rabbits instilling topical PRP on days 1 and 3 is evident and, even though the objective was not to assess the response of the rabbits to different therapies, symptom improvement was observed because the rabbits were less irritable than those treated only with physiological solution. Ortuño-Prados et al.<sup>37</sup> reported the use of autologous PRP combined with Tutopach® (bovine pericardium biological membrane) in the treatment of neurotrophic corneal ulcers, demonstrating short-term effectiveness and diminished immune reactions.

Even though this research only utilized PRP, effective corneal regeneration rates were obtained with lower posology as compared with the other applied treatments.

PRP has the advantage of being a nonsurgical procedure in addition to low cost and ease of access for health professionals by centrifugation of the rabbits blood. In what concerns posology, it also exhibits advantages vis-à-vis conventional topical treatments. The administration of one PRP drop on days 1 and 3 exhibited a similar corneal epithelium healing rate as the daily applications of the commercially available gel. As Solcoseryl®, PRP did not produce ocular surface irritations. In addition, PRP is an excellent source of growth factors and

platelets. At present, the main interest is focused on researching its regeneration-inducing potential.

The researchers conclude that PRP demonstrated efficiency in noninfectious extensive corneal ulcers and is a good alternative vis-à-vis the above mentioned processes.

### Conflict of interests

No conflict of interests has been declared by the authors.

### Acknowledgments

The authors express their gratitude to graduate Sebastián Marun for his cooperation in processing platelet-rich plasma and graduate María Inés Ahumada for her contribution to statistical analysis.

### REFERENCES

1. Bengoa González A. Atlas Urgencias en Oftalmología, vol. II. Barcelona: Editorial Glosa, S.L.; 2003. p. 140–9.



2. Duran de la Colina JA. Complicaciones de las lentes de contacto. País Vasco: Tecnimedia Editorial, S.L.; 1998. p. 383-406.
3. Zarranz-Ventura J, de Nova E, Moreno-Montañés J. Manifestaciones corneales en las enfermedades sistémicas. *An Sist Sanit Navarra*. 2008;31.
4. Martín Carretero G, [serial online]. Artículos de polo anterior. Quemaduras oculares térmicas y químicas. Available from: <http://www.torrecardenas.eloculista.es/index.php/ofthalmologia/articulos-ugc-ofthalmologia/19-articulos-de-polo-anterior/65-quemaduras-oculares-termicas-y-quimicas> [cited 03.03.12].
5. Cantor Pinzón NL. Queratitis bacteriana por pseudomonaaeruginosa asociada al uso de lentes de contacto. Bogotá: Pontificia Universidad Javeriana Facultad de Ciencias Básicas; 2009. p. 55 [Trabajo de grado].
6. Duran de la Colina J [serial online] Úlcera corneal progresiva; 2004. p. 22. Available from: <http://www.oftalmo.com/studium/studium2004/stud04-2/04b-02.htm> [accessed 24.04.12].
7. Chidambaram JD. Recent advances in the diagnosis and management of bacterial keratitis. *Int Ophthalmol Clin* [serial online]. 2007;47:1-6. Available from: <http://www.ncbi.nlm.nih.gov/pubmed/17667271> [cited 12.04.12].
8. Kanski J. *Oftalmología clínica*, 250-261, 6th ed. Barcelona, Spain: Elsevier; 2009. p. 275-6.
9. Chiang CC, Lin JM, Chen WL, Chiu YT, Tsai YY. Tratamiento de úlcera corneal bacteriana con solución compuesta de vancomicina fortificada-amikacina. *Intramed* [serial online]. 2010. Available from: <http://www.intramed.net/contenidover.asp?contenidoID=64791> [accessed 24.04.12].
10. Caviedes SA, Collado Hornillos J, Gómez Dacasa A. *Oftalmología II*. Cantabria: Universidad de Cantabria: Servicio de Publicaciones; 1991. p. 91-3.
11. American Academy of Ophthalmology. *Enfermedades externas y córnea 2007-2008*. Barcelona, Spain: Elsevier; 2008. p. 428-9, 436-438.
12. SAO NEWS. Informativo oficial sociedad argentina de oftalmología. 2009;7:6.
13. Declós L. Nuevas aplicaciones clínicas del plasma rico en plaquetas en patologías musculoesqueléticas. México: Conferencia dictada en la Facultad de Medicina, Universidad Nacional Autónoma de México; 2013.
14. Beca T, Hernández G, Morante S, Bascones A. Plasma rico en plaquetas. Una revisión bibliográfica. *Av Periodon Implantol*. 2007;19:39-52.
15. Reyes M, Montero S, Cifuentes J, Zarzar E. Actualización de la técnica de obtención y uso del plasma rico en factores de crecimiento (P.R.G.F). *Rev Dent Chile*. 2002;93:25-8.
16. Ohashi Y, Motokura M, Kinoshita Y, Mano T, Watanabe H, Kinoshita S, et al. Presence of epidermal growth factor in human tears. *Invest Ophthalmol Vis Sci*. 1989;30:1879-82.
17. Van Setten GB, Tervo T, Tervo K, Tarkkanen A. Epidermal growth factor (EGF) in ocular fluids: presence, origin and therapeutical considerations. *Acta Ophthalmol Suppl*. 1992;202:54-9.
18. Pastor JC, Calonge M. Epidermal growth factor and corneal wound healing. A multicenter study. *Cornea*. 1992;11:311-4.
19. Gupta A, Monroy D, Ji Z, Yoshino K, Huang A, Pflugfelder SC. Transforming growth factor beta-1 and beta-2 in human tear fluid. *Curr Eye Res*. 1996;15:605-14.
20. Fredj-Reygrobellet D, Plouet J, Delayre T, Baudouin C, Bourret F, Lapalus P. Effects of aFGF and bFGF on wound healing in rabbit corneas. *Curr Eye Res*. 1987;6:1205-9.
21. Yoshino K, Garg R, Monroy D, Ji Z, Pflugfelder SC. Production and secretion of transforming growth factor beta (TGF-beta) by the human lacrimal gland. *Curr Eye Res*. 1996;15: 615-24.
22. Wilson SE, Lloyd SA, Kennedy RH. Basic fibroblast growth factor (FGF) and epidermal growth factor (EGF) receptor messenger RNA production in human lacrimal gland. *Invest Ophthalmol Vis Sci*. 1991;32:2816-20.
23. Nishida T, Ohashi Y, Awata T, Manabe R. Fibronectin. A new therapy for corneal trophic ulcer. *Arch Ophthalmol*. 1983;101:1046-8.
24. Phan TM, Foster CS, Shaw CD, Zagachin LM, Colvin RB. Topical fibronectin in an alkali burn model of corneal ulceration in rabbits. *Arch Ophthalmol*. 1991;109:414-9.
25. Días-Valle D, Benítez del Castillo Sánchez JM, Díaz Rodríguez E, Toledano Fernández N, Arteaga Sánchez A, Sayagúez Gómez O. Manejo de la queratopatía neurotrófica mediante tarsorrafia con cianoacrilato y suero autólogo. *Arch Soc Esp Oftalmol*. 2003;78:119-22.
26. Ballesteros CL, Corvino V, Brunzini R. [serial online] Recubrimientos conjuntivales en queratocosis. Hospital Oftalmológico Santa Lucía, Buenos Aires, Argentina. Available from: [http://www.hospitalsantalucia.com.ar/osl/osl04/recubrimientos\\_conjuntivales.htm](http://www.hospitalsantalucia.com.ar/osl/osl04/recubrimientos_conjuntivales.htm)[http://www.hospital\\_santalucia.com.ar/osl/osl04/recubrimientos\\_conjuntivales.htm](http://www.hospital_santalucia.com.ar/osl/osl04/recubrimientos_conjuntivales.htm) [accessed 08.05.12].
27. Cervera M. Ojo seco refractario. *Stodium phthalmologicum* [serial online]; 1999. Available from: <http://www.oftalmo.com/studium/studium1999/stud99-1/controversia/controver.b.htm> [accessed 23.04.12].
28. Shahriari HA, Tokhmehchi F, Reza M. Comparison of the effect of amniotic membrane suspension and autologous serum on alkaline corneal epithelial wound healing in the rabbit model. *Cornea*. 2008;27:1148-50. Available from: <http://www.ncbi.nlm.nih.gov/pubmed/19034130> [accessed 27.04.12].
29. Noble BA, Loh RS, MacLennan S, Pesudovs K, Reynolds A, Bridges LR, et al. Comparison of autologous serum eye drops with conventional therapy in a randomised controlled crossover trial for ocular surface disease. *Br J Ophthalmol*. 2004;88:647-52.
30. Tsubota K, Goto E, Fujita H, Ono M, Inoue H, Saito I, et al. Treatment of dry eye by autologous serum application in Sjogren's syndrome. *Br J Ophthalmol*. 1999;83:390-5.
31. Poon AC, Geerling G, Dart JK, Fraenkel GE, Daniels JT. Autologous serum eyedrops for dry eyes and epithelial defects: clinical and in vitro toxicity studies. *Br J Ophthalmol*. 2001;85:1188-97.
32. Días-Valle D, Benítez del Castillo Sánchez JM, Díaz Rodríguez E, Toledano Fernández N, Arteaga Sánchez A, Sayagues Gómez O. Manejo de la queratopatía neurotrófica mediante tarsorrafia con cianoacrilato y suero autógeno. *Arch Soc Esp Oftalmol*. 2003;78:119-22.
33. Matsumoto Y, Dogru M, Goto E, Ohashi Y, Kojima T, Ishida R, et al. Autologous serum application in the treatment of neurotrophic keratopathy. *Ophthalmology*. 2004;111:1115-20.
34. López-García JS, García-Lozano I, Rivas L, Martínez-Garchitorena J. Aplicaciones del suero autógeno en Oftalmología. *Arch Soc Esp Oftalmol*. 2007;82:9-20.
35. Tananuvat N, Daniell M, Sullivan LJ, Yi Q, McKelvie P, McCarty DJ, et al. Controlled study of the use of autologous serum in dry eye patients. *Cornea*. 2001;20:802-6.
36. Malavazzi GR, Lake JC, Dantas PE. Effect of honey and autologous serum on corneal epithelial healing in rabbits. *Arq Bras Oftalmol*. 2005;68:347-51.
37. Ortuño Prados VJ, Alio JL. Tratamiento de úlcera corneal neurotrófica con plasma rico en plaquetas y Tutopatch®. *Arch Soc Esp Oftalmol*. 2011;86:121-3.