



# Outcomes of adrenal-sparing surgery or total adrenalectomy in pheochromocytoma associated with multiple endocrine neoplasia type 2: an international retrospective population-based study

Frederic Castinetti, Xiao-Ping Qi, Martin K Walz, Ana Luiza Maia, Gabriela Sansó, Mariola Peczkowska, Kornelia Hasse-Lazar, Thera P Links, Sarka Dvorakova, Rodrigo A Toledo, Caterina Mian, Maria Joao Bugalho, Nelson Wohllk, Oleg Kollyukh, Letizia Canu, Paola Loli, Simona R Bergmann, Josefina Biarnes Costa, Ozer Makay, Attila Patocs, Marija Pfeifer, Nalini S Shah, Thomas Cuny, Michael Brauckhoff, Birke Bausch, Ernst von Dobschuetz, Claudio Letizia, Marcin Barczynski, Maria K Alevizaki, Malgorzata Czetwertynska, M Umit Ugurlu, Gerlof Valk, John T M Plukker, Paola Sartorato, Debora R Siqueira, Marta Barontini, Malgorzata Szperl, Barbara Jarzab, Hans H G Verbeek, Tomas Zelinka, Petr Vlcek, Sergio P A Toledo, Flavia L Coutinho, Massimo Mannelli, Monica Recasens, Lea Demarquet, Luigi Petramala, Svetlana Yaremchuk, Dmitry Zabolotnyi, Francesca Schiavi, Giuseppe Opocher, Karoly Racz, Andrzej Januszewicz, Georges Weryha, Jean-Francois Henry, Thierry Brue, Bernard Conte-Devolx\*, Charis Eng\*, Hartmut P H Neumann\*

## Summary

*Lancet Oncol* 2014; 15: 648–55  
Published Online  
April 16, 2014  
[http://dx.doi.org/10.1016/S1470-2045\(14\)70154-8](http://dx.doi.org/10.1016/S1470-2045(14)70154-8)

\*Joint senior authors contributed equally

Department of Endocrinology, La Timone Hospital, Hopitaux de Marseille and Centre de Recherche en Neurobiologie et Neurophysiologie de Marseille, Aix-Marseille University, Marseille, France

(F Castinetti MD, Prof T Brue MD, Prof B Conte-Devolx MD);

Departments of Oncologic and Urologic Surgery, The 117th PLA Hospital, PLA Hangzhou Clinical College, Anhui Medical University, Hangzhou, China (Prof X-P Qi MD); Department of Surgery and Center of Minimally Invasive Surgery, Kliniken Essen-Mitte, Essen, Germany (Prof M K Walz MD);

Thyroid Section, Endocrinology Division, Hospital de Clinicas de Porto Alegre, Universidade Federal do Rio Grande do Sul, Brazil (A L Maia MD, D R Siqueira MD); Center for Endocrinological Investigations, Hospital de Niños R Gutierrez, Buenos Aires, Argentina (G Sansó PhD, M Barontini MD); Department of Hypertension, Institute of Cardiology, Warsaw, Poland (M Peczkowska MD, M Szperl PhD, A Januszewicz MD); Department of Nuclear Medicine and Endocrine Oncology, Maria Skłodowska Curie Memorial Center and Institute of Oncology, Gliwice Branch,

**Background** The prevention of medullary thyroid cancer in patients with multiple endocrine neoplasia type 2 syndrome has demonstrated the ability of molecular diagnosis and prophylactic surgery to improve patient outcomes. However, the other major neoplasia associated with multiple endocrine neoplasia type 2, pheochromocytoma, is not as well characterised in terms of occurrence and treatment outcomes. In this study, we aimed to systematically characterise the outcomes of management of pheochromocytoma associated with multiple endocrine neoplasia type 2.

**Methods** This multinational observational retrospective population-based study compiled data on patients with multiple endocrine neoplasia type 2 from 30 academic medical centres across Europe, the Americas, and Asia. Patients were included if they were carriers of germline pathogenic mutations of the *RET* gene, or were first-degree relatives with histologically proven medullary thyroid cancer and pheochromocytoma. We gathered clinical information about patients' *RET* genotype, type of treatment for pheochromocytoma (ie, unilateral or bilateral operations as adrenalectomy or adrenal-sparing surgery, and as open or endoscopic operations), and postoperative outcomes (adrenal function, malignancy, and death). The type of surgery was decided by each investigator and the timing of surgery was patient driven. The primary aim of our analysis was to compare disease-free survival after either adrenal-sparing surgery or adrenalectomy.

**Findings** 1210 patients with multiple endocrine neoplasia type 2 were included in our database, 563 of whom had pheochromocytoma. Treatment was adrenalectomy in 438 (79%) of 552 operated patients, and adrenal-sparing surgery in 114 (21%). Pheochromocytoma recurrence occurred in four (3%) of 153 of the operated glands after adrenal-sparing surgery after 6–13 years, compared with 11 (2%) of 717 glands operated by adrenalectomy ( $p=0.57$ ). Postoperative adrenal insufficiency or steroid dependency developed in 292 (86%) of 339 patients with bilateral pheochromocytoma who underwent surgery. However, 47 (57%) of 82 patients with bilateral pheochromocytoma who underwent adrenal-sparing surgery did not become steroid dependent.

**Interpretation** The treatment of multiple endocrine neoplasia type 2-related pheochromocytoma continues to rely on adrenalectomies with their associated Addisonian-like complications and consequent lifelong dependency on steroids. Adrenal-sparing surgery, a highly successful treatment option in experienced centres, should be the surgical approach of choice to reduce these complications.

**Funding** European Union, German Cancer Foundation, Arthur Blank Foundation, Italian Government, Charles University, Czech Ministry of Health, Nanjing Military Command, National Science Centre Poland, National Research Council for Scientific and Technological Development, and State of São Paulo Research Foundation.

## Introduction

Multiple endocrine neoplasia type 2 is a rare autosomal dominant syndrome with a worldwide prevalence of between one per 30 000 and one per 50 000 population that has historically been divided into three distinct clinical variants (multiple endocrine neoplasia types 2A

and 2B, and familial medullary thyroid carcinoma). Medullary thyroid cancer is the defining component neoplasia in 95–100% of all patients with multiple endocrine neoplasia type 2. Two clinical variants include pheochromocytoma as another major disease manifestation: multiple endocrine neoplasia type 2A,

where half of patients will have pheochromocytoma and a quarter will have primary hyperparathyroidism; and multiple endocrine neoplasia type 2B, where all patients have mucosal ganglioneuromatosis and a Marfanoid habitus and half also develop pheochromocytoma. The mapping and identification of the *RET* susceptibility gene has enabled the molecular diagnosis, predictive testing, and early high-risk screening of as-yet unaffected relatives for multiple endocrine neoplasia type 2.<sup>1-7</sup> Since the prognosis of multiple endocrine neoplasia type 2 depends mainly on medullary thyroid cancer aggressiveness and the risk of distant metastatic disease, research efforts have focused on improving the management of this type of cancer. The treatment option of prophylactic thyroidectomy in patients with high-risk *RET* genotypes has drastically changed outcomes for these patients, and has transformed a fatal syndrome with metastatic cancer into a chronic disease that needs regular follow-up.

However, characterisation of this chronic disease should also focus on the other major component of the syndrome. Pheochromocytoma, although well recognised as a frequent manifestation of multiple endocrine neoplasia type 2, has often been viewed as a minor problem that can be abrogated by bilateral adrenalectomy.<sup>4</sup> Despite progress in the surgical management of pheochromocytoma (ie, adrenal-sparing surgery or minimally invasive endoscopic operations<sup>8-10</sup>), these techniques are still not regarded as standard of care, even in recent guidelines for medullary thyroid cancer and multiple endocrine neoplasia type 2.<sup>4</sup>

More up-to-date knowledge about the characteristics and optimal management of pheochromocytoma is essential to further reduce morbidity and mortality in patients with multiple endocrine neoplasia type 2.<sup>11</sup> We therefore initiated this multicentre, multinational study to re-assess the diagnosis, treatment, and outcomes of pheochromocytoma in multiple endocrine neoplasia type 2.

## Methods

### Study design and participants

The European–American–Chinese–Indian MEN-2 Pheochromocytoma Study (EACIMPS) was initiated in 2012. Experts from Europe, America, China, and India founded a consortium with the intention to create a registry for details of patients with multiple endocrine neoplasia type 2 to re-assess the diagnosis, treatment, and outcome of pheochromocytoma in this syndrome.

The EACIMPS centres are located in 14 countries in Europe, four in the Americas, and two in Asia. 30 centres participated in total, all of which have a long-lasting interest in multiple endocrine neoplasia type 2 and have gathered data from participating patients for the past three decades. All centres are either part of a department or division of endocrinology, of endocrine surgery, or of human or medical genetics, and all either have their own molecular genetic diagnostic laboratory or are closely

affiliated with such laboratories. All centres have access to biochemical and imaging diagnostic technologies relevant to the range of tumours related to multiple endocrine neoplasia type 2. Adrenal-sparing surgery is used in 25 of the 30 centres. Policies for adrenal-sparing surgery differ between centres regarding the criteria used to establish the appropriateness of this surgical approach. In all centres, minimally invasive methods for adrenal surgeries are routine, and access was obtained through retroperitoneoscopy. All except for two centres defined a maximum tumour size for endoscopic surgery as smaller than 6–8 cm; of the other two centres, one used a limit of smaller than 10 cm and the other did not have a size restriction. Timing of surgery was patient driven. By contrast with management of medullary thyroid carcinoma in multiple endocrine neoplasia type 2, no firm guidelines exist for the timing of surgery in this syndrome.<sup>4</sup>

We established the EACIMPS database on Nov 1, 2012 and collected data on patients from the records of the participating centres up to a cutoff of Oct 1, 2013. Patients included in the database were enrolled at the participating centres from 1968 to 2013. Patients included in the database had to be diagnosed as carriers of germline pathogenic mutations of the *RET* gene. Additionally, first-degree relatives with histologically proven medullary thyroid carcinoma and pheochromocytoma (defined by the association of increased urinary or plasma metanephrins and adrenal tumour) were included. Multiple endocrine neoplasia type 2 patients without pheochromocytoma had to be older than 15 years of age at last follow-up to be included.

We gathered demographic, clinical, and molecular genetic data for patients included in the database. We gathered data on age at diagnosis for pheochromocytoma, whether the disease was unilateral or bilateral, if medullary thyroid carcinoma was diagnosed, and if there were any presenting symptoms associated with pheochromocytoma. For patients with pheochromocytoma, all centres had performed plasma or urinary metanephrine measurements in symptomatic patients, or in asymptomatic patients every 6–12 months depending on each investigator. Imaging was done systematically when metanephrine concentrations increased and every 3–5 years in patients with normal metanephrine values. These data were also included in our database.

Data were collected on whether surgeries were unilateral or bilateral operations, either as adrenalectomy or adrenal-sparing surgery as open or endoscopic operations. In cases of a second or subsequent pheochromocytoma-related surgery, these data were also recorded accordingly. Recurrence of pheochromocytoma was defined as increased metanephrine concentration associated with a positive adrenal imaging ipsilateral to the surgical intervention. For patients who underwent bilateral adrenal-sparing operations, glucocorticoid

Gliwice, Poland (K Hasse-Lazar MD, B Jarzab MD); Department of Endocrinology, University Medical Center Groningen, University of Groningen, Netherlands (T P Links MD, H H G Verbeek MD); Department of Molecular Endocrinology, Institute of Endocrinology, Prague, Czech Republic (S Dvorakova PhD); Department of Endocrinology, University of Sao Paulo School of Medicine, Sao Paulo, Brazil (R A Toledo PhD, S P A Toledo MD, F L Coutinho MD); Operative Unit of the Endocrinology Department of Medicine (DIMED), University of Padova, Padova, Italy (C Mian MD); Servico de Endocrinologia, Instituto Portugues de Oncologia de Lisboa Francisco Gentil E.P.E. and Faculdade de Ciencias Médicas, Universidade Nova de Lisboa, Lisbon, Portugal (M J Bugalho PhD); Endocrine Section, Universidad de Chile, Hospital del Salvador, Santiago de Chile, Chile (N Wohllk MD); Institute of Endocrinology, Kiev, Ukraine (O Kollyukh MD); Department of Experimental and Clinical Biomedical Sciences, Endocrinology Unit, University of Florence, Florence, Italy (L Canu MD, Prof M Mannelli MD); Department of Endocrinology, Ospedale Niguarda Cà Granda, Milan, Italy (P Loli MD); Division of Endocrinology and Diabetology, Faculty of Medicine, Philipps University of Marburg, Marburg, Germany (S R Bergmann MD); Hospital Universitari de Girona, Gerencia Territorial Girona, Institut Català de la Salut, Girona, Spain (J B Costa MD, M Recasens MD); Department of General Surgery, Division of Endocrine Surgery, Ege University Hospital, Izmir, Turkey (O Makay MD); Molecular Medicine Research Group, HSA-SE "Lendület" Hereditary Endocrine Tumor Research Group, Hungarian Academy of Sciences and Semmelweis University, Budapest, Hungary (A Patocs MD); Department of Endocrinology, University Medical Center Ljubljana, Ljubljana, Slovenia (M Pfeifer MD); Department of Endocrinology, Seth G S Medical College, King

Edward Memorial Hospital, Parel, Mumbai, India (N S Shah MD); Department of Endocrinology, University Hospital, Nancy, France (T Cuny MD, L Demarquet MD, Prof G Weryha MD); Department of Endocrine Surgery, University of Bergen, Bergen, Norway (Prof M Brauckhoff MD); 2nd Department of Medicine (B Bausch MD), Department of Visceral Surgery (E von Dobschuetz MD), and Section for Preventive Medicine, Department of Nephrology and General Medicine (Prof H P H Neumann MD), University Medical Centre, Albert Ludwigs University of Freiburg, Freiburg, Germany; Department of Internal Medicine and Medical Specialties, University La Sapienza, Rome, Italy (C Letizia MD, L Petramala MD); Department of Endocrine Surgery, Third Chair of General Surgery, Jagiellonian University, Medical College, Krakow, Poland (M Barczynski MD); Endocrine Unit Evgenideion Hospital and Department of Medical Therapeutics, Alexandra Hospital, Athens University School of Medicine, Athens, Greece (Prof M K Alevizaki MD); Department of Endocrinology, Maria Skłodowska Curie Memorial Center and Institute of Oncology, Warsaw, Poland (M Czetwertynska MD); Department of General Surgery, Breast and Endocrine Surgery Unit, Marmara University, Istanbul, Turkey (M U Ugurlu MD); Department of Internal Medicine, University Medical Centre Utrecht, Utrecht, Netherlands (G Valk MD); Department of Surgery, University Medical Centre, Groningen, Netherlands (Prof J T M Plukker MD); Department of Internal Medicine, General Hospital, Montebelluna, Treviso, Italy (P Sartorato MD); 3rd Department of Medicine—Department of Endocrinology and Metabolism, First Faculty of Medicine, Charles University and General University Hospital, Prague, Czech Republic (T Zelinka MD); Department of Nuclear Medicine and Endocrinology, Second Faculty of Medicine,

replacement was initiated postoperatively in all patients, and cortisol was measured before and 30 and 60 min after injection of adrenocorticotrophic hormone at a timepoint decided by each investigator to assess whether patients were presenting with adrenal insufficiency. If the recommended steroid replacement was withdrawn, the occurrence of Addisonian-like episodes was defined as acute hypotension, fatigue, and abdominal discomfort. We did not assess quality of life because it was beyond the scope of this study.

Patients were classified as having malignant pheochromocytoma if metastases were present in lymph nodes or in tissues where paraganglial tissue is not typically present (eg, the lungs, bones, and liver), as shown by CT scans, MRI, or nuclear medicine imaging. All these data were also registered for *RET* mutation carriers in whom pheochromocytoma was excluded and who never had an adrenal operation. Additionally, we recorded whether medullary thyroid cancer was diagnosed before, together with, or after pheochromocytoma, in all carriers of multiple endocrine neoplasia type 2.

All patients included in the database were offered molecular genetic testing for germline mutations of the *RET* gene. Germline genomic DNA was extracted from ethylenediamine tetra-acetic acid-anticoagulated blood. The analyses were done according to international standards and the manufacturers' instructions in clinical and molecular biology laboratories. Routinely, the analyses included DNA extraction, PCR amplification, and Sanger sequencing of exons 8, 10, 11, and 13–16 of the *RET* gene.

In accordance with the institutional review board, all patients provided signed written informed consent for genetics and analyses of the results. Exceptions are the centres in Groningen and Utrecht in the Netherlands, and

Lisbon in Portugal, where the participants' identities were anonymised and protected by unique codes that were known only by two dedicated data managers; therefore, no further Institutional Review Board approval was needed at these centres.

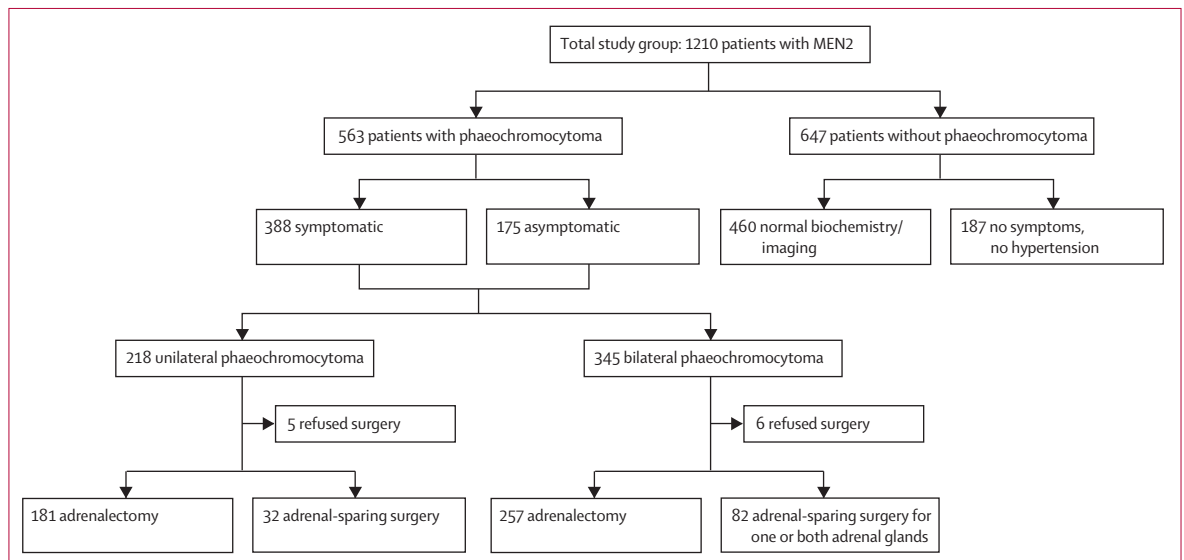
Our key aim was to compare disease-free survival after adrenal-sparing surgery or adrenalectomy in patients with pheochromocytoma. We also examined adrenal function recovery after adrenal-sparing surgery, compared disease-free survival after endoscopy or laparotomy surgeries, outcomes of the patients with pheochromocytoma (mortality and causes of death), occurrence of pheochromocytoma in relation to medullary thyroid cancer, and the rate of pheochromocytoma malignancy.

**Statistical analysis**

We summarised continuous variables as mean (SD), range, and median (IQR). We calculated age-dependent penetrance estimates of pheochromocytoma with the Kaplan-Meier method. We compared disease-free survival with the log-rank analysis. We did statistical comparisons of quantitative data with Student's *t* test or ANOVA. For statistical comparisons of dichotomous data, we used the  $\chi^2$  test. All statistical tests were two sided, and *p* values of less than 0.05 were deemed to indicate statistical significance. All analyses were done with XLStat Software (version 2013.4.05).

**Role of the funding source**

The funders had no role in study design, data collection, data analysis, data interpretation, or writing of the report. The corresponding author had full access to all the data in the study and had final responsibility for the decision to submit for publication.



**Figure 1: Study population** Of the 345 patients with bilateral pheochromocytoma, five had also extra-adrenal pheochromocytoma. Some cases of bilateral pheochromocytoma were synchronous and others were metachronous (see text). MEN2= multiple endocrine neoplasia type 2.

## Results

1210 patients with multiple endocrine neoplasia type 2 from 30 different academic medical centres in Europe, America, China, and India were included in our study (figure 1, appendix). Of these patients, 559 (46%) were male and 651 (54%) female. Mean age at final follow-up was 42 years (SD 18·4; median 41 years [IQR 26–54]; range 12–89 years). Mutations in exon 11 were the most common type (792, 65%), followed by those in exon 10 (272, 22%). The remaining patients had mutations in exons 8 (four patients; <1%), 13 (12; 1%), 14 (67; 6%), and 16 (63; 5%).

563 patients presented with pheochromocytoma. Table 1 shows the characteristics of this population. In more than half of the patients, pheochromocytoma was diagnosed after medullary thyroid carcinoma, whereas it was detected at the same time as medullary thyroid carcinoma in about a third of patients, and was diagnosed without medullary thyroid cancer in the remaining patients (table 1). All the patients in the latter group subsequently developed medullary thyroid cancer, except for seven patients who had thyroidectomy but no medullary thyroid cancer on pathology, and four patients who did not have thyroidectomy because their calcitonin concentrations were normal at final follow-up. Thyroidectomy was done in 559 (99%) of 563 of the patients with pheochromocytoma. In the whole cohort of patients with multiple endocrine neoplasia studied, 48 (4%) did not have a thyroidectomy because of normal calcitonin concentration at last follow-up, which means that overall 1162 (96%) of the patients had a thyroidectomy.

Of the 563 patients with pheochromocytomas, at first presentation, 250 (44%) had bilateral and 313 (56%) unilateral pheochromocytomas. Of the 313 patients with unilateral pheochromocytomas, 95 (30%) subsequently developed a contralateral pheochromocytoma at a mean of 9 years (SD 9·3) later. Thus, ultimately, 345 (61%) patients had bilateral and 218 (39%) unilateral pheochromocytomas (figure 1, table 1). Extra-adrenal pheochromocytomas occurred in five patients who already had bilateral pheochromocytoma. All these tumours were located in the interaortocaval space close to the adrenal glands. Two patients had malignant pheochromocytomas at 46 and 43 years of age. Figure 2 shows the age-related cumulative incidence of unilateral and bilateral pheochromocytoma in the whole cohort of patients with multiple endocrine neoplasia type 2 for whom complete data were available, including the 563 patients with pheochromocytoma and the 460 without pheochromocytoma at the last follow-up (see later). 50% of the patients had unilateral pheochromocytoma by 44 years of age and bilateral pheochromocytoma by 61 years of age. Age at diagnosis was the only characteristic that differed between patients with different *RET* mutations: the mean age at diagnosis of first pheochromocytoma was 45·4 years (SD 16·1) for

exon 10, 37·2 years (SD 13·1) for exon 11, and 26·7 years (SD 10·2) for exon 16 (p=0·048).

In patients with pheochromocytoma, symptomatic presentations occurred in 388 (69%) patients, whereas 175 (31%) presented asymptotically without hypertension, sweating, or headaches. The asymptomatic

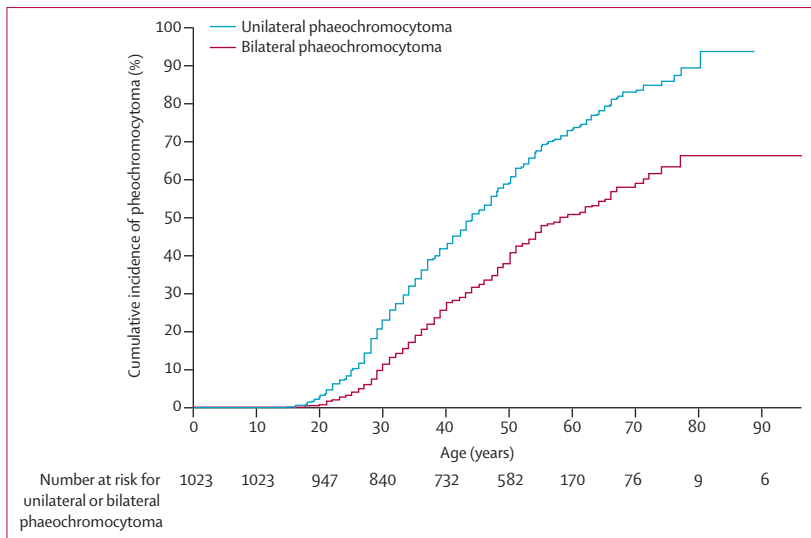
	Patients with pheochromocytoma (n=563)
<b>Patient characteristics</b>	
Age at first diagnosis, years	
Mean (SD)	37 (12·8)
Median (IQR)	36 (27–44)
Range	12–89
Age at final follow-up, years	
Mean (SD)	50·2 (14·6)
Median (IQR)	49 (40–59)
Range	14–96
Sex	
Men	252 (45%)
Women	311 (55%)
Unilateral pheochromocytoma	218 (39%)
Bilateral pheochromocytoma	345 (61%)
Malignant pheochromocytoma	2 (<1%)
Extra-adrenal pheochromocytoma	5*
Symptomatic at first diagnosis	388 (69%)
Asymptomatic at first diagnosis	175 (31%)
Occurrence with medullary thyroid carcinoma†	
Pheochromocytoma first	81 (15%)
Pheochromocytoma afterwards	302 (55%)
Both together	169 (30%)
<b>Mutations</b>	
Exon 8	3 (1%)
Cys515Ser	1 (<1%)
His533Cys	2 (<1%)
Exon 10	53 (9%)
Codon 609 (Cys609Phe, Cys609Gly, Cys609Arg, Cys609Ser)	9 (2%)
Codon 611 (Cys611Trp, Cys611X, Cys611Try)	6 (1%)
Codon 618 (Cys618Phe, Cys618Arg, Cys618Ser, Cys618Try)	21 (4%)
Codon 620 (Cys620Phe, Cys620Gly, Cys620Arg, Cys620Try)	17 (3%)
Exon 11 : codon 634 (Cys634Phe, Cys634Gly, Cys634Arg, Cys634Ser, Cys634Trp, Cys634Try)	472 (84%)
Exon 13 (Gln768Asn)	1 (<1%)
Exon 14	5 (1%)
Val804Met	3 (1%)
Ile852Met	1 (<1%)
Ala883Phe	1 (<1%)
Exon 16 (Met918Thr)	29 (5%)
Data are n (%) unless otherwise indicated. *Occurred with bilateral pheochromocytoma. †11 patients did not develop medullary thyroid carcinoma.	

**Table 1: Patient characteristics**

Charles University, Prague, Czech Republic (Prof P Vlcek MD); Institute of Otolaryngology NAMS of Ukraine, Kiev, Ukraine (S Yaremchuk MD, D Zabolotnyi MD); Familial Cancer Clinic and Oncoendocrinology, Veneto Institute of Oncology, IRCCS Padova, Padova, Italy (F Schiavi PhD); Department of Medicine (DIMED), University of Padova, Padova, Italy (G Opocher MD); 2nd Department of Internal Medicine, Semmelweis University, Budapest, Hungary (K Racz MD); Aix-Marseille University, Department of Endocrine Surgery, La Timone Hospital, Marseille, France (Prof J-F Henry MD); and Genomic Medicine Institute, Lerner Research Institute and Taussig Cancer Institute, Cleveland Clinic, Cleveland, OH, USA (Prof C Eng MD)

Correspondence to: Dr Frederic Castinetti, Aix-Marseille University, Department of Endocrinology, La Timone Hospital, 13005 Marseille, France [frederic.castinetti@ap-hm.fr](mailto:frederic.castinetti@ap-hm.fr)

See Online for appendix



**Figure 2: Cumulative incidence of unilateral and bilateral pheochromocytoma**

This figure includes the 563 patients with pheochromocytoma and the 460 without pheochromocytoma at the last follow-up (ie, the 1023 patients with multiple endocrine neoplasia type 2 for whom complete data were available). See appendix for a graph of overall incidence of pheochromocytoma.

patients were diagnosed with pheochromocytoma during clinical surveillance after testing positive for the *RET* mutation. These data were also available for 95 patients presenting with unilateral pheochromocytoma who later developed a second pheochromocytoma, of whom 57 (60%) had symptoms at diagnosis of the second pheochromocytoma and 38 (40%) were asymptomatic.

Details about surgical treatment were available for 552 (98%) patients with pheochromocytoma. 11 patients refused surgery and were not operated on during our study (table 2, figure 1). Before surgery, 24 centres used  $\alpha$  blockers for 7–15 days in patients with hypertension and also  $\beta$  blockers in patients with tachycardia; three centres used calcium blockers for 7 days; and three used saline perfusion for two to three nights before surgery.

In the 552 patients who had surgery, 438 (79%) underwent adrenalectomies, of whom 181 (41%) had unilateral adrenalectomy. Bilateral adrenalectomy was done in 257 (59%) of 438 patients (figure 1). In 190 (74%) of these 257 patients bilateral pheochromocytomas were found initially, and 67 (26%) patients who had unilateral adrenalectomy underwent a second surgery later because of contralateral pheochromocytoma.

In total, 114 (21%) patients had adrenal-sparing surgery (figure 1, table 3), of whom 32 had unilateral and 82 bilateral pheochromocytoma. In the latter group, bilateral pheochromocytomas occurred as an initial presentation (synchronous) in 54 patients and as a contralateral presentation later (metachronous) in 28 patients. In synchronous bilateral pheochromocytoma, adrenal-sparing surgery was done on one adrenal gland in 21 cases and in both adrenal glands in 33 cases. In patients with

metachronous bilateral pheochromocytoma, adrenal-sparing surgery was done at the first surgery in 11 patients and at the second surgery in 23 patients. Six of these 34 patients had bilateral adrenal-sparing surgery. The frequency of adrenal-sparing surgery increased over time: before 1999, there were 27 (8%) adrenal-sparing surgeries of 319 total operations on the adrenal glands, and this number increased to 66 (17%) of 377 in 1999–2008 and again to 64 (33%) of 195 in 2009–13 ( $p < 0.0001$  for the  $\chi^2$  trend test;  $p = 0.043$  for 2009–13 vs 1999–2008;  $p = 0.013$  for 2009–13 vs before 1999). In the 552 patients who underwent operations for their pheochromocytomas, the mean size of pheochromocytoma operated by adrenal-sparing surgery versus complete adrenalectomy did not differ (3.5 cm [SD 2.2] vs 4.2 cm [2.7];  $p = 0.093$ ). The rate of adrenal-sparing surgery did not differ between asymptomatic patients (44/175 [25%]) and symptomatic patients (70/388 [18%];  $p = 0.068$ ).

Endoscopic surgery was done in 190 of 552 patients (34%, table 2). The frequency of the endoscopic technique increased over time: before 1999, 17 (8%) of 226 operations were endoscopic; compared with 97 (35%) of 281 in 1999–2008, and 90 (64%) of 140 in 2009–13 ( $p < 0.001$  for the  $\chi^2$  trend test;  $p = 0.0008$  for 2009–13 vs 1999–2008;  $p = 0.031$  for 2009–13 vs before 1999). Mean tumour size did not differ in the patients who had endoscopic surgery (3.5 cm [SD 2.1]) compared with those who had open surgery (4 cm [SD 2.5];  $p = 0.11$ ). Intraoperative endoscopic ultrasonography was used occasionally (in five patients) to identify small tumours. Success was similar between open and endoscopic approaches: two recurrences (1%) were reported in the 204 endoscopic procedures (including one with adrenal-sparing surgery) compared with 13 recurrences in the 443 open procedures (3%;  $p = 0.24$ ).

Of the 563 patients, 533 were still alive at the time of study cutoff on Oct 31, 2013, and 30 have died. The causes of death were: metastases of medullary thyroid carcinoma in ten patients; pheochromocytoma crises in four patients (of these, three diagnoses were made post mortem, and one occurred during adrenal surgery despite preoperative treatment by  $\alpha$  blockers for 10 days); pheochromocytoma metastases in one patient; and other causes not related to multiple endocrine neoplasia type 2 in 15 patients.

Recurrence of pheochromocytoma in the same adrenal gland after adrenal-sparing surgery was recorded in four (3%) of 153 operated glands—or in four (4%) of 114 patients (figure 3). These recurrences occurred at 6, 8, 11, and 13 years in these four patients (table 3). One of these patients had been treated by endoscopic surgery. Mean follow-up for the 114 patients who underwent cortical-sparing adrenalectomy was 10 years (SD 9.5; range 1–28 years). After adrenalectomy, 11 (2%) of 717 glands—or 11 of 438 patients—had recurrence of pheochromocytoma after a mean time of 14.2 years

Patients (n=563)	
Unilateral phaeochromocytoma	218 (39%)
Adrenalectomy	181 (85%)
Adrenal-sparing surgery	32 (15%)
Open surgery	125 (59%)
Endoscopic surgery	88 (41%)
No surgery (surgery refusal)	5
Bilateral synchronous phaeochromocytoma	250 (44%)
Adrenalectomy	190 (76%)
Adrenal-sparing surgery	54 (22%)
One adrenal gland	21 (39%)
Both adrenal glands	33 (61%)
Open surgery	178 (73%)
Endoscopic surgery	66 (27%)
No surgery (surgery refusal)	6
Bilateral metachronous phaeochromocytoma	95 (17%)
First surgery	
Adrenalectomy	84 (88%)
Adrenal-sparing surgery	11 (12%)
Open surgery	79 (83%)
Endoscopic surgery	16 (17%)
Second surgery	
Adrenalectomy	72 (76%)
Adrenal-sparing surgery	23 (24%)
Open surgery	61 (64%)
Endoscopic surgery	34 (36%)
No surgery (surgery refusal)	0
Steroid dependency after surgery for bilateral phaeochromocytoma	
All patients	292/339 (86%)
Patients who had adrenal-sparing surgery	35/82 (43%)
Patients who had adrenalectomy	257/257 (100%)

To calculate the percentages in this table, the patients who refused surgery in each group were excluded from the denominators. Six patients with non-synchronous bilateral phaeochromocytoma had adrenal-sparing surgery at their first and second interventions.

**Table 2: Surgery details for patients with phaeochromocytoma**

(SD 6.5; range 1–23). Mean follow-up was 13 years (SD 9.3; range 1–40). There was no significant difference in recurrences between those operated on with adrenal-sparing surgery or with adrenalectomy ( $p=0.57$ ).

Of the 339 patients with bilateral phaeochromocytomas who underwent surgery, 292 (86%) were postoperatively steroid dependent, including 67 (81%) of 83 patients with asymptomatic bilateral phaeochromocytoma. 257 patients had a bilateral adrenalectomy. Adrenal-sparing surgery was attempted in 82 patients with bilateral phaeochromocytoma, either for one or both adrenal glands; 47 (57%) of these patients did not become steroid dependent and were not receiving steroid replacement therapy at final follow-up. Although at present no significant difference exists in phaeochromocytoma-free survival between the patients with bilateral phaeochromocytoma who received total adrenalectomy versus those who had adrenal-sparing surgery (4/82 [4.9%] with adrenal-sparing surgery vs 7/257

Results	
Patients who had the procedure	114/552 (21%)
Follow-up, years	
Mean (SD)	10 (9.5)
Median (IQR)	7 (3–13)
Unilateral phaeochromocytoma	32/114 (28%)
Recurrence	0
Bilateral phaeochromocytoma with adrenal-sparing surgery in one or two operated glands	82/114 (72%)
Recurrence	4 (5%)
Mean time to recurrence (SD)	9.5 years (3.1)
Adrenal gland side	3 right, 1 left
Postoperative steroid dependency	35/82 (43%)

Of the 34 patients with metachronous bilateral phaeochromocytoma who underwent a second surgery, six are included of the 11 who already had a first surgery.

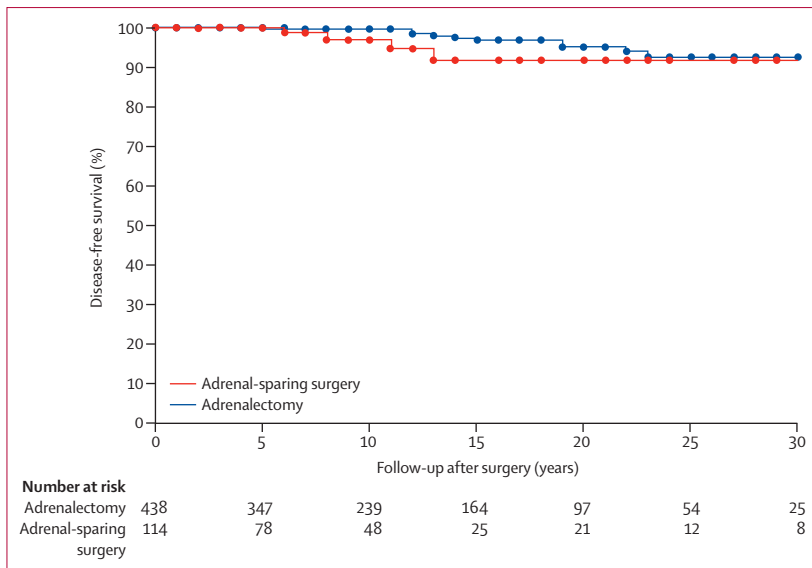
**Table 3: Adrenal-sparing surgery**

[2.7%] with adrenalectomy, difference 2.2% [95% CI  $-0.031$  to  $0.075$ ];  $p=0.57$ ), steroid dependency occurred in all of the 257 patients who had adrenalectomies compared with 42.7% (35/82) of those who had adrenal-sparing surgery (difference  $-57.3\%$  [95% CI  $-0.476$  to  $-0.67$ ;  $p=0.031$ ). The risk of adrenal insufficiency in patients with multiple endocrine neoplasia type 2 with phaeochromocytoma who underwent adrenalectomy was 41% before 50 years of age. Failure to preserve adrenal cortex function was caused by large tumour size (>6 cm diameter), previous contralateral adrenalectomy, and little experience in adrenal surgery. Patients in whom at least a third of one remnant adrenal gland was preserved did not develop adrenal cortical insufficiency. Phaeochromocytomas, such as neoplastic growth of tumour cells in the operation area and instrumentation channel, was not reported at all during follow-up.

647 (53%) of 1210 patients, 307 of whom were male and 340 female, at a mean age of 32.6 years (median 32 years [IQR 18–36]; range 15–89 years), did not have a diagnosis of phaeochromocytoma, although 187 of these patients had incomplete data. Of the 460 patients with complete data, phaeochromocytoma was ruled out by catecholamine measurements in 385 patients, and by biology and additional imaging (CT, MRI, or metaiodobenzylguanidine imaging) in 75. These 460 patients were included in estimations of age-related penetrance (figure 2).

## Discussion

Analysis of this multicentre and multinational registry, which includes a large number of patients with multiple endocrine neoplasia type 2-related phaeochromocytomas operated on during the asymptomatic stage, shows that phaeochromocytoma is nearly exclusively benign, involves both adrenal glands in about two-thirds of patients, is often diagnosed at an asymptomatic stage, and affected patients are mostly operated on before 35 years of age.



**Figure 3: Disease-free survival after adrenal-sparing surgery and adrenalectomy**  
Mean phaeochromocytoma-free survival did not differ between the two procedures ( $p=0.27$ ).

#### Panel: Research in context

##### Systematic review

As part of planning for our study, we did a systematic review in which we searched PubMed with the terms "phaeochromocytoma", "multiple endocrine neoplasia", "adrenal sparing surgery", "adrenalectomy", and "endoscopic adrenal surgery", up until Oct 31, 2013. We included only studies published in English. We then assessed each study for the design and quality of the data retrieved, and we compared the published data with our results. Our systematic review showed that no practice guidelines exist for the surgical management of phaeochromocytoma in multiple endocrine neoplasia type 2, and there is a scarcity of large systematic studies to inform such guidelines.

##### Interpretation

Despite recent improvements in the management of multiple endocrine neoplasia type 2-related phaeochromocytoma, adrenalectomy remains the major treatment option, but is associated with Addisonian-like complications. Adrenal-sparing surgery, a successful option in experienced centres, should be the surgical approach of choice to reduce the complications of classical adrenalectomy for multiple endocrine neoplasia type 2-associated phaeochromocytoma in the context of a low risk of recurrence.

Prevention medicine and cancer genetics are highly interlinked specialties of modern medicine that are increasing in importance. A 20-year history already exists, from the initiation of ideas to the identification of susceptibility genes to planning of the best possible outcome for affected patients.<sup>46</sup> A unique model for this

specialty is multiple endocrine neoplasia type 2, which enabled us to do accurate molecular diagnosis (since *RET* mutations are present in almost all cases), assess genotype-associated neoplasia risks, and undertake genotype-enabled surveillance and prophylaxis and predictive testing of family members.<sup>2,5,12–14</sup> The most fatal complication of multiple endocrine neoplasia type 2 is medullary thyroid carcinoma, which can present as metastatic disease at as early as 4 years of age in multiple endocrine neoplasia type 2B.<sup>15,16</sup> Therefore, the use of prophylactic surgery of the thyroid in genotype-specific age groups became routine but only became codified in formal practice guidelines after more than 10 years of practical use.<sup>4</sup>

By contrast, the other major component neoplasia of multiple endocrine neoplasia type 2, phaeochromocytoma, was believed to be a mostly benign tumour that could be treated by already established conventional methods. The progress that has been achieved in terms of adrenal surgery in general has also been applied to phaeochromocytoma, but rarely by dedicated multiple endocrine neoplasia type 2 teams. Although the idea of adrenal-sparing surgery in familial phaeochromocytoma was introduced in the early 1980s,<sup>17,18</sup> this approach has not become established in the routine multiple endocrine neoplasia type 2 armamentarium or practice guidelines<sup>4</sup> (panel).

Our data can be divided into two parts. The first part deals with the natural history of multiple endocrine neoplasia type 2-related phaeochromocytoma, and the second its treatment and outcomes. The first part unsurprisingly shows the high tendency for the development of bilateral adrenal tumours, with the majority of patients presenting with synchronous and metachronous bilateral disease. As suspected, although never formally proven, adrenal-based phaeochromocytoma predominates, with less than 1% of patients having extra-adrenal phaeochromocytoma. The other extremely rare feature is malignant phaeochromocytoma, which was present in less than 0.5% of the patients in our study. The potential limitations of our study are that the data were analysed retrospectively and that 30 centres contributed patients. Selection bias is unlikely, since the centres contributed all patients with multiple endocrine neoplasia type 2 who had treatment there.

The second part of our audit assesses phaeochromocytoma treatment and outcome. Surprisingly, only a fifth of patients were operated on to preserve part of their adrenal gland. Moreover, only a third of the patients with unilateral or bilateral phaeochromocytoma were operated on by endoscopic technology. However, experience with adrenal surgery, especially adrenal-sparing and endoscopic surgery, varied across centres. Good outcome after removal of a genetic phaeochromocytoma has four main considerations: true recurrence, a second and subsequent primary phaeochromocytoma, additional operation risks, and adrenal insufficiency. In this regard, we have shown that the rates

of recurrence or a second primary tumour do not differ between radical versus conservative surgery. In terms of the potential risks of adrenal-sparing operations, adrenal-sparing surgery does not increase surgical complications such as haemorrhage or infections compared with total adrenalectomies.<sup>18</sup> Finally, we have shown that adrenal insufficiency is greatly reduced in adrenal-sparing operations compared with adrenalectomies. Previous research in adrenal-sparing operations for von Hippel-Lindau-related pheochromocytoma demonstrated surgical success with minimal side-effects (ie, adrenal insufficiency),<sup>19</sup> therefore we recommend that adrenal-sparing surgeries should be strongly considered for the treatment of pheochromocytomas in patients with multiple endocrine neoplasia type 2. In particular, our data support the recommendation that in all patients who have previously lost one adrenal gland or need to be operated on for bilateral adrenal tumours, at least a third of one adrenal gland should be preserved to avoid the development of Addison's disease.<sup>8</sup>

With multiple endocrine neoplasia type 2, patients often experience the replacement of one disease by another: from the high risk of adrenal neoplasia, to the development of Addison's disease with lifelong steroid dependency. This situation emphasises the need for a better management of such patients, with avoidance of over-treatment and its resulting complications—the risk of chronic adrenal insufficiency in patients with bilateral pheochromocytoma is too high for a disease that remains benign in almost all cases. After eradication of the risks of medullary thyroid carcinoma by prophylactic thyroidectomy in patients at risk, we should be able to improve patients' long-term quality of life through adrenal-sparing surgery.

#### Contributors

FC, CE, and HPHN designed the study, interpreted the analyses, drafted and critically revised the report, and approved the final version. FC and X-PQ did the statistical analyses. All the other authors contributed patients and samples, undertook meticulous phenotyping of samples, critically revised the report, and approved the final version.

#### Declaration of interests

We declare that we have no competing interests.

#### Acknowledgments

The study was supported in part by grants from the European Union (grant LSHC-CT-2005-518200); the German Cancer Foundation (grant 107995 to HPHN); the Arthur Blank Foundation in Atlanta, GA, USA (to CE); the Italian Government project on rare diseases (grant 10FF11 to MM); the research programme of Charles University (P27/LF1/1) and a research grant from the Czech Ministry of Health (NT12336-4/2011) (to TZ); the Key Scientific Research Project of Nanjing Military Command, China (09Z038 and 10Z036 to X-PQ); the National Science Centre Poland (grant N401410639 to KH-L and BJ); the National Research Council for Scientific and Technological Development grant 401990/2010-9; the State of São Paulo Research Foundation (FAPESP) grants 2009/11942-1, 11/13518-2, and 13/01476-9 (to RAT, SPAT, and FLC), and grants IGA MH CZ NT/13901-4 and MH CZ 00023761 (to SD). CE is the Sondra J and Stephen

R Hardis Endowed Chair in Cancer Genomic Medicine at the Cleveland Clinic (OH, USA) and is an American Cancer Society Clinical Research Professor. SPAT is a CAPES visiting senior professor at the Federal University State of São Paulo (UNIFESP).

#### References

- 1 Donis-Keller H, Dou S, Chi D, et al. Mutations in the *RET* proto-oncogene are associated with MEN 2A and FMTC. *Hum Mol Genet* 1993; **2**: 851–56.
- 2 Mulligan LM, Kwok JB, Healey CS, et al. Germ-line mutations of the *RET* proto-oncogene in multiple endocrine neoplasia type 2A. *Nature* 1993; **363**: 458–60.
- 3 Machens A, Lorenz K, Sekulla C, et al. Molecular epidemiology of multiple endocrine neoplasia 2: implications for RET screening in the new millennium. *Eur J Endocrinol* 2013; **168**: 307–14.
- 4 Kloos RT, Eng C, Evans DB, et al. Medullary thyroid cancer: management guidelines of the American Thyroid Association. *Thyroid* 2009; **19**: 565–612.
- 5 Neumann HP, Eng C, Mulligan LM, et al. Consequences of direct genetic testing for germline mutations in the clinical management of families with multiple endocrine neoplasia, type II. *JAMA* 1995; **274**: 1149–51.
- 6 Eng C, Clayton D, Schuffenecker I, et al. The relationship between specific *RET* proto-oncogene mutations and disease phenotype in multiple endocrine neoplasia type 2. International RET mutation consortium analysis. *JAMA* 1996; **276**: 1575–79.
- 7 Eng C. Seminars in medicine of the Beth Israel Hospital, Boston. The *RET* proto-oncogene in multiple endocrine neoplasia type 2 and Hirschsprung's disease. *N Engl J Med* 1996; **335**: 943–51.
- 8 Alesina PF, Hinrichs J, Meier B, Schmid KW, Neumann HP, Walz MK. Minimally invasive cortical-sparing surgery for bilateral pheochromocytomas. *Langenbecks Arch Surg* 2012; **397**: 233–38.
- 9 Asari R, Scheuba C, Kaczirek K, Niederle B. Estimated risk of pheochromocytoma recurrence after adrenal-sparing surgery in patients with multiple endocrine neoplasia type 2A. *Arch Surg* 2006; **141**: 1199–205.
- 10 de Graaf JS, Lips CJ, Rutter JE, van Vroonhoven TJ. Subtotal adrenalectomy for pheochromocytoma in multiple endocrine neoplasia type 2A. *Eur J Surg* 1999; **165**: 535–38.
- 11 Stolk RF, Bakx C, Mulder J, Timmers HJ, Lenders JW. Is the excess cardiovascular morbidity in pheochromocytoma related to blood pressure or to catecholamines? *J Endocrinol Metab* 2013; **98**: 1100–06.
- 12 Eng C, Mulligan LM, Smith DP, et al. Low frequency of germline mutations in the *RET* proto-oncogene in patients with apparently sporadic medullary thyroid carcinoma. *Clin Endocrinol* 1995; **43**: 123–27.
- 13 Borrello MG, Smith DP, Pasini B, et al. *RET* activation by germline MEN2A and MEN2B mutations. *Oncogene* 1995; **11**: 2419–27.
- 14 Imai T, Uchino S, Okamoto T, et al. High penetrance of pheochromocytoma in multiple endocrine neoplasia 2 caused by germ line *RET* codon 634 mutation in Japanese patients. *Eur J Endocrinol* 2013; **168**: 683–87.
- 15 Lallier M, St-Vil D, Giroux M, et al. Prophylactic thyroidectomy for medullary thyroid carcinoma in gene carriers of MEN2 syndrome. *J Pediatr Surg* 1998; **33**: 846–48.
- 16 Wells SA Jr, Pacini F, Robinson BG, Santoro M. Multiple endocrine neoplasia type 2 and familial medullary thyroid carcinoma: an update. *J Clin Endocrinol Metab* 2013; **98**: 3149–64.
- 17 Neumann HP, Bender BU, Reincke M, Eggstein S, Laubenberg J, Kirste G. Adrenal-sparing surgery for pheochromocytoma. *Br J Surg* 1999; **86**: 94–97.
- 18 Walz MK. Extent of adrenalectomy for adrenal neoplasm: cortical sparing (subtotal) versus total adrenalectomy. *Surg Clin North Am* 2004; **84**: 743–53.
- 19 Baghai M, Thompson GB, Young WF Jr, Grant CS, Michels VV, van Heerden JA. Pheochromocytomas and paragangliomas in von Hippel-Lindau disease: a role for laparoscopic and cortical-sparing surgery. *Arch Surg* 2002; **137**: 682–88.