

## Accepted Manuscript

Title: Comparative myology of the ankle of *Leopardus wiedii* and *L. geoffroyi* (Carnivora: Felidae): functional consistency with osteology, locomotor habits and hunting in captivity

Authors: Miriam M. Morales, S. Rocío Moyano, Agustina M. Ortiz, Marcos D. Ercoli, Luis I. Aguado, Sergio A. Cardozo, Norberto P. Giannini


PII: S0944-2006(17)30163-0  
DOI: <https://doi.org/10.1016/j.zool.2017.12.004>  
Reference: ZOOL 25621

To appear in:

Received date: 10-7-2017  
Revised date: 9-12-2017  
Accepted date: 20-12-2017

Please cite this article as: Morales, Miriam M., Moyano, S.Rocío, Ortiz, Agustina M., Ercoli, Marcos D., Aguado, Luis I., Cardozo, Sergio A., Giannini, Norberto P., Comparative myology of the ankle of *Leopardus wiedii* and *L.geoffroyi* (Carnivora: Felidae): functional consistency with osteology, locomotor habits and hunting in captivity. *Zoology* <https://doi.org/10.1016/j.zool.2017.12.004>

This is a PDF file of an unedited manuscript that has been accepted for publication. As a service to our customers we are providing this early version of the manuscript. The manuscript will undergo copyediting, typesetting, and review of the resulting proof before it is published in its final form. Please note that during the production process errors may be discovered which could affect the content, and all legal disclaimers that apply to the journal pertain.



Comparative myology of the ankle of *Leopardus wiedii* and *L. geoffroyi* (Carnivora: Felidae): functional consistency with osteology, locomotor habits and hunting in captivity

Morales Miriam M.<sup>a,b,c\*</sup>, Moyano S. Rocío<sup>b,c</sup>, Ortiz Agustina M.<sup>d,e</sup>, Ercoli Marcos D.<sup>b,e</sup>, Aguado Luis I.<sup>d</sup>, Cardozo Sergio A.<sup>c,d</sup>, Giannini Norberto P.<sup>f,g</sup>

<sup>a</sup> Centro de Investigaciones y Transferencia de Jujuy. Consejo Nacional de Investigaciones Científicas y Técnicas (CONICET). San Salvador de Jujuy, C.P. 4600, Jujuy, Argentina.

<sup>b</sup> Instituto de Ecorregiones Andinas (INECOA), Universidad Nacional de Jujuy, Consejo Nacional de Investigaciones Científicas y Técnicas (CONICET). San Salvador de Jujuy, C.P. 4600, Jujuy, Argentina.

<sup>c</sup> Centro de Estudios Territoriales Ambientales y Sociales. Facultad de Ciencias Agrarias, Universidad Nacional de Jujuy. Alberdi 47, San Salvador de Jujuy, C.P. 4600, Jujuy, Argentina.

<sup>d</sup> Facultad de Ciencias Agrarias, Universidad Nacional de Jujuy. Alberdi 47, San Salvador de Jujuy, C.P. 4600, Jujuy, Argentina.

<sup>e</sup> Instituto de Geología y Minería, Universidad Nacional de Jujuy. Av. Bolivia 1661, San Salvador de Jujuy, C.P. 4600, Jujuy, Argentina.

<sup>f</sup> Unidad Ejecutora Lillo. Consejo Nacional de Investigaciones Científicas y Técnicas. Miguel Lillo 251, San Miguel de Tucumán, C.P. 4000, Tucumán, Argentina.

<sup>g</sup> American Museum of Natural History, Department of Mammalogy. Central Park West at 79th Street, New York, NY 10024-5192, United States.

\* Corresponding author at Centro de Estudios Territoriales Ambientales y Sociales,  
Facultad de Ciencias Agrarias, Universidad Nacional de Jujuy. Alberdi 47, San  
Salvador de Jujuy, C.P. 4600, Jujuy, Argentina. [moralesmiriamm@gmail.com](mailto:moralesmiriamm@gmail.com)

Silvana Rocío Moyano: [s.rociomoyano@gmail.com](mailto:s.rociomoyano@gmail.com)

Agustina Mariana Ortiz: [agustinaortiz129@gmail.com](mailto:agustinaortiz129@gmail.com)

Marcos Darío Ercoli: [marcosdarioercoli@hotmail.com](mailto:marcosdarioercoli@hotmail.com)

Luis Ignacio Aguado: [luis.ignacio\\_28@yahoo.com.ar](mailto:luis.ignacio_28@yahoo.com.ar)

Sergio Antonio Cardozo: [sergio\\_8008@hotmail.com.ar](mailto:sergio_8008@hotmail.com.ar)

Norberto Pedro Giannini: [norberto.giannini@gmail.com](mailto:norberto.giannini@gmail.com)

## Highlights

1. Margay is the only fully arboreal Neotropical felid and is able of complete hindfoot reversal.
2. Margay's invertor muscles of the tarsal joint were stronger than those in Geoffroy's cat.
3. EDLat is heavier and helps widening the holding surface of the foot of the margay.
4. In captivity Margay was able to hang head down releasing its forefeet to secure prey.
5. Captive Margay was more time efficient in hunting bird prey as compared with *L. geoffroyi*.

## ABSTRACT

*Leopardus wiedii* (margay) is the only arboreal Neotropical felid able to climb head-first down trees, due to its ability to rotate its tarsal joint 180°. A closely related, similar-sized species, *L. geoffroyi* (Geoffroy's cat) exhibits more typical terrestrial habits and lacks the arboreal capabilities of *L. wiedii*. There is osteological evidence that supports a mechanical specialization of *L. wiedii*'s tarsal joint for inversion, but there have been no studies on the myology of this specialization. Based on comparative gross-anatomy dissections of zeugo- and autopodial muscles related to the ankle joint of one margay specimen and two Geoffroy's cats, we identified myological specializations of *L. wiedii* that support its arboreal abilities. In addition, we documented both species hunting the same prey (domestic pigeon *Columba livia*, Aves: Columbidae) in captivity, to complement. We report differences in the origin, insertion and belly in 8 of the 10 dissected muscles. At least 3 of these interspecific variations can be associated with strengthening of the main muscles that command inversion/eversion movements of the

tarsal joint and support the body weight in the head-down climbing position typical of *L. wiedii*. Frame-by-frame video reconstructions depict the sequence of movements in these species while hunting and highlight the advantages of the arboreal abilities of *L. wiedii*.

Key words: arboreal; Geoffroy's cat; hind foot reversal; margay; myology

ACCEPTED MANUSCRIPT

## 1. INTRODUCTION

Hindlimb suspension ability is a significant foraging strategy that has arisen independently in a number of mammalian lineages, and is functionally related to the enhancement of hind foot reversal ability (e.g., Primates, Pilosa, Rodentia, Carnivora; Trapp, 1972; McEvoy, 1982; Jenkins and McClearn, 1984; Szalay, 1985; Meldrum et al., 1997; Candela and Picasso, 2008; Liu et al., 2016). In mammals [including the margay, *Leopardus wiedii* (Schinz, 1821)], specific bone modifications are key to achieve hind foot reversal (Jenkins and McClearn, 1984; Szalay, 1985; Heinrich and Rose, 1997; Ercoli, 2015; Liu et al., 2016) and it involves three joint movements: crurotalar plantar flexion, subtalar inversion and transverse tarsal supination (see Jenkins and McClearn, 1984; Meldrum et al., 1997).

Comparative myological studies of diverse carnivorans with contrasting locomotor modes (e.g., Windle and Parsons, 1897, 1898; Gambaryan, 1974; Taylor, 1976; Fisher et al., 2008; Ercoli et al., 2013) and specializations (e.g., large felids and myological reconstruction of saber-toothed cats: Antón et al., 2004; sprinting: Williams et al., 2008; Hudson et al., 2011a, b; arboreal specializations: Carlon and Hubbard, 2012) are available. However, myological studies about hind foot reversal are scarce. Among Carnivora, the only previous broadly comparative research was made by Liu et al. (2016) on *Bassariscus astutus* (Lichtenstein, 1830), a small (0.7-1.5 kg) Neotropical procyonid (Poglayen-Neuwall and Toweill, 1988). These authors did not find any myological differences in muscles characteristics or dimensions between *B. astutus* and other compared procyonids or other carnivores with different locomotor modes. However, they suggested that better-developed digital flexors, which maintain a grip while the body mass is supported by the hind limb, could characterize taxa capable of

making reversed postures. Also, some other carnivorans able to complete hind foot reversal were myologically described, at least partially, such as *Potos flavus* (Beswick-Perrin, 1871; Julitz, 1909) and *Neofelis nebulosa* (Carlon and Hubbard, 2012).

Particularly within Felidae, studies on muscle anatomy and function remain limited and have focused primarily on large species (e.g., Cuvier and Laurillard, 1850; Ross, 1876; Windle and Parsons, 1898; Barone, 1967; Gambaryan, 1974; Antón et al., 2004; Pacot, 2009; Hudson et al., 2011a, b). Most myological studies of small wild felids are relatively recent (e.g., Beswick-Perrin, 1871; Carlon and Hubbard, 2012; Julik et al., 2012; Viranta et al., 2016). Moreover, at present only the ankle myology and tarsal function of the domestic cat (another predominantly terrestrial felid) have been extensively studied within Felidae (e.g., Jayne, 1898; Reighard and Jennings, 1902; Davidson, 1903; Smith et al., 1977; O'Donovan et al., 1982; Lawrence et al., 1993; Young et al., 1993). As occurs in other species, most of the muscles acting at the cat ankle joint do not have an exclusive function, having different degrees of influence on each of the three spatial dimensions (Lawrence et al., 1993; Lawrence and Nichols, 1999; supplementary Fig. S1), and in some particular cases, a different function according to the starting position of the ankle joint (Young et al., 1992, 1993). Also, there is a sort of plane of symmetry about which the cat ankle joint is stabilized to enhance control during locomotion. To achieve this control or stabilization, co-contraction of antagonist muscles around an axis of rotation has been recognized as necessary (Young et al., 1992, 1993; Lawrence et al., 1993). Meanwhile, for wild felids, the mechanics of tarsal movements has only been described osteologically for *L. wiedii*; subtalar inversion and transverse tarsal supination movements were described as playing the main role in hind foot reversal in *L. wiedii* (Jenkins and McClearn, 1984). Although

there are no similar studies for *L. geoffroyi*, the osteological characteristics of the calcaneum and astragalus of *L. geoffroyi* are more similar to those of *F. catus* than to those of *L. wiedii* (Morales, pers. obs.), indicating limited subtalar movement in *L. geoffroyi* (see Jenkins and McClearn, 1984). There are no bibliographic reports of full or partial hind foot reversal for any other South American felid species. Furthermore, no myological study documents comparative variation associated with *L. wiedii*'s specialization. Fresh material from small Neotropical felids is still limited; therefore, access to appropriate specimens represents a unique opportunity to gain insight into the functional myology that is associated with different life modes of these species.

*Leopardus wiedii* is one of the four species of extant felids able to reverse its hind feet (Sunquist and Sunquist, 2002, 2009), and the only Neotropical felid capable of climbing head-first down trees and hanging from its fully reversed feet. This is accomplished primarily by complete reversal of its feet for holding the surface of tree trunks while descending (Leyhausen, 1963; Jenkins and McClearn, 1984). The closely related *Leopardus geoffroyi* (d'Orbigny and Gervais, 1844) (Geoffroy's cat; Johnson et al., 2006) is a predominantly terrestrial South American felid of comparable size (Guggisberg, 1975; Ximénez, 1975; Oliveira, 1994; Sunquist and Sunquist, 2002, 2009). *Leopardus wiedii* commonly consumes arboreal prey, although records on preference vary across regions, while *L. geoffroyi* consistently prefers small terrestrial prey, mostly rodents (Weigel, 1975; Ximenez, 1975; Álvarez del Toro, 1977; Konecny, 1989; Johnson and Franklin, 1991; Oliveira, 1994; Branch, 1995; Azevedo, 1996; Facure and Giaretta, 1996; Oliveira, 1998; Wang, 2002; Manfredi et al., 2004; Bisceglia et al., 2008; Sousa and Bager, 2008; Pereira, 2009; Rocha-Mendes and Bianconi, 2009;



Rocha-Mendes et al., 2010; Bianchi et al., 2011; Cinta-Magallón et al., 2012; Pereira et al., 2012).

In this contribution we study the muscular specializations related to foot reversal abilities of the specialized arboreal *L. wiedii* in comparison to the terrestrial *L. geoffroyi*, both small Neotropical felids. For the first time this morpho-functional relationship is tested in two closely related carnivoran species (same genus) of similar size, but with contrasting habits. With the aid of gross-anatomy dissections, we aimed to identify characters in hind limb musculature that could be associated with differences in tarsal movements and their possible influence on locomotion and hunting behavior in these two species. We complemented our myological data with observations of these species while hunting in captivity, which we believe greatly increases our understanding of adaptations of these wild felids to different modes of life. Such an approach has been an important source of information for understanding the capabilities and behavior of mammalian species, especially those that are difficult to observe in the wild such as felids (e.g., Leyhausen, 1963; Muul and Lim, 1970; Leyhausen, 1979; Petersen, 1979). On the base of different capabilities known and observed in felids and correlated with known osteological differentiation, we expect to find differences in muscle characteristics (e.g., differentiation of bellies, origin or insertion areas), or differences in the relative size (i.e., muscle mass) of muscles which control the ankle and thus pes movements, especially in invertors and their antagonists, which correlate with differences in forces generated and supported by this anatomical region.

## 2. MATERIALS AND METHODS

### 2.1. Dissections

We performed detailed dissections of 10 muscles related to movements of the tarsal joint in one specimen of *L. wiedii* (one complete limb) and two specimens of *L. geoffroyi* (two complete limbs and two partial limbs). All specimens studied were adults, based on a fully erupted adult dentition. The *L. wiedii* specimen was a female; it was fixed using commercial formalin (formaldehyde 40%) and is stored at the Museo Nacional de Historia Natural, Montevideo, Uruguay (MNHN 6432, from Arroyo Garzón on Road 9, Rocha, Uruguay, found dead on the road, assumed to be wild). The *L. geoffroyi* specimens were both males, and they were fixed following Woods (1972; one part of formalin (formaldehyde 40%) to 18 parts of water saturated with NaCl). One of these specimens (CML 10787) is stored at the Colección Mamíferos Lillo, San Miguel de Tucumán, Argentina. This specimen was wild-caught while juvenile and then lived in captivity for several years before dying. The other specimen (INBIAL-Ma 001) was found dead on the National Road 34, between Calilegua (Lote Libertad) and the entrance to Caimancito, Departamento Ledesma, Jujuy Province, Argentina, and we assumed it to be wild. Before dissection, specimens were transferred to 70% ethanol for manipulation and conservation. Dissections were performed extracting each muscle, describing form, origin, insertion, and relation to other muscles. We obtained a detailed photographic record of observed characters and produced illustrated muscular maps of every studied muscle. In the case of *L. wiedii*, we obtained fresh weight of each muscle (eliminating liquid excess), while for both specimens of *L. geoffroyi*, dissected muscles were dehydrated in a “San Jor” sterilization stove at 200°C and then weighed. Due to conservation problems with stored muscles we were only able to get complete weighing of the hind limb of the margay and one complete hind limb of *L. geoffroyi*. These

muscles mass data were standardized by the total mass of extracted muscles of each hind limb, in order to analyze the relative proportions of the main functional group of muscles, reducing the biases of different body sizes and weighing methodologies.

Muscle nomenclature follows *Nomina Anatomica Veterinaria* (Waibl et al., 2005), and muscular functions, as well as topological and functional terminology principally follow Lawrence et al. (1993). Throughout this study, movements of the tarsal joint were defined as follows: flexion/extension, are movements in the sagittal plane (can also be referred to as dorsiflexion and plantarflexion); adduction/abduction, are those movements in a transverse plane of the leg which makes the toes move medially and laterally, respectively; and eversion/inversion movements are related to rotation around the longitudinal axis of the foot, with the former equivalent to pronation and the latter equivalent to supination movements of the forelimb's autopods. These movements, especially the last two, are achieved by multiple tarsal articulations (see Jenkins and McClearn, 1984)

## 2.2. Behavioral observations

Our behavioral observations consisted of video recording one individual of each species while hunting living prey in captivity at the Estación de Cría Montes del Plata, M´Bopicuá, Uruguay. Observations were made in separate cages for each captive specimen during the time of ordinary feeding. Animals were offered the same prey (living domestic pigeons, *Columba livia*, Aves: Columbidae). The cage was made of wire mesh and measured for *L. wiedii* ca. 50 m<sup>2</sup> (10 x 5m x 2.50 m) and for *L. geoffroyi* ca. 27 m<sup>2</sup> (9 m x 3 m x 2.50 m). Recordings were obtained with the video function of a Canon PowerShot G10 camera of 14 MP and analyzed in the laboratory. Frame traces

were taken from footage to simplify the analysis of movements; these are presented as sketches of the captured movement sequences in Section 3.2.

### 3. RESULTS

#### 3.1. Dissections

In the following, we first describe the common characteristics of the dissected muscles and then highlight the inter- and intraspecific differences.

##### 3.1. 1. *M. tibialis cranialis* (*Tcr*; Figs. 1, 2, 3 and supplementary Figs. S1, S2)

It is large and the cranialmost of all muscles of the crural region. In both felids, this muscle originates from the lateral edge of the cnemial crest and the medial border of the anterior process of the head of the fibula (Fig. 1). Proximally, the belly splits up slightly to allow the tendon of *m. extensor digitorum longus* to pass through. *Leopardus wiedii* also exhibited an extra origin area which includes approximately one half of the caudal border of the lateral surface of the diaphysis of the tibia, the adjacent interosseous membrane and the proximal half of the cranio-medial surface of the diaphysis of the fibula (Figs. 1 and supplementary Fig. S2B). The crural extensor retinaculum holds this muscle near the ankle joint. The interosseous membrane and the fascia which covers the *m. tibialis cranialis* seem stronger in *L. wiedii* than in *L. geoffroyi*. In both felids the muscle inserts via a strong tendon at the first metatarsal (Fig. 2). *M. tibialis cranialis* flexes the ankle joint, inverts the pes and helps in adduction movements (Lawrence et al., 1993; Evans and de Lahunta, 2013). It may help in abduction movements depending on the initial angle of the joint (Young et al., 1993).

### 3.1.2. *M. extensor digiti I longus* (EDIL; Figs. 1, 2 and 3)

This muscle could not be recognized and was considered absent in *L. wiedii* and one specimen of *L. geoffroyi*. Nevertheless, in one specimen we recognized a separate group of fibers, although almost completely fused to m. tibialis cranialis. This “belly” could be interpreted as the remains of m. extensor digiti I longus which is largely fused with m. tibialis cranialis. This fusion could result in the muscle being easily overlooked, which may be why it is not recognized in some specimens. In the only limb found, it consisted in an elongated and undefined group of fibers which separated from m. tibialis cranialis’ belly easily, but was not surrounded by fascia, and was continuous with m. tibialis cranialis’ muscular fibers. Distally both muscles were completely fused. Origins of this muscle for this specimen only are represented in Figure 1. Given the fusion of the m. extensor digiti I longus with m. tibialis cranialis, the functions of these muscles are inferred to be the same.

### 3.1.3. *M. extensor digitorum longus* (EDLon; Figs. 2, 3 and supplementary Fig. S3)

It is a fusiform muscle, which originates via a strong tendon from the lateral surface of the distal epiphysis of the femur, cranial to the origin of the lateral collateral ligament (not shown). It passes through the sulcus extensorius of the tibia and runs beneath m. tibialis cranialis. Distally, it becomes superficial, lateral to the m. tibialis cranialis, and together, they pass through the crural extensor retinaculum. Muscular fibers are replaced by a tendon just before entering the tarsal extensor retinaculum; almost immediately the tendon separates into four tendons, which run distally over the dorsal aspect of the four digits. As it advances, each tendon receives and blends to other

tendons of intrinsic muscles of the foot. Digit V receives the tendons of corresponding medial and lateral mm. interossei. Digits IV and III receive the corresponding interossei tendons and one tendon of m. extensor digitorum brevis each. Digit II receives the tendons of the corresponding mm. interossei and two tendons of m. extensor digitorum brevis. For each digit, the area in which tendons fuse together forms a round, cup-like extensor expansion, which surrounds dorsally the articular joint between proximal and middle phalanges in digits III-V and the metatarso-phalangeal joint of digit II. This extensor expansion is attached to both sides of the distal end of the proximal phalange (digits III, IV and lateral aspect of digit V, not shown) via a short band of a ligament-like tissue. On the lateral aspect of digit V a shiny tendinous-like band attaches the tendon of m. extensor digitorum longus to the ventral aspect of the proximal end of the middle phalange. In *L. wiedii*, we found a small (1-1.5 mm of diameter) sesamoid of cartilaginous aspect on the dorsal side of the metatarso-phalangeal joint of digit III. It was embedded in a band of tendinous aspect which runs from the ventral side of the tendon of m. extensor digitorum longus and attaches to the dorsal aspect of the proximal phalanx between its proximal and second fourth (supplementary Fig. S3). In digit II, the tendons of mm. extensor digitorum longus, extensor digitorum brevis and the corresponding interossei fuse at the level of the metatarso-phalangeal joint in *L. wiedii* and form a sheath covering the dorsal and lateral aspects of the proximal phalanx and the articulation between proximal and middle phalanxes, attaching strongly to the dorsal aspect of the proximal end of the middle phalanx (Fig. 2). Then, it inserts through narrow flat tendons on each of the median regions of the caudal surface of the distal phalanges of the four digits.

In *L. geoffroyi* the main recognized difference was in the position of fusion of the tendons in digit II, which occurs at the level of the interphalangeal joint as in digits III-V. It was not possible to corroborate all lateral small attachments in this species. Muscle extensor digitorum longus extends the digits, but also flexes the ankle joint, everts the pes and helps in adduction/abduction movements, depending on the initial joint angle (Young et al., 1993; Evans and de Lahunta, 2013).

#### 3.1.4. *M. extensor digitorum lateralis* (EDL; =*fibularis tertius*; Figs. 1, 2 and 3)

This is a slender muscle lying deep to the m. fibularis longus and continues between the mm. fibularis brevis and flexor digitorum lateralis. In *L. wiedii*, it originates from fleshy fibers from a reduced area of the latero-cranial surface of the fibula at the level between the first and second proximal quarters of its diaphysis (Figs. 1A and B). In one specimen of *L. geoffroyi*, a small tendinous origin was also recorded on the head of the fibula (Fig. 1F). The fleshy belly is replaced by a thin tendon before reaching the level of the crural extensor retinaculum. The tendon then passes through the sulcus of the lateral malleolus, deep to the tendon of m. fibularis brevis. The tendon has a first insertion onto the lateral aspect of the proximal end of the proximal phalanx of the digit V (Fig. 2) by means of a small tendinous transversal band. We could not confirm the final insertion of this tendon, but it probably blends with the tendons of m. extensor digitorum longus and the external m. interosseus of the fifth digit, fusing in a common tendon that inserts onto the middle and distal phalanges (see m. extensor digitorum longus). No interspecific variation was found in general morphology of this muscle, but weight data suggest a larger relative mass in *L. wiedii* than in *L. geoffroyi*. Muscle extensor digitorum lateralis inverts the pes, slightly flexes the ankle joint (Lawrence et

al., 1993) and helps in abduction movements of the hind foot (Young et al., 1993); it also abducts and extends digit V (Evans and de Lahunta, 2013).

#### 3.1.5. *M. fibularis longus* (FiL; Figs. 1, 2 and 3)

It is an elongated muscle which originates from the cranio-lateral surface of the proximal end of the diaphysis of the fibula (Fig. 1). It covers the proximal portions of the mm. extensor digitorum lateralis and fibularis brevis. Muscular fibers give rise to a tendon just before entering to the crural extensor retinaculum. At the ankle joint it crosses the sulcus of the lateral malleolus where it is held by a strong and thick fascial mass. Distally, the tendon passes superficial to the tendons of the mm. extensor digitorum lateralis and fibularis brevis, and through the groove on the lateral side of the ventral surface of the fourth tarsal. Finally, it crosses the plantar surface transversely inside a sulcus located between the tarsal and metatarsal bones, heading for the second metatarsal and inserting on the planto-lateral region of its base. In one specimen of *L. geoffroyi*, some subtle insertions were observed on the base of all other metatarsal bones. *M. fibularis longus* everts and abducts the pes and flexes the ankle joint (Lawrence et al., 1993; Young et al., 1993).

#### 3.1.6. *M. fibularis brevis* (FiB; Figs. 1, 2, 3 and supplementary Fig. S4)

This is an elongated muscle, laying deep to the m. extensor digitorum lateralis between the mm. fibularis longus and flexor digitorum lateralis. In *L. wiedii*, the origin of this muscle is completely fleshy and attaches strongly to a wider surface than in *L. geoffroyi*; fibers run from the membrana interossea cruris and the lateral aspect of the diaphysis of the fibula (Figs. 1 and supplementary Fig. S4B). *Leopardus geoffroyi*



presents a very variable condition for the origin area of *m. fibularis brevis*. The muscular belly consistently lies on the lateral surface of the fibula, but most fibers could be easily removed from the bone, except at the cranial border. In one specimen, the muscle originates at the proximal region of the diaphysis of the fibula via a very thin aponeurosis which runs distally until muscular fibers occur at the level of the half of the diaphysis of the fibula (supplementary Fig. S4A). One limb of the other specimen had an extra origin via a thin tendon from the head of the fibula, while the muscular belly originated from the cranial border of the three distal fourths of the diaphysis of the fibula. The other limb did not have the tendinous proximal origin, but had the same fleshy origin described for the other limb. In both species, muscular fibers reach the level of the lateral malleolus where the muscle becomes a strong tendon and crosses the ankle joint. It inserts on the dorsolateral aspect of the base of the fifth metatarsal (Fig. 2). *M. fibularis brevis* is mostly related with eversion movements at the ankle joint and abduction of the pes, while also having a small role in flexion of this joint (supplementary Fig. S1; Lawrence et al., 1993; Young et al., 1993; Lawrence and Nichols, 1999).

### 3.1.7. *M. flexor digitorum profundus*

This muscle is compound by three muscles: *m. flexor digitorum lateralis* (= *m. flexor hallucis longus*), *m. flexor digitorum medialis* (= *flexor digitorum longus*) and *m. tibialis caudalis*. The first two bellies fuse and give rise to a plantar, exclusively tendinous, portion. These bellies are anatomical synergists, but in *F. catus* they present a functional dissociation, with activity patterns largely independent and dissociated

during treadmill locomotion and coactivation during jumping and landing (O'Donovan et al., 1982). *M. tibialis caudalis* constitutes a completely separate unit.

#### 3.1.7.1 *M. flexor digitorum lateralis* (FDPL; Figs. 1, 2 and 3)

It is a large bulky muscle, which originates from the caudal surfaces of the tibia and fibula (Fig. 1). Distally, muscular fibers reach the level of the distal epiphysis of the tibia where they end in a tendon, which passes through a canal just lateral to the one for the tendon of *m. flexor digitorum medialis* and on the medial side of the calcaneus (immediately caudal to the sustentacular process), towards the plantar side of the foot, where it joins the *m. flexor digitorum medialis*.

The origin area of *m. flexor digitorum lateralis* was larger in *L. wiedii* than in one specimen of *L. geoffroyi*, but about the same size (longer but narrower) in the other specimen. Muscle weight did not show any particular difference (Fig. 3), so we did not find a strong preponderance of this muscle in any of the species.

*M. flexor digitorum lateralis* flexes the digits and extends the ankle joint, it is an antigravity extensor, resembling the *mm. gastrocnemius* and *soleus* (O'Donovan et al., 1982). It also helps to invert and adduct the foot (Lawrence et al., 1993; Evans and de Lahunta, 2013). The later movements may change to everting and abduction respectively, depending on the initial angle of the joint when the muscle is activated (Young et al., 1993).

#### 3.1.7.2. *M. flexor digitorum medialis* (FDPM; Figs. 1, 2, 3 and supplementary Fig. S5)

It is a large spindle-shaped muscle that lays between the *mm. popliteus* and *flexor digitorum lateralis*, and partially covers *m. tibialis caudalis*. It originates from the caudal

region of the head of the fibula, surrounding the proximal region of m. soleus, and from the caudal surface of the tibia (Fig. 1). At the distal end of the middle third of the muscle, a strong aponeurosis raises and continues distally as a strong tendon. This aponeurosis was longer, but narrower and weaker, in *L. geoffroyi* than in *L. wiedii*. The tendon runs distally and passes through a canal at the distal epiphysis of the tibia, just between the one for the tendon of m. tibialis caudalis and the one for m. flexor digitorum lateralis.

In *L. wiedii*, the proximal fibers of mm. flexor digitorum medialis and tibialis caudalis intermingled in a compact mass, although distinct fiber directions of each muscle were visible (supplementary Fig. S5). In three limbs of dissected *L. geoffroyi*, the m. tibialis caudalis segregated completely and in one, shared fibers with m. flexor digitorum medialis. The muscle weight data suggest that this muscle is larger in *L. wiedii* (Fig. 3).

Muscles flexor digitorum lateralis and medialis fuse at the level of the proximal tarsal row and continue as a strong flat tendon. At about the same level, this tendon receives the insertion of the m. quadratus plantae. The tendon divides in four strong thick and rounded tendons which run towards the distal phalanges of digits II to V. These tendons are strongly attached to the base of the proximal phalanges, passing through the manica flexoria. At the ankle joint, m. flexor digitorum medialis works mostly on inversion and adduction of the foot, but also slightly extends the ankle joint and flexes the digits (Lawrence et al., 1993; Young et al., 1993; Evans and de Lahunta, 2013).

### 3.1.7.3 *M. tibialis caudalis* (*Tcd*; Figs. 1, 2, 3 and supplementary Fig. S5)

This is a spindle-shaped muscle. In *L. wiedii*, it is located deep to the mm. popliteus, flexor digitorum medialis and lateralis, but this relationship is slightly different in *L. geoffroyi*, where m. tibialis caudalis is mostly covered by the m. flexor digitorum medialis and flanked laterally by m. flexor digitorum lateralis. In both species, the muscular belly is bifurcated proximally, presenting two origin areas, one larger and tibial and the other smaller and fibular. The tibial origin is fleshy and occupies a little less than the proximal half of the caudal surface of the tibia; it is larger in *L. wiedii* than in *L. geoffroyi*. The second origin begins from a smaller region in the medial surface of the fibula (Fig. 1). One specimen of *L. geoffroyi* presented a smaller fibular origin restricted to a reduced area of the head of the fibula. Fibers from the fibular origin run distally towards the principal belly and fuse with it within the proximal fourth of the tibia. In both cats the total muscular belly occupies a little less than the proximal half of the tibia; distal to this point the muscle becomes tendinous. The distal tendon passes through the medial most notch of the medial malleolus to the plantar aspect of the foot. In *L. wiedii*, after passing the calcaneus and the talus, the tendon is closely appressed to the ligaments below cuneiforms I and II and the first metatarsal, inserting subtly on the latter. In one specimen of *L. geoffroyi*, the final insertion is onto the cuneiform I. In the other specimen, the tendon divided in two just before the insertion: the medial split inserts as in the other specimen, and the lateral split inserts onto the distal end of the ventral surface of the neck of the talus (Fig. 2). This muscle is fused partially with m. flexor digitorum medialis in *L. wiedii* and in one of the four limbs dissected of *L. geoffroyi*. Muscle tibialis caudalis is a strong invertor of the ankle joint and helps in adduction movement of the pes; it also subtly extends the ankle joint (Lawrence et al., 1993). Young et al. (1993) suggest that this muscle is capable of

both, inversion/eversion movements, depending on the initial angle of the joint, but always extends and adducts the pes.

3.1.8. *M. flexor digitorum superficialis* (FDS; = *m. plantaris*) and *m. flexor digitorum brevis* (FDB; Figs. 1, 2 and 3)

These muscles are described together as they are completely continuous among each other. The *m. flexor digitorum superficialis* originates in the lateral fabella, just proximal to the origin of the lateral head of the *m. gastrocnemius*. The *m. flexor digitorum superficialis* passes medial to the middle belly of the lateral head of *m. gastrocnemius*, with which it shares an aponeurosis. Some additional fibers originate from the patella and the fascia surrounding it, sharing this origin area with fibers of the lateral head of *m. gastrocnemius* (see below). The belly, on its caudal surface, has a strong fusiform aponeurosis.

Near the ankle joint, muscular fibers are replaced by a tendon which surrounds the tendons of *mm. gastrocnemius + soleus*, reaching a superficial (caudal) position. Distally the tendon widens, enclosing the caudal region of the proximal end of the calcaneal tuberosity forming a cup of cartilaginous aspect. From this cup, follows distally a flat and wide tendon from which originates the *m. flexor digitorum brevis*. At the level of this tendon there are two insertions on the lateral and medial aspect of the calcaneal tuber (Fig. 2). The lateral one is by means of transversal tendinous fibers that hold the tendon to the calcaneal tuber, just below the long part of the lateral collateral ligament of the ankle joint. The medial insertion is much stronger because the same tendon extends medially to insert. In the ventral aspect of the foot, the tendinous origin of *m. flexor digitorum brevis* gives rise to four, proximally inseparable muscular bellies

which separates towards digits II to V. Approximately at the level of the middle of the metatarsal series they become tendons. At the level of the metatarso-phalangeal joint each tendon forms a sheath (manica flexoria) which attaches to the ventral border of the sesamoid bones of each digit. Each tendon then divides in two narrower ones forming a ring, through which the tendons of m. flexor digitorum profundus passes through, and then continues to insert in the ventral aspect of the base of the middle phalange of the corresponding digits. No interspecific variation was found. Muscle flexor digitorum superficialis extends the ankle joint while m. flexor digitorum brevis is a flexor of the digits (Young et al., 1993; Evans and de Lahunta, 2013).

3.1.9. *M. triceps surae* (mm. soleus and gastrocnemius; Figs. 1, 3 and supplementary Fig. S6)

M. soleus is a fusiform elongated muscle lying deep to the mm. gastrocnemius and flexor digitorum superficialis. It originates from the caudal process of the head of the fibula (Figs. 1D, I). In *L. wiedii*, the insertion is composed by a single tendon which fuses with the one from m. gastrocnemius (supplementary Figs. S6C, D). In *L. geoffroyi*, the m. soleus exhibited two insertions on the proximal end of the calcaneal tuber, one small and dorsal and the other larger and plantar (supplementary Figs. S6A, B). Muscle soleus has the same actions on the cruro-tarsal joint that m. gastrocnemius, but with smaller effect (Smith et al., 1977; Walmsley et al., 1978; Sacks and Roy, 1982; Lawrence et al., 1993).

The m. gastrocnemius is a large muscle which occupies the most caudal position on the crus. It is compound by a lateral and a medial head. The medial head originates from the medial fabella via fleshy fibers and through the fabella from the distal end of

the caudo-lateral surface of the femur's diaphysis via a strong fan-shaped tendon (not shown). This area of origin is just caudal to the insertion of m. semimembranosus, although in one *L. geoffroyi* the origin was distal to the latter.

Proximally, the lateral head of m. gastrocnemius (LG) divides in three parts. One belly originates more distally and laterally and is very small and sharp proximally. It originates from the superficial fascia of the zeugopodium surrounding the knee joint and from a small but strong tendon that fuses with the deep surface of the aponeurosis of the m. biceps femoris, distal to its muscular fibers. Just distal to its origin, this small belly fuses completely with the largest belly, to which we will refer as middle belly. The latter comprises most of the muscle. It originates from the proximal region of the lateral fabella of the femur via fleshy fibers while the fabella attaches to the distal end of the caudo-lateral surface of the femur's diaphysis via a strong fan-shaped tendon. The common fibular nerve passes between these two bellies. The third belly is small and originates via a strong aponeurosis from the lateral edge of the patella and fusing with the adjacent tissue. The muscular fibers cross over and caudo-medially to the middle belly and fuse to the medial surface of the latter, sharing fibers with the m. flexor digitorum superficialis. Although the third belly was observed in three limbs of *L. geoffroyi* (in the fourth limb could not be confirmed), it seemed not to share fibers with the m. flexor digitorum superficialis in this species.

In *L. wiedii*, the m. gastrocnemius has a strong superficial aponeurosis, better developed on the lateral head of the muscle, which continues distally to form part of the common calcaneal tendon. In *L. geoffroyi* this aponeurosis is a very thin tendinous sheet. The common calcaneal tendon was slightly longer and wider in *L. geoffroyi*. Additionally, the lateral head of m. gastrocnemius has a deep aponeurosis from which

originates part of the belly of the m. flexor digitorum superficialis. This aponeurosis also marks the place where the middle and third belly of the lateral head separates. In one limb of *L. geoffroyi* some fibers of the lateral head of m. gastrocnemius originated from the aponeurosis of m. flexor digitorum superficialis.

In both species, the m. gastrocnemius inserts onto the lateral and plantar borders of the proximal end of the calcaneus. In *L. wiedii* the insertion was stronger, extended more cranially, and fused with the single insertion of the m. soleus (supplementary Figs. S6C, D). This muscle is a strong extensor of the tarsal joint, everts the pes and has a strong abduction effect in *F. catus* (Lawrence et al., 1993). It is as fast-contracting muscle, anatomically and physiologically suited for more forceful and rapid ankle extensions, as required during jumping and galloping (Smith et al., 1977; Walmsley et al., 1978; Sacks and Roy, 1982).

### 3.2. Behavioral observations

Video recordings of captive animals allowed us to reconstruct a step-by-step sequence of movements of these species while catching a domestic pigeon (Figs. 4, 5 and Videos S1 and S2 in the supplementary online Appendix). Sequences in Figures 4 (*L. wiedii*) and 5 (*L. geoffroyi*) show the position of the body and paws grabbing the wire fence when climbing to catch their prey. Remarkably, *L. wiedii* freed its forefeet from body support during prey capture, allowing the body to rotate while clinging from the hind paws only, and then climbing down the wire fence head down once the prey was secured in the mouth. By contrast, *L. geoffroyi* depended heavily on its forefeet along the whole sequence; the animal climbed down in successive lateral rotations, always head up and supported on all four paws, thus being unable to use the forefeet for



seizing prey. Time differences were also notable; while *L. geoffroyi* spent about 6 seconds in climbing up and down and hunting the dove; *L. wiedii* used less than half of the time in completing a comparable action. These observations are the picture-perfect examples of everything that is already known about the behavior of these species (e.g., Leyhausen, 1963, 1979; Sunquist and Sunquist, 2002, 2009 and citations therein).

#### 4. DISCUSSION

Myological differences between the investigated species suggest stronger musculature in *L. wiedii* than in *L. geoffroyi*. Some of the differences found could be interpreted as functionally associated with the ability of reversing the hind feet and hanging from them in *L. wiedii*, corroborating our hypothesis. These results differ from those of Liu et al. (2016) in musteloids. Subsequently, we discuss each of these muscular features in a comparative framework.

##### **4.1. Presence and fusion of *m. extensor digiti I longus***

The absence or presence of the *m. extensor digiti I longus* has been pointed out as a diagnostic feature for many of the families of Carnivora (e.g., Windle and Parsons, 1898; Fisher et al., 2008). Fisher et al. (2008) stated that the absence or reduction of this muscle is clearly tied to the reduction of the hallux in some lineages (e.g., felids, hyaenids, canids, and some other more generalized carnivorans); despite this general trend, this muscle persists in some species. Nevertheless, its presence is variable within Felidae. The muscle was reported to be present in *Acinonyx jubatus* (Ross, 1876), *Panthera tigris* (Macalister, unpublished data cited in Windle and Parsons, 1898), and

*Leopardus pardalis* (Windle and Parsons, 1898). It was described as variably present in *Panthera leo*, *P. pardus*, *Felis catus*, and the here studied *L. geoffroyi* (Rudolphi, 1820; Mivart, 1881; Jayne, 1898; Windle and Parsons, 1898; Reighard and Jennings, 1902; Davidson, 1903; Taylor and Weber, 1951; Barone, 1967; Sebastiani and Fishbeck, 2005; and is not visible in illustrations of *Panthera* spp. of Cuvier and Laurillard, 1850). In the single *L. wiedii* specimen here analyzed the muscle could be considered absent (or indistinguishable from m. tibialis cranialis), and a similar situation was recorded by Beswick-Perrin (1871) in *Caracal caracal*.

Among Carnivora, information about fusion of m. extensor digiti I longus and other muscles of the zeugopod is scarce, and within Felidae, the condition seems also variable. The m. extensor digiti I longus has been described as fused with m. tibialis cranialis in *F. catus* (Windle and Parsons, 1898; Sebastiani and Fishbeck, 2005), *L. geoffroyi*, and *L. wiedii* (see Section 3.1.2.), while in *A. jubatus* its belly was described as fused with m. extensor digitorum longus, but distinguishable at the level of the tendons (Ross, 1876). The fusion of m. extensor digiti I longus with m. extensor digitorum longus was not mentioned in Hudson's et al. cheetah study (2011a), but is occasionally observed in the cursorial carnivoran *Canis familiaris* (Evans and de Lahunta, 2013: 270). In summary, the diverse range of arrangement of m. extensor digiti I longus for felids, even variable for some genera and species, does not seem to be clearly related to any specific factor here considered.

#### ***4.2. Relative size and position of the combination of mm. tibialis cranialis and extensor digiti I longus***

M. tibialis cranialis has been proposed as possessing a major role in foot inversion in some mammals, including erethizontid rodents (McEvoy, 1982) and the squirrel *Sciurus aberti* (Pierotti, pers. comm. cited in Jenkins and McClearn, 1984; but see Peterka, 1936). In *S. aberti* electrical stimulation of the tibialis anterior nerve produced a ca. 90° foot inversion regardless of whether the foot is plantar flexed or dorsiflexed. The function of this muscle has been experimentally observed in *F. catus* (Lawrence et al., 1993; Young et al., 1993; Lawrence and Nichols, 1999), and m. tibialis cranialis has been found to be the strongest invertor of the foot. The major role of this muscle in inversion movements was also suggested for *L. wiedii* (among other studied mammals) based on osteological data (see Jenkins and McClearn, 1984).

Among carnivorans, there exist some variations in the origin area of m. tibialis cranialis and m. extensor digiti I longus. A larger origin area of these muscles together, mostly associated with m. extensor digiti I longus reaching or extending beyond the half of the fibula, sometimes accompanied by an origin of m. tibialis cranialis reaching the proximal region of the fibula (i.e., laterally extended regarding its always present tibial origin) were reported for most of the generalist, scansorial and arboreal taxa: viverrids (*Arctictis binturong*; Carlsson, 1920), ailurids (*Ailurus fulgens*; Fisher et al., 2008), procyonids (e.g., *Bassariscus astutus*; Liu et al., 2016; *Nasua* spp.; Mackintosh, 1875; McClearn, 1985; *Potos flavus*, Julitz, 1909; *Procyon lotor*; Gowell, 1897; McClearn, 1985) and mustelids (*Martes americana*; Hall, 1926). The size of the origin area is particularly well-developed in arboreal and large-sized taxa, and is also recorded in the large-sized, primarily terrestrial felid *P. leo* (Barone 1967). The combined origin of these muscles in ursids such as *Ailuropoda melanoleuca* (Davis, 1964), *Ursus americanus* (Shepherd, 1883) and *U. malayanus* (Ray, 1949), together with the aquatic

*Enhydra lutris* (Howard, 1975) is also large, although with a different configuration. In these species, m. extensor digitorum I longus originates distally on the zeugopod and both muscles, tibialis cranialis and extensor digitorum I longus may originate on the fibula, –in addition to the always present tibial origin of m. tibialis cranialis – (*Ailuropoda melanoleuca*; Davis, 1964; *U. malayanus*; Ray, 1949; *E. lutris*; Howard, 1975), or completely from the tibia and the interosseous membrane (*U. americanus*; Shepherd, 1883). This condition, especially enhanced in ursids and *E. lutris*, could be related to their plantigrade configuration and their large size. In these plantigrade and non-cursorial species, a broad and safe contact with the substrate and muscular control of the autopodium is prioritized, contrary to cursorial and digitigrade species in which a reduction of the contact surface with the substrate and the inertia of the limbs are promoted (Hildebrand, 1988; Taylor, 1989; Argot, 2002; Hudson et al., 2010).

Conversely, a condition of reduced origin area for both muscles (fused or not), mostly restricted to the proximal region of the zeugopod, and in some cases accompanied by a totally absent fibular origin, is recorded in most of the small-sized primarily terrestrial and/or cursorial taxa, with (inferred or confirmed) reduced inversion movements. This condition is exemplified by felids (*A. jubatus*; Ross, 1876; *F. catus*; Mivart, 1881; Jayne, 1898; Reighard and Jennings, 1902; *L. geoffroyi*; this study), hyaenids (*Crocuta crocuta*; Watson and Young, 1879; *Proteles cristata*, Watson, 1882), herpestids (*Herpestes ichneumon*; *Ichneumia albicauda*; Taylor, 1976), canids (*C. familiaris*, Evans and de Lahunta, 2013), mustelids (*Galictis cuja*; Ercoli et al., 2013) and mephitids (*Mephitis mephitis*; Hall, 1926). This reduced configuration is also recorded in the small-sized scansorial *Genetta* spp. (Taylor, 1976).

Beyond this, when considering muscles weight among diverse carnivorans (Gambaryan, 1974) we do not observe a clear relationship between origin area and muscle weight data at the ordinal level and a remarkable segregation of relative weight exists among families (see supplementary Table S1). For example, despite having distally extended origin areas, ursids have a very light m. tibialis cranialis with respect to the total weight of the hind limb (0.88-1.41%; Gambaryan, 1974: 247). Nevertheless, a more clearly defined relationship between these variables seems to arise at lower hierarchical levels (e.g., family). *Acinonyx jubatus* (1.4) presents the lowest value for felids (and similar to canids; 1.0-1.9), while other felids have higher weight values (2.1-2.9). In this case, the reduction in the origin area is accompanied by weight reduction of this muscle in the most cursorial species. Mustelids present typically heavier m. tibialis cranialis than the rest of the families (2.66-3.81), but the most arboreal taxa analyzed by Gambaryan (1974), *Martes foina*, have the highest weight value (4.13). Accordingly, this species belongs to a mustelid genus which is able to perform reversal of the foot (Haines, 1958; Liu et al., 2016). Unfortunately, data are still scarce and prevent us from reaching a definitive conclusion, although an incipient trend of heavier m. tibialis cranialis in species capable of hind foot reversal (or at least more arboreal species) can be seen among mustelids and felids when compared to other closely related species. Contrasting these results (and others considering muscles weight) with data from physiological cross-sectional areas of each muscle would be desirable in further investigations.

In the case of the present study, *L. wiedii* possesses a notably heavier and broadly developed origin area of the m. tibialis cranialis + m. extensor digiti I longus than *L. geoffroyi* (Figs. 1 and 3). In consequence, we assess that these myological differences

are related to the more arboreal specialization of the former, and functionally linked to enhanced inversion movements of the ankle and reversal of the foot present in *L. wiedii*.

#### 4.3. *M. flexor digitorum medialis*

*M. flexor digitorum medialis* is always present in Carnivora (e.g., Windle and Parsons, 1898). Together with *m. flexor digitorum lateralis*, they are considered anatomic synergists, although in *F. catus*, *m. flexor digitorum lateralis* works better in extending the tarsal joint, while *m. flexor digitorum medialis* has a more important role in inverting and adducting the pes, and almost no extension function on the ankle joint (Lawrence et al., 1993; Young et al., 1993; Lawrence and Nichols, 1999).

When data of muscle maps available are analyzed, *m. flexor digitorum medialis* seems to have a generally reduced origin area in a wide and diverse sample of carnivorans, such as felids (*L. geoffroyi*, *L. wiedii*, *F. catus*, *A. jubatus*; Jayne, 1898: 706; Hudson et al., 2010: 6; this study), viverrids (*G. genetta* and *G. tigrina*; Taylor, 1976: 237), herpestids (*H. ichneumon* and *I. albicauda*; Taylor, 1976: 237), the mustelid *G. cuja* (Ercoli et al., 2013: 320), the procyonid *Procyon lotor* (Gowell, 1897: Plate XVI), the canid *C. familiaris* (Evans and de Lahunta 2013: 265) and the ursid *Ailuropoda melanoleuca* (an arboreal taxon with relatively reduced inversion movements; Davis, 1964: 143-144). However, the origin area of this muscle is particularly more developed in two highly arboreal species which are able to climb head-first down trees and have ample inversion movements: *B. astutus* (capable of complete hind foot reversal; Liu et al., 2016) and *Ailurus fulgens* (which is capable of at least partial, if not complete, hind foot reversal; Fisher et al., 2008; Liu et al., 2016). In the present study, muscle weight and origin areas suggest that *m. flexor digitorum*

medialis is relatively larger in *L. wiedii* than in *L. geoffroyi* (Fig. 3). Thus, we suggest that a greater m. flexor digitorum medialis (evidenced by the origin area data), is present in arboreal carnivorans with enhanced inversion movements, and this relationship is confirmed in *L. wiedii* in relation to *L. geoffroyi* (supported by the origin area and muscle weight) and other felids (based on the origin area).

#### **4.4. *M. tibialis caudalis***

This muscle was found to be a strong invertor muscle in *F. catus* (Lawrence et al., 1993). Although m. tibialis caudalis is one of the smallest muscles of the zeugopod in *F. catus*, experimental studies have shown that it exerted the strongest toe-in torque during tarsal movement, thus revealing the importance of the levering system at the cat's ankle joint (Lawrence et al., 1993). Toe-in torque in this muscle is also important, and rivaled that of m. tibialis cranialis and sometimes even the magnitude of the toe-out torques exerted by the m. triceps surae (Young et al., 1993; Lawrence and Nichols, 1999; see Table 1 in Lawrence et al., 1993 and Fig. S1 in the supplementary online Appendix).

As in m. tibialis cranialis, m. tibialis caudalis was found to have different degrees of expansion among carnivores, and the reduction of this invertor muscle in cursorial species is also recorded. There is a more generalized pattern where m. tibialis caudalis originates from the middle or proximal part of the caudal region of the tibia and part of the head of the fibula, and sometimes the adjacent interosseous membrane. This pattern was observed in felids (*F. catus*, Mivart, 1881; Jayne, 1898; Reighard and Jennings, 1902; Taylor and Weber, 1951; Sebastiani and Fishbeck, 2005; *P. leo*, Barone, 1967; but Rudolphi, 1820, who described a tibial only origin; *L. geoffroyi*, *L. wiedii*, this study); viverrids (*Genetta tigrina*, Mivart, 1882; Taylor, 1976; *Viverra civetta*,

Macalister, 1873a); herpestids (*H. ichneumon* and *I. albicauda*, Taylor, 1976); the hyaenid *Proteles cristata* (Watson, 1882); the ailurid *Ailurus fulgens* (Fisher et al., 2008; but not Carlsson, 1925, who described origin from the proximal tibia only); procyonids (*B. astutus*; Liu et al., 2016; *Nasua* spp.; McClearn, 1985; *Procyon lotor*, Gowell, 1897), mustelids (*Aonyx cinereus*; Macalister, 1873b; *Eira barbara*; Macalister, 1873a; *G. cuja*; Ercoli et al., 2013; *Martes americana*; Hall, 1926); and mephitids (*Mephitis mephitis*; Hall, 1926). *M. tibialis caudalis* in *Arctictis binturong* (Carlsson, 1920), *Mustela putorius* (Alix, 1876) and *U. americanus* (Shepherd, 1883) was described as originating from the tibia only, but no special mention about the reduction was made by the authors in those cases. In more cursorial species this muscle can be reduced, e.g., *A. jubatus* (Felidae; Ross, 1876; but also in *Cynictis penicillata*, Herpestidae; Windle and Parsons, 1897); or absent or reduced, e.g., Canidae (Windle and Parsons, 1898; *C. familiaris*; Haughton, 1867; Evans and de Lahunta, 2013) and some Hyaenidae (*H. striata*; Young and Robinson, 1889; Windle and Parsons, 1897; *Crocuta crocuta*; Watson and Young, 1879; Windle and Parsons, 1897). As was described for *m. tibialis cranialis* and *extensor digiti I longus*, the *m. tibialis caudalis* of *Ailuropoda melanoleuca* (Davis, 1964) and *E. lutris* (Howard, 1975) differs from that in other carnivorans because they have very large origin areas but a more distal disposition of this muscle. No weight comparison could be made for this muscle, but the pattern observed in ursids and the sea otter could be related to size and plantigrade conditions, as was stated above for other zeugopodial muscles.

Information about the fusion and insertion of *m. tibialis caudalis* and other muscles in Carnivora is scarce, and available information does not allow seeing any emerging pattern in a large perspective.



In this work, we found that *m. tibialis caudalis* has a smaller origin area in *L. geoffroyi* than *L. wiedii* (see Fig. 1), but the weight of muscles does not differ (Fig. 3). The latter finding prevents us from claiming functional differences between the studied species. The only available comparable muscular map for a felid is from *F. catus* and is more similar to *L. wiedii* (Jayne, 1898), thus, more dissections and weighing would be necessary.

#### **4.5. *M. fibularis brevis***

This muscle was found to be associated with eversion and toe-out torques at the tarsal joint in the domestic cat (Lawrence et al., 1993; Young et al., 1993; Lawrence and Nichols, 1999) and appears to be a good antagonist for *m. flexor digitorum medialis* (see supplementary Fig. S1), which we have already mentioned is larger in *L. wiedii* than in *L. geoffroyi*; thus, we expected to find differences between species in this muscle.

Comparison among other carnivorans did not show any clear pattern in the way this muscle changes throughout previously studied carnivorans. Our study suggests that the origin area of this muscle is particularly variable in *L. geoffroyi*, but we never found a strongly attached fibrous belly as was recorded in *L. wiedii*, and the width of the origin area is clearly larger in the latter (Fig. 1). This difference is not reflected when comparing the muscle weight in both species, thus no clear functional pattern can be related to this muscle (Fig. 3).

#### **4.6. *M. extensor digitorum lateralis***

Although no differences were found between origin/insertion areas of the studied species, muscles weight allowed us to recognize a larger m. extensor digitorum lateralis in *L. wiedii*. This muscle is the main muscle responsible for the extension and abduction of the fifth digit (Evans and de Lahunta, 2013; Liu et al., 2016), while its role in the eversion of the pes is debatable (e.g., Lawrence et al., 1993; Young et al., 1993; Liu et al., 2016). In arboreal species in general, and in felids in particular, autopods tend to be wider in order to widen the support surface for climbing (e.g., Argot, 2002; Meachen-Samuels and Van Valkenburgh, 2009). Thus, m. extensor digitorum lateralis could play an important function in spreading the digits so as to augment *L. wiedii*'s grip.

## 5. Comprehensive functional comments

The only previous comparative myological work performed in carnivorans in relation to the hind foot reversal is the one made by Liu et al. (2016), focusing on *B. astutus*. Additionally, some other carnivorans capable of hind foot reversal have also been described, at least partially, such as *Potos flavus* (Julitz, 1909) and *N. nebulosa* (Carlson and Hubbard, 2012). Liu and collaborators (2016) did not find significant myological differences with other carnivorans which are incapable of foot inversion. These authors concluded that the position during suspension can be achieved primarily because of particular osteological features, without myological specializations. Conversely, our results suggest that *L. wiedii* has myological adaptations which complement its osteological specializations for hind foot reversal; i.e., stronger pes invertors (mm. tibialis cranialis + extensor digiti I longus, and flexor digitorum medialis). When studying *F. catus*, Young et al. (1993) found that most muscles working outside of the sagittal plane increased their moment arms when the joint is

moved away from neutral in a direction which elongates the muscle, thus suggesting that these muscles are particularly effective at pulling the joint back toward a neutral position, but not in deflecting it away from the neutral position. As a result, these authors indicate that “the cat can effectively level and center the foot following external perturbations, but it may have relatively little ability voluntarily to deflect its foot away from this neutral position in the absence of external forces” (Young et al., 1993: 148). This difficulty could explain the need for stronger adductor/abductor and invertor/eversor muscles in *L. wiedii* in two ways, the need for more musculature to compensate the small moments arms to actively complete reversal of the foot, or stronger musculature to stabilize the ankle joint being exposed to stronger/different forces when climbing down head-first or hanging from the feet.

Mm. flexor digitorum medialis and extensor digitorum lateralis can also enhance digital strength for grabbing tree trunks when climbing head-first or hanging from their feet, as suggested by Liu et al. (2016). Furthermore, the stronger abductor of the lateral digits (i.e., m. extensor digitorum lateralis) of *L. wiedii* seems to contribute to increasing the support surface during climbing. In addition to specific myologic considerations, it is worthwhile noting that *L. wiedii* has particularly longer hind limbs than other small South American felids due to its longer crus (tibia and fibula; Morales and Giannini, 2013). Thus, most of the studied muscles might have relatively longer effort arms in this species, as compared with *L. geoffroyi*. This osteological difference may influence the jumping ability of *L. wiedii*, given that a longer hind limb enables a longer contact period with the ground while jumping, favoring stability and lowering energy costs (Hudson et al., 2011a).

Differences between our results and those achieved by Liu and collaborators (2016) may be ascribed to different reasons. One notable thing is that in the three carnivoran species able to complete hind foot reversal according to the available myologic data (*B. astutus*; Peterka, 1936; Liu et al., 2016; *P. flavus*; Julitz, 1909; and *N. nebulosi*; Carlon and Hubbard, 2012) modifications of muscles of the hip were recognized, apparently helping rotational movements and abduction. This could imply that the hip joint is also involved in achieving hind foot reversal in these species, which is not supposed to happen in *L. wiedii*, as it was discounted by Jenkins and McClearn (1984). *Leopardus wiedii*'s hip myology remains to be studied so this inference is not conclusive.

Probably, the differences in the results arise from the fact that we could contrast detailed dissections of two closely related species of similar size; this allowed us to find subtle myological differences, which were then studied in a more extensive comparative framework. Thus, lack of differences in Liu et al. (2016) can be related to variations in body size, habits and phylogenetic affinities between compared species (see for example Ximenez, 1975; Poglayen-Neuwall and Toweill, 1988; Wilson and Mittermeier, 2009). Clearer morpho-functional patterns arise when closely related and similar-sized species are compared. This is particularly patent in the case of the mm. tibialis cranialis + extensor hallucis longus, for which a clear relationship between the enhanced condition of the origin area and marked arboreal habits emerges when similar-sized and closely related species are compared, as in our study. The same size difference between these muscles was highlighted by other authors in one-to-one comparisons, such as *Genetta* (arboreal) vs. *Herpestes* or *Ichneumia* (primarily terrestrial) (Taylor, 1976: 236) and *Mephitis mephitis* vs. *Martes americana* (Hall, 1926: 35). Additionally, the effect of

large body size differences could have masked the expected functional pattern in Liu et al. (2016). For example, Julitz (1909) denoted well-developed mm. tibialis cranialis and extensor digiti I longus for *Potos flavus* (able to perform full hind limb reversal); when we compared it with descriptions of other procyonids of similar size (i.e., *Nasua* and *Procyon*; see McClearn, 1985), difference in muscle size is likely; but this difference might have passed unnoticed when comparing the smaller-sized *Bassariscus* of Liu et al. (2016), which possesses similar reversal abilities.

Part of the myological variation found between the closely related and similar sized *L. wiedii* and *L. geoffroyi* can be more clearly linked to the enhancement of the hind foot reversal of the former (mm. tibialis cranialis + extensor hallucis longus and m. flexor digitorum medialis) and other movements related to support body weight in a head-down position, either while climbing down head-first, or hanging from a branch by its hind feet (m. extensor digitorum lateralis), sometimes with prey secured in the mouth (e.g., Fig. 4; Video S1). These myological observations fit nicely with the mechanical model proposed by Jenkins and McClearn (1984) based on tarsal osteology. These functional aspects, i.e., the osteological architecture of the tarsal joint (Jenkins and McClearn, 1984) and the stronger musculature to support its movements (this study), lend support to the observed behavior of *L. wiedii*. The major behavioral difference observed with respect to a closely related and comparable terrestrial felid counterpart (*L. geoffroyi*) could be directly related to *L. wiedii*'s ability to turn its hind feet 180° and hang head down. This allows *L. wiedii* to release its forefeet to secure prey before transferring it to the mouth, in less than half the time used by *L. geoffroyi* to complete the prey's capture sequence in a captivity setting. Thus, comparative behavioral observations of hunting in captivity allowed us to gain insight into the importance of

this functional adaptation, highlighting the clear advantages of *L. wiedii* as a predator in its stratified forest environment.

## ACKNOWLEDGEMENTS

We would like to thank Enrique González and Yennifer Hernández (Museo Nacional de Historia Natural, Montevideo, Uruguay); María Inés Zamar (Instituto de Biología de Altura, Jujuy, Argentina) and Rubén Barquez and Mónica Díaz (Colección Mamíferos Lillo, Tucumán, Argentina) for granting access to specimens under their care. We thank Juan Villalba and Estación de Cría Montes del Plata (Fray Bentos, Uruguay) for allowing captivity observations and filming. Thanks to Facultad de Ciencias Agrarias and Instituto de Geología y Minería, Universidad Nacional de Jujuy, for providing labs and infrastructure. Many thanks to Yennifer Hernandez and Alicia Álvarez for time and support. Thanks to Juliana Rajmil and Sofía D'Hiriart for helping during dissections. Many thanks to Elliott Smith (Marian Koshland Bioscience and Natural Resources Library, University of California, Berkeley), Julieta Grajales Conesa and Eduardo Reyes Grajales for assistance in obtaining difficult to find references. We thank Zack Shawn and three anonymous reviewers for their improvements to this manuscript. This work was partially supported by Consejo Nacional de Investigaciones Científicas y Técnicas (CONICET) and by Agencia Nacional de Promoción Científica y Tecnológica (PICT 2015-0708 to M.M.M.).

## REFERENCES

- Álvarez del Toro, M., 1977. Los mamíferos de Chiapas. Universidad Autónoma de Chiapas, Tuxla Gutierrez, Chiapas, Mexico.
- Alix M.E., 1876. Memoire sur la myologie du putois (*Putorius communis*, Cuv.). J. Zool. Paris. 5,153-188.
- Antón, M., Salesa, M.J., Pastor, J.F., Sánchez, I.M., Fraile, S., Morales, J., 2004. Implications of the mastoid anatomy of larger extant felids for the evolution and predatory behaviour of sabretoothed cats (Mammalia, Carnivora, Felidae). Zool. J. Linn. Soc. 140, 207–221.
- Argot, C., 2002. Functional-adaptive analysis of the hindlimb anatomy of extant marsupials and the paleobiology of the Paleocene marsupials *Mayulestes ferox* and *Pucadelphys andinus*. J. Morphol. 108, 76-108.
- Azevedo, F.C.C., 1996. Notes on the behavior of the margay *Felis wiedii* (Schinz, 1821), (Carnivora: Felidae), in the Brazilian Atlantic Forest. Mammalia 60, 325-328.
- Barone, R., 1967. La myologie du lion (*Panthera leo*). Mammalia 31, 459-516.
- Beswick-Perrin, J., 1871. On the myology of the limbs of the kinkajou (*Cercoleptes caudivolvulus*). Proc. Zool. Soc. Lond. 1871, 547–571.
- Bianchi, R.D.C., Rosa, A.F., Gatti, A., Mendes, S.L., 2011. Diet of margay, *Leopardus wiedii*, and jaguarundi, *Puma yagouaroundi* (Carnivora: Felidae) in Atlantic Rainforest, Brazil. Zoologia 28, 127–132.
- Bisceglia, S.B.C., Pereira, J.A., Teta, P., Quintana, R.D., 2008. Food habits of Geoffroy's cat (*Leopardus geoffroyi*) in the central Monte desert of Argentina. J. Arid Environ. 72, 1120-1126.
- Branch, L.C., 1995. Observations of predation by pumas and Geoffroy's cats on the plains vizcacha in semi-arid scrub of central Argentina. Mammalia 59, 152-156.

- Candela A.M. Picasso M.B.J., 2008. Functional anatomy of the limbs of Erethizontidae (Rodentia, Caviomorpha): indicators of locomotor behavior in Miocene porcupines. *J. Morphol.* 269, 552–593.
- Carlson, B., Hubbard, C., 2012. Hip and thigh anatomy of the clouded leopard (*Neofelis nebulosa*) with comparison to the domestic cat (*Felis catus*). *Anat. Rec.* 295, 577–589.
- Carlsson, A., 1920. Über *Arctictis binturong*. *Acta Zool.* 1, 337-380.
- Carlsson, A., 1925. Über *Ailurus fulgens*. *Acta Zool.* 6, 269-305.
- Cinta-Magallón, C.C., Bonilla-Ruz, C.R., Alarcón-D, I., Arroyo-Cabrales, J., 2012. Dos nuevos registros de margay (*Leopardus wiedii*) en Oaxaca, México, con datos sobre hábitos alimentarios. *Cuad. Investig. UNED* 4, 33-40.
- Cuvier, G., Laurillard, M., 1850. Anatomie Comparée: Recueil de Planches de Myologie. Chez Dusacq, Paris.
- Davidson, A., 1903. Mammalian Anatomy: with Special Reference to the Cat. P. Blakiston's son & Co, Philadelphia.
- Davis, D.D., 1964. The giant panda: a morphological study of evolutionary mechanisms. *Fieldiana Zool. Memoirs* 3, 1–339.
- Ercoli, M.D. 2015. Morfología del aparato músculo-esquelético del postcráneo de los mustélidos (Carnivora, Mammalia) fósiles y vivientes de América del Sur: implicancias funcionales en un contexto filogenético. Ph.D. Thesis, Universidad Nacional de La Plata, La Plata, Argentina.
- Ercoli, M.D., Echarri, S., Busker, F., Álvarez, A., Morales, M.M., Turazzini, G.F., 2013. The functional and phylogenetic implications of the myology of the lumbar



- region, tail, and hind limbs of the lesser grison (*Galictis cuja*). *J. Mamm. Evol.* 20, 309–336.
- Evans, H.E., de Lahunta, A., 2013. *Miller's Anatomy of the Dog*, fourth ed. China: Elsevier Saunders.
- Facure, K.G., Giaretta, A.A., 1996. Food habits of carnivores in a coastal Atlantic Forest of southeastern Brazil. *Mammalia* 60, 499–502.
- Fisher, R.E., Adrian, B., Elrod, C., Hicks, M., 2008. The phylogeny of the red panda (*Ailurus fulgens*): evidence from the hindlimb. *J. Anat.* 213, 607–628.
- Gambaryan, P.P., 1974. *How Mammals Run. Anatomical adaptations*. John Wiley & Sons, New York.
- Gowell, R.C., 1897. Myology of the hind limb of the raccoon. *Kan. Univ. Quar.* 6, 121–126.
- Guggisberg, C.A.W., 1975. *Wild Cats of the World*. David, Charles, Newton Abbot, London.
- Haines, R. W., 1958. Arboreal or terrestrial ancestry of placental mammals. *Q. Rev. Biol.* 33, 1–23.
- Hall, E.R., 1926. The muscular anatomy of three mustelid mammals, *Mephitis*, *Spilogale*, and *Martes*. *Univ. Calif. Publ. Zool.* 30, 7–39.
- Haughton, S., 1867. On the muscular anatomy of the lion. *Proc. R. Irish Acad. Sci. Ser.* 2, 85–93
- Heinrich, R.E., Rose, K.D., 1997. Postcranial morphology and locomotor behaviour of two early Eocene miacoid carnivorans, *Vulpavus* and *Didymictis*. *Paleontology* 40, 279–305.

- Howard, L.D. 1975. Muscular anatomy the hind limb of the sea otter (*Enhydra lutris*).  
Proc. Calif. Acad. Sci. 40, 335–416.
- Hudson, P.E., Corr, S.A., Payne-Davis, R.C., Clancy, S.N., Lane, E., Wilson, A.M.,  
2011a. Functional anatomy of the cheetah (*Acinonyx jubatus*) hindlimb. J. Anat. 218,  
363-374.
- Hudson, P.E., Corr, S.A., Payne-Davis, R.C., Clancy, S.N., Lane, E., Wilson, A.M.,  
2011b. Functional anatomy of the cheetah (*Acinonyx jubatus*) forelimb. J. Anat. 218,  
375-385.
- Jayne, H., 1898. Mammalian Anatomy, A Preparation for Human and Comparative  
Anatomy. Part I. The Skeleton of the Cat, Its Muscular Attachments, Growth, and  
Variations Compared with the Skeleton of Man. J. B. Lippincott Company,  
Philadelphia.
- Jenkins, F.A., McClearn, D., 1984. Mechanisms of hind foot reversal in climbing  
mammals. J. Morphol. 182, 197–219.
- Johnson, W.E., Franklin, W.L., 1991. Feeding and spatial ecology of *Felis geoffroyi* in  
Southern Patagonia. J. Mammal. 72, 815-820.
- Johnson, W.E., Eizirik, E., Pecon-Slattery, J., Murphy, W.J., Antunes, A., Teeling, E.,  
O'Brien, S., 2006. The late Miocene radiation of modern Felidae: a genetic  
assessment. Science 311, 73-77.
- Julik, E., Zack, S., Adrian, B., Maredia, S., Parsa, A., Poole, M., Starbuck, A., Fisher,  
R.E., 2012. Functional anatomy of the forelimb muscles of the Ocelot (*Leopardus  
pardalis*). J. Mamm. Evol. 19, 277-304.

- Julitz, C., 1909. Osteologie und Myologie der Extremitäten und des Wickelschwanzes vom Wickelbären, *Cercoleptes caudivolvulus*: mit besonderer Berücksichtigung der Anpassungserscheinungen an das Baumleben. Arch Naturgesch Berlin 75, 143–188.
- Konecny, M.J., 1989. Movement patterns and food habits of four sympatric carnivore species in Belize, Central America, In: Redford, K.H. (Ed.), Advances in Neotropical mammalogy. Sandhill Crane Press, Gainesville, FL, pp. 243–264.
- Lawrence, III J.H., Nichols, R., 1999. A three-dimensional biomechanical analysis of the cat ankle joint complex: I Active and passive postural mechanics. J. Appl. Biomech. 15, 95-105.
- Lawrence, III J.H., Nichols, T.R., English, A.W., 1993. Cat hindlimb muscles exert substantial torques outside the sagittal plane. J. Neurophysiol. 69, 282-285.
- Leyhausen, P., 1963. Über südamerikanische Pardelkatzen. Z. Tierpsychol. 20, 627–640.
- Leyhausen, P., 1979. Cat Behavior: The Predatory and Social Behavior of Domestic and Wild Cats. Garland STPM Press, New York.
- Liu, M., Zack, S.P., Lucas, L., Allen, D., Fisher, R.E., 2016. Hind limb myology of the ringtail (*Bassariscus astutus*) and the myology of hind foot reversal. J. Mammal. 97, 211-233.
- Macalister, A. 1873a. The muscular anatomy of the *civet* and *tayra*. Proc. R. Irish Acad. Ser. 1, 506-513.
- Macalister, A., 1873b. On the anatomy of *Aonyx*. Proc. R. Irish Acad. Ser. 2, 539-547.
- Mackintosh, H.W., 1875. Notes on the myology of the coati-mondi (*Nasua narica* and *N. fusca*) and common marten (*Martes foina*). Proc. R. Irish Acad. Ser. 2, 48–55.

- Manfredi, C., Lucherini, M., Canepuccia, A.D., Casanave, E.B., 2004. Geographical variation in the diet of Geoffroy's cat (*Oncifelis geoffroyi*) in pampas grassland of Argentina. *J. Mammal.* 85, 1111-1115.
- McClearn, D., 1985. Anatomy of raccoon (*Procyon lotor*) and coati (*Nasua narica* and *N. nasua*) forearm and leg muscles: Relations between fiber length, moment- arm length, and joint- angle excursion. *J. Morphol.* 183, 87-115.
- McEvoy, J.S., 1982. Comparative myology of the pectoral and pelvic appendages of the North American porcupine (*Erethizon dorsatum*) and the prehensile-tailed porcupine (*Coendu prehensilis*). *Bull. Am. Mus. Nat. Hist.* 173.
- Meachen-Samuels, J., Van Valkenburgh, B., 2009. Forelimb indicators of prey-size preference in the Felidae. *J. Morphol.* 270, 729-744.
- Meldrum, J.M, Dagosto, M., White, J., 1997. Hindlimb suspension and hind foot reversal in *Varecia variegata* and other arboreal mammals. *Am. J. Phys. Anthropol.* 103, 85-102.
- Mivart, S.G., 1881. *The Cat. An Introduction to the Study of Backboned Animals Especially Mammals.* John Murray, Albemarle Street, London.
- Mivart, S.G., 1882. Notes on some points in the anatomy of the *æluroides*. *Proc. Zool. Soc. Lond.* 50, 459-520.
- Morales, M., Giannini, P., 2013. Pleistocene extinctions and the perceived morphofunctional structure of the Neotropical felid ensemble. *J. Mamm. Evol.* 21, 395-405.
- Muul, I., Lim, B.L., 1970. Ecological and morphological observations of *Felis planiceps*. *J. Mammal.* 51, 806-808.

- O'Donovan, M.J., Pinter, M.J., Dum, R.P., Burke, R.E., 1982. Actions of FDL and FHL muscles in intact cats: functional dissociation between anatomical synergists. *J. Neurophysiol.* 47, 1126- 43.
- Oliveira, T.G. de, 1994. Neotropical Cats: Ecology and Conservation. EDUFMA, São Luis, Brasil.
- Oliveira, T.G. de, 1998. *Leopardus wiedii*. *Mamm. Species.* 579, 1-6.
- Pacot, A.C.M., 2009. Le guepard et le chat domestie: Elements D'osteologie et de myologie compares du member thoracique. PhD Thesis. Ecole Nationale Veterinaire de Nantes, France.
- Pereira, J.A., 2009. Efectos del manejo ganadero y disturbios asociados sobre ecología trófica y espacial y la demografía del gato montés (*Leopardus geoffroyi*) en el desierto del Monte, Argentina. Unpublished D. Biol. Sci. Thesis, Universidad de Buenos Aires.
- Pereira, J.A., Walker, R.S., Novaro, A.J., 2012. Effects of livestock on the feeding and spatial ecology of Geoffroy's cat. *J. Arid. Environ.* 76, 36-42.
- Peterka, H.E., 1936. A study of the myology and osteology of tree sciurids with regard to adaptation to arboreal, glissant and fossorial habits. *Trans. Kans. Acad. Sci.* 39, 313-332.
- Petersen, M.K., 1979. Behavior of the margay. *Carnivore* 2: 69-76.
- Poglayen-Neuwall, I., Toweill, D.E., 1988. *Bassariscus astutus*. *Mamm. Species* 327, 1-8.
- Ray, L.J., 1949. The myology of the inferior extremity of the Malay bear, *Ursus malayanus*. *J. Zool.* 119, 121-132.

- Reighard, J., Jennings H. S., 1902. Anatomy of the Cat. New York, Henry Holt and Company.
- Rocha-Mendes, F., Bianconi, G.V., 2009. Opportunistic predatory behavior of margay, *Leopardus wiedii* (Schinz, 1821), in Brazil. *Mammalia* 73, 151–152.
- Rocha-Mendes, F., Mikich, S.B., Quadros, J., Pedro, W.A., 2010. Feeding ecology of carnivores (Mammalia, Carnivora) in Atlantic Forest remnants, Southern Brazil. *Biota Neotrop.* 10, 21-30.
- Ross, F.O., 1876. Myology of the cheetah, or hunting leopard of India (*Felis jubata*). *Proc. R. Irish Acad. Sci.* 3, 23-32.
- Rudolphi, D.K.A., 1820. Beitrag zur Anatomie des Löwen. Eine in der Königlich-preussischen akademie der wissenschaften vorgelesene abhandlung. Berlin.
- Sacks, R.D., Roy, R.R., 1982. Architecture of the hind limb muscle of cats: functional significance. *J. Morphol.* 173,185-195.
- Sebastiani, A.M., Fishbeck, D.W., 2005. Mammalian Anatomy: The Cat. Morton Publishing Company, Englewood, Colorado.
- Shepherd, F.J., 1883. Short notes on the myology of the American black bear (*Ursus americanus*). *J. Anat. Physiol.* 18, 103-117.
- Smith, J.L., Edgerton, V.R., Betts, B., Collatos, T.C., 1977. EMG of slow and fast ankle extensors of cat during posture, locomotion, and jumping. *J. Neurophysiol.* 40, 503-513.
- Sousa, K.S., Bager, A., 2008. Feeding habits of Geoffroy's cat (*Leopardus geoffroyi*) in southern Brazil. *Mamm. Biol.* 73, 303-308.
- Sunquist, M.E., Sunquist, F.C., 2002. Wild Cats of the World. University of Chicago Press, Chicago.

- Sunquist, M.E., Sunquist, F.C., 2009. Family Felidae (Cats). In: Wilson, D.E., Mittermeier, R.A. (Eds.), Handbook of Mammals of the World. Vol. 1. Carnivores. Lynx ed., Barcelona, Spain.
- Szalay, F.S., 1985. Rodent and lagomorph morphotype adaptations, origins, and relationships: some postcranial attributes analyzed. In: Lockett W.P., Hartenberger J.L. (Eds) Evolutionary Relationships among Rodents. NATO Advanced Science Institutes (ASI) Series (Series A: Life Sciences), vol 92. Springer, Boston, MA.
- Taylor, M.E., 1976. The functional anatomy of the hindlimb of some African Viverridae (Carnivora). *J. Morphol.* 148, 227–254.
- Taylor, M.E., 1989. Locomotor adaptation by carnivores. In: Gittleman J.L., (Ed.), Carnivore Behavior, Ecology, and Evolution. Cornell University Press, Nueva York, pp. 383–409.
- Taylor, W.T., Weber, R.J., 1951. Functional Mammalian Anatomy (with Special Reference to the Cat). D. Van Nostrand Company, Princeton, New Jersey, New York.
- Trapp, G.R., 1972. Some anatomical and behavioral adaptations of ringtails, *Bassariscus astutus*. *J. Mammal.* 53, 549-557.
- Viranta, S., Lommi, H., Holmala, K., Laakkonen, J., 2016. Musculoskeletal anatomy of the Eurasian lynx, *Lynx lynx* (Carnivora: Felidae) forelimb: adaptations to capture large prey? *J. Morphol.* 277: 753-765.
- Waibl, H., Gasse, H., Hashimoto, Y., Burdas, K.D., Constantinescu, G.M., Saber, A.S., Simoens, P., Salazar, I., Sotonyi, P., Augsburger, H., Bragulla, H., 2005. Nomina Anatomica Veterinaria. International Committee on Veterinary Gross Anatomical Nomenclature, World Association of Veterinary Anatomists, Hannover.

- Walmsley, B., Hodgson, J.A., Burke, R.E., 1978. Forces produced by medial gastrocnemius and soleus muscles during locomotion in freely moving cats. *J. Neurophysiol.* 41, 1203-1216.
- Wang, E., 2002. Diets of ocelots (*Leopardus pardalis*), margays (*L. wiedii*), and oncillas (*L. tigrinus*) in the Atlantic Rainforest in Southeast Brazil. *Stud. Neotrop. Fauna Environ.* 37, 207-212.
- Watson, M., 1882. On the muscular anatomy of *Proteles* as compared with that of *Hyaena* and *Viverra*. *Proc. Zool. Soc. Lond.* 50, 579–586.
- Watson, M., Young, A.H., 1879. On the anatomy of *Hyaena crocuta* (*H. maculata*). *Proc. Zool. Soc. Lond.* 1879, 79–107.
- Weigel I., 1975. Small cats and clouded leopards. In Grizmek's animal life encyclopedia 12: Mammals III. Grzimek B. (Ed.), Van Nostrand Reinhold, New York, pp. 281-332.
- Williams, S.B., Wilson, A.M., Daynes, J., Peckham, K., Payne, R.C., 2008. Functional anatomy and muscle moment arms of the thoracic limb of an elite sprinting athlete: the racing greyhound (*Canis familiaris*). *J. Anat.* 23, 373-382.
- Wilson, D.E., Mittermeier, R.A., 2009. Handbook of Mammals of the World. Vol. 1. Carnivores. Lynx ed., Barcelona, Spain.
- Windle, B.C.A., Parsons F.G., 1897. On the myology of the terrestrial Carnivora. Part I: muscles of the head, neck, and fore-limb. *Proc. Zool. Soc. Lond.* 65, 370–409.
- Windle, B.C.A., Parsons, F.G., 1898. The myology of the terrestrial Carnivora. Part II. *Proc. Zool. Soc. Lond.* 66, 152–186.



Woods, A.C., 1972. Comparative miology of jaw, hyoid, and pectoral appendicular regions of New and Old World hystricomorph rodents. Bull. Am. Mus. Nat. Hist. 147, 117-198.

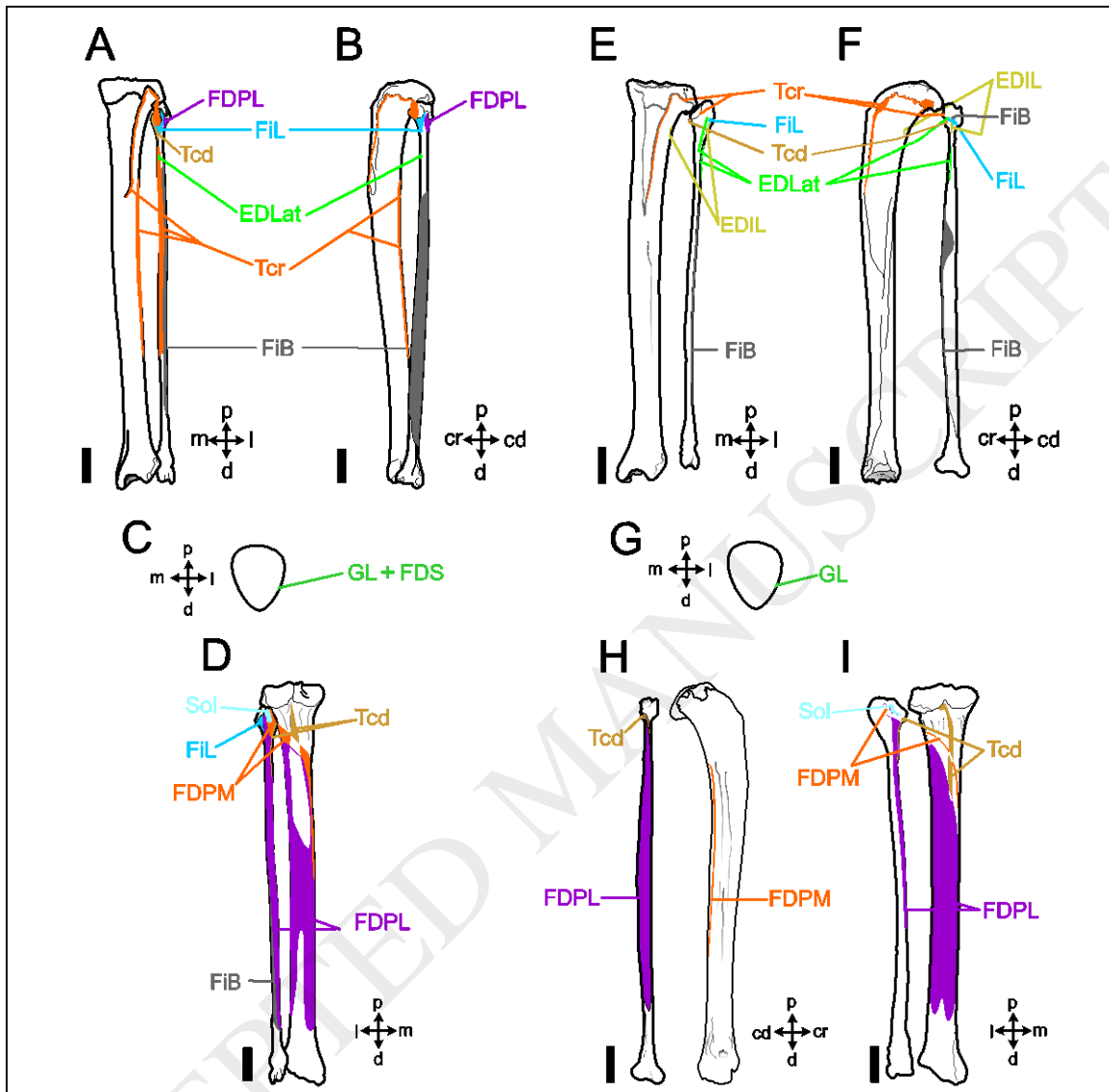
Young, A.H., Robinson, A., 1889. On the anatomy of *Hyaena striata*. Part II. J. Anat. Physiol. 23, 187–200.

Young, R.P., Scott, S.H., Loeb, G.E., 1992. An intrinsic mechanism to stabilize posture-joint-angle-dependent moment arms of the feline ankle muscles. Neurosci. Lett. 145, 137-140.

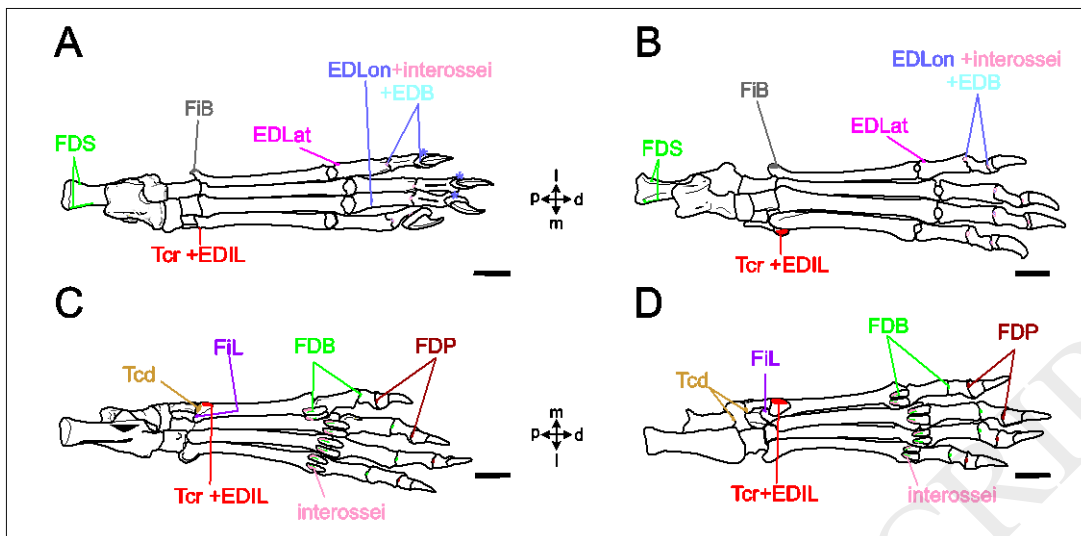
Young, R.P., Scott, S.H., Loeb, G.E., 1993. The distal hindlimb musculature of the cat: multiaxis moment arms at the ankle joint. Exp. Brain Res. 96, 141-151.

Ximénez, A., 1975. *Felis geoffroyi*. Mamm. Species 54, 1-4.

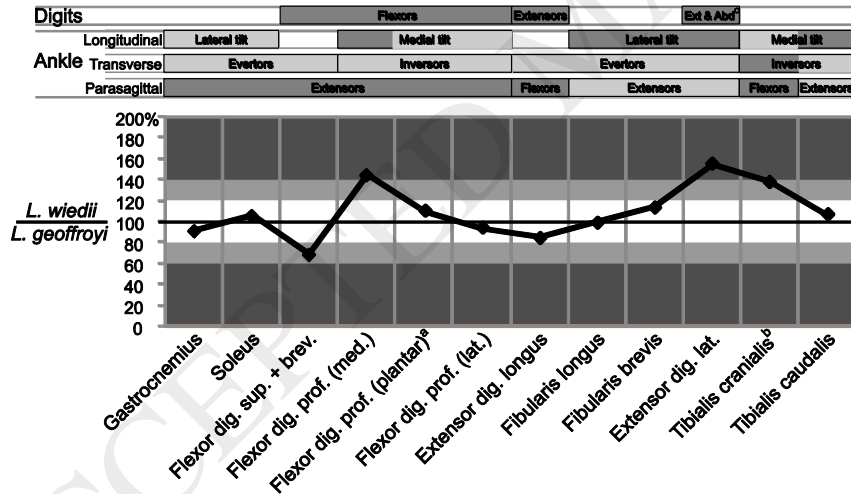
## Figure captions



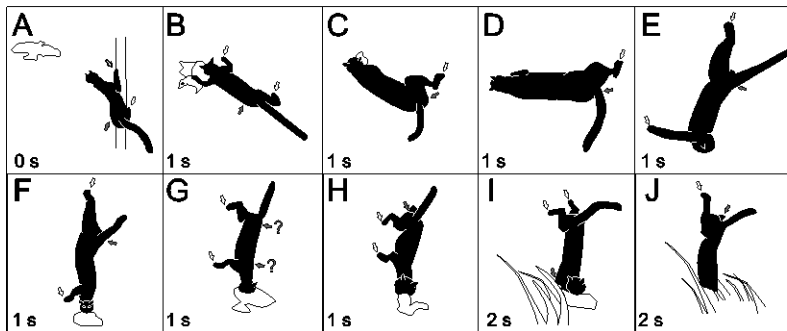
**Figure 1.** Muscle maps of *Leopardus wiedii* (A, B, C, D) and *L. geoffroyi* (E, F, G, H, I). Cranial (A, E, C, G), lateral (B, F), caudal (D, I) and medial (H) views of tibia, fibula and patella. Abbreviations: cd, caudal; cr, cranial; d, distal; EDIL, extensor digiti I longus; EDLat, extensor digitorum lateralis; FDPL, flexor digitorum profundus (lateralis); FDPM, flexor digitorum profundus (medialis); FDS, flexor digitorum superficialis; FiB, fibularis brevis; FiL, fibularis longus; GL, gastrocnemius lateralis; l, lateral; m, medial; Sol, soleus; Tcd, tibialis caudalis; Tcr, tibialis cranialis.



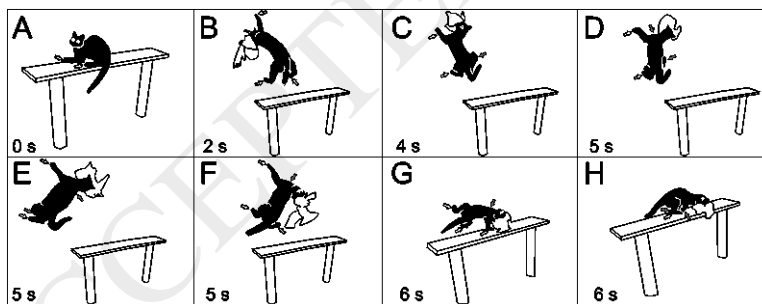
**Figure 2.** Muscular maps of *Leopardus wiedii* (A, C) and *L. geoffroyi* (B, D). Dorsal (A, B) and plantar (B, D) views of the hind limb autopod. Abbreviations: EDB, extensor digitorum brevis; EDLon, extensor digitorum longus; FDB, flexor digitorum brevis; FDP, flexor digitorum profundus. Other abbreviations as in Fig. 1.



**Figure 3.** Relative muscular weight of *Leopardus wiedii* and *L. geoffroyi*. Superscripts: <sup>a</sup> corresponds to the tendinous part of the muscle after separating mm. flexor digitorum medialis and lateralis, includes weight of mm. inteflexorii and lumbricalis. <sup>b</sup> includes weight of m. extensor hallucis longus (see text). <sup>c</sup> these functions correspond to the fifth digit.



**Figure 4.** Hunting sequence of a captive *L. wiedii*. White arrows show extremities grabbing the wire fence. Grey arrows indicate extremities that cannot be seen but that are thought to be grasping the fence. Numbers in the lower left corner indicate an approximation of elapsed time.



**Figure 5.** Hunting sequence of a captive *L. geoffroyi*. White arrows show extremities grabbing the wire fence or onto the bench. Grey arrows indicate extremities that cannot be seen but that are thought to be grasping the fence. Numbers in the lower left corner indicate an approximation of elapsed time.

**Supplemental material**

**Video S1.** *Leopardus wiedii* hunting a dove, *Columba livia* on a wire-fence in captivity at Estación de Cría Montes del Plata (Fray Bentos, Uruguay).

**Video S2.** *Leopardus geoffroyi* hunting a dove, *Columba livia* on a wire-fence in captivity at Estación de Cría Montes del Plata (Fray Bentos, Uruguay).

ACCEPTED MANUSCRIPT