



Boron Neutron Capture Therapy (BNCT) in an oral precancer model: Therapeutic benefits and potential toxicity of a *double* application of BNCT with a six-week interval

Andrea Monti Hughes^a, Emiliano C.C. Pozzi^{a,b}, Elisa M. Heber^a, Silvia Thorp^c, Marcelo Miller^c, Maria E. Itoiz^{a,d}, Romina F. Aromando^{a,d}, Ana J. Molinari^a, Marcela A. Garabalino^a, David W. Nigg^e, Verónica A. Trivillin^{a,f}, Amanda E. Schwint^{a,f,*}

^a Department of Radiobiology, National Atomic Energy Commission (CNEA), Argentina

^b Department of Research and Production Reactors, Ezeiza Atomic Center, CNEA, Argentina

^c Instrumentation and Control Dept., Ezeiza Atomic Center, CNEA, Argentina

^d Department of Oral Pathology, Faculty of Dentistry, University of Buenos Aires, Argentina

^e Idaho National Laboratory, 2525 North Fremont Street, P.O. Box 1625, Idaho Falls, ID 83415, USA

^f National Research Council (CONICET), Av. Rivadavia 1917, C1033AAJ CABA, Argentina

ARTICLE INFO

Article history:

Received 13 May 2011

Received in revised form 15 July 2011

Accepted 19 July 2011

Available online 12 August 2011

Keywords:

Boron Neutron Capture Therapy (BNCT)

Oral cancer

Hamster cheek pouch

Premalignant tissue

Second primary tumors

Mucositis

Boronophenylalanine (BPA)

GB-10

SUMMARY

Given the clinical relevance of locoregional recurrences in head and neck cancer, we developed a novel experimental model of premalignant tissue in the hamster cheek pouch for *long-term* studies and demonstrated the partial inhibitory effect of a *single* application of Boron Neutron Capture Therapy (BNCT) on tumor development from premalignant tissue. The aim of the present study was to evaluate the effect of a *double* application of BNCT with a 6 week interval in terms of inhibitory effect on tumor development, toxicity and DNA synthesis. We performed a *double* application, 6 weeks apart, of (1) BNCT mediated by boronophenylalanine (BPA-BNCT); (2) BNCT mediated by the combined application of decahydrodecaborate (GB-10) and BPA [(GB-10 + BPA)-BNCT] or (3) beam-only, at RA-3 nuclear reactor and followed the animals for 8 months. The control group was cancerized and sham-irradiated. BPA-BNCT, (GB-10 + BPA)-BNCT and beam-only induced a reduction in tumor development from premalignant tissue that persisted until 8, 3, and 2 months respectively. An early maximum inhibition of 100% was observed for all 3 protocols. No normal tissue radiotoxicity was detected. Reversible mucositis was observed in premalignant tissue, peaking at 1 week and resolving by the third week after each irradiation. Mucositis after the second application was not exacerbated by the first application. DNA synthesis was significantly reduced in premalignant tissue 8 months post-BNCT. A *double* application of BPA-BNCT and (GB-10 + BPA)-BNCT, 6 weeks apart, could be used therapeutically at no additional cost in terms of radiotoxicity in normal and dose-limiting tissues.

© 2011 Elsevier Ltd. All rights reserved.

Introduction

Boron Neutron Capture Therapy (BNCT) is a binary treatment modality that involves the selective accumulation of boron carriers in tumor followed by irradiation with a thermal or epithermal neutron beam. The high linear energy transfer α particles and recoiling ${}^7\text{Li}$ nuclei emitted during the capture of a thermal neutron by a ${}^{10}\text{B}$ nucleus have a range of approximately 5–9 μm in tissue and are known to have a high relative biological effectiveness (e.g. 1). In this

way, BNCT would conceivably target tumor tissue selectively and effectively, largely sparing normal tissue. Clinical trials of BNCT for the treatment of glioblastoma multiforme and/or melanoma and more recently, head and neck tumors and liver metastases, using boronophenylalanine (BPA) or sodium mercaptoundecahydrodecaborane (BSH) as the boron carriers, have been performed or are underway in Japan, the US, Argentina and Europe (see Refs. 2–7). Contributory translational studies have been carried out employing a variety of experimental models (e.g. 4).

We previously evidenced the therapeutic efficacy of BNCT mediated by BPA and/or decahydrodecaborate (GB-10) to treat oral cancer in an experimental model in the hamster cheek pouch with no normal tissue radiotoxicity, and without exceeding the radiotolerance of dose-limiting premalignant tissue surrounding

* Corresponding author. Address: Department of Radiobiology, National Atomic Energy Commission, Avenida General Paz 1499, B1650KNA San Martin, Prov. Buenos Aires, Argentina. Tel.: +54 11 6772 7149; fax: +54 11 6772 7188.

E-mail address: schwint@cnea.gov.ar (A.E. Schwint).

tumors.^{8–18} We also demonstrated the feasibility of treating spontaneous squamous cell carcinomas in felines with BNCT.^{19,20} Despite the success of the BNCT protocols employed in these studies to treat tumors, the inhibition of tumor development from premalignant tissue is an unresolved challenge. Second primary tumor locoregional recurrences that arise in field-cancerized tissue are a frequent cause of therapeutic failure.²¹ In head and neck cancer there is a risk of approximately 20% for second primary tumors.²² In addition, the constraints imposed on therapeutic protocols by the dose-limiting nature of premalignant tissue must be assessed. Within this context, the hamster cheek pouch oral cancer model poses a unique advantage in that the carcinogenesis protocol mimics the spontaneous process of malignant transformation, leading to the development of premalignant tissue from which tumors arise.¹² Thus, the model allows for the study of both tumors and field-cancerized tissue²³, unlike tumor models based on the growth of implanted tumor cells. However, the aggressiveness of the model as employed in tumor control studies (e.g. 9, 14–16, 18) precludes *long-term* follow-up. Given the need for *long-term* follow-up to better evaluate the effect of BNCT on premalignant tissue, we developed a novel model of premalignant tissue in the hamster cheek pouch that allows for *long-term* studies, i.e. is amenable to *long-term* follow-up but guarantees tumor development in $\geq 90\%$ of the animals.¹³ Employing this model, we demonstrated the *long-term* partial inhibitory effect of a *single* application of BNCT mediated by BPA, GB-10 or (GB-10 + BPA) on the development of tumors from hamster cheek pouch premalignant tissue, with no normal tissue radiotoxicity and without exceeding the tolerance of dose-limiting premalignant tissue.²⁴ Tumor development from premalignant tissue post-BNCT would model the development of the clinically relevant second primary tumors.

The aim of the present study was to evaluate the *long-term* effect of a *double* application of BNCT (full dose re-irradiation) mediated by BPA or (GB-10 + BPA) with a six-week interval in the model of oral premalignant tissue for *long-term* follow-up in terms of inhibition of tumor development, toxicity in normal tissue and in dose-limiting premalignant tissue and DNA synthesis in premalignant tissue. The potential benefits of a *double* application of BNCT for the treatment of tumors, in particular large tumors, and for the inhibition of the development of recurrent and/or second primary tumors, might be limited by premalignant tissue toxicity. Thus, the possibility of studying potential toxicity in premalignant tissue within the context of a *double* application of BNCT is particularly contributory. In a clinical scenario confluent oral mucositis is a frequent, dose-limiting side effect during conventional radiotherapy for advanced head and neck tumors^{25,26}, affecting approximately 80% of patients.²⁶ Despite its frequency and clinical relevance, no effective way to prevent or treat mucositis is currently available.^{25,26} Oral mucositis is a dose-limiting consideration in BNCT of brain tumors²⁷ and head and neck tumors (e.g. 8). In particular, oral mucositis has been posed as a concern following a *double* application of BNCT with a 3–5 week interval.⁷ Hence, the importance of evaluating the therapeutic efficacy and the cost of a *double* application of BNCT in terms of premalignant tissue mucositis.

Materials and methods

Model of oral precancer

We treated 100 animals with the carcinogenesis protocol for induction of premalignant tissue amenable to *long-term* follow-up, i.e. topical application of 0.5% DMBA in mineral oil in the right cheek pouch, twice a week for 6 weeks¹³, and then assigned them to the control group (cancerized, sham-irradiated) and different

groups for *in vivo* BNCT studies. Studies were initiated 1 week after completion of the carcinogenesis protocol (T0). Institutional guidelines for the care and use of laboratory animals were followed throughout.

In vivo BNCT studies

The cancerized hamsters were exposed to a *double* application of the following protocols, with a 6-week interval between applications: BPA-BNCT ($n = 10$), (GB-10 + BPA)-BNCT ($n = 13$) and beam-only ($n = 10$). Beam only irradiations were performed to assess the effect of background dose from the neutron source. Beam only irradiations were performed at the highest thermal neutron fluence (or the longest exposure time) used for BNCT irradiations. The interval between applications was chosen based on tissue response in previous studies performed with a *single* application of BNCT.²⁴ The remaining 77 cancerized hamsters were sham-irradiated and served as controls. An additional group of normal (non-cancerized) hamsters were exposed to a *double* application of the same protocols, i.e. BPA-BNCT ($n = 3$), (GB-10 + BPA)-BNCT ($n = 4$) and beam-only ($n = 3$) to evaluate potential normal pouch tissue toxicity. The animals were irradiated at the RA-3 thermal facility employing a lithium-6 carbonate shielding to protect the body of the animal while the cheek pouch is everted out of the enclosure onto a protruding shelf for exposure as previously described.¹⁶ The thermal neutron flux at the irradiation position was $6.5 \times 10^9 \text{ n cm}^{-2} \text{ s}^{-1}$ and the gamma dose rate in air was $4.8 \pm 0.5 \text{ Gy h}^{-1}$. Table 1 shows the prescribed total physical dose, the radiation components and irradiation times for each of the protocols. For the BPA-BNCT protocol, BPA was administered in bolus ip at a dose of $15.5 \text{ mg }^{10}\text{B/kg bw}$ 3 h before irradiation. For the (GB-10 + BPA)-BNCT protocol GB-10 and BPA were administered jointly. GB-10 was administered as an iv bolus injection at a dose of $34.5 \text{ mg }^{10}\text{B/kg bw}$ and BPA was administered as fractionated ip injections at a total dose of $31 \text{ mg }^{10}\text{B/kg bw}$ over 3 h. Irradiation was performed 3 h post-administration of GB-10 and 1.5 h after the last injection of BPA. The boron content values employed for dose calculations were previously obtained by Inductively Coupled Plasma Atomic Emission Spectroscopy (ICP-OES)²⁴ and are included in Table 1 as a reference.

Follow-up

The clinical signs and body weight of the animals were monitored regularly. Potential development of second primary tumors (defined as tumors that were not present at the time of the first irradiation) from premalignant tissue was assessed weekly by visual inspection and tumor volume assay (when pertinent) for 8 months after the first irradiation (T0). At the same time-points, potential radiotoxicity in terms of mucositis was monitored in premalignant and normal pouch tissue. The severity of mucositis was evaluated semi-quantitatively according to an oral mucositis scale based on macroscopic features, adapted from López Castaño et al.²⁸ and Sonis et al.²⁹, i.e. Grade 0: healthy appearance, no erosion or vasodilation; Grade 1: erythema and/or edema and/or vasodilation, no evidence of mucosal erosion; Grade 2: severe erythema and/or edema, vasodilation and/or superficial erosion; Grade 3: severe erythema and/or edema, vasodilation and formation of ulcers <2 mm in diameter; Grade 4: severe erythema and/or edema, vasodilation and formation of ulcers >2 mm in diameter; Grade 5: virtually complete ulceration of the pouch mucosa. Microscopic evaluation of mucositis was performed in additional sets of animals, treated in the same way with each of the BNCT protocols and killed humanely at different time-points selected for their clinical relevance on the basis of macroscopic appearance.

Table 1
Physical absorbed doses for the different experimental protocols.

	Boron concentration (ppm) ^a	Total Physical Absorbed Doses (Gy)	Physical Absorbed Doses (Gy) from the different radiation components			
			Fast Neutrons	Gamma-ray photons	Boron (quoted per part per million boron)	Induced protons
<i>(GB-10 + BPA)-BNCT: GB-10 (34.5 mg boron/kg body weight) + BPA (31 mg boron/kg body weight) (Effective irradiation time: 2.73 min)</i>						
Premalignant pouch tissue	45 ± 15	4 ± 1	–	0.30 ± 0.04	0.079 ± 0.007	0.22 ± 0.02
Normal pouch tissue	50 ± 20	4 ± 2				
<i>BPA-BNCT: (15.5 mg boron/kg body weight) (Effective irradiation time: 5.21 min)</i>						
Premalignant pouch tissue	19 ± 9	4 ± 1	–	0.58 ± 0.07	0.15 ± 0.01	0.43 ± 0.04
Normal pouch tissue	22 ± 11	4 ± 2				
<i>BEAM ONLY (Effective irradiation time: 5.19 min)</i>						
Premalignant pouch tissue	–	1.01 ± 0.08	–	0.58 ± 0.07	–	0.43 ± 0.04
Normal pouch tissue	–	1.01 ± 0.08				

All data are quoted for each irradiation.

^a Taken from Monti Hughes et al. (2009) (Ref. 24).

DNA synthesis

Thirty minutes prior to sacrifice at 8 months post-T0 we administered 2 ml of a 1% solution of 5-bromo-2'-deoxyuridine (BrdU) in distilled water (approximately 0.2 g BrdU/kg b.w.) i.p. to each hamster. Samples of premalignant pouch tissue of representative BNCT-treated and control cases were processed for immunohistochemical demonstration of BrdU employing the peroxidase-anti-peroxidase technique.³⁰ Adjacent, hematoxylin-eosin stained sections were employed for complementary histological analysis. Nuclei with positive staining exhibited brown diaminobenzidine deposits that contrasted against unlabeled nuclei counterstained with hematoxylin. BrdU-labeled cells were counted by light microscopy at a 400× magnification as the brown nuclei in all the epithelial strata above a fixed length (300 μm) of basal layer employing a grid fitted into the eyepiece, spanning the full length of the basal layer available for each pouch section. The mean nuclear area and mean number of nuclei/unit area were unchanged after BNCT¹², thus allowing us to perform a direct comparison of BrdU-positive nuclei counts between control and BNCT-treated samples. The following histological categories were evaluated individually within the premalignant tissue corresponding to DMBA-treated animals: No unusual microscopic features (NUMF), hyperplasia and dysplasia. Four animals were evaluated for each of the BNCT protocols and nine animals were evaluated for the control group. One pouch section was measured for each hamster. All the areas corresponding to each of the histological categories present in each pouch in the case of cancerized tissue were counted for each hamster. The total number of fields evaluated per protocol for each histological category is indicated in the Results section. Not all pouches exhibited areas corresponding to all the histological categories.

Statistical analysis

Statistical analysis of the data was performed by ANOVA and the test of differences between proportions as appropriate. Statistical significance was set at $p = 0.05$.

Results

The *double* application of BPA-BNCT, (GB-10 + BPA)-BNCT and beam only induced an inhibition in tumor development from premalignant tissue compared to the control group (cancerized, sham-irradiated) that persisted until 8, 3, and 2 months post-T0 respectively (Fig. 1). The inhibitory effect reached statistical significance

for the (GB-10 + BPA)-BNCT and beam only groups. Early 100% inhibition was observed for all 3 protocols 2 weeks post-T0. Values of T50 and T80 (time at which 50% and 80% of the animals respectively exhibited tumor development from premalignant tissue) provided additional evidence of the inhibitory effect of treatment on tumor development. T50 was 1 month for the control group but was 2, 4, and 2 months for the beam only, (GB-10 + BPA)-BNCT and BPA-BNCT groups respectively. T80 was 4–5 months for the control, beam only and (GB-10 + BPA)-BNCT groups but was not reached within the follow-up period in the case of the BPA-BNCT group. The cancerized pouches of the animals in the (GB-10 + BPA)-BNCT and BPA-BNCT groups that had not developed tumors at 8 months were macroscopically and histologically similar to the pouches that had never been cancerized and differed from the cancerized pouches 8 months post sham-irradiation (Fig. 2). These findings showed that BNCT was capable of reverting the macroscopic and histological hallmarks of precancer.

The animals did not exhibit any clinical signs of radiotoxicity throughout the follow-up period. No radiotoxicity was observed in normal tissues at any time point for any of the protocols. The premalignant tissue treated with a *double* application of (GB-10 + BPA)-BNCT, BPA-BNCT or beam only exhibited reversible mucositis that peaked 1 week after the first and second applications (Table 2) and had resolved by 3 weeks after each of the applications. None of the animals in the (GB-10 + BPA)-BNCT group reached Grade 2 mucositis whereas 33% and 25% of the animals in the BPA-BNCT group reached Grade 2 mucositis 1 week after the first and second applications, respectively. The finding that 14% of the cancerized, sham-irradiated (control) animals exhibited Grade 1 mucositis 6 weeks after the first irradiation of the treated animals, could be considered counter-intuitive. However, Grade 1 mucositis was assigned even in the case of slight erythema and has been previously observed associated to DMBA-induced carcinogenesis in the hamster cheek pouch³¹ and to occasional minor trauma caused by food pellets. The severity of mucositis after the second irradiation was not enhanced by the first irradiation (Table 2). Histological findings confirmed the macroscopic observations.

Table 3 shows DNA synthesis values expressed in terms of BrdU-labeled nuclei/field. A highly statistically significant reduction in DNA synthesis values was observed for BNCT-treated groups versus control in all cases. Dysplastic areas were virtually absent in BNCT-treated groups. The pooled values (with no distinction of histological categories) of 0.57 ± 1.13 for BPA-BNCT and 1.01 ± 1.56 for (GB-10 + BPA)-BNCT are closer to the previously reported¹² value of 0.81 ± 1.22 corresponding to normal (non-cancerized) tissue than to the value of 2.72 ± 2.91 corresponding to cancerized tissue.

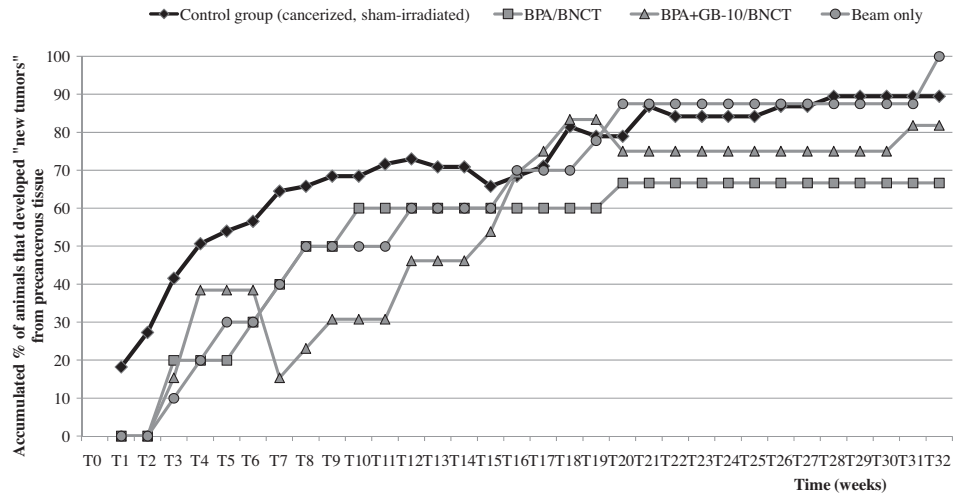


Figure 1 Accumulated percentage of animals (%) that exhibited tumor development from premalignant tissue for each of the treatment and control groups.

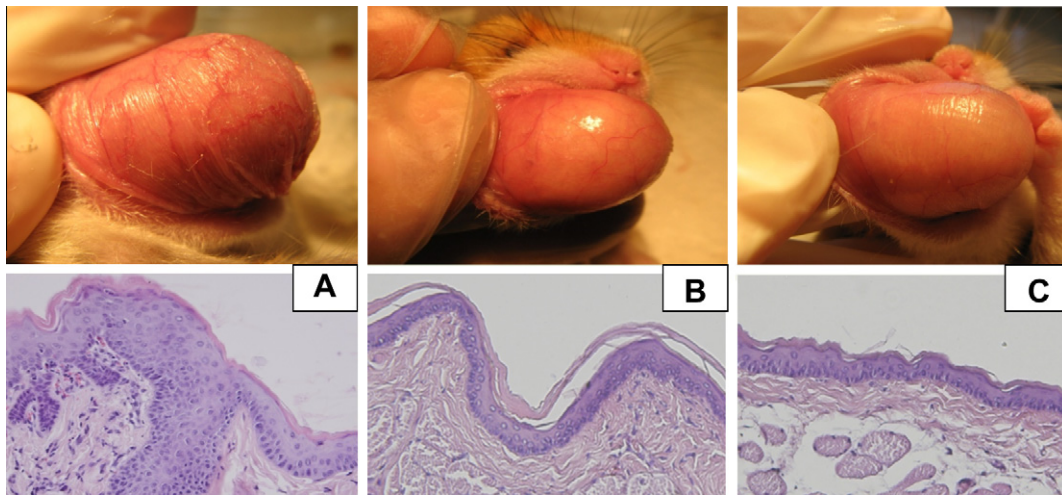


Figure 2 (A) Cancerized pouch, 8 months post sham-irradiation; (B) cancerized pouch 8 months post-BPA-BNCT; (C) normal pouch (non cancerized, not irradiated). Below, in each case, the corresponding characteristic light microscopy images (original magnification 40x, H&E).

Table 2 Severity of mucositis: percentage of animals affected by each grade of mucositis 1 week after the first irradiation, 6 weeks after the first irradiation (time at which second irradiation was performed) and 1 week after second irradiation. Control animals were sham-irradiated and time-matched for follow-up.

	BNCT protocol/severity of mucositis	Grade 0 (%)	Grade 1 (%)	Grade 2 (%)	Grade 3 (%)	Grade 4 (%)	Grade 5 (%)
1 week after 1st irradiation	BPA-BNCT	27	40	33	0	0	0
	(GB-10 + BPA)-BNCT	33	67	0	0	0	0
	Beam only	93	7	0	0	0	0
6 weeks after 1st irradiation	Control group	100	0	0	0	0	0
	BPA-BNCT	100	0	0	0	0	0
	(GB-10 + BPA)-BNCT	100	0	0	0	0	0
	Beam only	100	0	0	0	0	0
1 week after 2nd irradiation	Control group	86	14	0	0	0	0
	BPA-BNCT	25	50	25	0	0	0
	(GB-10 + BPA)-BNCT	73	27	0	0	0	0
	Beam only	92	8	0	0	0	0
	Control group	100	0	0	0	0	0

Discussion

The double application of the BNCT protocols that proved therapeutically useful as a single application, did not exceed the tolerance of premalignant tissue (dose-limiting tissue) or surrounding normal tissues, did not enhance mucositis in premalignant tissue,

reduced DNA synthesis in premalignant tissue 8 months post-treatment, and partially inhibited the development of tumors in field-cancerized tissue (pre-malignant tissue). As previously discussed in Monti Hughes et al.²⁴, the differential effect of BNCT on premalignant tissue vs normal tissue cannot be attributed to the preferential accumulation of boron in premalignant tissue vs

Table 3
Number of BrdU-labeled nuclei / field for each of the groups at 8 months-follow up.

	BrdU-labeled nuclei/field for each histological category			BrdU-labeled nuclei/field (with no distinction of histological categories)
	Dysplasia	Hyperplasia	NUMF	
CONTROL GROUP (Cancerized, sham-irradiated)	10.63 ± 4.63 (n = 8)	3.67 ± 3.21 (n = 204)	1.68 ± 1.65 (n = 247)	2.72 ± 2.91 (n = 459)
BPA-BNCT	^a -(n = 0)	1.68 ± 1.89 (n = 19)	0.46 ± 0.95 (n = 180)	0.57 ± 1.13 (n = 119)
(GB-10 + BPA)-BNCT	0 (n = 1)	2.14 ± 2.47 (n = 66)	0.67 ± 0.91 (n = 212)	1.01 ± 1.56 (n = 279)

Values are expressed as mean ± SD. n indicates the total number of fields measured per protocol.

^a Not all pouches exhibited areas corresponding to all histological categories.

normal tissue. As seen in Table 1, boron content in premalignant tissue and normal pouch tissue did not differ significantly. Although BNCT selective tumor damage is classically attributed to the differential accumulation of boron in tumor versus healthy tissues¹, other mechanisms of selective action have been described. In the case of BNCT mediated by the chemically non-selective boron compound GB-10³², selective tumor lethality would result from selective damage to aberrant tumor blood vessels rather than from selective uptake of the boron compound. Furthermore, potential differences in the microdistribution of equal boron concentration values (gross boron content as determined by ICP-OES), will condition therapeutic effect.¹⁵ In addition, differences in radiosensitivity between tissues and tissue areas would explain differences in therapeutic effect that cannot be attributed to differences in boron uptake.¹⁸ Based on these notions, the selective effect of BNCT on areas of premalignant tissue could be due to potential differences in the Compound Biological Efficacy (CBE) factor between premalignant and normal tissue, preferential microlocalization (undetectable by ICP-OES measurements) of boron in premalignant foci at a higher risk of malignant transformation, and vascular targeting by GB-10-BNCT in the (GB-10 + BPA)-BNCT protocol that might affect the process of angiogenesis, pivotal to malignant transformation. The inhibitory effect on premalignant tissue would be due to cellular and/or vascular targeting of foci at a high risk of malignant transformation¹², the effect on the microenvironment of these foci³³ or both.

The differences in response elicited by BPA-BNCT and (GB-10 + BPA)-BNCT could be ascribed to differences in the uptake, distribution and mechanism of action of the boron carriers involved. BPA is transported actively across the cell membrane by the L-amino-acid transport system.³⁴ Thus, uptake will depend on metabolic status and viability, resulting in selective but heterogeneous tumor boron targeting. Conversely, GB-10 has been described as a largely diffusive agent, leading to non-selective but homogeneous tumor boron targeting. In terms of mechanism of action, GB-10 would be a vascular targeting compound whereas BPA is a cellular targeting compound. GB-10 and BPA would combine vascular and cellular targeting respectively.^{11,15} Although the present study was not designed to elucidate the mechanisms underlying tissue response, boron carriers with different properties and complementary uptake mechanisms employed as stand-alone (BPA) or combined (GB-10 + BPA) drugs in the different protocols would be partially responsible for differences in tissue response to the different BNCT protocols. Within this context, a slight therapeutic advantage was noted for BPA-BNCT over (GB-10 + BPA)-BNCT. This advantage was associated to enhanced mucositis in premalignant tissue. However, mucositis did not exceed Grade 2 in any of the cases. Grade 3 mucositis is considered an acceptable level of toxicity in clinical trials.⁷ Given that BPA-BNCT did not induce mucositis exceeding Grade 2 in premalignant tissue, BPA-BNCT would be the recommended BNCT protocol to treat premalignant tissue, profiting from a slight therapeutic advantage without exceeding acceptable levels of mucositis.

The fact that the first irradiation did not enhance mucositis in premalignant tissue after the second irradiation might be partially

due to a small degree of repair of the sublethal damage mostly induced by the low Linear Energy Transfer (LET) dose component of BNCT.³⁵ In addition, and based on the known fact that mucositis is a multi-stage process initiated by mucosal injury and associated to an increased production of inflammatory cytokines which cause direct mucosal damage and initiate positive feedback loops³⁶, the interval between BNCT applications might conceivably allow the inflammatory process to partially subside before the second dose is delivered, precluding the exacerbation of mucositis.

Having demonstrated that in the conditions of this study a double application of BNCT with a 6 week interval between applications is therapeutically useful but does not enhance toxicity in premalignant tissue, its use in the treatment of head and neck tumors and the surrounding premalignant tissue would warrant assessment in a clinical scenario.

Conflict of interest statement

None declared.

Acknowledgments

Partially funded by Grant of Agencia Nacional de Promoción Científica y Tecnológica, Argentina (Principal Investigator A.E. Schwint, PICT2006-00700). Partially supported by the Department of Energy through Idaho National Laboratory (US).

References

- Coderre JA, Morris GM. The radiation biology of boron neutron capture therapy. *Radiat Res* 1999;**151**:1–18.
- González SJ, Bonomi MR, Santa Cruz GA, Blaumann HR, Calzetta Larriue OA, Menéndez P, et al. First BNCT treatment of a skin melanoma in Argentina: dosimetric analysis and clinical outcome. *Appl Radiat Isot* 2004;**61**:1101–5.
- Kato I, Ono K, Sakurai Y, Ohmae M, Maruhashi A, Imahori Y, et al. Effectiveness of BNCT for recurrent head and neck malignancies. *Appl Radiat Isot* 2004;**61**:1069–73.
- Barth RF, Coderre JA, Vicente MGH, Blue TE. Boron neutron capture therapy of cancer: current status and future prospects. *Clin Cancer Res* 2005;**11**:3987–4002.
- Zonta A, Prati U, Roveda L, Ferrari C, Zonta S, Clerici AM, et al. Clinical lessons from the first applications of BNCT on unresectable liver metastases. *J Phys Conf Ser* 2006;**41**:484–95.
- Kankaanranta L, Seppälä T, Koivunoro H, Välimäki P, Beule A, Collan J, et al. L-Boronophenylalanine-mediated boron neutron capture therapy for malignant glioma progressing after external beam radiation therapy: a phase I study. *Int J Radiat Oncol Biol Phys* 2011;**80**(2):369–76.
- Kankaanranta L, Seppälä T, Koivunoro H, Saarialhti K, Atula T, Collan J, et al. Boron neutron capture therapy in the treatment of locally recurrent head-and-neck cancer: final analysis of a phase I/II trial. *Int J Radiat Oncol Biol Phys* 2011; doi:10.1016/j.ijrobp.2010.09.057.
- Kreimann EL, Itoiz ME, Dagrosa A, Garavaglia R, Fariás S, Batistoni D, et al. The hamster cheek pouch as a model of oral cancer for boron neutron capture therapy studies: selective delivery of boron by boronophenylalanine. *Cancer Res* 2001;**61**:8775–81.
- Kreimann EL, Itoiz ME, Longhino J, Blaumann H, Calzetta O, Schwint AE. Boron Neutron Capture Therapy for the treatment of oral cancer in the hamster cheek pouch model. *Cancer Res (Advances in Brief)* 2001;**61**:8638–42.
- Heber E, Trivillin V, Nigg D, Kreimann EL, Itoiz ME, Rebagliati RJ, et al. Biodistribution of GB-10 (Na(2)(10)B10H10) in an experimental model of oral cancer in the hamster cheek pouch. *Arch Oral Biol* 2004;**49**:313–24.

11. Heber EM, Trivillin VA, Nigg DW, Itoiz ME, González BN, Rebagliati RJ, et al. Homogeneous boron targeting of heterogeneous tumors for boron neutron capture therapy (BNCT): chemical analyses in the hamster cheek pouch oral cancer model. *Arch Oral Biol* 2006;**51**:922–9.
12. Heber EM, Aromando RF, Trivillin VA, Itoiz ME, Nigg DW, Kreimann EL, et al. Therapeutic effect of boron neutron capture therapy (BNCT) on field cancerized tissue: inhibition of DNA synthesis and lag in the development of second primary tumors in precancerous tissue around treated tumors in DMBA-induced carcinogenesis in the hamster cheek pouch oral cancer model. *Arch Oral Biol* 2007;**52**:273–9.
13. Heber EM, Monti Hughes A, Pozzi EC, Itoiz ME, Aromando RF, Molinari AJ, et al. Development of a model of tissue with potentially malignant disorders (PMD) in the hamster cheek pouch to explore the long-term potential therapeutic and/or toxic effects of different therapeutic modalities. *Arch Oral Biol* 2010;**55**:46–51.
14. Trivillin VA, Heber EM, Itoiz ME, Nigg D, Calzetta O, Blaumann H, et al. Radiobiology of BNCT mediated by GB-10 and GB-10+BPA in experimental oral cancer. *Appl Radiat Isot* 2004;**61**:939–45.
15. Trivillin VA, Heber EM, Nigg DW, Itoiz ME, Calzetta O, Blaumann H, et al. Therapeutic success of Boron Neutron Capture Therapy (BNCT) mediated by a chemically non-selective boron agent in an experimental model of oral cancer: a new paradigm in BNCT radiobiology. *Radiat Res* 2006;**166**:387–96.
16. Pozzi E, Nigg DW, Miller M, Thorp SI, Heber EM, Zarza L, et al. Dosimetry and radiobiology at the new RA-3 Reactor Boron Neutron Capture Therapy (BNCT) facility: Application to the treatment of experimental oral cancer. *Appl Radiat Isot* 2009;**67**(7–8 Suppl):S309–312.
17. Aromando RF, Trivillin VA, Heber EM, Pozzi E, Schwint AE, Itoiz ME. Early effect of boron neutron capture therapy mediated by boronophenylalanine (BPA-BNCT) on mast cells in premalignant tissue and tumors of the hamster cheek pouch. *Oral Oncol* 2010;**46**:355–9.
18. Molinari AJ, Pozzi ECC, Monti Hughes A, Heber EM, Garabalino MA, Thorp SI, et al. “Sequential” Boron Neutron Capture Therapy (BNCT): a novel approach to BNCT for the treatment of oral cancer in the hamster cheek pouch model. *Radiat Res* 2011;**175**:463–72.
19. Rao M, Trivillin VA, Heber EM, Cantarelli MA, Itoiz ME, Nigg DW, et al. BNCT of 3 cases of spontaneous head and neck cancer in feline patients. *Appl Radiat Isot* 2004;**61**:947–52.
20. Trivillin VA, Heber EM, Rao M, Cantarelli MA, Itoiz ME, Nigg DW, et al. Boron neutron capture therapy (BNCT) for the treatment of spontaneous nasal planum squamous cell carcinoma in felines. *Radiat Environ Biophys* 2008;**47**:147–55.
21. Smith BD, Haffty BG. Molecular markers as prognostic factors for local recurrence and radioresistance in head and neck squamous cell carcinoma. *Radiat Oncol Investig* 1999;**7**(3):125–44.
22. Hoebers F, Heemsbergen W, Moor S, Lopez M, Klop M, Tesselaar M, et al. Reirradiation for head-and-neck cancer: delicate balance between effectiveness and toxicity. *Int J Radiat Oncol Biol Phys* 2011; doi:10.1016/j.ijrobp.2011.01.004.
23. Braakhuis BJM, Tabor MP, Kummer JA, Leemans CR, Brakenhoff RH. A genetic explanation of Slaughter’s concept of field cancerization. *Cancer Res* 2003;**63**:1727–30.
24. Monti Hughes A, Heber EM, Pozzi E, Nigg DW, Calzetta O, Blaumann H, et al. Boron Neutron Capture Therapy (BNCT) inhibits tumor development from field-cancerized tissue: an experimental study that supports a new application of BNCT. *Appl Radiat Isot* 2009;**67**(7–8 Suppl):S313–7.
25. Sonis ST. A biological approach to mucositis. *J Support Oncol* 2004;**2**:21–32. discussion 35–36.
26. Sonis ST. Mucositis: the impact, biology and therapeutic opportunities of oral mucositis. *Oral Oncol* 2009;**45**:1015–20.
27. Coderre JA, Morris GM, Kalef-Ezra J, Micca PL, Ma R, Youngs K, et al. The effects of boron neutron capture irradiation on oral mucosa: evaluation using a rat tongue model. *Radiat Res* 1999;**152**(2):113–8.
28. López Castaño F, Oñate-Sánchez RE, Roldán-Chicano R, Cabrerizo-Merino MC. Measurement of secondary mucositis on oncohematologic treatment by means of different scale. *Med Oral Patol Oral Cir Bucal* 2005;**10**(5):412–21.
29. Sonis ST, Peterson RL, Edwards LJ, Lucey CA, Wang L, Mason L, et al. Defining mechanisms of action of interleukin-11 on the progression of radiation-induced oral mucositis in hamsters. *Oral Oncol* 2000;**36**(4):373–81.
30. Sternberg LA, Hardy PH, Cuculis JJ, Meyer HG. The unlabeled antibody enzyme method of immunohistochemistry. Preparation and properties of soluble antigen-antibody complex (horseradish peroxidase) and its use in identification of spirochetes. *J Histochem Cytochem* 1970;**18**:315–30.
31. Yang Y, Ge J-P, Zhou Z-T. Effects of thalidomide on DMBA-induced oral carcinogenesis in hamster with respect to angiogenesis. *J Oral Pathol Med* 2009;**38**:455–62.
32. Garabalino MA, Monti Hughes A, Molinari AJ, Heber EM, Pozzi ECC, Cardoso JE, et al. Boron neutron capture therapy (BNCT) for the treatment of liver metastases: biodistribution studies of boron compounds in an experimental model. *Radiat Environ Biophys* 2011;**50**:199–207.
33. Laconi E, Doratiotto S, Vineis P. The microenvironments of multistage carcinogenesis. *Semin Cancer Biol* 2008;**18**(5):322–9.
34. Wittig A, Sauerwein WA, Coderre JA. Mechanisms of transport of p-boronophenylalanine through the cell membrane in vitro. *Rad Res* 2000;**153**:173–80.
35. Hopewell JW, Morris GM, Schwint A, Coderre JA. The radiobiological principles of boron neutron capture therapy: a critical review. *Appl Radiat Isot* 2011; doi:10.1016/j.apradiso.2011.04.019.
36. Mais K. Mucositis from radiotherapy to the head and neck: an overview. *Nursing* 2006;**1**:18–20.