

9. Lewis EJ, Hunsicker LG, Bain RP, et al. The effect of angiotensin-converting-enzyme inhibition on diabetic nephropathy. The Collaborative Study Group. *N Engl J Med.* 1993;329:1456.
10. Lewis EJ, Hunsicker LG, Clarke WR, et al. Renoprotective effect of the angiotensin-receptor antagonist irbesartan in patients with nephropathy due to type 2 diabetes. *N Engl J Med.* 2001;345:851.

## Intensive Treatment With Ivermectin and Iota-Carrageenan as Pre-exposure Prophylaxis for COVID-19 in Health Care Workers From Tucuman, Argentina

### *To the Editor:*

After COVID-19 emerged, a multitude of both novel and repurposed therapeutic agents were used empirically and studied in controlled clinical trials.<sup>1-3</sup> Ivermectin is a broad spectrum antiparasitic agent that has shown to have antiviral activity against a wide range of viruses.<sup>4,5</sup> On March 31, the World Health Organization (WHO) stated that evidence about ivermectin use for COVID-19 treatment is not conclusive. However, it encouraged its utilization in controlled clinical trials. At June 2021, there were 65 studies registered at <https://www.ClinicalTrials.gov> and 45 studies listed at [https://ClinicalTrials.gov/ct2/who\\_table](https://ClinicalTrials.gov/ct2/who_table) about the safety and effectiveness of ivermectin in subjects with COVID-19, of which 16 studies have been completed (for COVID-19 treatment). Most of these studies on ivermectin repositioning came from developing countries like ours, Argentina, with limited access to vaccines. These emergent economies have the need to find supportive therapies that are synergistic or alternatives to contain the spread of the disease and deter the health systems' collapse.

Kory's meta-analysis (2021) reported that ivermectin has antiviral and anti-inflammatory mechanisms with statistically significant positive outcome.<sup>6</sup> However, most of these studies were not published in peer-reviewed journals; nevertheless, several expert groups including the WHO have undertaken a global effort to contact all active clinical trials to rapidly gather the data needed to perform a systematic review and meta-analyses. In Kory's publication,<sup>6</sup> ivermectin showed ability to prevent transmission and improvement in the treatment in both observational<sup>9,10</sup> and randomized trials.<sup>7,8,11,12,13</sup> Our work was included in this systematic review. This letter to the editor aims to provide more details of our findings, presenting experimental evidence for the prophylactic use of

ivermectin associated with iota-carrageenan in health workers.<sup>12</sup>

We conducted a randomized controlled 1-1 clinical trial (registry number NCT04701710 [www.ClinicalTrials.gov](http://www.ClinicalTrials.gov)) in 234 adults. The subjects were divided into the experimental group (EG),  $n = 117$ , median age = 40 years [interquartile range (IQR), 32-46], and 65 F (55.56%) and the control group (CG)  $n = 117$ , 37 years (IQR, 33-44), and 69 F (58.97%). All subjects completed the study; 134 were female (57.3%) and 100 were men (42.7%), and 77.4% were health care workers (Table 1). The experimental group received ivermectin orally 2 tablets of 6 mg every 7 days and iota-carrageenan 6 sprays per day for 4 weeks. All participants were evaluated by physical examination and COVID-19 diagnosed with negative reverse transcription polymerase chain reaction at the protocol baseline. We calculated odds ratio (OR) and created a logistic regression using comorbidity, sex, age, and job designation as covariables. A  $P$  value  $< 0.05$  was considered significant.

The number of subjects who were diagnosed with COVID-19 in the EG was lower than subjects in the CG ( $P$  value = 0.0001), Figure 1A. Overall, 19 patients had mild symptoms, 4 were in the EG whereas 15 were in the CG ( $P$  value = 0.001), Figure 1B. The probability of becoming ill with COVID-19 was significantly lower in the EG [OR 0.13, 95% confidence interval (CI) 0.03-0.40;  $P$  value = 0.0001]. We also found that increasing age decreases the risk of contagion (OR = 0.93, 95% CI 0.88-0.98,  $P$  value = 0.02). The probability of contracting COVID-19 was dependent on the subject's pre-existing comorbidity (OR 3.45, 95% CI 1.55-7.67,  $P$  value = 0.002). The other variables (sex and job designation) did not have influence on COVID-19 infection.

Health personnel are one of the most exposed groups to COVID-19 because of their steady contact with infected patients. In this study, treatment with IVER/IOTACR

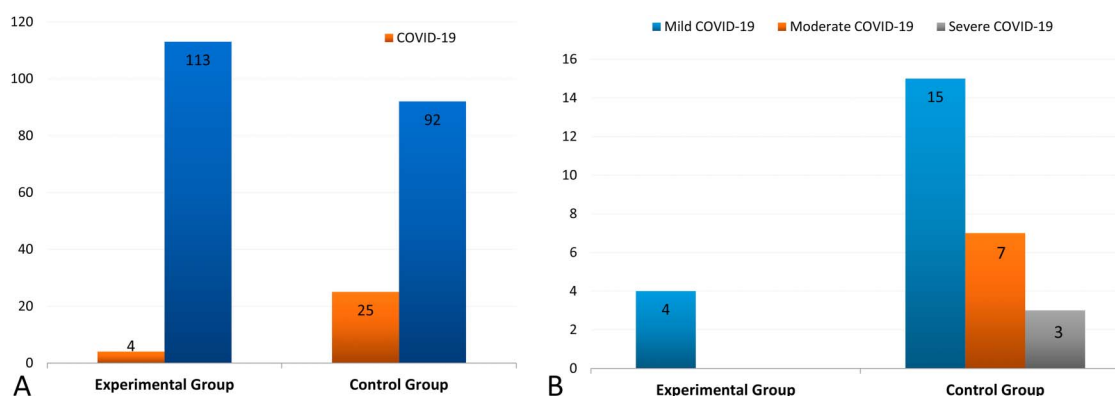
**Table 1.** Demographic profile.

Variables	Experimental Group (n= 117)	Control Group (n= 117)
Demographic profile		
Median age (in yr)	40	37
IQR	IQR25: 32; IQR75: 46	IQR25: 33; IQR75: 44
Sex, no. (%)		
Female	65 (55.56%)	69 (58.97%)
Male	52 (44.44%)	48 (41.03%)
Comorbidities, no. (%)		
Hypertension	13 (11.11%)	8 (7.55%)
Diabetes	10 (8.55%)	7 (6.60%)
Obesity	10 (8.55%)	18 (16.98%)
>60 yrs	5 (4.27%)	5 (4.27%)
Chronic kidney disease	3 (1.36%)	2 (1.89%)
Designation		
Health care personnel	99 (84.62%)	82 (70.09%)
Not an health care personnel	18 (15.38%)	35 (29.91%)

for pre-exposure prophylaxis to COVID-19 has shown a protective effect over the control group. People infected with COVID-19 at the end of the follow-up was significantly higher in the CG compared with the EG (Figure 1B).

Our findings are supported by several recent prevention trials such as Alam et al<sup>10</sup> (also cited by Kory's meta-analysis), who conducted an observational prophylactic study in 118 health care workers and found significant less contagious infection in subjects who received ivermectin.<sup>6,10</sup> Our findings, similarly to Carvallo et al and Abd-Elsalam et al, confirm the hypothesis that IVER/

IOTACRC decreases the possibility of infection with severe acute respiratory syndrome coronavirus 2 (SARS-CoV-2) and possibly acts synergistically.<sup>9,14,15</sup> We hypothesize that a double viral barrier is formed, enhancing its action in the following ways: (1) The first barrier for viral protection would be at the entry of the virus into the nasal cavity where the carrageenan would behave as a mucolytic agent in the barrier of sulfated polysaccharides with negative charge<sup>9</sup>; (2) ivermectin decreases the viral load based on its systemic cellular action.<sup>5,16</sup> Ivermectin has shown viral clearance in other clinical trials which



**FIGURE 1.** COVID-19 case in the EG versus the CG. (A) Number of COVID-19 cases and healthy cases in the experimental and control group (n = 234). (B) Clinical state of the COVID-19 cases in the experimental and control group (n = 234). The most frequent symptoms were fever experienced by 21 patients (17%) in the CG versus 1 (0.9%) in the EG (21),  $P < 0.0001$ . Nineteen patients (16%) in the CG experienced taste and/or smell disturbances and 0 (0%) in the EG,  $P < 0.0001$ . Furthermore, 19 patients (16%) experienced headache in the CG versus 1 (0.9%) in the EG,  $P < 0.0001$ . A higher frequency of polyarthralgia, diarrhea, abdominal pain, and low oxygen saturation was also reported in the control group. Acute lower respiratory infection symptoms and signs were reported in 1 patients in the control group.

evaluate its use to treat COVID-19. Kolewieski et al found that a 5-day intensive treatment of ivermectin resulted in earlier clearance of the virus compared with the control group.<sup>8</sup>

Ivermectin can prevent the entry into the cell nucleus of the viral RNA by blocking importin alpha/beta, thereby preventing replication because SARS-CoV-2 does not have the nuclear mechanisms and enzymatic actions for the transcription of new viral replicates.<sup>4</sup> Our study is supported by findings which demonstrated the effect of ivermectin as a drug for inhibiting viral replication in vitro and places the drug as a new therapeutic candidate against SARS-CoV-2.<sup>16,17</sup> In a meta-analysis published in June 2021, Bryant et al after analyzing different clinical trials showed that ivermectin may have beneficial effects in both prophylaxis and treatment of Covid-19.<sup>18</sup>

Our study shows agreement with other research groups regarding positive findings in the use of ivermectin for the treatment of COVID-19 that deserves further studies about repurposing ivermectin.

**Rossana E. Chahla, MD, PhD<sup>1</sup>**

**Luis Medina Ruiz, MD<sup>2</sup>**

**Eugenia S. Ortega, MSc<sup>3</sup>**

**Marcelo F. Morales, RN<sup>4</sup>**

**Francisco Barreiro, MD<sup>5</sup>**

**Alexia George, MD<sup>5</sup>**

**Cesar Mancilla, RN<sup>4</sup>**

**Sylvia D' Amato, RN<sup>4</sup>**

**Guillermo Barrenechea, MSc<sup>3</sup>**

**Daniel G. Goroso, PhD<sup>3,6</sup>**

**Maria Peral de Bruno, PhD<sup>3,7</sup>**

<sup>1</sup>Ministry of Health, Tucumán, Argentina

<sup>2</sup>Province Health System, SI.PRO.SA, Tucumán  
Argentina

<sup>3</sup>Health Research Institute, Ministry of Health  
Tucumán, Argentina

<sup>4</sup>Clinical Hospital "Ángel C. Padilla," Tucumán  
Argentina

<sup>5</sup>Medical Center Emergence, Tucumán, Argentina

<sup>6</sup>Research and Technology Center, Mogi das Cruzes  
University, Brazil

<sup>7</sup>School of Medicine-Superior Institute of Biological  
Research (INSIBIO—CCT CONICET), Tucumán  
Argentina

The authors have no conflicts of interest to declare.

## REFERENCES

1. Chong CR, Sullivan DJ. New uses for old drugs. *Nature*. 2007;448:645–646.

2. Liu Z, Fang H, Reagan K, et al. In silico drug repositioning: what we need to know. *Drug Discov Today*. 2013;18:110–115.
3. Ashburn TT, Thor KB. Drug repositioning: identifying and developing new uses for existing drugs. *Nat Rev Drug Discov*. 2004;3:673–683.
4. Caly L, Wagstaff KM, Jans DA. Nuclear trafficking of proteins from RNA viruses: potential target for antivirals? *Antivir Res*. 2012;95:202–206.
5. Caly L, Druce JD, Catton MG, et al. Since January 2020 Elsevier has created a COVID-19 resource centre with free information in English and Mandarin on the novel coronavirus COVID-19. The COVID-19 resource centre is hosted on Elsevier Connect, the company's public news and information. *Antivir Res*. 2020;178:104787.
6. Kory P, Meduri GU, Varon J, et al. Review of the emerging evidence demonstrating the efficacy of ivermectin in the prophylaxis and treatment of COVID-19. *Am J Ther*. 2021;28:e299–e318.
7. Chaccour C, Casellas A, Matteo AB, et al. The effect of early treatment with ivermectin on viral load, symptoms and humoral response in patients with non-severe COVID-19: a pilot, double-blind, placebo-controlled, randomized clinical trial. *EClinicalMedicine*. 2021;3:100720.
8. Krolewiecki A, Lifschitz A, Moragas M, et al. Antiviral effect of high-dose ivermectin in adults with COVID-19: A proof-of-concept randomized trial. *EClinicalMedicine*. 2021;37:100959.
9. Héctor C, Roberto H, Psaltis A, et al. Study of the efficacy and safety of topical ivermectin + iota-carrageenan in the prophylaxis against COVID-19 in health personnel. *J Biomed Res Clin Investig*. 2020;2:1007.
10. Alam MT, Murshed R, Gomes PF, et al. Ivermectin as pre-exposure prophylaxis for COVID-19 among health-care providers in a selected tertiary hospital in dhaka—an observational study. *Eur J Med Heal Sci*. 2020;2:1–5.
11. Shouman WM, Hegazy AA, Nafae RM, et al. Use of ivermectin as a potential chemoprophylaxis for COVID-19 in Egypt: a randomized clinical trial. *J Clin Diagn Res*. 2021;15:27–32.
12. Chahla E. Prophylaxis covid-19 in health workers through intensive treatment with ivermectin and iota-carrageenan (Ivercar-Tuc). *ClinicalTrials.gov*. 2020;20:NCT047017.
13. Chaccour C, Ruiz-Castillo P, Richardson MA, et al. The sars-cov-2 ivermectin navarra-isglobal trial (saint) to evaluate the potential of ivermectin to reduce covid-19 transmission in low risk, non-severe covid-19 patients in the first 48 hours after symptoms onset: a structured summary of a study protocol. *Trials*. 2020;21:1–4.
14. Hirsch R, Hector C. Covid 19 and ivermectin prevention and treatment update. *J Infect Dis Trav Med*. 2020;4:1–4.
15. Abd-Elsalam S, Noor RA, Badawi R, et al. Clinical study evaluating the efficacy of ivermectin in COVID-19 treatment: A randomized controlled study [published online ahead of print, 2021 Jun 2]. *J Med Virol*. 2021. doi: 10.1002/jmv.27122.

16. Sharun K, Dhama K, Patel SK, et al. Ivermectin, a new candidate therapeutic against SARS-CoV-2/COVID-19. *Ann Clin Microbiol Antimicrob.* 2020;19:23–25.
17. Şimşek Yavuz S, Ünal S. Antiviral treatment of covid-19. *Turkish J Med Sci.* 2020;50:611–619.
18. Bryant A, Lawrie TA, Dowswell T, et al. Ivermectin for Prevention and Treatment of COVID-19 Infection: A Systematic Review, Meta-analysis, and Trial Sequential Analysis to Inform Clinical Guidelines. *Am J Ther.* 2021; 28:e434–e460.

## Immune-Mediated Thrombocytopenia Associated With Ad26.COV2.S (Janssen; Johnson & Johnson) Vaccine

### *To the Editor:*

Immune thrombocytopenia (ITP) is an acquired coagulopathy caused by antibody-mediated platelet destruction. Patients may be asymptomatic or may present with mucocutaneous to life-threatening bleeding.<sup>1</sup> Vaccines such as influenza, MMR, hepatitis B, and diphtheria-tetanus-pertussis have been reported to cause ITP.<sup>2</sup> Approximately 40 cases of ITP were reported to the Vaccine Adverse Event Reporting System after receiving the Pfizer and Moderna COVID-19 vaccines by the end of January 2021.<sup>3</sup> It is unknown whether these cases include those with pre-existing thrombocytopenia. Here, we present a case report of an elderly woman presenting with life-threatening thrombocytopenia after receiving the Ad26.COV2.S (Janssen; Johnson & Johnson, New Brunswick, NJ) vaccine. To the best of our knowledge, this is the first publication of isolated severe thrombocytopenia in a patient with no pre-existing risk factors after receiving the Ad26.COV2.S vaccine.

A 63-year-old woman with a medical history of cervical cancer status after total hysterectomy, presented to the hospital with complaints of bleeding from her gums for the past 3 days. Seventeen days before presentation, the patient had received the Ad26.COV2.S (Janssen; Johnson & Johnson) vaccine. She did not experience any major side effects after her vaccination except for muscle soreness at the administration site. She did not have fever, chills, shortness of breath, or recent infections. A week later, she went for a routine dental checkup which was unremarkable. She started experiencing bleeding in her gums 3 days before presentation. She later had sudden onset nose bleeds which prompted her to go to the emergency department.

On presentation to the emergency department, the patient was hemodynamically stable and afebrile. Her bleeding had resolved. Complete blood count showed hemoglobin 12.2 g/dL, hematocrit 36.3%, white blood

cell count  $10.9 \times 10^3$  cells/uL, and significant severe thrombocytopenia  $2 \times 10^9$ /L. Her international normalized ratio was 1.02, with a prothrombin time of 13.5 seconds and a partial thromboplastin time of 27.0 seconds. Hemolytic workup was completed with lactate dehydrogenase 150 U/L, haptoglobin 192 mg/dL, and D-dimer 0.76.

On admission, she received 2 units of platelets. She was also given a one-time dose of prednisone 60 mg orally. Her repeat platelet count posttransfusion improved to  $14 \times 10^9$ /L. Hematology was consulted and recommended starting the patient on immune globulin (human) infusion intravenously and dexamethasone 20 mg daily.

Throughout admission, the patient's platelet count steadily increased. She did not have further bleeding episodes and did not require additional platelet transfusions. Testing for HIV and hepatitis B and C was negative. Heparin-induced platelet IgG antibody was negative. Imaging including ultrasound Doppler of the abdomen/pelvis, ultrasound Doppler of upper and lower extremities, magnetic resonance venogram of the head, and computed tomography angiography of the thorax showed no evidence of thrombosis. The patient remained hemodynamically stable throughout admission with no signs of active bleeding. She was ultimately deemed stable for discharge 5 days after admission, with a platelet count of  $252 \times 10^9$ /L.

Immune thrombocytopenia purpura (ITP) is a diagnosis of exclusion characterized by a decrease in platelet count and prolonged bleeding time secondary to impaired platelet production or destruction of circulating platelets. Patients are commonly asymptomatic; however, based on the severity of thrombocytopenia, clinical features include easy bruising, petechiae, bleeding gums, hematuria, or melena. ITP is often triggered idiopathically; however, other triggers include previous viral or bacterial infections, lymphoma or