

# Strongyloidiasis Outside Endemic Areas: Long-term Parasitological and Clinical Follow-up After Ivermectin Treatment

Silvia A. Repetto,<sup>1,2</sup> Paula Ruybal,<sup>1</sup> Estela Batalla,<sup>1</sup> Carlota López,<sup>3</sup> Vanesa Fridman,<sup>2</sup> Mariela Sierra,<sup>2</sup> Marcelo Radisic,<sup>4</sup> Pablo M. Bravo,<sup>2,4</sup> Marikena G. Riso,<sup>1</sup> Stella M. González Cappa,<sup>1</sup> and Catalina D. Alba Soto<sup>1</sup>

<sup>1</sup>Facultad de Medicina, Instituto de Investigaciones en Microbiología y Parasitología Médica, Consejo Nacional de Investigaciones Científicas y Técnicas and <sup>2</sup>División Infectología, Hospital de Clínicas "José de San Martín," Universidad de Buenos Aires, <sup>3</sup>Sección Infectología, Hospital General de Agudos "Carlos G. Durand", and <sup>4</sup>División de Enfermedades Infecciosas, Instituto de Nefrología/Nephrology, Buenos Aires, Argentina

**Background.** *Strongyloides stercoralis* affects 30–100 million people worldwide. The first-line therapy is ivermectin. Cure is defined as the absence of larvae by parasitological methods 1 year after treatment. To date, no longitudinal parasitological studies for longer periods of time have been conducted to confirm its cure. Here, we evaluated treatment response in long-term follow-up patients with chronic infection using parasitological and molecular methods for larvae or DNA detection.

**Methods.** A prospective, descriptive, observational study was conducted between January 2009 and September 2015 in Buenos Aires, Argentina. Twenty-one patients with *S. stercoralis* diagnosis were evaluated 30, 60, and 90 days as well as 1, 2, 3, and/or 4 years after treatment by conventional methods (fresh stool, Ritchie method, agar plate culture), *S. stercoralis*-specific polymerase chain reaction (PCR) in stool DNA, and eosinophil values.

**Results.** During follow-up, larvae were detected by conventional methods in 14 of 21 patients. This parasitological reactivation was observed starting 30 days posttreatment (dpt) and then at different times since 90 dpt. Eosinophil values decreased ( $P = .001$ ) 30 days after treatment, but their levels were neither associated with nor predicted these reactivations. However, *S. stercoralis* DNA was detected by PCR in all patients, both in their first and subsequent stool samples, thus reflecting the poor efficacy of ivermectin at eradicating parasite from host tissues. Asymptomatic eosinophilia was the most frequent clinical form among chronically infected patients.

**Conclusions.** These results suggest that the parasitological cure is unlikely. Strongyloidiasis must be considered a chronic infection and ivermectin administration schedules should be reevaluated.

**Keywords.** strongyloidiasis follow-up; helminth molecular diagnosis; ivermectin; *S. stercoralis* treatment.

*Strongyloides stercoralis* infection is not always self-limited due to its autoinfection cycle, which leads to chronic infection. Long-term persistence of this parasitosis has been well documented among World War II former prisoners who acquired the infection in endemic areas before returning to their countries [1]. People infected with *S. stercoralis* who live outside endemic areas can remain asymptomatic for decades while disseminated or severe forms of the disease are found to be major complications only among the immunocompromised. In these cases, increasing numbers of circulating larvae reaching the lungs as well as adult nematodes in the intestine are commonly observed. Circulating larvae may also attain several tissues including the central nervous system. These erratic nematodes carrying their cuticle gram-negative intestinal bacteria can lead

to the development of secondary bacterial infections with high mortality rates [2]. Larvae output is usually intermittent, leading to poor sensitivity of microscopic stool examination for the diagnosis and to assess the efficacy of antiparasitic therapy. Although diverse molecular methods have been developed [2], larvae visualization by microscopy remains the gold standard for diagnosis. In a recent study, we reported a specific and highly sensitive polymerase chain reaction (PCR) assay for the detection of *S. stercoralis* in stool samples [3].

The role of antiparasitic treatments is to control the symptomatology and to prevent the development of severe forms of the disease. Nevertheless, mebendazole requires long treatment schedules (100 mg twice daily for 4–5 days repeated at least twice) [4] while, for albendazole, cure rates of 62% and 69% have been calculated with multiple or single (400 mg) doses, respectively [4]. Presently, ivermectin is the drug of choice against *S. stercoralis* [5], with reported cure rates of 88% using a single oral dose (200 µg/kg/day), increasing to 96% when a second dose is administered [6, 7]. However, many reports revealed that this drug fails to attain a complete success, probably because ivermectin activity is limited to the intestinal stages

Received 14 September 2017; editorial decision 18 November 2017; accepted 30 November 2017; published online January 19, 2018.

Correspondence: S. A. Repetto, Facultad de Medicina, Universidad de Buenos Aires, Paraguay 2155, Piso 14, Buenos Aires C1121ABG, Argentina (silvia\_repetto@yahoo.com.ar).

Clinical Infectious Diseases® 2018;66(10):1558–65

© The Author(s) 2018. Published by Oxford University Press for the Infectious Diseases Society of America. All rights reserved. For permissions, e-mail: journals.permissions@oup.com. DOI: 10.1093/cid/cix1069

of *S. stercoralis*, rendering its effect on the extraintestinal stages uncertain [8]. To date, no studies have been focused on evaluating the long-term response to ivermectin treatment. Moreover, ivermectin efficacy has only been assessed by conventional diagnostic methods, thus posing an additional drawback when concluding about the efficacy of this antihelminthic drug against *S. stercoralis* human infection.

Parasitological cure is currently defined as the absence of larval stages after 1 year posttreatment, but no reports have established whether *S. stercoralis* can be eradicated from the host [9, 10]. Moreover, no longitudinal parasitological studies for prolonged periods of time after parasiticide treatment have been conducted to confirm cure in patients who did not return to endemic areas.

The aim of this study was to evaluate the response to ivermectin in long-term follow-up patients with chronic strongyloidiasis without any risk of exogenous infection.

## MATERIALS AND METHODS

### Study Design and Patients

A prospective, descriptive, observational study was conducted between January 2009 and September 2015 in Buenos Aires, Argentina, to evaluate the clinical and parasitological evolution of strongyloidiasis after ivermectin treatment. Patients aged >18 years attending the Hospital General de Agudos Carlos G. Durand, the Instituto de Nefrología, and the Hospital de Clínicas José de San Martín, Division Infectología (Universidad de Buenos Aires [UBA]) were referred to the Clinical Parasitology Unit at the last hospital for evaluation. Stool samples were sent to the Laboratory of Clinical and Molecular Parasitology of Instituto de Investigaciones en Microbiología y Parasitología Médica (Consejo Nacional de Investigaciones Científicas y Técnicas, UBA) for parasitological diagnosis.

All subjects presented history of residence in *S. stercoralis*-endemic areas and current residence in nonendemic ones during the period studied. Northeastern and northwestern regions of Argentina and other worldwide tropical and subtropical regions were considered endemic areas [3]. All patients answered a rigorous questionnaire at each medical appointment during the follow-up, thus guaranteeing the absence of parasite reexposure risk (ie, travel to the endemic area). Those patients who returned to or visited endemic areas were withdrawn from this study.

Admission records of patients included past residence in endemic areas, clinical manifestations attributable to *S. stercoralis* infection, underlying illnesses, and complete blood and eosinophil counts. Clinical strongyloidiasis was categorized as asymptomatic, intestinal, respiratory, or severe disease (hyperinfection and disseminated forms). Eosinophilia corresponds to  $\geq 450$  cells/ $\mu\text{L}$  peripheral blood eosinophils. Immunological status was defined according to the presence of chronic illness, immunosuppressive or steroid therapy, hematologic malignancies, human immunodeficiency virus (HIV) infection, human

T-lymphotrophic virus 1 (HTLV-1) infection, and transplantations or connective tissue diseases. HIV- and HTLV-1-infected patients were screened by enzyme immunoassays and confirmed by Western blotting. Exclusion criteria included the risk of novel exogenous infections over the last 5 years and pregnancy.

### Stool Samples

Participants collected stool samples for 7 consecutive days in 5% formaldehyde into a single flask and separated fresh stool samples for diagnosis and follow-up. Fresh samples were stored at  $-20^{\circ}\text{C}$  in our facilities [11, 12]. Details about the use of fresh, fixed, or frozen stool are provided below.

### *S. stercoralis* Diagnosis: Conventional and Molecular Methods

Each technique was performed by independent operators to eliminate test interpretation bias. Patients were considered infected when rhabditoid/filariform *S. stercoralis* larvae were visualized and/or *S. stercoralis*-specific PCR was positive. A participant was considered negative when neither larvae nor PCR-specific bands were detected.

DNA isolation from fresh or frozen stool and *S. stercoralis*-specific PCR were performed on the first stool and every follow-up sample obtained from each participant.

### Microscopic Diagnosis

One gram of fresh stool was homogenized in phosphate-buffered saline and centrifuged, and pellets were analyzed by light microscopy. Formalin-fixed stools were studied by the Ritchie method.

### Agar Plate Culture

Fresh stool was seeded in the center of agar plates in triplicate, incubated at  $37^{\circ}\text{C}$  for up to 7 days, and examined daily under a stereomicroscope searching for larvae or their migration tracks. Worm morphology was confirmed by microscopic examination [11, 12].

### DNA Isolation

To obtain the templates for diagnostic PCR, DNA extraction was performed on fresh or frozen stool samples using the combined method standardized in our laboratory [11].

*Trypanosoma cruzi* epimastigotes were added to each sample before DNA isolation as exogenous amplification control for the extraction and amplification processes [11].

### *S. stercoralis*-Specific PCR

Amplification of a 101-bp region of *S. stercoralis* 18S small subunit ribosomal RNA gene (GenBank accession number AF279916) was performed using primers Stro 18S-1530F 5'-GAATTC-CAAGTAAACGTAAGTCATTAGC-3' and Stro 18S-1630R 5'-TGCCTCTGGATATTGCTCAGTTC-3' [13]. PCR was performed in a final volume of 20  $\mu\text{L}$  with 0.01 U/L Taq polymerase (Hot Start, Fermentas), 0.1 g/L bovine serum albumin, and

0.5 µM of each primer, and 4 µL of DNA was extracted as mentioned above as template. Cycling conditions were: 3 minutes at 95°C, 35 cycles of 45 seconds at 95°C, 1 minute at 55°C, and 45 seconds at 72°C with a final elongation of 5 minutes at 72°C. Nuclease-free water and stool DNA from healthy subjects were used as negative controls. DNA isolated from *S. stercoralis*-spiked stool was used as positive control. PCR products were visualized in agarose gels stained with GelGreen Nucleic Acid Gel Stain (Biotium) in a Molecular Imager Gel Doc XR System (BioRad).

#### Exogenous Internal Amplification Control

*Trypanosoma cruzi*-specific PCR was performed on clinical samples using primers TCZ1: 5'-CGAGCTCTTGCCCA-CACGGGTGCT-3' and TCZ2: 5'-CCTCCAAGCAGCGGATAGTTCAGG-3' (expected product size 188 bp) as reported previously [12].

#### Pharmacological Treatment

Patients with confirmed strongyloidiasis received oral ivermectin (200 µg/kg) once a day for 2 days. Treatment was repeated after 2 weeks. Later, during the follow-up period, ivermectin was readministered only in the presence of larvae and/or symptoms. Positive PCR was not considered a criterion to start treating asymptomatic patients through the follow-up. The first 2 doses of ivermectin were administered under the physician's supervision and the remaining doses were observed by the patient's companion and recorded to ensure compliance.

#### Follow-up

After the first ivermectin administration, patients were reevaluated for the presence of symptoms compatible with strongyloidiasis, eosinophilia, and parasites (detected by conventional methods and PCR).

Parasitological techniques and PCR were performed 30, 60, and 90 days as well as 1, 2, 3, and 4 years after treatment.

#### Statistical Analyses

Both descriptive and inferential statistical analyses were performed using SPSS software package for Windows (version 21) and GraphPad Prism software package (version 5.03). A *P* value <.05 was considered statistically significant for the inferential tests. For continuous variables, data distribution was tested for normality using the Shapiro or Wilks *W* tests. Mean, median, and confidence interval were estimated. Nonparametric statistical tests (Wilcoxon signed-rank test, Mann-Whitney test, and Kruskal-Wallis with Dunn posttest) were used in the events where data distribution was not normal.

#### Ethics Statement

This study was approved by the Ethics Committee of the Medical School Hospital (Hospital de Clínicas José de San Martín) at UBA. Informed consents were signed by all participants before sample collection.

## RESULTS

#### Study Population Profile

Forty-eight *S. stercoralis*-infected individuals (diagnosed by conventional methods and/or PCR) were treated with ivermectin. Of them, 27 did not return for control, and 21 were followed up for a median of 730 days (IQI, 735 days) (Figure 1).

#### Molecular Diagnosis Reveals the Limited Efficacy of Ivermectin for the Eradication of Strongyloidiasis

*Strongyloides stercoralis* DNA was detected in all the stool samples obtained from all patients, both in their first sample and during the follow-up period. In contrast, larvae were detected in stool by conventional methods only in 14 of 21 follow-up patients (66.7%). Larvae were even detected during the ivermectin treatment follow-up in 4 patients whose initial diagnosis had been confirmed only by PCR since the conventional test rendered negative results.

The persistence of positive PCR in stool samples was independent of larvae observation by conventional methods and clinical manifestations. Considering ivermectin failure at eradicating *S. stercoralis* and the limited use of PCR in stool samples to detect a potentially harmful increase in parasite load, particularly among immunocompromised patients, we sought to define additional predictors of disease reactivation.

#### Parasitological Follow-up of *S. stercoralis* Infection and Immunological Status

Among the 21 patients who adhered to the follow-up, 14 (66.7%) were immunosuppressed and 7 (33.3%) immunocompetent (Table 1). Parasitological reactivation was observed at any time during the follow-up in 9 of 14 (64.3%) immunosuppressed and in 5 of 7 (71.4%) immunocompetent patients without significant

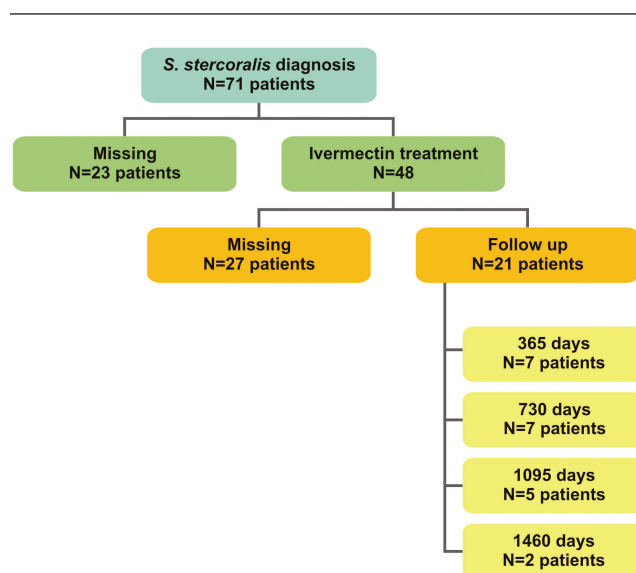


Figure 1. Evolution over time of the study population considering ivermectin treatment.

**Table 1. Reactivation and Clinical Manifestations During Patients Follow-up**

Patient	Sex/Age	Patient Characteristics		Immunosuppressive		Parasitological Reactivation		Clinical Reactivation	
		Underlying Conditions	Drugs	Reactivation	Larvae Detection Method (dpt)	Signs and Symptoms	Signs and Symptoms	(Positive PCR/Without Larvae Visualization in Stool)	
1 <sup>a</sup>	M/45	Tuberculosis infection	None	Parasitological and clinical	<i>Strongyloides stercoralis</i> APC (30 and 730)	Asymptomatic eosinophilia	Asymptomatic eosinophilia (60)		
2 <sup>a</sup>	F/68	Chronic myeloid leukemia	Meprednisone	Parasitological and clinical	Fresh stool (90)	Dyspnea and eosinophilia	Dyspnea and eosinophilia (60 and 730)		
3 <sup>a</sup>	F/53	Rheumatoid arthritis	Meprednisone	Parasitological and clinical	Fresh stool (90 and 360)	Asymptomatic eosinophilia	Asymptomatic eosinophilia (30)		
4 <sup>a</sup>	F/55	AIDS	None	Parasitological and clinical	Fresh stool (730)	Asymptomatic	Asymptomatic eosinophilia (30)		
5 <sup>a</sup>	F/42	Leukocytoclastic vasculitis	Meprednisone	Parasitological and clinical	APC (360)	Asymptomatic eosinophilia	Asymptomatic eosinophilia (30)		
6 <sup>a</sup>	F/65	Primary biliary cirrhosis	Meprednisone	Parasitological and clinical	Fresh stool and APC (360)	Pneumonia and septic shock <sup>b</sup>	...		
7 <sup>a</sup>	M/62	Rheumatoid arthritis	Etanercept	Parasitological	APC (360)	Asymptomatic eosinophilia	...		
8	F/37	None	None	Parasitological	Fresh stool and APC (90 and 730)	Asymptomatic eosinophilia	...		
9	M/32	None	None	Parasitological	APC (360)	Asymptomatic eosinophilia	...		
10	F/54	None	None	Parasitological	APC (600)	Asymptomatic eosinophilia	...		
11	M/47	None	None	Parasitological	APC (30 and 730)	Asymptomatic eosinophilia	...		
12 <sup>a</sup>	M/31	AIDS	None	Parasitological	APC (360 and 1095)	Asymptomatic	...		
13	F/67	None	None	Parasitological	APC (30)	Asymptomatic	...		
14 <sup>a</sup>	M/45	AIDS	None	Parasitological	APC (360)	Asymptomatic	...		
15 <sup>a</sup>	F/63	Kidney transplant recipient	Meprednisone	Clinical	...	...	<i>Escherichia coli</i> sepsis and eosinophilia (90)		
16 <sup>a</sup>	F/59	Giant-cell arteritis	Meprednisone	Clinical	...	...	Peritonitis (360) <sup>b</sup>		
17 <sup>a</sup>	M/30	AIDS	None	Clinical	...	...	Asymptomatic eosinophilia (30)		
18 <sup>a</sup>	M/46	AIDS	None	No reactivation	...	...	...		
19	M/45	None	None	No reactivation	...	...	...		
20 <sup>a</sup>	M/64	AIDS	None	No reactivation	...	...	...		
21	M/65	None	None	No reactivation	...	...	...		

Abbreviations: APC, agar plate culture; dpt, days posttreatment; F, female; M, male; PCR, polymerase chain reaction.

<sup>a</sup>Immunosuppressed patient.

<sup>b</sup>Deceased patient.

associations between parasitological reactivation and immunological status (Fisher test  $P = .57$ ; **Figure 2A**). Among the immunosuppressed patients with disease reactivation, 3 were positive for HIV and none for HTLV-1 (data not shown).

Regarding the parasitological method for *S. stercoralis* detection among the immunosuppressed patients, larvae were detected by agar plate culture (APC) in 5 of 9 (55.6%) patients, in fresh stool samples in 3 of 9 (33.3%) patients, and in 1 patient by both methods. Among the immunocompetent patients, larvae were detected by APC in 4 of 5 (80%) patients and by fresh stool examination in 1 patient who was also positive by APC (20%) (**Figure 2B**).

### Parasite Burden and Clinical Manifestations

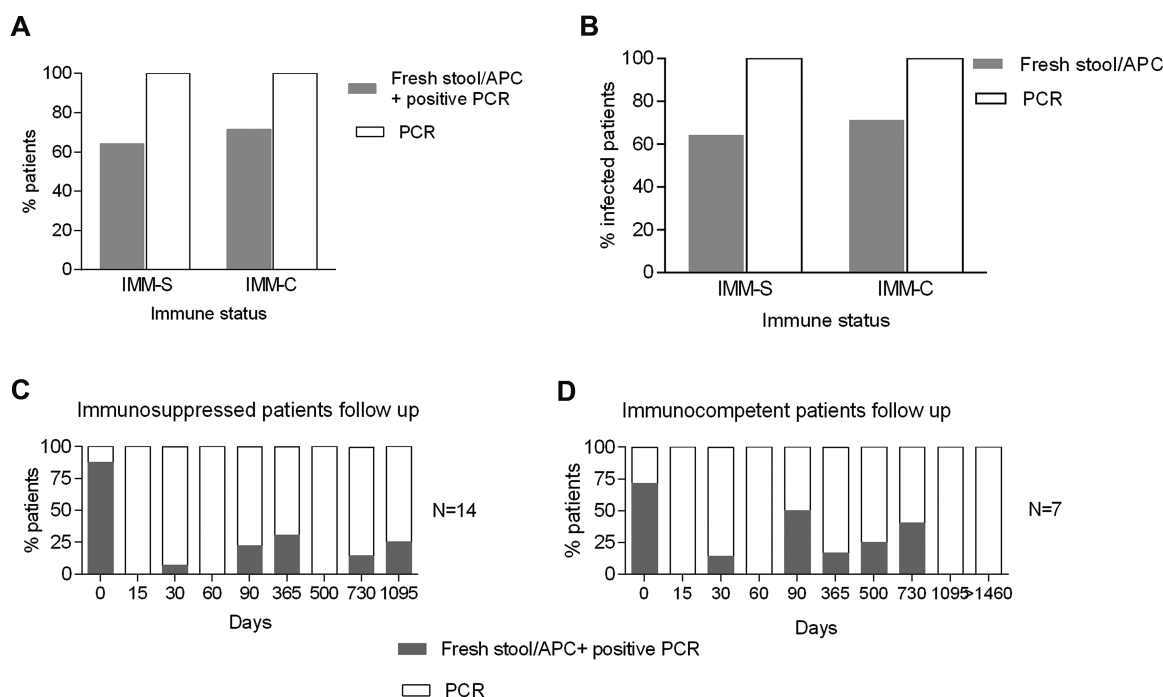
The first round of ivermectin treatment was consistently followed by a temporary decrease in parasite burden. Indeed, larvae were not detected in stool by parasitological methods 15 days posttreatment (dpt) (**Figure 2C**). Thereafter, parasitological reactivation was detected by fresh stool microscopic examination or APC starting at 30 dpt and then at different times since 90 dpt (**Figure 2C and D**; **Table 1**). Such variations in parasite load were independent of patients' immune status. Furthermore, even though patients received additional rounds of ivermectin after parasitological reactivation, 8 patients had >1 episode of reactivation after etiological treatment.

**Table 1** shows the diverse clinical manifestations observed in patients with chronic infection. Those with parasitological

reactivation may present without any symptoms or only with eosinophilia. However, severe forms of infection may occur in immunocompromised patients. Clinical reactivation of the disease was defined as the recurrence of symptoms and/or eosinophilia without larvae visualization in fresh stool or by APC. In addition, 4 patients showed neither parasitological nor clinical reactivation even when all their stool samples collected during the follow-up were PCR positive.

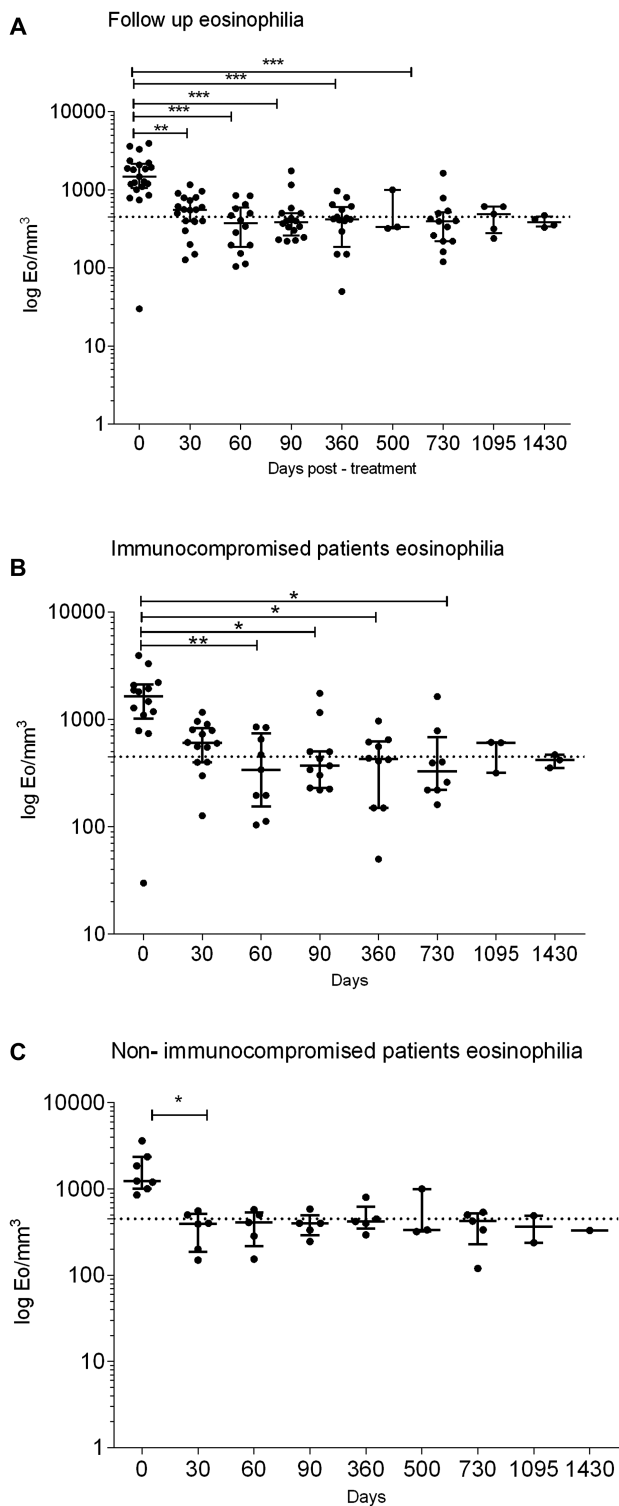
### Use of Eosinophilia as a Parasitological Reactivation Marker

Parasite persistence after ivermectin treatment as detected by PCR reveals the chronic trait of this infection which, in addition, involves fluctuating parasitic burden. In this context, we evaluated the potential use of eosinophil count for predicting a harmful rise in larvae burden. Eosinophil counts decreased significantly in all patients 30 dpt even though normal values were not reached in all the patients (pretreatment median, 1774 eosinophils/ $\mu\text{L}$  [interquartile range, 1097]; post-treatment median, 554.5 eosinophils/ $\mu\text{L}$  [interquartile range, 381.8];  $P = .001$ ; **Figure 3A**). No significant differences were observed in eosinophil values between immunocompromised and non-immunocompromised patients during the follow-up (Wilcoxon test  $P = .47$ ; **Figure 3B and 3C**). The dispersion of eosinophil counts among the immunocompromised individuals is noteworthy, as these values may vary according to their underlying condition.



**Figure 2.** A, Parasitological reactivation according to immune status considering the follow-up. B, Conventional diagnosis of *Strongyloides stercoralis* in stool samples. C and D, Time scale of different parasitological reactivation episodes in immunosuppressed (IMM-S) and immunocompetent (IMM-C) patients (C and D, respectively). Gray squares: larvae observation in fresh stool/agar plate culture (APC) and positive polymerase chain reaction (PCR). White squares: No larvae observation by conventional method; only positive PCR. Day 0: initial time of *S. stercoralis* diagnosis and ivermectin treatment.





**Figure 3.** A, Follow-up eosinophilia values in all patients. Individual and median (interquartile range [IQR]) eosinophil (Eo) counts are plotted at day 0 and along the follow-up period after the first ivermectin therapy. Follow-up of eosinophilia values according to immunological status of the patients—immunosuppressed (B) or immunocompetent (C). Individual and median (IQR) eosinophil counts are plotted at day 0 and along the follow-up period after the first ivermectin therapy. The dotted horizontal line indicates the accepted normal threshold of eosinophil counts (450 eosinophils/ $\mu$ L). Kruskal-Wallis, Dunn posttest, \* $P < .01$ , \*\* $P < .001$ , \*\*\* $P < .0001$ .

## DISCUSSION

Several studies focused on evaluating ivermectin efficacy for strongyloidiasis have already been published [14–24]. However, none of them performed molecular methods or long-term parasitological clinical follow-up to confirm parasitological cure in patients who did not return to endemic areas.

Treatment options for uncomplicated strongyloidiasis are thiabendazole, albendazole, and ivermectin, with the latter being the drug of choice for this parasitosis [14, 15]. Two oral doses of 200 mg/kg/day is the scheme most frequently used to treat asymptomatic/intestinal forms [14]. Table 2 shows some representative studies based on parasitological methods of limited sensitivity to assess ivermectin efficacy in which post-treatment response does not always reach 100% [16–24]. In our laboratory, a molecular method such as PCR with steady positive results in stool reveals that the current treatment diminishes parasite load but does not eliminate the parasite from the host, thus confirming *S. stercoralis* persistence at low parasite burden and progression to chronic infection. Furthermore, in 67% of our study population, larvae were visualized by conventional parasitological methods at least once during the posttreatment follow-up. Parasitological reactivations were documented mostly 1 year posttreatment or later, indicating that shorter observation periods may be insufficient to detect the whole dimension of treatment failure.

On the other hand, APC and Baermann methods have been recommended by different authors for the posttreatment follow-up [9, 10, 15]. Our results show that the frequency of parasitological reactivation is similar among immunocompetent and immunocompromised patients. Thereafter, every patient should be followed up regularly by APC and, in the event of a increase in parasite burden detected by using this technique, antiparasitic treatment should be indicated.

Persistence of parasite DNA detection by PCR among our patients with such high rates of recurrence of larvae detection in stool samples strongly indicates the ineffectiveness of ivermectin at eliminating the parasite from the host. Therefore, a high sensitivity technique such as the conventional PCR can be suitable for early diagnosis but not for the posttreatment monitoring of *S. stercoralis* infection. It would be optimal to have a sensitive and specific method to quantify parasite load in stool to predict parasite reactivation accurately.

Nuesch et al [25] reported that monitoring of blood eosinophil count may also be an effective tool to predict therapeutic success as a significant decrease is achieved after treatment. When eosinophilia was evaluated here as an immunological marker to predict parasite reactivation, 3 criteria were chosen for the analysis: initial counts, 30 dpt, and long term follow-up. As we have described previously, the presence of eosinophilia at the time of diagnosis increased the probability of infection

**Table 2. Studies on Ivermectin Efficacy to *Strongyloides stercoralis* Treatment**

Ivermectin	Patients, No.	Follow-up Duration	Parasitological Method	Posttreatment Response, No. (%)	Reinfection Risk	Reference
1 Single dose, 100 µg/kg/day	22	3 months	APC	17 (25)	None	[16]
Two days, 200 µg/kg/day	35			35 (100)		
2 Single dose, 150–200 µg/kg/day	29	30 days	Fresh stool and Kato smears, formalin and Baermann technique	24 (83)	None	[17]
3 Single dose, 200 µg/kg/day	16	Up to 30 months	Fresh stool and Baermann technique	16 (100)	None	[18]
Two days, 200 µg/kg/day				18 (100)		
4 Single dose, 200 µg/kg/day	152	3 weeks	Baermann technique	126 (82.8)	Yes	[19]
5 Two days, and repeat 2 weeks apart, 6 mg/day	67	12 months	Formalin-ether concentration, Harada-Mori fecal culture	65 (97)	Yes	[20]
6 Single dose, 150–200 µg/kg/day	78	30 days	APC	77 (98.7)	Yes	[21]
7 Single dose, 200 µg/kg/day	106	6 months	APC and IFAT	75 (70.8) <sup>a</sup> 30 (87.5) <sup>b</sup>	None	[22]
8 Single dose, 200 µg/kg/day	31	39 (2–74) weeks	Direct microscopic, formalin-ether concentration, modified Koga APC	30 (96.8)	ND	[23]
Two days, and repeat 2 weeks apart, 200 µg/kg/day	29	26 (2–74) weeks		27 (93.1)		
9 Single dose, 6 mg	21	4 weeks	APC	19 (90.5)	ND	[24]

Abbreviations: APC, agar plate culture; IFAT immune fluorescence antibody test; ND, not determined.

<sup>a</sup>Cure criteria: decreased serologic titer only.

<sup>b</sup>Cure criteria: negative stool culture.

by *S. stercoralis* by 6.24-fold, and values decreased significantly after 30 dpt [4]. This response to ivermectin is an indirect confirmation of parasite infection and parasite load reduction. In this small cohort, eosinophilia is not a marker for long-term follow-up as changes in this parameter are not significant except for some particular cases. Moreover, eosinophil levels may remain low in patients with either parasitological or clinical reactivation, regardless of their immunological status.

Due to the lack of a suitable marker and the sporadic larvae excretion, parasitological studies should be performed as frequently as possible in all of the patients with clinical symptoms compatible with strongyloidiasis. In this context, patients should be monitored posttreatment at least every 3 months during the first year and then twice a year. This control should be more frequent in immunocompromised patients to avoid severe forms of infection.

The difficulty in *S. stercoralis* elimination from the host relies on several causes. First, its autoinfective cycle favors parasite establishment. Second, the immune response is directed against the filariform infective L3 larvae, which possesses a different antigen pattern from L3a, the autoinfective larvae. Therefore, L3a is able to evade the immune response, thus favoring the establishment of chronic infection [26]. Third, larvae diapause with periodic reactivations in tissues has been suggested by several authors [27, 28]. Finally, experimental models of *S. stercoralis* infection suggest that ivermectin is effective against adult worms but less effective against eggs and larval stages at tissue levels [8, 9, 29]. In view of the duration of the autoinfective cycle (2–4 weeks), the administration of 2 doses of ivermectin 2 weeks apart was adopted as a current practice as shown in Table 2. Our

results suggest that administration of additional rounds of ivermectin could be implemented to kill female worms to eradicate L3a stages. Further studies are required to evaluate the effectiveness of this ivermectin schedule, and quantitative methods of high sensitivity and accuracy are needed to monitor treatment success or to predict reactivation. These results reveal the tip of the iceberg for future and in-depth studies focused on achieving the cure of this neglected disease.

## Notes

**Financial support.** This work was supported by grants from Agencia Nacional de Promoción Científica y Tecnológica (PICT 2013-0698) and Universidad de Buenos Aires (UBACYT 20021030100753BA-2014).

**Potential conflicts of interest.** All authors: No reported conflicts of interest. All authors have submitted the ICMJE Form for Disclosure of Potential Conflicts of Interest. Conflicts that the editors consider relevant to the content of the manuscript have been disclosed.

## References

- Grove DI. Strongyloidiasis in Allied ex-prisoners of war in south-east Asia. *Br Med J* 1980; 280:598–601.
- Toledo R, Muñoz-Antoli C, Esteban JG. Strongyloidiasis with emphasis on human infections and its different clinical forms. *Adv Parasitol* 2015; 88:165–241.
- Repetto SA, Ruybal P, Solana ME, et al. Comparison between PCR and larvae visualization methods for diagnosis of *Strongyloides stercoralis* out of endemic area: a proposed algorithm. *Acta Trop* 2016; 157:169–77.
- Shikiya K, Uehara T, Uechi H, et al. Clinical study on ivermectin against *Strongyloides stercoralis*. *Kansenshogaku Zasshi* 1991; 65:1085–90.
- Keiser J, Utzinger J. The drugs we have and the drugs we need against major helminth infections. *Adv Parasitol* 2010; 73:197–230.
- Ashraf M, Gue CL, Baddour LM. Case report: strongyloidiasis refractory to treatment with ivermectin. *Am J Med Sci* 1996; 311:178–9.
- Intapan PM, Maleewong W, Wongsaraj T, Singthong S, Morakote N. Comparison of the quantitative formalin ethyl acetate concentration technique and agar plate culture for diagnosis of human strongyloidiasis. *J Clin Microbiol* 2005; 43:1932–3.
- Greaves D, Coggle S, Pollard C, Aliyu SH, Moore EM. *Strongyloides stercoralis* infection. *BMJ* 2013; 347:f4610.

9. Satoh M, Kokaze A. Treatment strategies in controlling strongyloidiasis. *Expert Opin Pharmacother* **2004**; 5:2293–301.
10. Requena-Méndez A, Chiadini P, Bisoffi Z, Buonfrate D, Gotuzzo E, Muñoz J. The laboratory diagnosis and follow up of strongyloidiasis: a systematic review. *PLoS Negl Trop Dis* **2013**; 7:e2002.
11. Repetto Silvia A, Durán Pablo A, Lasala María B, González-Cappa SM. High rate of strongyloidiasis infection, out of endemic area, in patients with eosinophilia and without risk of exogenous reinfections. *Am J Trop Med Hyg* **2010**; 82:1088–93.
12. Repetto SA, Alba Soto CD, Cazorla SI, et al. An improved DNA isolation technique for PCR detection of *Strongyloides stercoralis* in stool samples. *Acta Trop* **2013**; 126:110–4.
13. Verweij JJ, Canales M, Polman K, et al. Molecular diagnosis of *Strongyloides stercoralis* in faecal samples using real-time PCR. *Trans R Soc Trop Med Hyg* **2009**; 103:342–6.
14. Mejia R, Nutman TB. Screening, prevention, and treatment for hyperinfection syndrome and disseminated infections caused by *Strongyloides stercoralis*. *Curr Opin Infect Dis* **2012**; 25:458–63.
15. Buonfrate D, Requena-Mendez A, Angheben A, et al. Severe strongyloidiasis: a systematic review of case reports. *BMC Infect Dis* **2013**; 13:78.
16. Igual-Adell R, Oltra-Alcaraz C, Soler-Company E, Sánchez-Sánchez P, Matogoyana J, Rodríguez-Calabuig D. Efficacy and safety of ivermectin and thiabendazole in the treatment of strongyloidiasis. *Expert Opin Pharmacother* **2004**; 5:2615–9.
17. Detry A, Hilmarsdottir I, Mayorga-Sagastume R, et al. Treatment of *Strongyloides stercoralis* infection with ivermectin compared with albendazole: results of an open study of 60 cases. *Trans R Soc Trop Med Hyg* **1994**; 88:344–5.
18. Gann PH, Neva FA, Gam AA. A randomized trial of single- and two-dose ivermectin versus thiabendazole for treatment of strongyloidiasis. *J Infect Dis* **1994**; 169:1076–9.
19. Marti H, Haji HJ, Savioli L, et al. A comparative trial of a single-dose ivermectin versus three days of albendazole for treatment of *Strongyloides stercoralis* and other soil-transmitted helminth infections in children. *Am J Trop Med Hyg* **1996**; 55:477–81.
20. Toma H, Sato Y, Shiroma Y, Kobayashi J, Shimabukuro I, Takara M. Comparative studies on the efficacy of three anthelmintics on treatment of human strongyloidiasis in Okinawa, Japan. *Southeast Asian J Trop Med Public Health* **2000**; 31:147–51.
21. Nontasut P, Muennoo C, Sa-nguankiat S, Fongsri S, Vichit A. Prevalence of strongyloides in northern Thailand and treatment with ivermectin vs albendazole. *Southeast Asian J Trop Med Public Health* **2005**; 36:442–4.
22. Bisoffi Z, Buonfrate D, Angheben A, et al. Randomized clinical trial on ivermectin versus thiabendazole for the treatment of strongyloidiasis. *PLoS Negl Trop Dis* **2011**; 5:e1254.
23. Suputtamongkol Y, Premasathian N, Bhumimuang K, et al. Efficacy and safety of single and double doses of ivermectin versus 7-day high dose albendazole for chronic strongyloidiasis. *PLoS Negl Trop Dis* **2011**; 5:e1044.
24. Shikiya K, Kinjo N, Uehara T, et al. Efficacy of ivermectin against *Strongyloides stercoralis* in humans. *Intern Med* **1992**; 31:310–2.
25. Nuesch R, Zimmerli L, Stockli R, Gyr N, Christoph Hatz FR. Imported strongyloidosis: a longitudinal analysis of 31 cases. *J Travel Med* **2005**; 12:80–4.
26. Brigandi RA, Rotman HL, Nolan TJ, Schad GA, Abraham D. Chronicity in *Strongyloides stercoralis* infections: dichotomy of the protective immune response to infective and autoinfective larvae in a mouse model. *Am J Trop Med Hyg* **1997**; 56:640–6.
27. Genta RM. Dysregulation of strongyloidiasis: a new hypothesis. *Clin Microbiol Rev* **1992**; 5:345–55.
28. Giacometti A, Cirioni O, Drenaggi D, et al. *Strongyloides stercoralis* infection: unknown transmission or late recrudescence? *J Infect* **1998**; 37:306–7.
29. Sithithaworn P, Fujimaki Y, Mitsui Y, Prasanthong R, Yutanawiboonchai W, Aoki Y. Efficacy of ivermectin against *Strongyloides stercoralis* infection in jirds (*Meriones unguiculatus*). *Exp Parasitol* **1998**; 89:205–12.