




# *Calodium hepaticum* (Nematoda: Capillariidae) in wild rodent populations from Argentina

María C. Fantozzi<sup>1</sup> · María del Rosario Robles<sup>2</sup> · Fiama E. Peña<sup>1</sup> · Leandro R. Antoniazzi<sup>1</sup> · Pablo M. Beldomenico<sup>1</sup>  · Lucas D. Monje<sup>1</sup>

Received: 1 March 2018 / Accepted: 19 June 2018  
© Springer-Verlag GmbH Germany, part of Springer Nature 2018

## Abstract

*Calodium hepaticum* (Nematoda; Capillariidae) is a parasitic nematode of mammals with a cosmopolitan distribution. Adults of this nematode can infect the liver of many mammalian species, including humans, but the main hosts are members of the superfamily Muroidea. Among these, *Rattus* spp. have the highest apparent prevalences reported worldwide. There are only two reports of *C. hepaticum* infecting Sigmodontinae species (Muroidea: Cricetidae). In this survey, we examined the occurrence of *C. hepaticum* in two assemblages of Sigmodontinae rodents from Argentina (Santa Fe and Entre Ríos provinces). The diagnosis was made by morphological features, histopathological exam, and molecular characterization of 18S ribosomal RNA gene region. Here, we show that *C. hepaticum* is a common parasite of Sigmodontinae. We report the infection in six species (all new hosts): *Akodon azarae*, *Calomys callidus*, *Calomys venustus*, *Oligoryzomys flavescens*, *Oligoryzomys nigripes*, and *Oxymycterus rufus*. This is the first report of *C. hepaticum* in Sigmodontinae rodents from Argentina and the second record in this subfamily for South America. It is also the first confirmation of *C. hepaticum* infection in Sigmodontinae by molecular diagnosis. The genetic findings and the prevalences observed, together with the existing information on *C. hepaticum*, lead us to propose that *Rattus* spp. brought *C. hepaticum* to the New World exposing Sigmodontinae rodents, which are frequently infected by this parasite. The high prevalence of infection in *A. azarae* (41.2%) suggests that this host may be playing an important role in *C. hepaticum* dynamics in the New World.

**Keywords** *Calodium hepaticum* · Argentina · Sigmodontinae · Wild rodents

## Introduction

*Calodium hepaticum* Moravec, 1982 (Nematoda, Capillariidae) is a cosmopolitan parasite of mammals, including humans (Ferreira and Andrade 1993; Duque et al. 2012; Fuehrer et al. 2011; Fuehrer 2014a, b). The main hosts of this parasite are rodents of the superfamily Muroidea (Fuehrer

2014a). Adults of *C. hepaticum* are found in the liver. Hepatic infections occur following ingestion of embryonated eggs by a mammal. After hatching, the larvae penetrate through the intestinal wall, migrate into the hepatic portal system, and develop as adults in the hepatic parenchyma (Spratt and Singleton 2001). Gravid females lay immature eggs there, and they are exposed to the next host after the death and decomposition of the infected host or when it becomes prey (Spratt and Singleton 2001; Camargo et al. 2010). Rothenburger et al. (2014) suggested that cannibalism may be important in transmission among rats.

Among the Muroidea rodents, *C. hepaticum* has been reported in over 90 host species of at least 44 genera of the families Muridae (Murinae, Deomyinae) and Cricetidae (Arvicolinae, Neotominae, Cricetinae, Sigmodontinae, Gerbilinae, and Cricetomyinae) (Fuehrer 2014a). However, this parasite is found frequently and at high prevalences (> 50%) in rats (*Rattus* spp.), for which rats are considered the main hosts of *C. hepaticum* (Ceruti et al. 2001; Spratt and

✉ Pablo M. Beldomenico  
pbeldome@fcv.unl.edu.ar

<sup>1</sup> Laboratorio de Ecología de Enfermedades, Instituto de Ciencias Veterinarias del Litoral (ICiVet-Litoral), Universidad Nacional del Litoral (UNL) / Consejo Nacional de Investigaciones Científicas y Técnicas (CONICET), RP Kreder 2805, 3080 Esperanza, Santa Fe, Argentina

<sup>2</sup> Centro de Estudios Parasitológicos y de Vectores (CEPAVE), CCT-CONICET - La Plata/Universidad Nacional de La Plata, Bv. 120 e/61 y 64, 1900 La Plata, Buenos Aires, Argentina

Singleton 2001; Duque et al. 2012; Moreira et al. 2013; Fuehrer 2014a; Simões et al. 2014). In the New World, the predominant Muroidea rodents are the Sigmodontinae, which comprise 381 species (D'Elia and Pardiñas 2015). Many of them live in sympatry with the introduced Murinae *Rattus norvegicus* Berkenhout, 1769 and *Rattus rattus* Linnaeus, 1758. Despite the large diversity of Sigmodontinae present across the Americas, *C. hepaticum* has only been recorded in *Akodon venezuelensis* Allen, 1899 and *Sigmodon hispidus* Say & Ord, 1825, both diagnosed through morphological exam (Vogelsang and Espin 1949; Kinsella 1974). Diagnosis of *C. hepaticum* infection by molecular techniques has not been reported in Sigmodontinae. Recently, there has been an increase in the molecular analyses of Trichinelloidea nematodes (including works on Trichuridae and Capillariidae) from rodents (e.g., Robles et al. 2014, 2018; Callejón et al. 2016). Particularly, a study had clarified the phylogenetic position of *C. hepaticum* among the capillarids and the relationships between some species of two families, Capillariidae and Trichuridae (Guardone et al. 2013).

In this context, the aim of this paper was to document the occurrence of *C. hepaticum* in two rodent assemblages of central Argentina, basing the diagnosis on morphological characteristics, histopathological exam, and 18S ribosomal RNA sequences. Also, we provide a comprehensive summary of existing records from rodents in South America and compare our molecular findings with previous genetic studies.

## Materials and methods

### Data collection

A total of 409 Sigmodontinae rodents were trapped in Esperanza (ES), Santa Fe Province (31° 24' 20" S–60° 58' 16" W) and La Picada (LP), Entre Ríos Province (31° 44' 06" S–60° 21' 53" W), Argentina, during several field trapping sessions carried out between June 2014 and September 2016. Rodents captured were identified to the species level by assessing cranium morphology (Massoia and Fornes 1965; Massoia 1973; Goncalvez and De Oliveira 2004). The Sigmodontinae species captured and total count were as follows: *Akodon azarae* Fischer, 1829 ( $n = 119$  ES and 26 LP), *Calomys callidus* Thomas, 1916 ( $n = 29$  LP), *Calomys venustus* Thomas, 1894 ( $n = 101$  ES), *Holochilus chacarius* Thomas, 1906 ( $n = 14$  ES and 2 LP), *Necromys lasiurus* Lund, 1840 ( $n = 5$  ES), *Oligoryzomys flavescens* Waterhouse, 1837 ( $n = 42$  ES and 9 LP), *Oligoryzomys nigripes* Olfers, 1818 ( $n = 15$  ES), and *Oxymycterus rufus* Fischer, 1814 ( $n = 47$  LP).

All captured specimens were necropsied, and livers were dissected and stored in plastic bags with ethanol (70%). At the laboratory, they were examined under a stereoscopic microscope in order to observe lesions consistent with *C.*

*hepaticum* infection. The worm parts that could be recovered from the lesions were cleared in lactophenol, studied under light microscope, and then identified following Wright (1961). In a subset of samples, diagnosis was complemented by histopathology (following routine procedures) and by molecular determination.

The prevalence (P) of *C. hepaticum* in each host population was estimated by macroscopic and microscopic exams of the lesions and helminths (as only part of the sample was processed by histopathology or molecular techniques) and was calculated following Bush et al. (1997).

### Molecular determination

Three specimens morphologically identified as *C. hepaticum* (two from *A. azarae* and one from *C. callidus*) were washed extensively in 0.9% saline solution and stored in 70% ethanol until used for PCR and sequencing. Genomic DNA from individual worms was extracted using the AccuPrep® Genomic DNA Extraction Kit (Bioneer) according to the manufacturer's protocol. Genomic DNA concentration and purity were assessed using the SPECTROstar Nano and the MARS Data Analysis Software (BMG Labtech, Germany). 18S rRNA partial gene was amplified by the polymerase chain reaction (PCR), using primers 18S 965 and 18S 1573R (Powers et al. 2009). The PCR was performed in an Ivema T-18 thermocycler (Ivema Desarrollos, Argentina) using 5 µl of 5× Phire® reaction buffer, 200 µM dNTP, 0.4 pM of each primer, 100 ng of genomic DNA, and 0.5 µl of Phire® Hot Start II DNA polymerase (Finnzymes, Finland) and completed to 25 µl with molecular grade water. PCR conditions were as follows: 1 cycle at 98 °C for 3 min, followed by 35 cycles at 98 °C for 10 s, 57 °C for 20 s, 72 °C for 35 s; and 1 final cycle at 72 °C for 5 min. A negative control was included in each amplification run.

A phylogenetic analysis using the 18S rRNA sequences obtained in this study and others from closely related species previously published in the GenBank was performed with the maximum likelihood (ML) method by using the program MEGA 5.0 (Tamura et al. 2011). Best fitting substitution models were determined with the Akaike information criterion using the ML model test implemented in MEGA 5.0. Support for the topologies was tested by bootstrapping over 1000 replications.

## Results

In the present survey, we found liver lesions consistent with *C. hepaticum* infection in 64 of 409 rodents (15.6%), recovering in all cases female nematodes and eggs. Table 1 shows details of the findings by site and host species. The most frequently parasitized species was *A. azarae*.

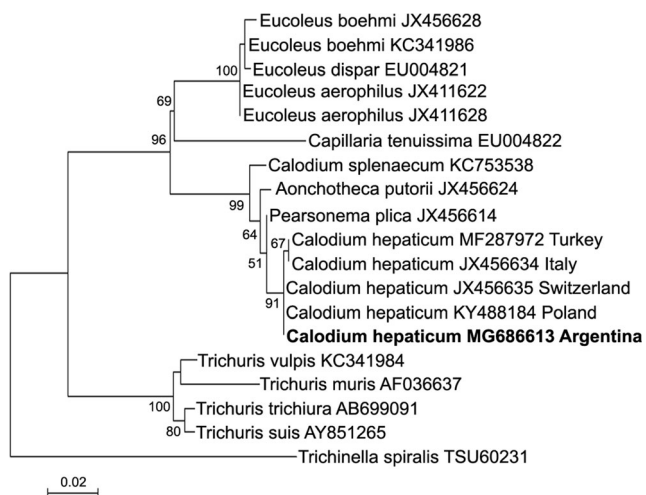
**Table 1** Host species parasitized by *C. hepaticum* in two studies sites (Esperanza [ES], Santa Fe, and La Picada [LP], Entre Ríos, Argentina). *P*, prevalence; *CI*, 95% confidence interval

	<i>A. azarae</i>	<i>C. callidus</i>	<i>C. venustus</i>	<i>H. chacarius</i>	<i>N. lasiurus</i>	<i>O. flavescens</i>	<i>O. nigripes</i>	<i>O. rufus</i>
ES	<i>P</i> = 41.2% (49/119), <i>CI</i> = 32–50%	–	<i>P</i> = 1% (2/100), <i>CI</i> = 0.3–7%	0/14	0/5	<i>P</i> = 7.1% (3/42), <i>CI</i> = 1–17%	<i>P</i> = 6.7% (1/15), <i>CI</i> = 0.3–30%	–
LP	<i>P</i> = 7.7% (2/26), <i>CI</i> = 1–26%	<i>P</i> = 13.8% (3/29), <i>CI</i> = 4–32%	–	0/2	–	0/9	–	<i>P</i> = 6.4% (4/49), <i>CI</i> = 1–18%

Male specimens were not found. The morphological characters observed in female specimens agree with the description given by Wright (1961).

A fragment of the 18S rRNA gene was amplified from three adult female worms. These worms were obtained from heavily parasitized hosts (two *A. azarae* and one *C. callidus*) and were selected because they could be dissected completely, being free from host liver tissue. The resulting sequences (excluding primers) were 100% identical (600/600) to the corresponding 18S rRNA sequence of *C. hepaticum* (KT875351) obtained from *R. norvegicus* in Argentina. Complete identity was also observed with smaller overlapping segments of 18S rRNA of *C. hepaticum* from other hosts in the Old World (JX456635, Switzerland, *Arvicola terrestris* Linnaeus, 1758) (Guardone et al. 2013). The phylogenetic tree (Fig. 1) inferred from maximum likelihood analysis of the 18S rRNA sequences from *C. hepaticum* and other species of Trichinelloidea showed that *C. hepaticum* from Argentina nested in a clade together with *C. hepaticum* from Italy, Switzerland, Poland, and Turkey. Consensus sequence from *C. hepaticum* 18S rRNA gene from this study was deposited in GenBank (accession number MG686613).

Histopathology of 40 subsamples identified lesions consistent with *C. hepaticum* infection.

**Fig. 1** Dendrogram based on the partial 18S rRNA gene sequences of *Calodium hepaticum* and related species of Trichinelloidea

## Discussion

In this study, we report *C. hepaticum* infection in six Sigmodontinae species, all new hosts for this parasite. This is the first report of *C. hepaticum* in Sigmodontinae rodents from Argentina and the second record in this subfamily for South America. In addition, this is the first report of *C. hepaticum* in Sigmodontinae rodents confirmed by molecular analysis. In Table 2, we offer a summary of the existing reports *C. hepaticum* in Muroidea rodents from South America, including the results of this survey.

Spratt and Singleton (2001) described that *C. hepaticum* females move through host hepatic parenchyma, destroying hepatocytes. Subsequent encapsulation is by fibrous connective tissue of the host (Rothenburger et al. 2014). Interestingly, there are no studies describing the sex of adult *C. hepaticum* recovered from the liver. The absence of males in the liver parenchyma is surprising and suggests that new studies should establish whether they are naturally scarce or if they are present in other organs.

The dendrogram based on partial 18S rRNA gene sequences (Fig. 1) shows a remarkable separation of Capillariidae nematodes, where one clade groups respiratory parasites (*Eucoleus aerophilus*, *Eucoleus boehmi*, and *Eucoleus dispar*) and another capillariids colonizing abdominal organs of mammals (*Calodium splenaecum*, *Aonchotheca putorii*, *Pearsonema plica*, and *C. hepaticum*), as previously shown by Guardone et al. (2013). No difference was observed between the 18S rRNA sequences obtained from *C. hepaticum* hosted in Sigmodontinae in the present study and those reported from *C. hepaticum* hosted in *Rattus* spp. from different geographical origins (Argentina, KT875351, and Poland, KY488184) and in *Arvicola terrestris* Linnaeus, 1758 (Switzerland, JX456635–JX456636). Moreover, a minimal difference was observed (599/600 bp) when compared to the 18S rRNA sequence of *C. hepaticum* infesting *Cricetulus migratorius* Pallas, 1773 (Turkey, MF287972) and *Vulpes vulpes* Linnaeus, 1758 (Italy, JX456631–JX456634). Previous studies demonstrated that dissemination of invasive species, as *Rattus* spp., played a key role in the introduction of parasites in new geographical areas (Hayman et al. 2013; Kosoy et al. 2015; Puckett et al. 2016), which in turn may lead to altered parasite community dynamics (Telfer et al. 2010). In this regard, our results suggest that *C. hepaticum* originally circulating in

**Table 2** *Calodium hepaticum* in Muroidea rodents from South America. Host species, geographic location, infection prevalence (P %), and references

Species	P (%)	Country (city)	Reference
<i>Rattus norvegicus</i>	20.1	Colombia (Medellín)	Duque et al. 2012
	45.0	Brazil (Rio de Janeiro)	Simoes et al. 2014
	NA	Brazil (Salvador-Bahía)	Ferreira and Andrade 1993
	56.5	Brazil (Bahía)	Galvao 1981
	83.0	Brazil (Salvador)	Walker et al. 2016
	54.1	Brazil (Belém)	Moreira et al. 2013
	NA	Chile (Santiago)	Rojas et al. 1971
	33.3	Chile (Valdivia)	Torres and Gonzalez 1972
	30.0	Argentina (Buenos Aires)	Hancke et al. 2011
	<i>Rattus rattus</i>	64.0	Brazil (Bahía)
43.1		Brazil (Sao Paulo)	Meira 1931
2.0		Brazil (Porto Velho)	Rocha et al. 2015
NA		Brazil (Bahía)	Ferreira and Andrade 1993
38.4		Brazil (Belém)	Moreira et al. 2013
69.8		Brazil (Sao Paulo)	Almeida-Silva et al. 2011
<i>Species</i>		Prev. (%)	Country- City
<i>Akodon venezuelensis</i>	NA	Venezuela	Vogelsang and Espin 1949
<i>Akodon azarae</i>	41.2	Argentina (Santa Fe)	Present paper
	7.7	Argentina (Entre Ríos)	Present paper
<i>Calomys callidus</i>	13.8	Argentina (Entre Ríos)	Present paper
<i>Calomys venustus</i>	0.9	Argentina (Santa Fe)	Present paper
<i>Oligoryzomys flavescens</i>	7.1	Argentina (Santa Fe)	Present paper
<i>Oligoryzomys nigripes</i>	6.7	Argentina (Santa Fe)	Present paper
<i>Oxymycterus rufus</i>	6.4	Argentina (Entre Ríos)	Present paper

NA, no prevalence data reported

Europe and Asia might have been introduced into the New World by rats, which transmitted the parasite to sigmodontine rodents. So far, paleoparasitological studies found no evidence of the presence of this parasite prior to rat introductions in the New World. However, further research on the phylogeography of *C. hepaticum* is necessary to test this hypothesis. Like in other parts of the world, in South America, *Rattus* spp. have high prevalence of *C. hepaticum*, ranging from 2 to 83% (see Table 2). In Argentina, *C. hepaticum* was only reported in *R. norvegicus* with a prevalence above 30% in Buenos Aires Province (Hancke et al. 2011). The only previous reports of *C. hepaticum* in Sigmodontinae rodents are *Akodon venezuelensis* from Venezuela (Vogelsang and Espin 1949) and *S. hispidus* from Florida, USA (Kinsella 1974); however, these diagnoses were attained only by assessment of the presence/absence of gross lesions. The prevalences reported here in Sigmodontinae rodents were lower than those found in rats, except for *A. azarae* from Santa Fe, where the prevalence was 41.2%.

In summary, an analysis of the genetic findings and the prevalences observed here, together with the existing information on *C. hepaticum*, leads us to propose that *Rattus* spp. brought *C. hepaticum* to the New World exposing Sigmodontinae rodents, which are frequently infected by this parasite. The prevalence

levels observed in *A. azarae* suggest that this host may be playing an important role in *C. hepaticum* dynamics in the New World.

**Acknowledgements** Special thanks are given to Pablo Teta and Ulyses Pardiñas for the identification of the hosts; Pablo Cuervo for the help in the assembly of the figures; Alfredo Berduc, María Lucía Reynoso, Camilo Andrés Fernández, Agustín Fasano, Ivana Monsalvo, Natalia Mordini, Tamara Ricardo, Pablo Hernán Capovilla, and Cintia Palavecino for their collaboration during fieldwork.

**Funding information** María C. Fantozzi is a fellow of the Consejo Nacional de Investigaciones Científicas y Técnicas (CONICET, Argentina). This study was supported by grants from CONICET and Agencia Nacional de Promoción Científica y Tecnológica (ANPCyT), project number: PICT 2012-1552.

### Compliance with ethical standards

**Ethical considerations** Sample collection was carried out during fieldwork under official permits granted by the Dirección General de Recursos Naturales, Gobierno de Entre Ríos (autorización no. 002/14 and 001/16, Expediente 1.657.179) and Ministerio de Aguas, Servicios Públicos y Medio Ambiente, Gobierno de Santa Fe (authorization number 193, file 02101-0014145-3). This study was carried out in accordance with protocol no. 135/12 approved by the bioethics committee of Facultad de Ciencias Veterinarias, Universidad Nacional del Litoral. Specimens collected in live traps were humanely sacrificed (euthanized by cervical dislocation while

being deeply anesthetized with isoflurane), following the recommendations of the Ethics Committee for Research on Laboratory Animals, Farm and Obtained from Nature of the National Council of Scientific and Technical Research (CONICET), and subsequently by ANPCCyT. No endangered species were involved in this study.

**Conflict of interest** The authors declare that they have no conflict of interest.

## References

- Almeida-Silva MJF, Fava CD, Potenza M, Reis F, Campos ADC (2011) Diagnosis of *Capillaria hepatica* in *Rattus rattus* by histopathology. In 7th International Conference on Urban Pests, Ouro Preto, Brazil, pp. 233–235. In: Fuehrer HP (2014a) An overview of the host spectrum and distribution of *Calodium hepaticum* (syn. *Capillaria hepatica*): part 1—Muroidea. *Parasitol Res* 113:619–640
- Bush AO, Lafferty KD, Lotz JM, Shostak AW (1997) Parasitology meets ecology on its own terms: Margolis et al. revisited. *J Parasitol* 83: 575–583. <https://doi.org/10.2307/3284227>
- Callejón R, Robles MR, Panei CJ, Cutillas C (2016) Molecular diversification of *Trichuris* spp. from Sigmodontinae (Cricetidae) rodents from Argentina based on mitochondrial DNA sequences. *Parasitol Res* 115:2933–2945. <https://doi.org/10.1007/s00436-016-5045-y>
- Camargo LMA, Camargo JDSA, de Souza Vera LJ, Barreto PDT, Tourinho EK, de Souza MM (2010) Capillariasis (Trichurida, Trichinellidae, *Capillaria hepatica*) in the Brazilian Amazon: low pathogenicity, low infectivity and a novel mode of transmission. *Parasit Vectors* 3:11. <https://doi.org/10.1186/1756-3305-3-11>
- Ceruti R, Sonzogni O, Origgi F, Vezzoli F, Cammarata S, Giusti AM, Scanziani E (2001) *Calodium hepaticum* infection in wild brown rats (*Rattus norvegicus*) from the urban area of Milan, Italy. *J Vet Med B Infect Dis Vet Public Health* 48:235–240. <https://doi.org/10.1046/j.1439-0450.2001.00436.x>
- D'Elia G, Pardiñas UFJ (2015) Subfamily Sigmodontinae Wagner, 1843. In Patton JL, Pardiñas UFJ, D'Elia G (Eds.) *Mammals of South America*. Volume 2 – Rodents. University of Chicago Press, Chicago, Illinois pp. 63–70
- Duque BA, Aranzazu D, Agudelo-Flórez P, Londoño AF, Quiroz VH, Rodas JD (2012) *Rattus norvegicus* as an indicator of circulation of *Capillaria hepatica* and *Taenia taeniaeformis* on a groceries trade center of Medellín, Colombia. *Biomédica* 32:510–518. <https://doi.org/10.1590/S0120-41572012000400006>
- Ferreira LA, Andrade ZA (1993) *Capillaria hepatica*: a cause of septal fibrosis of the liver. *Mem Inst Oswaldo Cruz* 88:441–447. <https://doi.org/10.1590/S0074-02761993000300015>
- Fuehrer HP (2014a) An overview of the host spectrum and distribution of *Calodium hepaticum* (syn. *Capillaria hepatica*): part 1—Muroidea. *Parasitol Res* 113:619–640
- Fuehrer HP (2014b) An overview of the host spectrum and distribution of *Calodium hepaticum* (syn. *Capillaria hepatica*): part 2—Mammalia (excluding Muroidea). *Parasitol Res* 113:641–651
- Fuehrer HP, Igel P, Auer H (2011) *Capillaria hepatica* in man—an overview of hepatic capillariasis and spurious infections. *Parasitol Res* 109:969–979. <https://doi.org/10.1007/s00436-011-2494-1>
- Galvão VA (1976) *Capillaria hepatica*, incidence study in rats of Salvador, Bahia, and preliminary immunopathological data. *Rev Soc Bras Med Trop* 10:333–338
- Galvão VA (1981) Estudos sobre *Capillaria hepatica*: uma avaliação do seu papel patogênico para o homem. *Mem Inst Oswaldo Cruz* 76: 415–433. <https://doi.org/10.1590/S0074-02761981000400010>
- Goncálvez PR, De Oliveira JA (2004) Morphological and genetic variation between two sympatric forms of *Oxymycterus* (Rodentia: Sigmodontinae): an evaluation of hypotheses of differentiation within the genus. *J Mammal* 85:148–161. <https://doi.org/10.1644/BER-012>
- Guardone L, Deplazes P, Macchioni F, Mag JM, Mathis A (2013) Ribosomal and mitochondrial DNA analysis of Trichuridae nematodes of carnivores and small mammals. *Vet Parasitol* 197:364–369. <https://doi.org/10.1016/j.vetpar.2013.06.022>
- Hancke D, Navone G, Suarez O (2011) Endoparasite community of *Rattus norvegicus* captured in a shantytown of Buenos Aires City, Argentina. *Helminthologia* 48:167–173
- Hayman DTS, McDonald KD, Kosoy M (2013) Evolutionary history of rat-borne Bartonella: the importance of commensal rats in the dissemination of bacterial infections globally. *Ecol Evol* 3:3195–3203. <https://doi.org/10.1002/ece3.702>
- Kinsella JM (1974) Comparison of helminth parasites of the cotton rat, *Sigmodon hispidus*, from several habitats in Florida. *Am Mus Novit* 2540:1–11 <http://digitallibrary.amnh.org/handle/2246/2742>
- Kosoy M, Khlyap L, Cosson JF, Morand S (2015) Aboriginal and invasive rats of genus *Rattus* as hosts of infectious agents. *Vector Borne Zoonotic Dis* 15:3–12. <https://doi.org/10.1089/vbz.2014.1629>
- Massoia E, Fornes A (1965) Contribución al conocimiento de los roedores miomorfos argentinos vinculados con la fiebre hemorrágica argentina. Ministerio de Asuntos Sociales y Salud Pública de la Nación, Difusión de la Comisión Nacional Coordinadora para el Estudio y Lucha contra la Fiebre Hemorrágica Argentina
- Massoia E (1973) Descripción de *Oryzomys fornesi*, nueva especie y nuevos datos sobre algunas especies y subespecies argentinas del subgénero *Oryzomys* (*Oligoryzomys*) (Mammalia – Rodentia – Cricetidae). *Revista de Investigaciones Agropecuarias, INTA, Serie 1, Biología y Producción Animal* 10: 21–37
- Meira JA (1931) Nota sobre helmintos encontrados nos ratos de São Paulo. *Brasil Med* 45:1212–1216
- Moravec F (1982) Proposal of a new systematic arrangement of nematodes of the family Capillariidae. *Folia Parasitol* 29:119–132
- Moreira VLC, Giese EG, Silva DCBD, Melo FTDV, Furtado AP, Maldonado A Jr, Santos JND (2013) *Calodium hepaticum* (Nematoda: Capillariidae) in synanthropic rodents (*Rattus norvegicus* and *Rattus rattus*) in Eastern Amazonia. *Rev Bras Parasitol Vet* 22: 265–269. <https://doi.org/10.1590/S1984-29612013000200046>
- Powers TO, Neher DA, Mullin P, Esquivel A, Giblin-Davis RM, Kanzaki N, Stock SP, Mora MM, Uribe-Lorio L (2009) Tropical nematode diversity: vertical stratification of nematode communities in a Costa Rican humid lowland rainforest. *Mol Ecol* 18:985–996
- Puckett EE, Park J, Combs M, Blum MJ, Bryant JE, Caccone A, Costa F, Deinum EE, Esther A, Himsforth CG, Keightley PD (2016) Global population divergence and admixture of the brown rat (*Rattus norvegicus*). *Proc R Soc B* 283:20161762. <https://doi.org/10.1098/rspb.2016.1762>
- Robles MR, Cutillas C, Callejón R (2018) Morphological-molecular characterization and phylogenetic relationships of a new *Trichuris* species (Nematoda: Trichuridae) parasitic on *Holochilus chacarius* (Cricetidae: Sigmodontinae) from the Chaco ecoregion (Argentina). *Infec Genet Evol* 58:66–76. <https://doi.org/10.1016/j.meegid.2017.11.029>
- Robles MR, Cutillas C, Panei CJ, Callejón R (2014) Morphological and molecular characterization of a new *Trichuris* species (Nematoda: Trichuridae), and phylogenetic relationships of *Trichuris* species of cricetid rodents from Argentina. *PLoS One* 9:e112069. <https://doi.org/10.1371/journal.pone.0112069>
- Rocha EJGD, Basano SDA, Souza MMD, Honda ER, Castro MBD, Colodel EM, Camargo LMA et al (2015) Study of the prevalence of *Capillaria hepatica* in humans and rodents in an urban area of the city of Porto Velho, Rondônia, Brazil. *Rev Inst Med Trop São Paulo* 57:39–46. <https://doi.org/10.1590/S0036-46652015000100006>

- Rojas A, Villarroel F, Diaz F, Rubio P, Schenone H (1971) Investigación de triquinosis y capilariasis hepática en *Rattus norvegicus* del Matadero Municipal de Santiago (Chile). *Bol Chil Parasitol* 26:65–66
- Rothenburger J, Himswoth CG, Chang V, LeJeune M, Leighton FA (2014) *Capillaria hepatica* in wild Norway rats (*Rattus norvegicus*) from Vancouver, Canada. *J Wildl Dis* 50:628–633. <https://doi.org/10.7589/2013-09-256>
- Simões RO, Luque JL, Faro MJ, Motta E, Maldonado JR (2014) Prevalence of *Calodium hepaticum* (syn. *Capillaria hepatica*) in *Rattus norvegicus* in the urban area of Rio de Janeiro, Brazil. *Rev Inst Med Trop São Paulo* 56:455–457. <https://doi.org/10.1590/S0036-46652014000500016>
- Spratt DM, Singleton GR (2001) Hepatic capillariasis. In: Samuel WM, Pybus MJ, Kocan AA (eds) *Parasitic diseases of wild mammals*. Iowa State University Press, Ames, pp 365–379
- Tamura K, Peterson D, Peterson N, Stecher G, Nei M, Kumar S (2011) MEGA5: molecular evolutionary genetics analysis using maximum likelihood, evolutionary distance, and maximum parsimony methods. *Mol Biol Evol* 28:2731–2739. <https://doi.org/10.1093/molbev/msr121>
- Telfer S, Lambin X, Birtles R, Beldomenico P, Burthe S, Paterson S, Begon M (2010) Species interactions in a parasite community drive infection risk in a wildlife population. *Science* 330:243–246. <https://doi.org/10.1126/science.1190333>
- Torres P, Gonzalez H (1972) Capilariasis hepática en Valdivia, primera comprobación en Chile. *Arch Med Vet* Vol 4:30–32. In: Fuehrer HP (2014a) An overview of the host spectrum and distribution of *Calodium hepaticum* (syn. *Capillaria hepatica*): part 1—Muroidea. *Parasitol Res* 113:619–640
- Vogelsang EG, Espin J (1949) Dos nuevos huéspedes para *Capillaria hepatica* (BANCROFT, 1893) TRAVASSOS 1915; nutria (*Myopotamus coypus*) y el ratón mochilero (*Akodon venezuelensis*). *Rev Med Vet Parasitol* 8: 73–78. In: Fuehrer HP (2014a) An overview of the host spectrum and distribution of *Calodium hepaticum* (syn. *Capillaria hepatica*): part 1—Muroidea. *Parasitol Res* 113:619–640
- Walker R, Carvalho-Pereira T, Serrano S, Pedra G, Hacker K, Taylor J, Souza FN et al (2016) Factors affecting carriage and intensity of infection of *Calodium hepaticum* within Norway rats (*Rattus norvegicus*) from an urban slum environment in Salvador, Brazil. *Epidemiol Infect* 145:334–338
- Wright KA (1961) Observations on the life cycle of *Capillaria hepatica* (Bancroft, 1893) with a description of the adult. *Can J Zool* 39:167–182. <https://doi.org/10.1139/z61-022>